

CASE REPORT

I Baran
R Nalcaci
M Kocak

Dyskeratosis congenita: clinical report and review of the literature

Authors' affiliations:

Ilgi Baran, Department of Prosthetic Dentistry, Faculty of Dentistry, Kırıkkale University, Kırıkkale, Turkey
Rana Nalcaci, Department of Oral Diagnosis and Radiology, Faculty of Dentistry, Kırıkkale University, Kırıkkale, Turkey
Mukadder Kocak, Department of Dermatology, Faculty of Medicine, Kırıkkale University, Kırıkkale, Turkey

Correspondence to:

Dr Ilgi Baran
Department of Prosthetic Dentistry
Faculty of Dentistry
Kırıkkale University
Yeni Dogan Mah. Mimar Sinan Cad.
No. 25, 71100 Kırıkkale
Turkey
Tel.: +90 318 2244927
Fax: +90 318 2250685
E-mail: ilgice@hotmail.com

Abstract: Dyskeratosis congenita (DKC) is an inherited disorder that usually presents in males, consisting of the triad of leukoplakia of the mucous membranes, nails dystrophy and skin pigmentation. Oral and dental abnormalities may also be present. Most cases are X-linked autosomal dominant, but recessive forms have also been reported. This study describes herein a case in which the classic triad of signs was present, along with the development of leukoplakia in the buccal mucosa. Our patient, a 25-year-old man, presented with several characteristic systemic features of this condition, together with the following oral features: hypodontia, delayed dental eruption, short blunt roots, extensive caries, gingival inflammation and bleeding, loss of alveolar bone and buccal mucosa with leukoplakia and irregular ulcers. The patient was given full preventive care. The primary teeth were extracted under local anaesthesia. After establishing optimal oral health, oral hygiene instructions were given to the patient and he was rehabilitated with fixed and removable partial denture. Prosthetic treatments were carried out after establishing optimal oral health. This treatment option appears beneficial in this patient, resulting in rehabilitation of occlusion and less mechanical irritation to the oral mucosa.

Key words: dyskeratosis congenita; leukoplakia; oral mucosa

Dates:

Accepted 14 January 2009

To cite this article:

Int J Dent Hygiene
DOI: 10.1111/j.1601-5037.2009.00364.x
Baran I, Nalcaci R, Kocak M. Dyskeratosis congenita: clinical report and review of the literature.

© 2009 John Wiley & Sons A/S

Introduction

Dyskeratosis congenita (DKC; also known as Zinsser-Engman-Cole syndrome) is an unusual inherited disease characterized by the triad of abnormal skin pigmentation, nail dystrophy and mucosal leukoplakia (1–3). DKC is reported to have been first

described in 1906 by Zinsser. Bone marrow failure, which occurs in approximately 50% of cases, and predisposition to malignancy are principal causes of early mortality (3–5). The X-linked recessive form, with the most likely location Xq28, occurs only in males; however, in some instances it is transmitted in an autosomal dominant form, and autosomal recessive forms of the disease are also recognized (6–8) along with genitourinary, pulmonary, skeletal, neurological, ophthalmic, dental and gastrointestinal abnormalities (4, 9–15). Patients may suffer from some or all of these symptoms. DKC patients have characteristic abnormally shaped finger- and toenails, a lacy rash on the face and chest, and white patches in the mouth. Seventy-five per cent of the patients are males. About half of DKC patients develop bone marrow failure. Onset may be in early childhood, but diagnosis is often made later since the findings on physical examination become more obvious with age. Two genes have now been identified as causing DKC, but more remain to be discovered (16–24). Oral and dental abnormalities have been reported in a few cases (12, 16, 17, 25–36), and include: hypodontia (24, 25), short blunted roots (24, 25, 33), hypocalcification (6), thin enamel (33), gingival recession (24, 33), gingival inflammation with oedema (24), gingival bleeding (16, 25), alveolar bone loss (24, 25), periodontitis (24, 33), extensive caries (4, 16, 25, 33), smooth atrophic tongue mucosa (24, 33, 34), leukoplakia and lichen planus (25, 33).

Clinical report

A 25-year-old man was admitted to the Faculty of Dentistry, Department of Oral Diagnosis and Radiology, for prosthodontic treatment. On examination, the patient appeared generally well; there was apparent increased reticular pigmentation around the neck and shoulders, and mild dystrophy of the fingernails was noted. There was no regional lymphadenopathy associated with the patient's oral manifestation. He had 20 missing permanent teeth. Standing teeth included 17, 16, 54, 53, 52, 51, 65, 26, 27, 37, 34, 73, 72, 71, 81, 82, 45 and 47 (Fig. 1a and b). Oral hygiene was poor with plaque accumulation and gingival inflammation. The tongue was normal in size. Irregular white patches were present on the buccal mucosa. The ulcers in the mouth started at the age of 10 years. He appeared to have a slightly dry mouth. The oropharynx and fauces were normal. Angular cheilitis was present intermittently. Panoramic radiograph revealed the congenital absence of 18, 15, 14, 13, 12, 11, 21, 22, 23, 24, 25, 28, 38, 35, 33, 32, 31, 42, 42, 43, 48 and generalized alveolar bone loss, most markedly around 16, 26, 37, 47. A diagnosis of DKC was proposed, in view of oral mucosal leukoplakia combined with

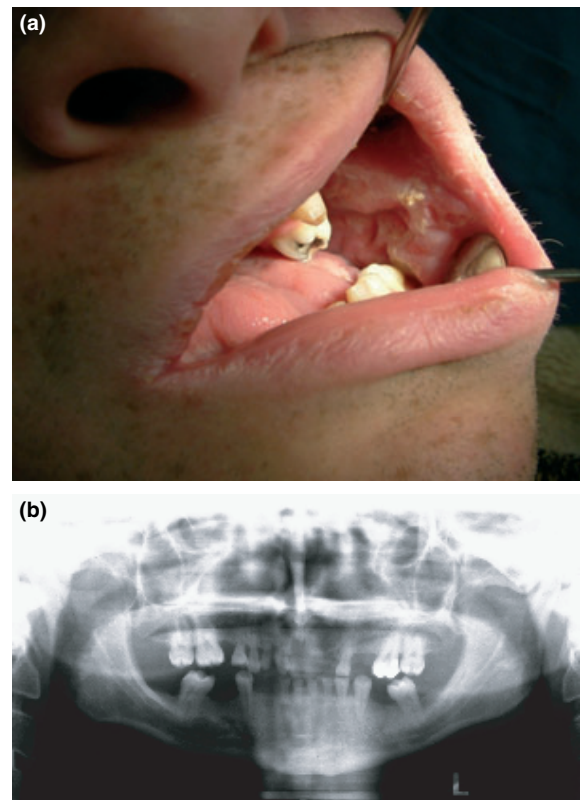


Fig. 1. Oral findings; irregular white patches were present on the buccal mucosa (a) and panoramic radiograph showing the present status of dentition included twelve primary teeth, six permanent teeth (b).

oligodontia, skin hyperpigmentation and nail dystrophy. He was referred to the Dermatology Department for definite diagnosis. The study was undertaken with the understanding and written consent of parents.

The patient was diagnosed as DKC in the Department of Dermatology. He presented with mild learning difficulties, growth retardation, mucosal leukoplakia, epiphora, oligodontia, micrognathia and nail dystrophy, and there was evidence of pancytopenia, alopecia and microcephaly.

Clinically, his skin was dry and coarse. Fine reticulated poikiloderma of sun-exposed areas with hyperpigmentation of the skin was obvious on the front of his neck and shoulders (Fig. 2). His hair was fine and sparse. All his nails were affected to varying degrees; the dystrophic changes apparently started at the age of 6 years and consisted of longitudinal ridging with irregular free edges, easily splitting nails with some brittleness and slight deformity (Fig. 3). Buccal mucosal lesions demonstrated leukoplakia presenting as an asymptomatic, asymmetric white plaque. The skin lesions were excised and multiple biopsy specimens of the lesions on the buccal mucosa were reported as hyperkeratosis, acanthosis, parakeratosis,

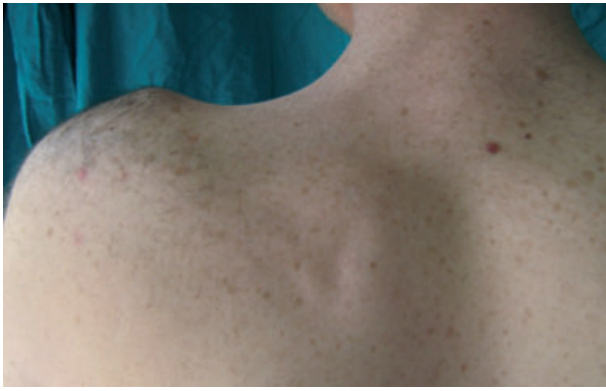

Fig. 2. Reticulate pigmentation of the skin was on the front of his neck and shoulders.

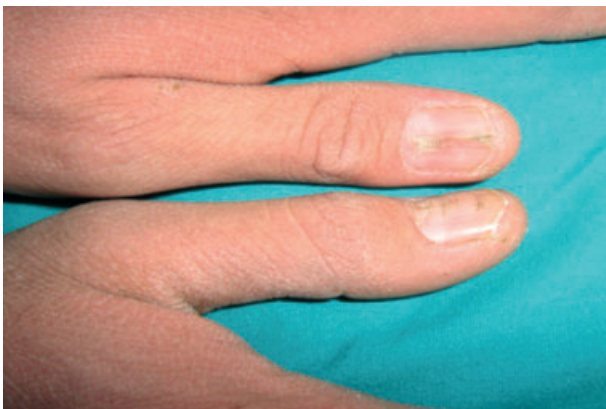

Fig. 3. Nail dystrophy in hand.

tosis and chronic inflammation. Pigmentary incontinence was also seen, all being features of leukoplakia.

Skin biopsy specimens from the areas of reticulated pigmentation typically show non-specific changes, including mild hyperkeratosis, epidermal atrophy, telangiectasia of the superficial blood vessels and melanophages in the papillary dermis. Interface changes have also been reported, with mild basal layer vacuolization and a lymphocytic inflammatory infiltrate in the upper dermis. Chest and skull X-rays showed no abnormality of the skeletal structures and general medical examination showed a normal patient.

A blood count revealed normal values, and biochemical tests revealed elevated alkaline phosphatase and bilirubin levels. Urea and electrolyte values were normal. Immunoglobulin and liver function tests were normal. He was the second of two children in the family, and his brother was unaffected. However, his uncle and father had oral findings of mucosal leukoplakia, poor oral hygiene, micrognathia and oligodontia.

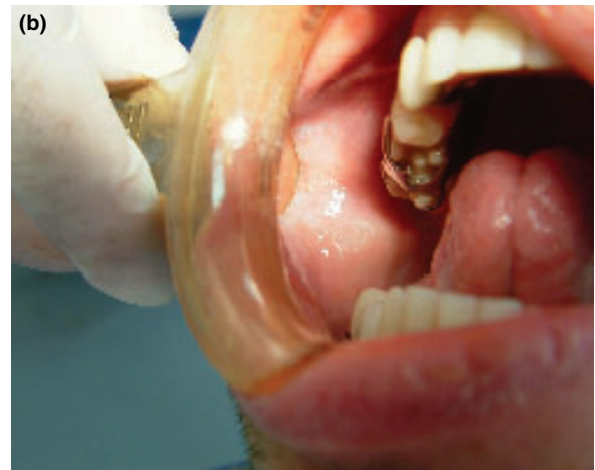
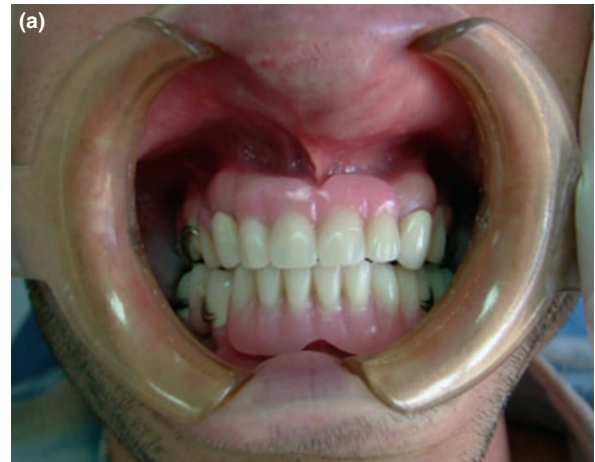
Fig. 4. Oral hygiene instructions were given to the patient and the patient was rehabilitated with fixed and removable partial denture (a). Clinical appearance of the buccal mucosa after therapy (b).

The dental treatment was performed according to plan. The treatment plan included a strict prevention protocol: cleaning; fluoride varnish was applied after restorative treatment, meticulous oral hygiene instructions; restorations of the permanent molars; extraction of primary teeth. The primary teeth were extracted under local anaesthesia. After establishing optimal oral health (e.g. restoration of carious teeth and scaling), oral hygiene instructions were given to the patient and he was rehabilitated with fixed and removable partial denture (Fig. 4a and b).

We present a patient of DKC with dental abnormality, oligodontia and leukoplakia. Oral rehabilitation of teeth and mucosal lesions are important not only because of aesthetics, checked occlusion and functional concerns, but also because there may be a positive psychological impact for the patient. This clinical report describes rehabilitation of a patient using fixed and removable partial denture. Treatment not only improves speech and masticatory function but also has

psychological implications that may greatly help in regaining self-confidence. Patients suffering from oligodontia may have severe psychological, aesthetic and functional problems. Thus, diagnosis and treatment of these patients are necessary for less mechanical irritation to the oral mucosa. It is emphasized that conventional prosthetic treatment can lead to a satisfactory result. The patient's speech and masticatory function improved greatly. He was also pleased with the better facial aesthetics. The patient is to be seen on a 6-month recall schedule, and he remains well.

Review of the literature

Skin abnormalities

The primary finding is abnormal skin pigmentation, with tan-to-grey hyperpigmented or hypopigmented macules and patches in a mottled or reticulated pattern. Reticulated pigmentation occurs in approximately 90% of patients (17). Poikilodermatous changes with atrophy and telangiectasia is common. The cutaneous presentation may clinically and histologically resemble graft versus host disease. The typical distribution involves the sun-exposed areas, including the upper trunk, neck and face (6). Other reported skin changes include alopecia of the scalp, eyebrows and eyelashes; premature greying of the hair; hyperhidrosis; hyperkeratosis of the palms and soles and adermatoglyphia (loss of dermal ridges on fingers and toes) (5, 6, 17, 26).

Nail abnormalities

Nail dystrophy is seen in approximately 90% of patients, with fingernail involvement often preceding toenail involvement (17). Progressive nail dystrophy begins with ridging and longitudinal splitting (5). Progressive atrophy, thinning, pterygium and distortion eventuate in small, rudimentary or absent nails (5, 6).

Mucosal abnormalities

Mucosal leukoplakia occurs in approximately 80% of patients and typically involves the buccal mucosa, tongue and oropharynx (17). This can occur on any mucosal surface, but has been most frequently reported as affecting the oral mucosa. The specific intra-oral sites previously published include lingual mucosa (12, 27–29), buccal mucosa (30) and the palate (31), with the tongue being the most frequently affected (32). The leukoplakia may become verrucous, and ulceration may occur

(31, 33). Lichen planus in association with DKC has previously been reported as the only oral manifestation in a case of two Singaporean Chinese cousins, in whom leukoplakia was not observed (33). Patients also may have an increased prevalence and severity of periodontal disease (6, 33, 34), hypocalcified teeth (6) and taurodontism (35, 36). We present a patient of DKC with dental abnormality, oligodontia and leukoplakia lesions on the buccal mucosa and tongue in this case. Prosthetic treatments were carried out after establishing optimal oral health. This treatment option appears beneficial in this patient, resulting in rehabilitation of occlusion and less mechanical irritation to the oral mucosa. Other mucosal sites may be involved (e.g. oesophagus, urethral meatus, glans penis, lacrimal duct, conjunctiva, vagina, anus) (6). Constriction and stenosis can occur at these sites, with subsequent development of dysphagia, dysuria, phimosis and epiphora (6, 16, 27).

Bone marrow failure

Bone marrow failure is reported as the principal cause of death in 70% of patients with DKC, as a consequence of bleeding or opportunistic infections with cytomegalovirus, *Pneumocystis carinii* or candida (5). In some patients, the development of bone marrow abnormalities may appear before the classical cutaneous manifestations, resulting in the initial diagnosis of idiopathic aplastic anaemia (17, 37–39). It has been shown that 85% of DKC patients have a peripheral cytopenia of one or more lineages, with approximately 75% of these patients developing pancytopenia (17). In 80% of these patients, the age of onset for the development of pancytopenia is less than 20 years of age, with half of them developing pancytopenia before 10 years. It has been estimated that 80–90% of patients will have developed bone marrow failure by the age of 30 (4, 17), with the figure approaching 94% by the age of 40 years (17). DKC patients also have features that overlap with Fanconi's anaemia, which is also characterized by bone marrow failure and a predisposition to malignancy (40, 41).

Pulmonary complications

Approximately 20% of individuals with DKC develop pulmonary complications, including pulmonary fibrosis and abnormalities of pulmonary vasculature (17). The mortality rate from these pulmonary complications has been estimated between 10% and 15% (17). Postmortem studies on two subjects who died suddenly from acute pulmonary failure showed

abnormalities of pulmonary vasculature and abnormally high levels of pulmonary fibrosis (17, 40). Pulmonary complications in the past may have been overlooked and may well provide the answer as to why there is such a high incidence of fatal pulmonary complications following bone marrow transplantation (17, 40, 42, 43). The recommendation is that DKC patients avoid taking drugs with pulmonary toxicity (e.g. busulfan) and that they have their lungs shielded from radiation during bone marrow transplantation (17, 44, 45).

Increased risk of malignancy

Patients have an increased prevalence of malignant mucosal neoplasms, particularly squamous cell carcinoma of the mouth (22, 23, 46), nasopharynx, oesophagus, rectum, vagina or cervix (6). These include ultrastructural change (47), p53 expression (48) and cytokeratin profiles (49, 50). Evidence for increased cellular activity revealed increased numbers of mitochondria, nucleoli and the retention of complex cell-to-cell contact at a time when most cells would be terminally differentiated. When DKC is complicated by malignant disease, the prognosis is generally considered to be poor. Other malignancies reported include Hodgkin lymphoma (51), adenocarcinoma of the gastrointestinal tract and bronchial and laryngeal carcinoma (17). There is a wide age variation in the initial presentation of clinical signs of DKC. Nail dystrophy, leukoplakia and skin hyperpigmentation tend to appear in the first decade of life (5, 39), with median ages of onset of 6, 7 and 8 years respectively. Malignancy tends to develop in the third decade of life (17, 52).

Neurological system findings

Other abnormalities reported include altered mental status and learning difficulties, microcephaly, intracranial calcifications, alopecia, hair greying, deafness and amyloidosis (52), peripheral neuropathy (53) and choanal atresia (54, 55).

Haematological findings

Haematological findings include anaemia (56, 57), marrow hypoplasia (35) and thrombocytopenia (37).

Ophthalmic system findings

Ophthalmic abnormalities include epiphora secondary to nasolacrimal duct obstruction, conjunctivitis, blepharitis, pterygium formation, ectropion, loss of eyelashes, strabismus, cataracts

and optic atrophy. These ophthalmic abnormalities have been observed in approximately half of DKC cases, with lacrimal duct stenosis resulting in epiphora being the most common (58–60).

Skeletal system findings

Patients may have mandibular hypoplasia, osteoporosis, avascular necrosis, abnormal bone trabeculation and scoliosis (61–63). The skeletal anomalies are reportedly seen in approximately 20% of cases (60–63).

Gastrointestinal system findings

These may include oesophageal webs, hepatosplenomegaly and cirrhosis. Gastrointestinal abnormalities reported in the literature include developmental oesophageal webs in the post-cricoid region resulting in dysphagia (6, 31, 34) which have been associated with malignant transformation (53), hepatomegaly and cirrhosis.

Genitourinary system findings

Hypospastic testes, hypospadias, phimosis, horse-shoe kidneys and ureteral stenosis are reported (5, 60).

Genetics and molecular basis

Female carriers of DKC may have subtle clinical features. A recent study showed that three of 20 female carriers had clinical features that included a single dystrophic nail, a patch of hypopigmentation or mild leukoplakia (5). Linkage analysis assigned location of the gene for DKC to Xq28 (64, 65). Positional cloning of the mutated gene at that locus followed and this is now known as DKC1 (NAP57) (2, 4, 65–67). Mutations in DKC have been shown to cause the X-linked form of DKC. The inheritance pattern of most cases of DKC is X-linked recessive, but autosomal dominant and recessive patterns have been reported (68–73).

Conclusion

Dyskeratosis congenita is a rare disease and systemic and oral symptoms of this disease should be kept in mind in dentistry. The present case demonstrated the multidisciplinary approach in the dental treatment of a patient suffering from DKC. The roles of oral diagnosis, dermatologist and prosthodontist were crucial in the planning and performing of the dental treatment.

Goals of dental treatment; free from acute infection, free from potential dental and gingival infection, observe the oral mucosa for ulcers and leukoplakia lesions. Oral rehabilitation of this patient helped to minimize mechanical irritation to the oral mucosa. Although the prognosis is good in this disease, the unexpected changes in haematological values and mucocutaneous malignant changes should be remembered. Furthermore, genetic counselling, early detection of the condition and referral to the dental and oral condition to manage and educate the patient regarding oral hygiene and dental and occlusal problems are important.

References

- Dokal I. Dyskeratosis congenita. *Br J Haematol* 1999; **105**: 11–15.
- Heiss NS, Knight SW, Vulliamy TJ *et al*. X-linked dyskeratosis congenita is caused by mutations in a highly conserved gene with putative nucleolar functions. *Nat Genet* 1998; **19**: 32–38.
- Davidson HR, Connor JM. Dyskeratosis congenita. *J Med Genet* 1988; **25**: 843–846.
- Knight S, Vulliamy TJ, Copplestone A, Gluckman E, Mason P, Dokal I. Dyskeratosis Congenita (DC) Registry: identification of new features of DC. *Br J Haematol* 1998; **103**: 990–996.
- Dokal I. Dyskeratosis congenita: an inherited bone marrow failure syndrome. *Br J Haematol* 1996; **92**: 775–779.
- Sirinavin C, Trowbridge AA. Dyskeratosis congenita: clinical features and genetic aspects: report of a family and review of the literature. *J Med Genet* 1975; **12**: 339–354.
- Vulliamy T, Marrone A, Szydlo R, Walne A, Mason PJ, Dokal I. Disease anticipation is associated with progressive telomere shortening in families with dyskeratosis congenita due to mutation in TERC. *Nat Genet* 2004; **36**: 447–449.
- Marrone A, Mason PJ. Dyskeratosis congenita. *Cell Mol Life Sci* 2003; **60**: 507–517.
- Elliot MA, Graham GE, Bernstein M, Mazer B, Teebi AS. Dyskeratosis congenita: an autosomal recessive variant. *Am J Med Gen* 1999; **83**: 178–182.
- Addison M, Rice MS. The association of dyskeratosis congenita and Fanconi's anaemia. *Med J Aust* 1965; **1**: 797–799.
- Bryan HG, Nixon RK. Dyskeratosis congenita and familial pancytopenia. *JAMA* 1965; **192**: 203–208.
- Milgrom H, Stoll HL, Crissey JT. Dyskeratosis congenita: a case with new features. *Arch Derm* 1964; **89**: 345–349.
- Selmanowitz VJ, van Volen GA. Fanconi's anemia and dyskeratosis congenita. *JAMA* 1971; **216**: 2015.
- Tchou PK, Kohn T. Dyskeratosis congenita: an autosomal dominant disorder. *J Am Acad Dermatol* 1982; **6**: 1034–1039.
- Brown KE, Kelly TE, Myers BM. Gastrointestinal involvement in a woman with dyskeratosis congenita. *Dig Dis Sci* 1993; **38**: 181–184.
- Drachtman RA, Alter BP. Dyskeratosis congenita. *Dermatol Clin* 1995; **13**: 33–39.
- Dokal I. Dyskeratosis congenita in all its forms. *Br J Haematol* 2000; **110**: 768–779.
- Vulliamy TJ, Marrone A, Knight SW, Walne A, Mason PJ, Dokal I. Mutations in dyskeratosis congenita: their impact on telomere length and the diversity of clinical presentation. *Blood* 2006; **107**: 2680–2685.
- Bessler M, Wilson DB, Mason PJ. Dyskeratosis congenita and telomerase. *Curr Opin Pediatr* 2004; **16**: 23–28.
- Treister N, Lehman LE, Cherrick I, Guinan EC, Woo SB. Dyskeratosis congenita vs. chronic graft versus host disease: report of a case and a review of the literature. *Oral Surg Oral Med Oral Pathol Oral Radiol Endol* 2004; **98**: 566–571.
- Hreidarsson S, Kristjansson K, Johannesson G, Johannsson JH. A syndrome of progressive pancytopenia with microcephaly, cerebellar hypoplasia and growth failure. *Acta Paediatr Scand* 1988; **77**: 773–775.
- Baykal C, Kavak A, Gülcan P, Büyükbabani N. Dyskeratosis congenita associated with three malignancies. *J Eur Acad Dermatol Venerol* 2003; **17**: 216–218.
- Moretti S, Spallanzani A, Chiarugi A, Muscarella G, Battini ML. Oral carcinoma in a young man: a case of dyskeratosis congenita. *J Eur Acad Dermatol Venerol* 2000; **14**: 123–125.
- Yavuzilmaz E, Yamalik N, Yetgin S, Kansu O. Oral-dental findings in dyskeratosis congenita. *J Oral Pathol Med* 1992; **21**: 280–284.
- Brown CJ. Dyskeratosis congenita: report of a case. *Int J Paediatr Dent* 2000; **10**: 328–334.
- Joshi RK, Atukorala DN, Abanmi A, Kudwah A. Dyskeratosis congenita in a female. *Br J Dermatol* 1994; **130**: 520–522.
- Cannel H. Dyskeratosis congenita. *Br J Oral Surg* 1971; **9**: 8–10.
- Inoue S, Mekarrik G, Mahallat M, Zuelzer WW. Dyskeratosis congenita with pancytopenia. Another constitutional anaemia. *Am J Dis Child* 1973; **126**: 384–389.
- Sedano HO, Sauk JJ, Gorlin RJ. *Oral Manifestations of Inherited Disorders*. London, Butterworths, 1977, 55.
- Ortega JA, Swanson VL, Landing BH, Hammond GD. Congenital dyskeratosis. Zinsser-Engman-Cole syndrome with thymic dysplasia and aplastic anemia. *Am J Dis Child* 1972; **124**: 701–705.
- Sorrow JM, Hitch JM. Dyskeratosis congenita. First report of its occurrence in a female and a review of the literature. *Arch Dermatol* 1963; **86**: 114–115.
- Ling NS, Fenske NA, Julius RL, Espinoza CG, Drake LA. Dyskeratosis in a girl simulating chronic graft vs host disease. *Arch Dermatol* 1985; **121**: 1424–1428.
- Loh HS, Koh ML, Giam YC. Dyskeratosis congenita in two male cousins. *Br J Oral Maxillofac Surg* 1987; **25**: 492–499.
- Wald C, Diner H. Dyskeratosis congenita with associated periodontal disease. *Oral Surg Oral Med Oral Pathol* 1974; **37**: 736–744.
- Jacobs P, Saxe N, Gordon W, Nelson M. Dyskeratosis congenita. Haematologic, cytogenic and dermatologic studies. *Scand J Haematol* 1984; **32**: 461–468.
- Jorgenson RJ. The conditions manifesting taurodontism. *Am J Med Genet* 1982; **11**: 435–442.
- De Boeck K, Degreef H, Verwilghen R, Corbeel L, Casteels-Van Daele M. Thrombocytopenia: first symptom in a patient with dyskeratosis congenita. *Pediatrics* 1981; **67**: 898–903.
- Forni GL, Melevendi C, Jappelli S, Rasore-Quartino A. Dyskeratosis congenita: unusual presenting features within a kindred. *Paediatr Hematol Oncol* 1993; **10**: 145–149.
- Philips RJ, Judge M, Webb D, Harper JI. Dyskeratosis congenita: delay in diagnosis and successful treatment of pancytopenia by bone marrow transplantation. *Br J Dermatol* 1992; **127**: 278–280.
- Dokal I, Bungey J, Williamson P, Oscier D, Hows C, Luzatto L. Dyskeratosis congenita fibroblasts are abnormal and have unbalanced chromosomal rearrangements. *Blood* 1992; **80**: 3090–3096.

- 41 Auerbach AD, Buchwald M, Joenje H. Fanconi anemia. In: Vogelstein B, Kinzler KW, eds. *The Genetic Basis of Human Cancer*. New York, Mc Graw-Hill, 1998, 317–332.
- 42 Kehrer H, Krone W. Chromosome abnormalities in cell cultures derived from the leukoplakia of a female patient with dyskeratosis congenita. *Am J Med Genet* 1992; **42**: 217–218.
- 43 Kehrer H, Krone W, Schindler D, Kaufmann R, Schrenzenmeier H. Cytogenetic studies of skin fibroblast cultures from a karyotypically normal female with dyskeratosis congenita. *Clin Genet* 1992; **41**: 129–134.
- 44 Langston AA, Sanders JE, Deeg HJ et al. Allogeneic marrow transplantation for aplastic anaemia associated with dyskeratosis congenita. *Br J Haematol* 1996; **92**: 758–765.
- 45 Berthou C, Devergie A, D'Agay MF et al. Late vascular complications after bone marrow transplantation for dyskeratosis congenita. *Br J Haematol* 1991; **79**: 335–336.
- 46 Sabesan T, Baheerathan NN, Ilankovan V. Dyskeratosis congenita: its connections with oral and maxillofacial surgery. *Br J Oral Maxillofac Surg* 2007; **45**: 156–158.
- 47 McKay GS, Ogden GR, Chisholm DM. Lingual hyperkeratosis in dyskeratosis congenita: preliminary ultrastructural report. *J Oral Pathol Med* 1991; **20**: 196–199.
- 48 Ogden GR, Lane DP, Chisholm DM. p53 expression in dyskeratosis congenita: a marker for oral premalignancy? *J Clin Pathol* 1993; **46**: 169–170.
- 49 Ogden GR, Chisholm DM, Leigh IM, Lane EB. Cytokeratin profiles in dyskeratosis congenita: an immunocytochemical investigation of lingual hyperkeratosis. *J Oral Pathol Med* 1992; **21**: 353–357.
- 50 Mahiques L, Febrer I, Vilata JJ, Fortea JM. A case of dyskeratosis congenita associated with schizophrenia and two malignancies. *J Eur Acad Dermatol Venereol* 2006; **20**: 1159–1160.
- 51 Connor JM, Teague RH. Dyskeratosis congenita. Report of a large kindred. *Br J Dermatol* 1981; **105**: 321–325.
- 52 Ogden GR, Connor E, Chisholm DM. Dyskeratosis congenita. Report of a case and review of the literature. *Oral Surg Oral Med Oral Pathol* 1988; **65**: 586–591.
- 53 Ip P, Knight R, Dokal I, Manzur AY, Muntoni F. Peripheral neuropathy – a novel finding in dyskeratosis congenita. *Eur J Paediatr Neurol* 2005; **9**: 85–89.
- 54 Schamberg IL. Dyskeratosis congenita with pigmentation, dystrophy unguium and leukokeratosis oris. *Arch Dermatol* 1960; **81**: 266.
- 55 Lener EV, Tom WL, Cunningham BB. Dyskeratosis congenita in an adolescent girl with associated choanal atresia. *Pediatr Dermatol* 2005; **22**: 31–35.
- 56 Womer R, Clark JE, Wood P, Sabio H, Kelley TE. Dyskeratosis congenita: two examples of this multisystem disorder. *Pediatrics* 1983; **71**: 603–609.
- 57 Dokal I, Vulliamy T. Dyskeratosis congenita: its link to telomerase and aplastic anaemia. *Blood Rev* 2003; **17**: 217–225.
- 58 Chambers JK, Salinas CF. Ocular findings in dyskeratosis congenita. *Birth Defects Orig Artic Ser* 1982; **18**: 167–174.
- 59 Handley TPB, Ogden GR. Dyskeratosis congenita: oral hyperkeratosis in association with lichenoid reaction. *J Oral Pathol Med* 2006; **35**: 508–512.
- 60 Handley TPB, McCaul JA, Ogden GR. Dyskeratosis congenita. *Oral Oncol* 2006; **42**: 331–336.
- 61 Kelly TE, Stelling CB. Dyskeratosis congenita: radiological features. *Paediatr Radiol* 1982; **12**: 31–36.
- 62 Kalb RE, Grossman ME, Hutt C. Avascular necrosis of bone in dyskeratosis congenita. *Am J Med* 1986; **80**: 511–513.
- 63 Liebllich CM, Auerbach R, Auerbach AD. Dyskeratosis congenita and intracranial calcification. *Arch Dermatol* 1981; **117**: 523–524.
- 64 Connor JM, Gatherer D, Gray FC, Pirrit LA, Affara NA. Assignment of the gene for dyskeratosis congenita to Xq28. *Hum Genet* 1986; **72**: 348–351.
- 65 Arngrimsson R, Dokal I, Luzzatto L, Connor JM. Dyskeratosis congenita: three additional families show linkage to a locus in Xq28. *J Med Genet* 1993; **30**: 618–619.
- 66 Hassock S, Vetrie D, Giannelli F. Mapping and characterization of the X-linked dyskeratosis congenita (DKC) gene. *Genomics* 1999; **55**: 21–27.
- 67 Jiang W, Middleton K, Yoon HJ, Fouquet C, Carbon J. An essential yeast protein, CBF5p, binds in vitro to centromeres and microtubules. *Mol Cell Biol* 1993; **13**: 4884–4893.
- 68 Knight SW, Heiss NS, Vulliamy TJ et al. X-linked dyskeratosis congenita is predominantly caused by missense mutations in the DKC1 gene. *Am J Hum Genet* 1999; **65**: 50–58.
- 69 Vulliamy TJ, Knight SW, Heiss NS et al. Dyskeratosis congenita caused by a 3' deletion: germline and somatic mosaicism in a female carrier. *Blood* 1999; **94**: 1254–1260.
- 70 Knight SW, Vulliamy TJ, Morgan B, Devriendt K, Mason PJ, Dokal I. Identification of novel DKC1 mutations in patients with dyskeratosis congenita: implications for pathophysiology and diagnosis. *Hum Genet* 2001; **108**: 299–303.
- 71 Heiss NS, Megarbane A, Klauk SM et al. One novel and two recurrent missense DKC1 mutations in patients with dyskeratosis congenita. *Genet Counsel* 2001; **12**: 129–136.
- 72 Hiramatsu H, Fujii T, Kitoh T et al. A novel missense mutation in the DKC1 gene in a Japanese family with X-linked dyskeratosis congenita. *Paediatr Hematol Oncol* 2002; **19**: 413–419.
- 73 Fuante J, Dokal I. Dyskeratosis congenita: advances in the understanding of the telomerase defect and the role of stem cell transplantation. *Pediatr Transplant* 2007; **11**: 584–594.

Copyright of International Journal of Dental Hygiene is the property of Blackwell Publishing Limited and its content may not be copied or emailed to multiple sites or posted to a listserv without the copyright holder's express written permission. However, users may print, download, or email articles for individual use.