



CASE REPORT

*N Kanda
Y Soga
M Meguro
A Tanabe
Y Yagi
Y Himuro
Y Fujiwara
S Takashiba
N Kobayashi*

Authors' affiliations:

*N Kanda, Y Soga, M Meguro, A Tanabe,
Y Yagi, Y Himuro, Y Fujiwara, N Kobayashi,*
Department of Dentistry, Mannari Hospital,
Okayama, Japan
N Kanda, Y Soga, M Meguro, S Takashiba,
Department of Pathophysiology –
Periodontal Science, Okayama University
Graduate School of Medicine, Dentistry and
Pharmaceutical Sciences, Okayama, Japan

Correspondence to:

Naoki Kobayashi, DDS, PhD
Head Dentist,
Department of Dentistry, Mannari Hospital,
1-6-5 Tani-Mannari,
Kita-ku,
Okayama 700-0071
Japan
Tel.: +81 86 252 2261
Fax: +81 86 254 0800
E-mail: oralcare@mannari.or.jp

Discovery of a patient with strongly suspected bullous pemphigoid in a ward by oral health care providers

Abstract: *Objectives:* Oral health care providers may discover systemic diseases incidentally from signs observed in the oral cavity. Here, we report a case in which oral health care providers in a hospital discovered a patient with strongly suspected bullous pemphigoid (BP), which is a relatively rare but important disease, in a ward. *Methods:* The patient was a 78-year-old Japanese woman admitted to our hospital because of severe Alzheimer's disease. We discovered recurrent ulcers in the oral mucosa and skin when performing oral care in her ward. Biopsy could not be performed safely because of involuntary biting. We performed blood tests for anti-BP180-NC16a antibody, which is autoantibody specific for BP. *Results:* The patient had a very high anti-BP180-NC16a antibody titre. We consulted a dermatologist regarding her clinical course and the clinical features of the oral mucosa and skin along with blood test results. BP was very strongly suspected. *Discussion:* In cases in which oral health care providers suspect their patients may have BP, appropriate examination and provision of information to the doctor are important. Oral health care providers should have knowledge about systemic diseases, the signs of which appear in oral cavity to avoid missing important systemic diseases.

Key words: bullous pemphigoid; discover; oral care

Dates:

Accepted 19 February 2010

To cite this article:

Int J Dent Hygiene 9, 2011; 159–162
DOI: 10.1111/j.1601-5037.2010.00448.x
Kanda N, Soga Y, Meguro M, Tanabe A, Yagi Y,
Himuro Y, Fujiwara Y, Takashiba S, Kobayashi N.
Discovery of a patient with strongly suspected
bullous pemphigoid in a ward by oral health care
providers.

© 2010 John Wiley & Sons A/S

Introduction

The relationships between general and oral health have attracted considerable attention. A number of studies in the field of 'periodontal medicine' have indicated that poor periodontal condition is related to poor general condition, e.g. diabetes mellitus, cardiovascular diseases, etc. There have been a number of consensus reports and commissioned reviews from authoritative societies in periodontology, in addition to reports in a broad range of fields related to oral care, regarding these relationships (1–3). Especially, it was reported that oral care reduced the incidence of pneumonia in older patients in nursing homes (4, 5).

Our hospital (Mannari Hospital) is a psychiatric and geriatric hospital with 560 beds, which has Departments of Psychiatry, Internal Medicine, Psychosomatic Medicine and Dentistry. The Department of Dentistry is

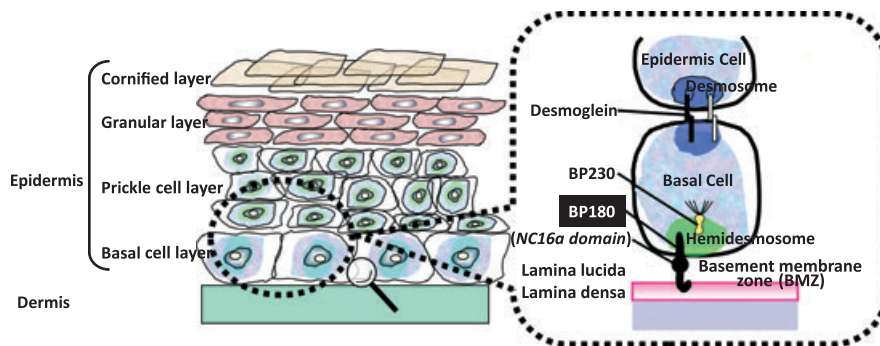


Fig. 1. Structure of the dermal-epidermal junction site.

composed of gerodontists, periodontists, and dental hygienists. We engage in not only general treatment of outpatients but also in the treatment and care of inpatients in the wards, especially those with severe senile dementia who cannot maintain oral hygiene by themselves not only to provide oral health but also to contribute to general health. Each ward has a dental hygienist in charge, and they make routine visits to their wards. When dental hygienists discover problems in the oral cavity and consider it necessary to refer the patient to a dentist, they call the dentist to the ward or take patients to the clinic.

As the signs of systemic diseases are sometimes manifested in the oral cavity, such diseases may be discovered incidentally by oral health care providers during examination of patients. Bullous pemphigoid (BP) is a subepidermal blistering disorder seen primarily in the elderly (6). The lesional/perilesional skin of BP patients exhibits detachment of the basal keratinocytes of the epidermis from the dermis at the level of the lamina lucida, resulting in tense, fluid-filled vesicles. Involved sites in this disease include the genital mucosa, anus and oral cavity (7).

Bullous pemphigoid is both an inflammatory disease and an autoimmune disease, characterized by inflammatory infiltrate at the site of the dermal-epidermal junction separation and by the deposition of autoantibodies and complement components along the basement membrane zone (BMZ) (7). The structure around BMZ is shown in Fig. 1. BP patients generate a repertoire of polyclonal autoantibodies that bind to the BMZ and activate complement, in addition to circulating autoantibodies. These autoantibodies target two major hemidesmosomal antigens of 230 kD (BP230 or BPAG1) and 180 kD (BP180, BPAG2 or type XVII collagen) (8). BP230, a component of the hemidesmosomal plaque, is an intracellular protein, while BP180 is a type II transmembrane protein (9). Similar to BP230, the amino-terminal portion of BP180 is localized to the intracellular hemidesmosomal plaque (9). Its carboxy-terminal region extends into the extracellular milieu of the BMZ, making it the preferred target for pathogenic BP autoantibodies (10).

Oral health care providers may discover systemic diseases incidentally based on signs observed in the oral cavity. Here, we report a case in which the oral health care providers in hospital discovered a patient with strongly suspected BP, which is a relatively rare but important disease, in a ward.

Case description and results

Patient

The patient was a 78-year-old Japanese woman who was admitted to our hospital due to severe Alzheimer's disease. Her activity of daily living (ADL) was very low, with a functional independence measure (FIM) of level 1 (total assistance). The patient's medical history from entering the hospital showed recurrent aspiration pneumonia.

Clinical course

The patient showed severe recurrent oral mucosal ulcers despite daily gentle brushing of the teeth by a dental hygienist, dentist and nurses for 1 week (Fig. 2). The ulcers were

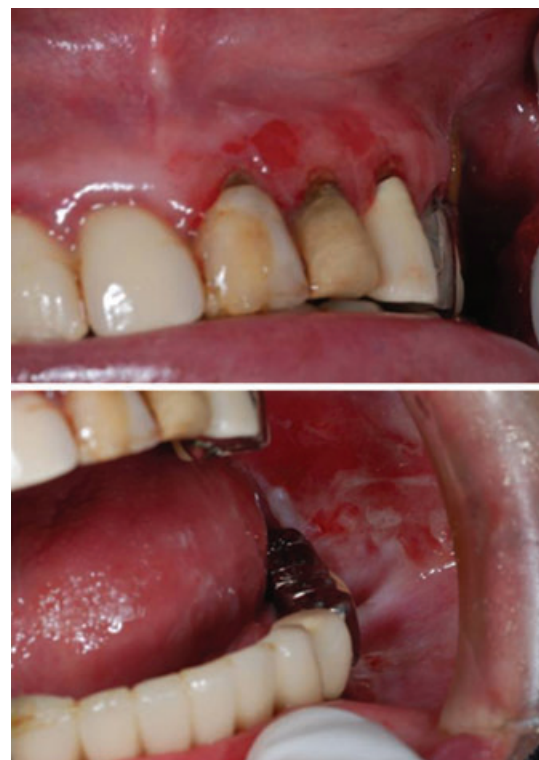

Fig. 2. Observed oral mucosal ulcer. Severe recurrent oral mucosal ulcers were observed despite intensive oral care.

Table 1. Microorganisms detected in the patient's oral mucosa with ulcerations

Detected microorganisms	Level
<i>α-Streptococcus</i> spp.	+++
<i>γ-Streptococcus</i> spp.	+
<i>Candida albicans</i>	+
<i>Candida glabrata</i>	+

subjected to bacterial examination. Culture and identification of microorganisms were performed by a clinical laboratory testing service. Microbial samples from mucosal swabs were plated onto brain heart infusion agar plates and cultured under aerobic conditions at 37°C. Identification of colonies thus obtained was performed using rapid ID 32 STREP API®, rapid ID 32 E API® or ID 32 GN API® identification kits (Japan bioMérieux, Tokyo, Japan) according to the manufacturer's instructions. The results are shown in Table 1. Candidiasis was suspected, but application of antifungal drugs to the oral mucosa yielded no changes in oral signs.

On the other hand, ulcers and scars were observed on the patient's skin (Fig. 3), which were recognized as dermatitis senilis by the physician in charge. The patient's oral ulcers were suspected to represent signs of a systemic disease. Some oral mucous membrane diseases are known to be associated with systemic disorders, such as Behçet's disease, lichen planus, lupus erythematosus, pemphigus, BP, etc. (10). The patient did not show remarkable xerostomia. The patient also showed extraoral ulcers. No facial erythema was observed. Thus, from the symptoms and medical history, we suspected that this patient was likely suffering from pemphigus or BP.

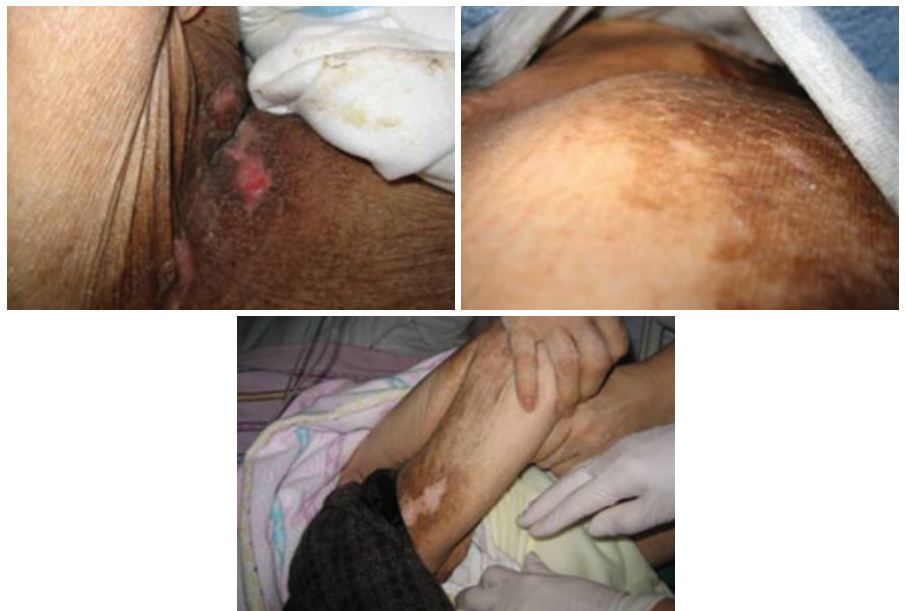Oral mucosa biopsy could not be performed safely because of involuntary biting. We performed a blood test for autoanti-

Table 2. Results of the blood test to determine antibody titre associated with pemphigus and BP by ELISA

Examination	Antibody titre		Decision from clinical laboratory
	This patient	Normal range	
For pemphigus			
Anti-desmoglein 1 Ab	7	<14	–
Anti-desmoglein 3 Ab	12	<7	±
For BP			
Anti-BP180 Ab	45	<9	+

BP, bullous pemphigoid; ELISA, enzyme-linked immunosorbent assay.

bodies specific in pemphigus or BP using the remaining serum from a routine blood test performed by her physician. Enzyme-linked immunosorbent assays (ELISA) were performed to determine anti-desmoglein 1, anti-desmoglein 3 and anti-BP180 antibody titres in blood (Table 2). Anti-BP180 antibody titre was remarkably elevated. As our hospital did not have a dermatologist (now our hospital has a dermatologist after the experience of this case), we consulted the dermatological authorities of the university hospital regarding the patient's clinical course and features focusing on the oral mucosa and the results of skin and blood tests. BP was very strongly suspected in this case, but unfortunately the patient again suffered aspiration pneumonia just after this consultation. Further examination for BP, for example skin biopsy, was post-poned because of her worsened general condition. Despite rigorous antibiotic treatment, the patient died because of pneumonia under intensive and palliative oral care for the symptoms strongly suspected BP by oral care providers consisted of dental hygienists, nurses in her ward and dentists.

**Fig. 3.** Ulcers and scars in the patients' skin.

Discussion

This patient could not be diagnosed accurately because biopsy could not be performed, but we strongly suspected BP. BP180-NC16a ELISA is useful for the detection of pathogenic anti-BP180 IgG autoantibodies at the initial disease stage of BP, as it not only has high sensitivity (89%) and specificity (98%), but is also easy to perform (11). This ELISA may provide valuable information for the accurate and reliable serodiagnosis of BP (11). A recent study also showed that ELISA detection of circulating antibodies against the NC16a portion of BP180 antigen had high sensitivity (93%) and specificity (96%) for BP (12).

Other possible diagnostic tests for BP include direct immunofluorescence, which is a technique that is used to detect the *in vivo* deposition of immunoreactants, such as BP180, in biopsy samples from affected sites (13). In this case, however, we could not communicate with the patient and involuntary movements were severe because of her Alzheimer's disease. As biopsy of the oral mucosa could not be performed safely, this ELISA blood test was the first choice for diagnosis and it was added to routine blood tests ordered by the physician in charge. Using the patient's serum, the indirect immunofluorescence (IIF) method, which investigates the presence of circulating antibodies in the patient's serum, can be performed (13). However, a recent study showed that BP180-NC16a ELISA is superior to IIF in sensitivity and specificity for BP (12).

In the case described here, BP was missed by the physician in charge. In cases where oral health care providers suspect that their patients may have BP, appropriate examination and provision of information to the physician in charge are important. We would like to emphasize that not only biopsy but also BP180-NC16a ELISA blood test may provide important information in this process.

Oral health care providers should have knowledge about systemic diseases, the signs of which appear in oral cavity to ensure that they do not miss important systemic diseases in their patients.

Acknowledgements

We thank Dr Yoshinori Sirafuji and Prof. Keiji Iwatsuki, Department of Dermatology, Okayama University Hospital of Medicine and Dentistry, Japan, for valuable suggestions regarding this case.

This case report was supported by The Nippon Koa Welfare Foundation (to MM).

We have no conflicts and interests in this report.

References

- 1 Kinane D, Bouchard P, Group E of European Workshop on Periodontology. Periodontal diseases and health: consensus Report of the Sixth European Workshop on Periodontology. *J Clin Periodontol* 2008; **35**: 333–337.
- 2 Friedewald VE, Kornman KS, Beck JD *et al.* The American Journal of Cardiology and Journal of Periodontology editors' consensus: periodontitis and atherosclerotic cardiovascular disease. *J Periodontol* 2009; **80**: 1021–1032.
- 3 Mealey BL, Oates TW, American Academy of Periodontology. Diabetes mellitus and periodontal diseases. *J Periodontol* 2006; **77**: 1289–1303.
- 4 Yoneyama T, Yoshida M, Matsui T, Sasaki H. Oral care and pneumonia. Oral Care Working Group. *Lancet* 1999; **354**: 515.
- 5 Yoneyama T, Yoshida M, Ohnishi T *et al.* Oral care reduces pneumonia in older patients in nursing homes. *J Am Geriatr Soc* 2002; **50**: 430–433.
- 6 Lever WF. Pemphigus. *Medicine* 1953; **32**: 1–123.
- 7 Stanley JR. Bullous pemphigoid. In: Freedberg IM, Eisen AZ, Wolff K, Austen KF, Goldsmith LA, Katz SI, eds. *Fitzpatrick's Dermatology in General Medicine*. New York, McGraw-Hill, 2007, pp. 666–671.
- 8 Verraes S, Hornebeck W, Polette M, Borradori L, Bernard P. Respective contribution of neutrophil elastase and matrix metalloproteinase 9 in the degradation of BP180 (type XVII collagen) in human bullous pemphigoid. *J Invest Dermatol* 2001; **117**: 1091–1096.
- 9 Ishiko A, Shimizu H, Kikuchi A, Ebihara T, Hashimoto T, Nishikawa T. Human autoantibodies against the 230-kD bullous pemphigoid antigen (BPAG1) bind only to the intracellular domain of the hemidesmosome, whereas those against the 180-kD bullous pemphigoid antigen (BPAG2) bind along the plasma membrane of the hemidesmosome in normal human and swine skin. *J Clin Invest* 1993; **91**: 1608–1615.
- 10 Altenburg A, Krah D, Zouboulis CC. Non-infectious ulcerating oral mucous membrane diseases. *J Dtsch Dermatol Ges* 2009; **7**: 242–257.
- 11 Sakuma-Oyama Y, Powell AM, Oyama N, Albert S, Bhogal BS, Black MM. Evaluation of a BP180-NC16a enzyme-linked immunosorbent assay in the initial diagnosis of bullous pemphigoid. *Br J Dermatol* 2004; **151**: 126–131.
- 12 Barnadas MA, Rubiales MV, González MJ *et al.* Enzyme-linked immunosorbent assay (ELISA) and indirect immunofluorescence testing in a bullous pemphigoid and pemphigoid gestationis. *Int J Dermatol* 2008; **47**: 1245–1249.
- 13 Dayan S, Simmons RK, Ahmed AR. Contemporary issues in the diagnosis of oral pemphigoid: a selective review of the literature. *Oral Surg Oral Med Oral Pathol Oral Radiol Endod* 1999; **88**: 424–430.

Copyright of International Journal of Dental Hygiene is the property of Wiley-Blackwell and its content may not be copied or emailed to multiple sites or posted to a listserv without the copyright holder's express written permission. However, users may print, download, or email articles for individual use.