



CASE REPORT

ML Salas
AC McClellan
SR MacNeill
KM Satheesh
CM Cobb

Author's affiliations:

ML Salas, AC McClellan, SR MacNeill,
KM Satheesh, CM Cobb, Department of
Periodontics, UMKC School of Dentistry,
Kansas City, MO, USA

Correspondence to:

Dr. M.L. Salas
Department of Periodontics
UMKC School of Dentistry
650 East 25th Street
Kansas City, MO 64108, USA
Tel.: +816 235 2147
Fax: +816 235 5472
E-mail: salasmartinez@umkc.edu

Interproximal cervical lesions caused by incorrect flossing technique

Abstract: This case report describes an interproximal cervical lesion caused by the incorrect use of dental floss. A 58-year-old man who was asymptomatic, presented with unusual notch-like cervical lesions. After clinical and radiographical examinations, it was concluded that the aetiology of these lesions was an incorrect flossing technique. The treatment plan included extraction of maxillary 3rd molars and re-education of the patient in oral hygiene technique. **Conclusion:** These lesions are irreversible and often go undiagnosed; therefore, it is important for the clinician to be familiar with the clinical presentation and aetiology.

Key words: dental devices; home care/adverse effects; oral hygiene; tooth abrasion/aetiology

Introduction

It is widely accepted that dental biofilms are intimately involved with the two most common dental diseases, i.e. dental caries and periodontal disease (1). Therefore, effective oral hygiene involving removal and control of dental biofilm formation plays a crucial role in prevention and successful treatment of dental diseases (1–3). However, numerous articles have suggested that improper oral hygiene procedures may result in abrasion and/or physical injury of both teeth and the gingivae. These lesions often occur in highly motivated patients who misunderstand or misapply proper flossing and brushing techniques (4). Although the association between improper use of the manual toothbrush and gingival recession and/or cervical abrasion of teeth has been extensively discussed, other disorders that are usually asymptomatic may go undiagnosed (4). For example, consider floss-induced injury: although interdental tissues are vulnerable to injury, floss can be extended an average of 2 mm apical to the tip of the gingival papilla without inflicting damage to the gingiva or periodontal ligament (5). Nevertheless, long-term vigorous flossing can lead to tooth abrasion with the posterior lingual areas being most commonly affected. Interestingly, Sangnes and Gjermo (6) have reported a few cases of interdental floss-induced trauma, although most investigators suggest that floss-induced injury is common, but rarely diagnosed (4).

It should be noted that the benefits associated with flossing outweigh the risk of damage. Although toothbrushing is an effective method for mechanical plaque removal (3, 7, 8), when used as a monotherapy for control of dental biofilm, it is not totally effective in preventing diseases of the teeth and their supporting tissues (9, 10). Control of interproximal biofilm formation requires use of an interdental oral hygiene aid, one such aid being dental floss.

Accurate clinical diagnosis, on occasion, requires recognition of signs and symptoms of lesions resulting from habitual performance of bizarre

Dates:

Accepted 13 July 2011

To cite this article

Int J Dent Hygiene 10, 2012; 83–85
DOI: 10.1111/j.1601-5037.2011.00524.x
Salas ML, McClellan AC, MacNeill SR,
Satheesh KM, Cobb CM. Interproximal cervical
lesions caused by incorrect flossing technique.

© 2011 John Wiley & Sons A/S

oral hygiene procedures. This article describes a case in which abrasion of the proximal tooth surfaces was related to a long-standing unusually vigorous and incorrect use of dental floss.

Case description

A 58-year-old Caucasian male was referred by his general dentist to the University of Missouri–Kansas City, Graduate Periodontal Clinic for periodontal evaluation. The general dentist noted periodontal problems as well as unusual linear notch-like cervical lesions on the distal of the maxillary and mandibular molars. The patient's medical history was insignificant and non-contributory. The patient's dental history included orthodontic treatment as a teenager, for which all first premolars were extracted. Despite the orthodontic treatment, crowding of the mandibular incisors was evident. Interestingly, there was a positive history of a diagnosis of chronic periodontitis for which the patient had received no definitive treatment. Radiographic examination revealed a generalized moderately severe horizontal bone loss with localized areas of angular bone loss. The clinical examination noted poor oral hygiene, heavy staining, and light supra and subgingival calculus. Periodontal probing depths ranged from 3 to 9 mm for the maxillary and mandibular posterior teeth and 3–6 mm for the anterior sextants. Bleeding on probing for all sites was 45%. Tooth mobility was localized to the mandibular incisor teeth, which exhibited Grade I and II mobility. Grade I or II furcation involvement was recorded for all molars. Lastly, there was a generalized gingival recession ranging from 1 to 2 mm.

Both radiographical and clinical examination revealed linear 'notch-like' abrasion lesions involving the distal cementoenamel junction (CEJ) that extended onto the distal-lingual and distal-facial surfaces of teeth nos 1, 2, 3, 15, 18 and 31 (Figs 1–3). The lesions were approximately 2 mm deep and not consistent with a pattern generally associated

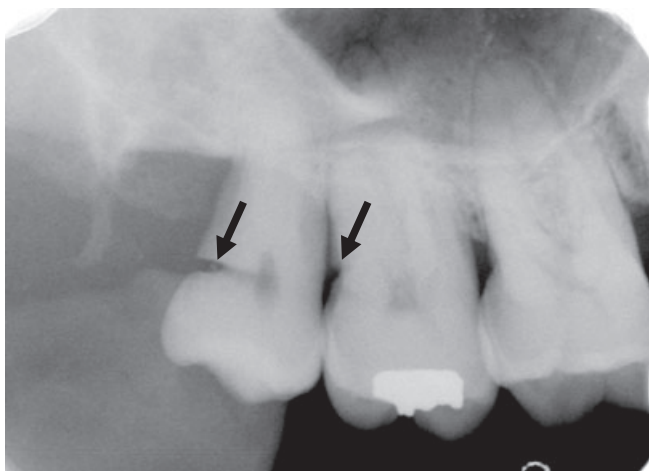


Fig. 1. Radiograph of maxillary left molars. Note deep notch-like lesion at the distal cementoenamel junction of tooth no. 1 and a similar but more shallow lesion on the distal root surface of no. 2 (arrows).

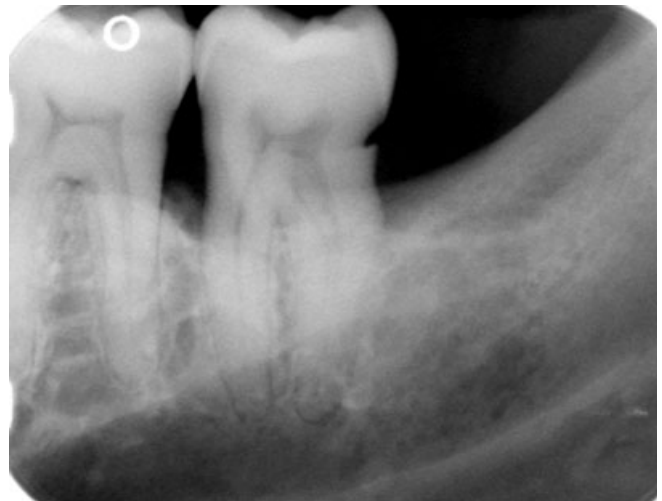

Fig. 2. Radiograph of mandibular left 2nd molar (no. 18) showing 'V'-shaped notch-like defect on distal surface.

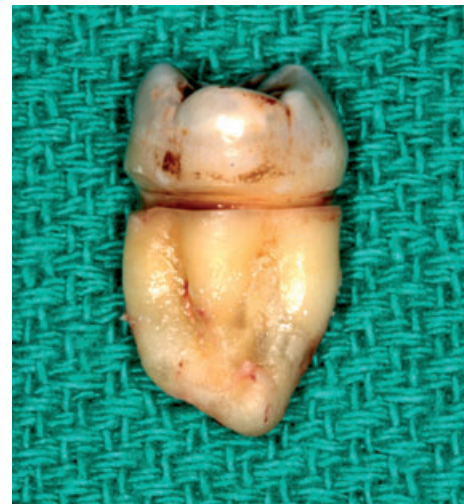

Fig. 3. Extracted tooth no. 1 showing the extensive linear notch-like defect resulting from 'sawing' with dental floss.

with aggressive horizontal toothbrushing. When asked to demonstrate his flossing technique, the patient passed the floss between his molars, slipped it into the distal abrasion defect (Fig. 4) and held the extended threads parallel to one another. Once in place, he flossed using a sawing action. The patient stated that he had used this technique daily for many years.

The initial periodontal treatment included extensive patient re-education in the use of dental floss and a mechanical toothbrush, followed by four quadrants of scaling and root planing (SRP) and re-evaluation at 5 weeks post-scaling. Following the initial therapy, it was decided to reflect a full thickness mucoperiosteal flap involving the posterior sextants of teeth for access to perform further SRP and osteoplasty and to extract teeth no. 1 and no. 16. Subsequent to the extraction of the 3rd molar teeth, the exposed distal root surfaces of the second

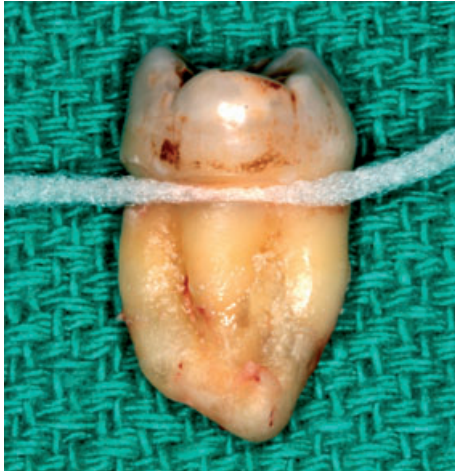

Fig. 4. Extracted tooth no. 16 with floss inserted into the linear notch-like defect demonstrating a tight fit that facilitated the sawing action.

molars were inspected to insure that caries had not involved the linear notch-like defect.

Discussion

This article describes a case in which abrasion of the proximal tooth surfaces was related to a long-standing aggressive and incorrect use of dental floss. There are numerous studies on relating mechanical tooth cleansing procedures to various soft and hard tissue lesions most being concerned with gingival recession and tooth abrasion as a consequence of faulty toothbrushing. Sangnes and Gjermo (6) after examined 533 individuals and reported that 51% of the subjects exhibited gingival recession and 45% had cervical abrasion related to toothbrushing habits. Results on floss-related lesions were not reported. Indeed, published reports concerning floss-induced injury are rare. Gillette and Van House (4) noted in their report that the effects (i.e. shape and extent of the deformity) of using dental floss with a sawing action was dictated by the patient's specific flossing technique. They also reported that floss-induced defects generally exhibited a 'glassy smooth' surface.

Everett and Kunkel (11) reported proximal and lingual flossing abrasion lesions involving the mandibular incisors. Approximately 35 years later, Rawlison (12) described a similar lesion located on the buccal surface of the maxillary central incisors. In both cases, the floss was wrapped between adjacent teeth, crossed over the adjacent teeth and then used in a sawing action. In the current case report, the floss was used with a similar movement, but both threads were parallel to each other and not crossed. This explains the distal location of the lesion, leaving the buccal surface uncompromised. Walters and Chang (13) reported a case where chronic trauma from improper flossing resulted in interproximal bone loss, indicating a type of factitious injury. Not surprisingly, however, the pain associated with the faulty flossing technique discouraged the patient from

inducing more damage to the periodontium. In contrast, the patient in the current case did not feel any discomfort, so he continued practicing his aggressive flossing technique, every day for many years, until his general dentist detected the lesion.

Even though overly aggressive toothbrushing is the most common cause for tooth cervical abrasion lesions, the patient's flossing technique should not be overlooked when trying to determine the aetiology of unusual CEJ lesions – particularly those with an interproximal location.

Conclusion

Analysis of the literature reveals that lesions like the one described in the current case report, often go undiagnosed. In view of the fact that these lesions are irreversible, it is important for the practitioner to detect the clinical signs of such lesions during periodic examinations. Obviously, in cases of overly aggressive flossing and/or toothbrushing, implementation of a patient educational programme in the proper use of dental hygiene aids is crucial.

References

- 1 Loe H, Theilade E, Jensen SB. Experimental gingivitis in man. *J Periodontol* 1965; **36**: 177–187.
- 2 Ash M, Gitlin B, Smith W. Correlation between plaque and gingivitis. *J Periodontol* 1964; **35**: 424.
- 3 Lindhe J, Axelsson P. The effect of controlled oral hygiene and topical fluoride application on caries and gingivitis in Swedish schoolchildren. *Community Dent Oral Epidemiol* 1973; **1**: 9–16.
- 4 Gillette WB, Van House RL. Ill effects of improper oral hygiene procedure. *J Am Dent Assoc* 1980; **101**: 476–480.
- 5 Waerhaug J. Healing of the dento-epithelial junction following the use of dental floss. *J Clin Periodontol* 1981; **8**: 144–150.
- 6 Sangnes G, Gjermo P. Prevalence of oral soft and hard tissue lesions related to mechanical toothcleansing procedures. *Community Dent Oral Epidemiol* 1976; **4**: 77–83.
- 7 Hansen F, Gjermo P. The plaque removing effect of four toothbrushing methods. *Scand J Dent Res* 1971; **79**: 502.
- 8 Lang NP, Cumming BR, Loe H. Toothbrushing frequency as it relates to plaque development and gingival health. *J Periodontol* 1973; **44**: 396–405.
- 9 Bergenholtz A, Brithon J. Plaque removal by dental floss or toothpicks. An intra-individual comparative study. *J Clin Periodontol* 1980; **7**: 516–524.
- 10 Carter-Hanson C, Gadbury-Amyot C, Killoy W. Comparison of the plaque removal efficacy of a new flossing aid (Quik Floss) to finger flossing. *J Clin Periodontol* 1996; **23**: 873–878.
- 11 Everett FG, Kunkel PW. Abrasion through the abuse of dental floss. *J Periodontol* 1953; **24**: 186–187.
- 12 Rawlison A. Case report. Labial cervical abrasion caused by misuse of dental floss. *Dent Health (London)* 1987; **26**: 3–4.
- 13 Walters JD, Chang EI. Periodontal bone loss associated with an improper flossing technique: a case report. *Int J Dent Hyg* 2003; **1**: 115–119.

Copyright of International Journal of Dental Hygiene is the property of Wiley-Blackwell and its content may not be copied or emailed to multiple sites or posted to a listserv without the copyright holder's express written permission. However, users may print, download, or email articles for individual use.