International Journal of Paediatric Dentistry 2006; **16:** 143–146

Sotos syndrome with hypodontia

A. P. CALLANAN, P. ANAND & E. C. SHEEHY
Department of Paediatric Dentistry, Guy's Hospital, King's College London School of Dentistry, London, UK

Summary. Sotos syndrome, or cerebral gigantism, is a rare genetic condition characterized by tall stature, gigantism, dolichocephaly, advanced bone age and learning disability. The purpose of this case report is to highlight the dental management of a 10-year-old boy with Sotos syndrome who presented with hypodontia and dental caries.

Introduction

Sotos syndrome was first reported by Sotos *et al*. in 1964 [1]. The main clinical features of the syndrome are tall stature, gigantism, a prominent forehead (dolichocephaly), advanced bone age and learning disability [2]. The mode of inheritance of Sotos syndrome is thought to be sporadic [3], but autosomal dominant and recessive forms have been documented [4,5]. Recently, haploinsufficiency of the nuclear receptor-binding SET domain-containing protein (NSD1) gene has been identified as a major cause of Sotos syndrome, with iatrogenic mutations or submicroscopic microdeletions being found in about 60–70% of clinically diagnosed cases of Sotos syndrome [6,7]. It arises in all ethnic groups and has been detected throughout the world. The prevalence is estimated to be between one in 10 000 and one in 50 000 [8].

Sotos syndrome is characterized by excessive growth pre- and postnatally. Birth length and weight are usually above the ninety-seventh percentile, and between the seventy-fifth and ninety-seventh percentiles, respectively. Growth during the first few years of life exceeds normal limits, after which it continues at relatively normal rates, but is consistently found in the high percentiles [8].

The most obvious craniofacial feature is increased head circumference, which generally proceeds above the ninety-seventh percentile throughout growth [9]. Other distinctive craniofacial anomalies include dolichocephaly, a flat nasal bridge, a high arch palate and premature eruption of the primary teeth. Narrow temples make the eyes appear wide-set, but true ocular hypertelorism is not found. The mandible is long and narrow inferiorly, square or pointed, but true prognathism is rare [10].

Approximately 8% of patients with Sotos syndrome have a congenital cardiac anomaly which is of particular relevance to the dental management of these patients. Seizures, abnormal glucose tests and an increased risk of neoplasm (e.g. Wilms tumour, hepatocellular carcinoma, mixed parotid tumour and giant cell granuloma of the mandible) have also been reported in patients with the syndrome [2,10].

This report describes the dental management of a patient with Sotos syndrome who presented with hypodontia and dental caries.

Case report

A 10-year-old Caucasian boy was referred to the Department of Paediatric Dentistry, Guy's Hospital, London, UK, for oral rehabilitation. A detailed medical history revealed that the patient had Sotos syndrome, asthma, learning disability and behavioural problems. He had also had an atrioventricular septal defect that was repaired at 2 years of age. The patient attended the dentist infrequently. The family history was unremarkable.

Clinical examination revealed that the patient was above the ninety-seventh percentile for height and weight. He exhibited the characteristic craniofacial features consistent with Sotos syndrome including macrocrania, frontal bossing, a thin, receding hairline, down-slanting palpebral fissures, epicanthic folds, large ears, a flat nasal bridge, and a pointed chin (Fig. 1). Intraoral examination revealed that the patient

Correspondence: Dr E. C. Sheehy, Department of Paediatric Dentistry, Floor 22, Guy's Hospital Tower, St Thomas' Street, London SE1 9RT, UK. E-mail: evelyn.sheehy@kcl.ac.uk

Fig. 1. Photograph of the patient’s face showing macrocrania, frontal bossing, a thin, receding hairline, down-slanting palpebral fissures, epicanthic folds, large ears, a flat nasal bridge, and a pointed chin.

Fig. 2. Photograph of the teeth in occlusion showing generalized chronic marginal and papillary gingivitis and the presence of a Class I malocclusion with severe lower labial segment crowding.

Fig. 3. Photograph of the maxillary dentition showing gross caries and tooth surface loss in the primary and permanent molar teeth.

was in the mixed dentition. There was generalized chronic marginal and papillary gingivitis consistent with poor oral hygiene (Fig. 2). Dental caries and tooth surface loss were present in all the first permanent molars. The primary molars showed extensive tooth surface loss and dental caries involving the dentine and the pulp (Figs 3 and 4). The patient had a Class 1 malocclusion with severe mandibular labial segment crowding and a high palatal vault. Radiographic examination, comprising a dental panoramic tomogram (Fig. 5) and a maxillary standard occlusal view (Fig. 6), confirmed the extent of the dental caries and tooth surface loss, advanced root resorption in the primary molars, and absence of the following teeth:

(18; 15; 14; 12; 22; 24; 25; 28; 38; 37, 35; 34; 44; 45; 48).

8 5 4 2	2 4 5 8
8 5 4	4 5 7 8

Fig. 4. Photograph of the mandibular dentition showing severe labial segment crowding, and gross caries and tooth surface loss in the primary and permanent molar teeth.

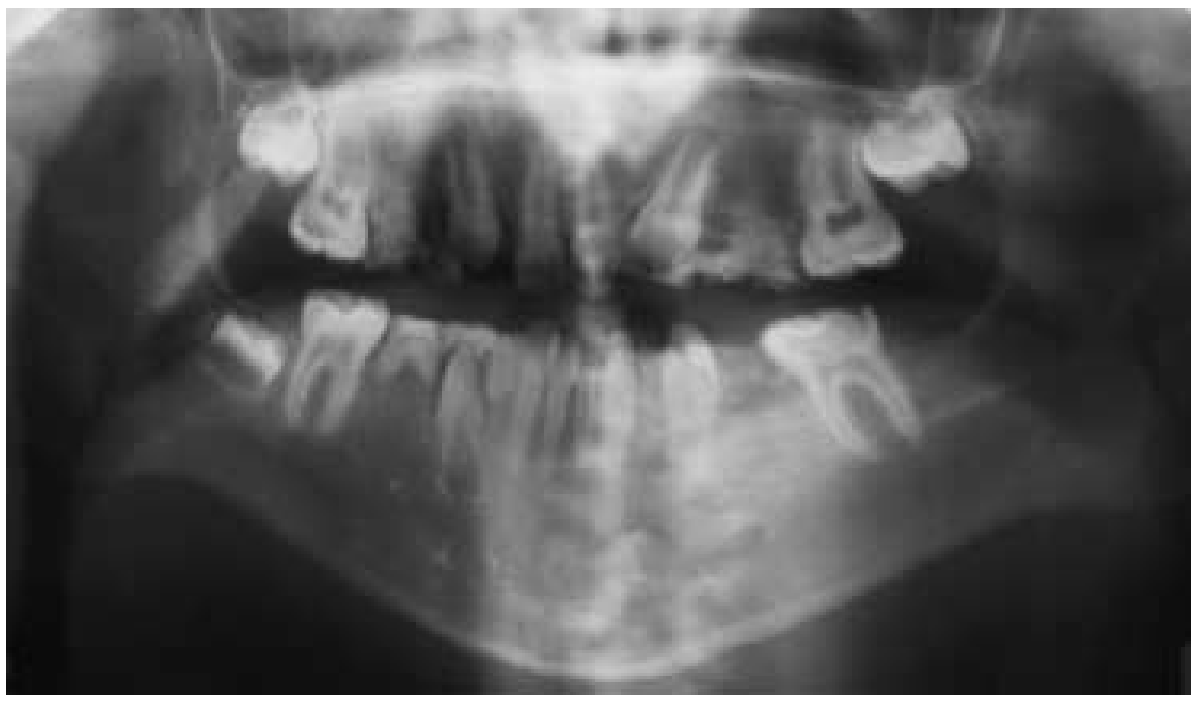

Fig. 5. Dental panoramic tomogram confirming the absence of maxillary permanent lateral incisors, all premolars, the mandibular left second molar and the third molars.

Fig. 6. Maxillary anterior occlusal radiograph confirming the absence of permanent lateral incisors.

A preventive programme was implemented for the patient, consisting of oral hygiene instruction, and dietary and fluoride advice. Particular emphasis was placed on reducing the consumption of carbonated beverages and fruit juices, which had contributed to the presence of dental caries and erosion, especially in the primary teeth.

Because of the uncooperative behaviour of the patient, the presence of a congenital cardiac anomaly and the extent of the treatment required, it was decided to carry out oral rehabilitation under general anaesthesia and antibiotic cover. The grossly carious mandibular left first permanent molar and the extensively worn carious primary teeth were extracted because the patient was at risk of infective endocarditis and pulp therapy was contraindicated.

Following orthodontic consultation preoperatively, it was also decided to extract the mandibular right permanent central incisor, which was labially excluded from the arch, as it was felt that the patient would not be amenable to orthodontic treatment. All the remaining first permanent molars were restored.

The patient's recovery was uneventful and a follow-up examination revealed no problems. A 3-monthly recall programme was organized for the patient to review his oral health and development, and to positively reinforce prevention. The patient had an upper partial denture fitted to replace his missing permanent lateral incisors and premolars. The fitting of a lower partial denture will also be considered in the future, depending on the patient's cooperation.

Discussion

The congenital absence of all premolars, all third molars, maxillary permanent lateral incisors and the mandibular left second permanent molar would seem to be the first report of hypodontia in a patient with Sotos syndrome. There was no family history of either Sotos syndrome or hypodontia. The authors are aware of only one other case report in the dental literature that has described the absence of mandibular premolars in a patient with Sotos syndrome [11]. However, the above report was inconclusive since radiographic evidence of hypodontia was incomplete. Secondly, the patient was only 2·5 years of age; therefore, one could not rule out late development of premolars, especially mandibular second premolars, which may not be visible radiographically until as late as 8 years of age.

Hypodontia in Sotos syndrome may be linked to haploinsufficiency of the NSD1 gene. Generation of NSD1-deficient mice has shown that this gene is essential for early postimplantation development. Furthermore, enriched levels of NSD1 have been observed during mouse development in tooth buds, the brain, the spinal cord, intestinal crypt cells, the thymus, salivary glands, and in regions of ossification of the developing bones and the periosteum [12].

In this case, a radical approach to treatment was unavoidable because the patient was at risk of infective endocarditis, had severe behavioural problems, learning disability and poor compliance. This case highlights the importance of early referral of patients with complex medical histories to tertiary paediatric dental centres. A preventive programme must be implemented early for all patients, especially those with complex medical histories, in order to avoid premature loss of teeth, and unnecessary pain and sepsis, which may compromise both their general and dental health. While the replacement of congenitally missing permanent teeth with implants in the long term would be ideal, this will depend on the patient's cooperation and compliance with preventive dental advice.

In conclusion, paediatric dentists should be aware of the possibility of hypodontia in patients with Sotos syndrome. Early prevention and a multidisciplinary approach to the care of these patients are essential.

What this case report adds

- Sotos syndrome or cerebral gigantism is a rare genetic condition characterised by tall stature, gigantism, dolichocephaly and advanced bone age.
- Mental disability in patients with Sotos syndrome may complicate the dental management.

Why this paper is important for paediatric dentists

- The presence of a congenital cardiac anomaly and the need for antibiotic prophylaxis for the prevention of infective endocarditis should be considered by the paediatric dentist.
- This case also highlights the presence of hypodontia in Sotos syndrome.
- Early prevention and a multidisciplinary team approach to care of patients with Sotos syndrome are essential.

Acknowledgements

Thanks to Dr Martyn Cobourne, Senior Lecturer/Honorary Consultant in Orthodontics, who helped with this case.

References

1 Sotos JF, Dodge PR, Muirheard D, Crawford JD, Talbot NB. Cerebral gigantism in childhood: a syndrome of excessively rapid growth with acromegalic features and a non-progressive neurological disorder. *New England Journal of Medicine* 1964; **271**: 109–116.
2 Melo DG, Pina-Neto JM, Acosta AX, Castro JDV, Santos AC. Neuroimaging and echocardiographic findings in Sotos syndrome. *American Journal of Medical Genetics* 1999; **90**: 423–433.
3 Hook EB, Reynolds JW. Cerebral gigantism: endocrinological and clinical observation of six patients including a congenital giant, concordant monozygotic twins and a child who achieved adult gigantic size. *Journal of Pediatrics* 1967; **70**: 900–914.
4 Mangono L, Palmeris S, Dotti MT, Moschini F, Faderico A. Macrosomia and mental retardation: evidence of autosomal dominant inheritance in four generations. *American Journal of Medical Genetics* 1989; **32**: 67–71.
5 Nevo S, Zeltzer M, Benderly A, Levy J. Evidence for autosomal recessive inheritance in cerebral gigantism. *Journal of Medical Genetics* 1974; **11**: 158–165.
6 Nookawa N. Molecular basis of Sotos syndrome. *Hormone Research* 2004; **62**: 60–65.
7 Visser R, Matsumoto N. Genetics of Sotos syndrome. *Current Opinions in Pediatrics* 2003; **15**: 598–606.
8 Sotos JF. Overgrowth. *Clinical Pediatrics* 1997; **36**: 89–103.
9 Cole TRP, Hughes HE. Sotos syndrome: a study of the diagnostic criteria and the natural history. *Journal of Medical Genetics* 1994; **31**: 20–32.
10 Gorlin RJ, Cohen MM, Hennekam RCM. *Syndromes of the Head and Neck*, 4th edn. Oxford: Oxford University Press, 2001: 399–427.
11 Inokuchi M, Nomura J, Matsumura Y, Sekida M, Tagawa T. Sotos syndrome with enamel hypoplasia: a case report. *Journal of Clinical Pediatric Dentistry* 2001; **25**: 313–316.
12 Rayasam GV, Wendling O, Angrand P-O, *et al*. NSD1 is essential for early post-transplantation development and has a catalytically active SET domain. *EMBO Journal* 2003; **22**: 3153–3163.