

Oral mucous membrane pemphigoid in a 6-year-old boy: diagnosis, treatment and 4 years follow-up

MOSTAFA I. MOSTAFA¹, NEHAL F. HASSIB¹ & AMANY H. NEMAT²

¹Human Genetics and Genome Research Division, Department of Oro-dental Genetics, and ²Medical Division, Oro-dental Research Department, National Research Center, Cairo, Egypt

International Journal of Paediatric Dentistry 2010; 20: 76–79

Background. Childhood oral pemphigoid is extremely rare and usually takes the form of desquamative gingivitis.

Case report. We describe a 6-year-old boy who presented with gingival bleeding, pain, eating difficulty, and peeling of the gums. Clinical examination revealed desquamative gingivitis with no extra-oral involvement. The diagnosis was established as oral pemphigoid based on

the clinical, histological, and immunofluorescence findings. Symptoms resolved on treatment with occlusive topical corticosteroids. The patient was a carrier of the HLA-DQB1*0301 allele.

Conclusion. Mucous membrane pemphigoid should be considered in the differential diagnosis of chronic desquamative gingivitis in childhood. Occlusive therapy with topical fluocinonide may alleviate the symptoms.

Introduction

Mucous membrane pemphigoid (MMP) is a chronic immune-mediated subepithelial vesiculobullous disease of adults. Children are rarely affected. The term oral pemphigoid (OP) is used when lesions are confined to the mouth. Oral lesions usually take the form of desquamative gingivitis^{1–3}. There is an association between MMP and HLA-DQB1*0301^{4,5}.

Case report

A 6-year-old boy with gingival bleeding, pain, eating difficulty, and peeling of the gums was referred to the Oro-Dental Genetics Department, National Research Center in Cairo. His parents had first noted redness of the gums at the age of 3 with the symptoms that led to the referral developing at the age of 5. Seven months prior to referral to our department, a diagnosis of chronic periodontitis was made but he did not respond to the treatment.

Correspondence to:

M. I. Mostafa, Human Genetics and Genome Research Division, Department of Oro-dental Genetics, National Research Center, 33, Dokki St, Cairo, Egypt.
E-mail: mostafanrc@yahoo.com

Clinical examination revealed generalized redness of the gingiva in both upper and lower jaws (Fig. 1a,b). Application of gentle lateral pressure on the gingiva using a piece of cotton caused peeling of the gums, indicating a positive Nikolsky's sign. Desquamative gingivitis was suspected. Histological findings showed separation of the epithelium from the underlying connective tissue (Fig. 1c). Direct immunofluorescence showed linear deposition of IgG and C3 at the mucosal-submucosal junction (Fig. 1d). No extra-oral abnormalities were detected. The diagnosis was established as OP based on the clinical, histological, and immunofluorescence findings. The patient had the genotype HLA-DQB1*0501/0301, 0309, 0313.

Occlusive topical steroid therapy (5 mg betamethasone cream b.d.) was commenced. Upper and lower vacuum-formed trays with spacers at the gingival portion were constructed to retain the cream. An artificial space was designed in the trays to allow the eruption of the permanent incisors (Fig. 1e). A 0.2% chlorhexidine mouth wash was prescribed twice daily 1 week of the 4 weeks to avoid candidosis and calculus formation, which may aggravate the condition. The

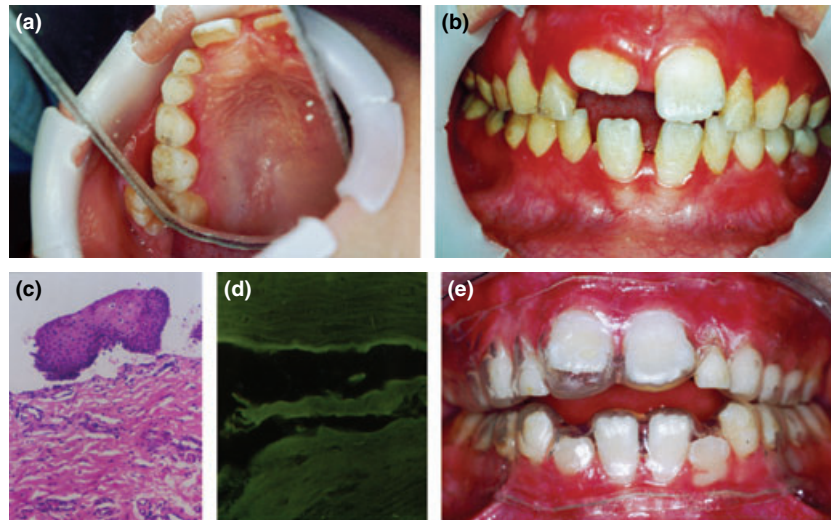


Fig. 1. (a) Desquamation of palatal gingival margin related to left primary first molar and right permanent central incisor. (b) Gingival redness with desquamated bloody areas in both upper and lower jaws. (c) Histological (H&E) findings show separation of the epithelium from the underlying connective tissue with lymphocytic infiltrate (original magnification $\times 40$). (d) Direct immunofluorescence shows linear deposition of IgG at the mucosal-submucosal junction. (e) Vacuum-formed trays with artificial space.

parents were instructed to avoid giving the child highly acidic foods and hard foods. Scaling and oral hygiene measures were performed. After 2 weeks a small improvement was noted. The treatment was modified, continuing betamethasone for the lower jaw but changing to 0.05% fluocinonide ointment for the upper one jaw. Five weeks later, the patient complained of bleeding, pain, and

peeling of the gums of the lower jaw only and clinical examination confirmed that there was a greater improvement in the upper gingival mucosa (Fig. 2a). Fluocinonide was continued for upper and lower jaws for another 5 weeks. After that period (12 weeks), the signs and symptoms had resolved except for the redness of the gingiva (Fig. 2b). The patient was reviewed monthly and signs and

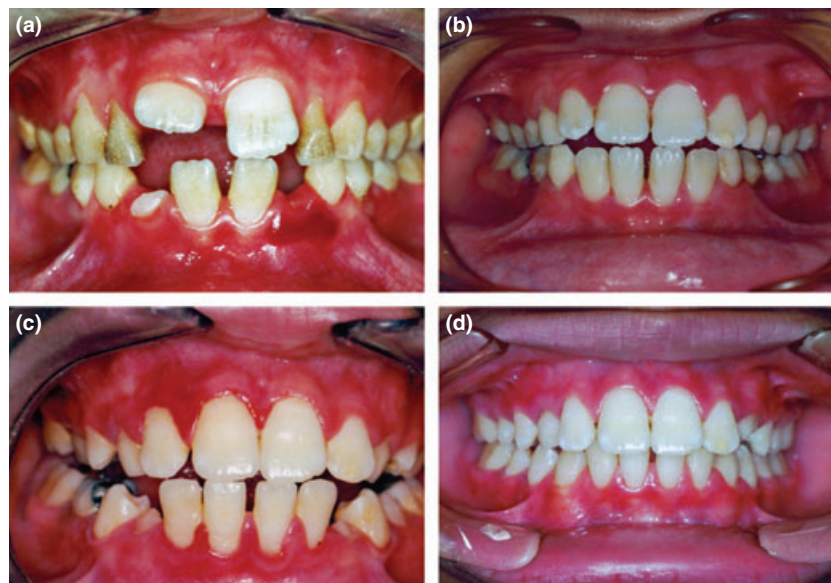

Fig. 2. (a) Seven weeks after starting treatment: the upper gingival mucosa has improved, and bleeding and desquamation present in the lower gingival mucosa. (b) Twelve weeks after starting treatment: signs have disappeared except for the gingival redness. (c) Recurrence of signs about 30 months from starting treatment. (d) Appearance at most recent follow-up, off treatment: gingival mucosa appears normal.

symptoms recurred after 6 months. Again they responded to 2 weeks topical treatment with fluocinonide. During the 4 years of follow-up (Fig. 2c,d), signs and symptoms recurred at approximately six monthly intervals, although there was a remission for 1 year gap before the last recurrence. Patient was also reviewed every 6 months for extra-oral examination particularly ophthalmological.

Comment

Mucous membrane pemphigoid rarely affects children. Only seven previous cases of childhood OP (oral lesions only) have been reported in the international English literature^{2,3,6-10}. This case is thought to be the eighth.

Desquamative gingivitis is a non-specific clinical manifestation of several diseases, the most common being MMP, lichen planus, and pemphigus vulgaris successively. DIF shows intercellular epithelial antibodies in pemphigus vulgaris whereas lichen planus shows fibrin staining of the basement membrane¹¹.

Several studies indicated that HLA-DQB1*0301 alleles confer a predisposition to all subgroups of MMP in Caucasian patients. It may have a role in T cell recognition of basement membrane antigens and the subsequent B cell production of anti-basement membrane zone autoantibodies. It has been suggested that OP and ocular pemphigoid are part of a spectrum of a single disorder and that they have the same genetic predisposition^{4,5}, thus it is interesting to note that the patient we describe has this allele.

Use of vacuum-formed trays in children has not previously been reported. We designed an artificial space in the tray to allow eruption of the permanent incisors. We found that opening windows around the erupting teeth rendered the tray non-retentive.

There is no absolute effective agent for the treatment of OP but corticosteroids are the drugs of choice. Topical corticosteroids are the treatment of choice for MMP, especially for localized oral lesions, although immunosuppressants and dapsone have also been used. In this case, we found fluocinonide to be more effective than betametha-

sone. Yet, similar reported cases are very few and the true benefits of such drugs are therefore not yet clear^{3,12,13}.

Intervals between relapses may lengthen as the child becomes older and more attentive to oral hygiene and aware of the stimulating factors. At the same time, shedding and eruption mechanisms could be among the predisposing factors.

In conclusion, MMP should be considered in the differential diagnosis of chronic desquamative gingivitis in childhood. Occlusive therapy with topical fluocinonide until symptoms resolve is recommended, with repeated courses if symptoms recur. This approach has fewer side effects than systemic corticosteroids or dapsone, particularly in childhood. We also recommend periodic ophthalmologic examination in affected patients.

What this paper adds

- Recording a very rare case of childhood OP.
- Using occlusive topical steroid therapy in the treatment of childhood OP.

Why this paper is important to paediatric dentists

- Oral pemphigoid that is common in old age can also affect children and must be considered in the differential diagnosis of chronic desquamative gingivitis in childhood.
- Adding a new clinical experience for OP cases, as these cases are extremely rare.

Acknowledgements and conflict of interest

This work was carried out under the annual research fund for the National Research Center. The authors thank Dr Maha R. Abou-zeid and Dr Mennat I. Mehrez, the National Research Center, Cairo, Egypt, for their help in manuscript preparation and Professor Dr Judith Goodship, Professor of Medical Genetics, Newcastle University, England, for scientific editing of the manuscript. All authors have declared no conflict of interest.

References

- 1 Scully C, Carrazzo M, Gandolfo S, Puiatti P, Monteil R. Update on mucous membrane pemphigoid. A heterogeneous immune-mediated subepithelial

- blistering entity. *Oral Surg Oral Pathol Oral Med Oral Radiol Endod* 1999; **88**: 56–68.
- 2 Musa NJ, Kumar V, Humphreys L, Aguirre A, Neiders ME. Oral pemphigoid masquerading as necrotizing ulcerative gingivitis in a child. *J Periodontol* 2002; **73**: 657–663.
 - 3 Laskaris G, Triantafyllou A, Economopoulou P. Gingival manifestations of childhood cicatricial pemphigoid. *Oral Surg* 1988; **66**: 349–352.
 - 4 Yunis JJ, Mobini N, Yunis EJ *et al*. Common major histocompatibility complex class II markers in clinical variants of cicatricial pemphigoid. *Proc Natl Acad Sci U S A* 1994; **91**: 7747–7751.
 - 5 Carrozzo M, Fasano ME, Broccoletti R *et al*. HLA-DQB₁ alleles in Italian patients with mucous membrane pemphigoid predominantly affecting the oral cavity. *Br J Dermatol* 2001; **145**: 805–808.
 - 6 Worsaae N, Dabelsteen E. Benign mucous membrane pemphigoid in an 18-year-old woman. *Arch Dermatol* 1978; **114**: 1093–1094.
 - 7 Sklavounou A, Laskaris G. Childhood cicatricial pemphigoid with exclusive gingival involvement. *J Oral Maxillofac Surg* 1990; **19**: 179–199.
 - 8 Roche C, Field EA. Benign mucous membrane pemphigoid presenting as desquamative gingivitis in a 18-year-old child. *Int J Paediatr Dent* 1997; **7**: 31–34.
 - 9 Cheng YS, Rees TD, Wright JM, Plemons JM. Childhood oral pemphigoid: a case report and review of the literature. *J Oral Pathol Med* 2001; **30**: 372–377.
 - 10 Lourenco SV, Boggio P, Agner Machado Martins LE, Santi CG, Aoki V, Menta Simonsen Nico M. Childhood oral mucous membrane pemphigoid presenting as desquamative gingivitis in a 4-year-old girl. *Acta Derm Venereol* 2006; **86**: 351–354.
 - 11 Sklavounou A, Laskaris G. Frequency of desquamative gingivitis in skin diseases. *Oral Surg* 1983; **56**: 141–144.
 - 12 Lozada F, Silverman S. Topically applied fluocinonide in an adhesive base in the treatment of oral vesiculoerosive diseases. *Arch Dermatol* 1980; **116**: 898–901.
 - 13 Sacher C, Hunzelmann N. Cicatricial pemphigoid (mucous membrane pemphigoid): current and emerging therapeutic approaches. *Am J Clin Dermatol* 2005; **6**: 93–103.

Copyright of International Journal of Paediatric Dentistry is the property of Blackwell Publishing Limited and its content may not be copied or emailed to multiple sites or posted to a listserv without the copyright holder's express written permission. However, users may print, download, or email articles for individual use.