

# Maxillary labial frenum attachment in children

ELIZABETH A. BOUTSI<sup>1</sup> & DIMITRIS N. TATAKIS<sup>2</sup>

<sup>1</sup>Dental Clinic, Public Health Center, Lavrion, Greece, and <sup>2</sup>Division of Periodontology, College of Dentistry, The Ohio State University, Columbus, OH, USA

*International Journal of Paediatric Dentistry* 2011; 21: 284–288

**Background.** The distribution of the attachment of the maxillary labial frenum in the children of different ethnic backgrounds has not been studied extensively.

**Aim.** The purpose of this cross-sectional study was to examine the prevalence of the various types of maxillary labial frenum attachment in the children of different ethnic backgrounds.

**Design.** Children (aged 1–18) attending a public health clinic in Lavrion, Greece, were clinically examined for maxillary frenum attachment location. Demographic information was recorded. Parents provided written informed consent.

**Results.** The examined children were 226, with mean ( $\pm$ standard deviation) age of  $8.5 \pm 3.0$  years. They were of Greek (51%), Albanian (20%), Turkish (12%), and Afghan (11%) descent. The prevalence of the maxillary labial frenum attachment was mucosal (10.2%), gingival (41.6%), papillary (22.1%), and papillary penetrating (26.1%). Frenum attachment differed significantly by age ( $P = 0.001$ ). The age of children with mucosal- or gingival-type frenum was significantly greater than the age of children with papillary penetrating-type frenum. Frenum attachment did not differ by gender or ethnic background ( $P \geq 0.20$ ).

**Conclusions.** The results of this study suggest that, in children, ethnic background and gender are not associated with maxillary labial frenum attachment type, whereas age is strongly associated.

## Introduction

The frenum is a collagenous fibrous tissue fold of the mucous membrane connecting the lip to the alveolar process in the midline of both maxilla and mandible. The frenum, which embryologically originates as remnant of the central cells of the vestibular lamina at the midsagittal area,<sup>1</sup> consists primarily of connective tissue and epithelium and occasionally contains muscle fibres.<sup>2,3</sup>

The size of the frenum varies among individuals, as does the location where the frenum inserts into the soft tissues covering the alveolar process. When the frenum inserts into the gingiva in a manner that allows the frenum to retract the gingival margin, to facilitate diastema development, or to limit lip movement, it is considered abnormal.<sup>4,5</sup>

In children, the maxillary labial frenum has been associated with several clinical problems. It has been associated with midline diaste-

mata, preventing contact between central incisors; it can complicate orthodontic therapy and can contribute to post-orthodontic relapse;<sup>6</sup> it may also contribute to caries development in breastfeeding children.<sup>7</sup> The maxillary labial frenum is also a local anatomic factor that affects the accumulation and retention of plaque and can interfere with effective toothbrushing, by influencing the patient's ability to remove plaque. In adults, an abnormal frenum might contribute to the establishment and progression of periodontal disease, increase the difficulty in controlling gingival recession, and influence the fit or retention of dentures.<sup>8</sup>

Placek *et al.*<sup>9</sup> introduced a clinical morphological classification of maxillary frenum insertion, depending on the anatomic location of attachment, to help clinicians identify functional problems requiring intervention. They classified frenum attachment based on whether the attachment was located in the mucogingival junction, the attached gingiva, the interdental papilla, and through the interdental papilla right up to the palate. The prevalence of different types of maxillary

Correspondence to:

E. Boutsi, Post Box 18076, Pagrati, Athens 11610, Greece.  
E-mail: eboutsi@otenet.gr

labial frenum has been examined in adults and teens, but studies utilizing this classification in children are lacking. Furthermore, the distribution of frenum attachment type among different ethnic groups has not been examined. The purpose of the present cross-sectional epidemiological study was to describe the prevalence of the 4 types of maxillary labial frenum attachment in children and to determine any possible relation between type of attachment and ethnic background, age, or gender of the children.

## Material and methods

### Experimental design

This study was a cross-sectional epidemiological investigation using a convenience sample of children attending the Public Health Center Dental Clinic, Lavrion, East Attica, Greece. The study was conducted according to the guidelines of the 'Declaration of Helsinki', and all parents or legal guardians of the children who participated provided written informed consent.

### Study population

The systemically healthy children recruited for participation were regular attendees of the Dental Clinic and presented for routine evaluation or treatment. Children with orofacial anomalies, history of surgical intervention in the maxillary labial area, or on medications known to affect the gingiva (e.g., phenytoin) were excluded from the study. Most of the children were local residents of the town of Lavrion, whereas several came from a nearby international refugee camp. The children, aged 1–18, were of various ethnic backgrounds, and all examinations took place between February 2008 and September 2010. The following demographic information was recorded: age, gender, and ethnic background.

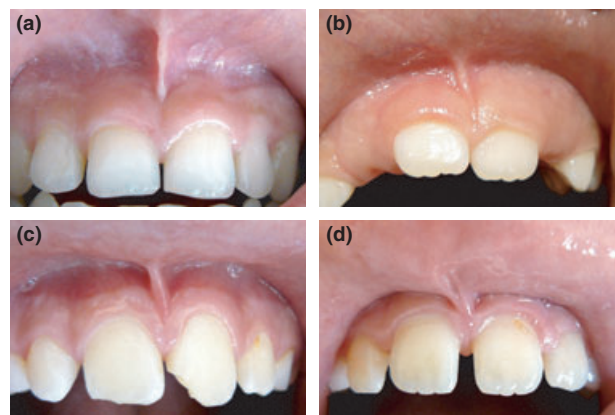
### Clinical examination

All children were examined in the dental chair under adequate lighting by the same examiner. Frenal attachment was categorized

into four types according to the classification of Placek *et al.*,<sup>9</sup> with more detailed criteria as outlined as follows. Frenum insertion was always examined with the lip gently stretched away from the alveolar process in almost horizontal direction.

The four types of frenal attachment were defined as follows (Fig. 1):

- Mucosal (Fig. 1a): frenum inserting up to and including the mucogingival junction with no evidence of crossing into the attached gingiva, i.e., the stretched frenum did not appear to elevate the keratinized tissue.
- Gingival (Fig. 1b): frenum inserting into the attached gingiva and not extending coronal to the line demarcating the base of the midline papilla. The line demarcating the base of the midline papilla was defined as the line connecting the gingival zeniths of the two central incisors.
- Papillary (Fig. 1c): frenum inserting coronal to the line demarcating the base of the midline papilla without any visible evidence of frenum extension to the palatal aspect or of blanching anywhere on the palatal aspect of the midline papilla or on the incisive papilla, even when further tension was applied to the frenum.
- Papillary penetrating (Fig. 1d): frenum inserting coronal to the line demarcating the base of the midline papilla combined with visible evidence of frenum extension to the palatal aspect or of blanching anywhere on the palatal aspect of the midline



**Fig. 1.** Examples of frenum attachment types. (a) Mucosal. (b) Gingival. (c) Papillary. (d) Papillary penetrating.

papilla or on the incisive papilla when further tension was applied to the frenum.

### Data analysis

Descriptive statistics were calculated for the recorded parameters. The association of frenum type with age, gender, or ethnic background was examined using chi-square test or ANOVA as appropriate. Post hoc analysis of differences between specific groups was performed using the Tukey–Kramer test. Statistical significance was set at  $\alpha = 0.05$ .

### Results

A total of 226 children were examined, with a mean ( $\pm$ standard deviation; SD) age of  $8.5 \pm 3.0$  years. Sixty-three children were 1–6 years old, 140 were 7–12 years old, and 23 were 13–18 years old. The gender distribution was fairly even, with 119 children being male (53%), aged  $8.4 \pm 2.8$ , and 107 being female (47%), aged  $8.6 \pm 3.2$ . There was no statistically significant age difference between boys and girls ( $P = 0.52$ , *t*-test). The ethnic background of the children varied, with 116 being of Greek origin (51%), 45 Albanian (20%), 28 Turkish (12%), 25 Afghan (11%), and 12 of other origin (6%).

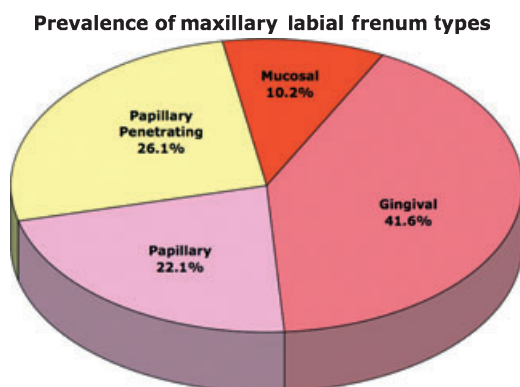
The prevalence of the frenum attachment types is depicted in Fig. 2. The most common type of attachment was the gingival type (almost 42% of the children; Fig. 1b), whereas papillary penetrating-type (Fig. 1d)

or papillary-type (Fig. 1c) attachments were less common; the least common type of attachment was the mucosal one (10% of children; Fig. 1a).

The frenum-type frequency distribution was examined in relation to age, gender, and ethnic background. There were no statistically significant differences in frenum-type distribution between genders ( $P = 0.49$ , chi-square test) or between Greek and non-Greek children ( $P = 0.20$ , chi-square test). Frenum distribution, however, varied by age ( $P = 0.001$ , chi-square test). Age differed significantly among children with different type of frenum attachment ( $P = 0.0006$ ; ANOVA). Children with mucosal-type frenum were the oldest, while children with papillary penetrating-type frenum were the youngest among all groups (Table 1). Post hoc analysis revealed that children with papillary penetrating-type frenum differed significantly in age from children with mucosal- or gingival-type frenum ( $P < 0.05$ ; Tukey–Kramer test) but not from children with papillary-type frenum (Table 1).

### Discussion

The present study investigated the prevalence of different types of maxillary labial frenum attachment in 226 children of different ethnic background, aged 1–18 years old, in Greece. It was found that the most prominent type of attachment, apparent in 42% of the children, was the gingival type of attachment, while the mucosal attachment was the least common. The frenum distribution was found to differ by age; the gingival



**Fig. 2.** Maxillary labial frenum attachment type distribution. Prevalence of four types of frenum attachment in a population of 226 children aged 1–18 years old.

**Table 1.** Children's age by frenum type.

Frenum type	Children (n)	Age (years)
Mucosal	23	$9.4 \pm 2.7^A$
Gingival	94	$9.1 \pm 3.0^A$
Papillary	50	$8.5 \pm 2.9^{A,B}$
Papillary penetrating	59	$7.2 \pm 2.9^B$

Age is reported as mean  $\pm$  standard deviation. Age differs significantly by frenum type ( $P = 0.0006$ , ANOVA). <sup>A,B</sup>Groups connected by same letter are not significantly different from each other (Tukey–Kramer post hoc test).

type of frenum was prominent in children that were of older age, while children with papillary penetrating type of frenum were significantly younger. The distribution was similar for children of Greek and non-Greek origin. To the best of our knowledge, the present study is the first one to compare maxillary labial frenum attachment among children of different ethnic backgrounds and to report on labial frenum anatomy in Greek children.

There are several studies in the literature on the attachment of maxillary labial frenum in children, adolescents, and adults.<sup>9-17</sup> The frenum attachment classification schemes used by different authors, however, vary, and previous studies provided inadequate/incomplete information regarding the employed criteria, or included a juvenile population sample of limited age range, or did not include other information, as will be detailed in the following paragraphs. Furthermore, all previously reported studies included a single ethnic group.

The earliest report on the epidemiology of maxillary labial frenum attachment in children was published by Bergese.<sup>10</sup> In a sample of 428 Italian children aged 9–12, the frenum was found to be inserted most commonly in the attached gingiva (58.2%). The frenum was also classified as attached to the alveolar mucosa (5.5%), the mucogingival junction (12.6%), the sulcus of the free gingiva (10.5%), the free gingiva (7.1%), and the palatal papilla (4.8%); there was no further data analysis in the study. Although the classification schemes vary between the two studies, the results of the present study regarding the most prevalent type of frenum attachment are consistent with the results of Bergese.

In their study, Placek *et al.*<sup>9</sup> examined 465 Czech teens and adults, aged 15–40. For the entire group, they found the mucosal type of maxillary frenum attachment to be most common (46.5%), with the gingival type second most frequent (34.3%). They reported no age or gender difference in the prevalence of different types of frenum attachment; they, however, did not provide any statistical analysis. Because of the lack

of information on the number of children included in the study or the distribution of the frenum categories in children, it is not possible to directly compare their results with the present study.

Lindsey<sup>11</sup> examined 1285 English infants, children, and adults and reported that the prevalence of papillary penetrating frenum, as determined by movement or blanching in response to lip pull, decreased from 43% in infants and children with only the permanent central incisors erupted, to 14% in children with all six permanent maxillary anterior teeth erupted, to  $\leq 7\%$  in adults and children with all maxillary permanent teeth erupted (excluding third molars). The present findings are consistent with the significant decline of papillary penetrating frenum with increasing age (both chronological and dental). Lindsey did not characterize other forms of attachment; therefore, no information is available regarding the distribution of other types of frenum attachment in the English sample.

Popovich *et al.*<sup>12</sup> reported that from age 9 to age 16, the frenum attachment might move from a more coronal to a more apical position, while movement in the opposite direction was never detected. The results of this longitudinal assessment are consistent with the results of the present cross-sectional study, where the children with the most coronal attachment were, on average, the youngest. The explanation for the apparent apical migration of the frenum is the growth of the alveolar process in a coronal direction.<sup>12</sup>

Jańczuk and Banach<sup>13</sup> in a study of Polish teens aged 15–17, and using the Placek classification, reported that the most common type of attachment was mucosal (39%), closely followed by the gingival type (36%), with the papillary penetrating being the least common (5%). The Polish study reported 'slight differences' in the prevalence distribution between boys and girls but no further information. The prevalence differences between the present study and the results of Jańczuk and Banach can be attributed, at least in part, to the significant difference in the age of the examined children.



Addy *et al.*<sup>14</sup> examined Welsh children aged 11.5–12.5. The vast majority of the children had maxillary frenum attached into the attached gingiva (77%); the high prevalence of the gingival attachment in this Welsh study is consistent with the results of the present study.

Kaimenyi<sup>15</sup> used the Placek classification to examine 419 Kenyan children with midline diastema and reported that 50% of them had gingival attachment, with 26% having mucosal and 24% having papillary penetrating. No information was provided on the age or gender of the children with diastema; this makes impossible any direct comparisons with the present study. Although other studies exist in children,<sup>16</sup> the use of a very different classification system<sup>17</sup> precludes direct comparisons with the present study.

The present study is the first one to provide a direct comparison between children of different ethnic backgrounds. The results indicate that, at least for the ethnic groups included herein, there is no difference in the prevalence of frenum attachment types among different ethnic groups.

The overall evidence indicates that the attachment of the frenum in children will shift to a more apical position with increasing age. While there is strong evidence for age-dependent differences in frenum attachment, there is little, if any, evidence to support gender- or ethnicity-dependent differences. Therefore, a clinician assessing the anatomy of the maxillary labial frenum should take into consideration the age of the child under examination and the possibility that the morphology of the frenum attachment may change as the child grows older.

#### What this paper adds?

- This paper provides the first direct comparison among different ethnic groups, and the first report on Greek children, regarding frenum attachment types.

#### Why this paper is important to paediatric dentists?

- The evidence presented indicates that, in children, ethnic background and gender are not associated with the type of maxillary labial frenum attachment, while age is strongly associated.

## References

- 1 Moore KL. *The Developing Human*, 4th edn. Philadelphia: WB Saunders Co, 1988.
- 2 Gartner LP, Schein D. The superior labial frenum: a histologic observation. *Quintessence Int* 1991; **22**: 443–445.
- 3 Ross RO, Brown FH, Houston GD. Histologic survey of the frena of the oral cavity. *Quintessence Int* 1990; **21**: 233–237.
- 4 Bresslin WW. Excision of the abnormal frenum. *J Can Dent Assoc* 1949; **15**: 20.
- 5 Fischer TJ, Psaltis GL. The diastema and the abnormal frenum. *ASDC J Dent Child* 1981; **48**: 264–268.
- 6 Edwards JG. The diastema, the frenum, the frenectomy: a clinical study. *Am J Orthod* 1977; **71**: 489–508.
- 7 Kotlow LA. The influence of the maxillary frenum on the development and pattern of dental caries on anterior teeth in breastfeeding infants: prevention, diagnosis, and treatment. *J Hum Lact* 2010; **26**: 304–308.
- 8 Fowler EB, Breault LG. Early creeping attachment after frenectomy: a case report. *Gen Dent* 2000; **48**: 591–593.
- 9 Placek M, Skach M, Mrklas L. Significance of the labial frenum attachment in periodontal disease in man. Part I. Classification and epidemiology of the labial frenum attachment. *J Periodontol* 1974; **45**: 891–894.
- 10 Bergese F. Research on the development of the labial frenum in children of age 9–12 (in Italian). *Minerva Stomatol* 1966; **15**: 672–676.
- 11 Lindsey D. The upper mid-line space and its relation to the labial fraenum in children and in adults. A statistical evaluation. *Br Dent J* 1977; **143**: 327–332.
- 12 Popovich F, Thompson GW, Main PA. The maxillary interincisal diastema and its relationship to the superior labial frenum and intermaxillary suture. *Angle Orthod* 1977; **47**: 265–271.
- 13 Jańczuk Z, Banach J. Prevalence of narrow zone of attached gingiva and improper attachment of labial frena in youths. *Community Dent Oral Epidemiol* 1980; **8**: 385–386.
- 14 Addy M, Dummer PM, Hunter ML, Kingdon A, Shaw WC. A study of the association of fraenal attachment, lip coverage, and vestibular depth with plaque and gingivitis. *J Periodontol* 1987; **58**: 752–757.
- 15 Kaimenyi JT. Occurrence of midline diastema and frenum attachments amongst school children in Nairobi, Kenya. *Indian J Dent Res* 1998; **9**: 67–71.
- 16 Díaz-Pizán ME, Lagravère MO, Villena R. Midline diastema and frenum morphology in the primary dentition. *J Dent Child (Chic)* 2006; **73**: 11–14.
- 17 Sewerin I. Prevalence of variations and anomalies of the upper labial frenum. *Acta Odontol Scand* 1971; **29**: 487–496.

Copyright of International Journal of Paediatric Dentistry is the property of Wiley-Blackwell and its content may not be copied or emailed to multiple sites or posted to a listserv without the copyright holder's express written permission. However, users may print, download, or email articles for individual use.