

denture until the person has fewer than three posterior functional units.”⁷ It must, however, also be emphasized that esthetic concerns play a role in seeking treatment and resisting the functional implications of an SDA. The subjective role played in patients’ motivation to seek treatment remains complex and often misunderstood. Numerous health care disciplines, including prosthodontics, are confronted with patients’ needs to feel good about their appearance, with a visible display of missing molars regarded as unacceptable.

Consequences

The scientific findings made in SDA patients have led to the concept of a shortened dental arch. This concept includes both a diagnostic and a therapeutic challenge. Since the requirements of a functional dentition can also be met with a shortened dental arch, the reasons for treating SDA patients have to be provided in each individual case. Priority should be given to maintaining and replacing the strategically important parts of the dental arch—the anterior and premolar regions. However, since the functional requirements may vary considerably from one patient to the next, the therapy

in each case should be adjusted to the individual conditions of the patient and to the patient’s needs and ability to adapt. Moreover, a patient’s esthetic concerns regarding dental appearance may play a significant role in determining the merits of an SDA mind-set in finalizing a treatment plan.

References

1. Beyron H. Optimal occlusion. *Dent Clin North Am* 1969;13:537–554.
2. Käyser AF. Shortened dental arches and oral function. *J Oral Rehabil* 1981;8:457–462.
3. Armellini D, von Fraunhofer JA. The shortened dental arch: A review of the literature. *J Prosthet Dent* 2004;92:531–535.
4. Sarita PTN, Witter DJ, Kreulen CM, Van’t Hof MA, Creuger NHJ. Chewing ability of subjects with shortened dental arches. *Community Dent Oral Epidemiol* 2003;31:328–334.
5. Witter DJ, Creugers NH, Kreulen CM, de Haan AF. Occlusal stability in shortened dental arches. *J Dent Res* 2001;80:432–436.
6. Sarita PTN, Kreulen CM, Witter DJ, Creugers NHJ. Signs and symptoms associated with TMD in adults with shortened dental arches. *Int J Prosthodont* 2003;16:265–270.
7. Leake JL, Hawkins R, Locker D. Social and functional impact of reduced posterior dental units in older adults. *J Oral Rehabil* 1994;21:1–10.

Osteoarthrosis/Osteoarthritis in the Temporomandibular Joints

Pierre de Grandmont, DMD, MSc
Professor, Faculty of Dental Medicine
University of Montreal, Canada
Email: pierre.de.grandmont@umontreal.ca

Temporomandibular disorders (TMDs) can be categorized into three groups: muscle disorders, internal derangements, and degenerative diseases. Historically, the latter have been overlooked as a structural basis for TMD.

Osteoarthrosis is a noninflammatory disease characterized by a pattern of reaction of the joints to injury. Deterioration and abrasion of articular cartilage and soft tissue surfaces, thickening and remodeling of the underlying bone, and formation of marginal spurs and subarticular cysts can be observed. These changes are very common in elderly patients, but are often asymptomatic.

Patients may become symptomatic and severely disabled when osteoarthrosis is associated with synovitis. Secondary inflammatory changes resulting from tissue damage in the joint may play a role in producing pain. The term osteoarthritis best describes this secondary inflammatory arthropathy.

Prevalence

Osteoarthrosis/osteoarthritis (OA) is the most common degenerative disease of temporomandibular joints (TMJs); however, the prevalence is difficult to establish since there is a lack of concordance between structural changes and pain. The method of examination is a significant factor in determining the prevalence of OA (Table 1 and Fig 1). OA is strongly correlated with age, and occurs more often and is more generalized in women than in men.

Table 1 Prevalence of OA in TMJs

Method of evaluation	Prevalence (%)
Clinical	8–18
Radiologic	14–44
Macro/Microscopic (from autopsy)	22–84

Etiology

The etiology of TMJ OA is not clearly established but appears to include both systemic and local factors. Joint overload is predominant in the development of OA. Articular cartilage is primarily affected since it shows limited adaptive capacity compared with other connective tissues and subchondral bone. Overloading may exceed mechanical properties of the cartilage and disturb tissue remodeling.

Age is clearly a predisposing factor, although the evidence of age-dependant alterations in joint tissue is unclear. Many autopsy studies suggest a strong correlation between loss of molar support and the occurrence of OA, especially in individuals over 40 years of age. Because of the high prevalence of partial and complete edentulism in elderly patients, it can be suggested that the role of aging is significant in this context of depleted dentitions and resulting adverse biomechanical loading.

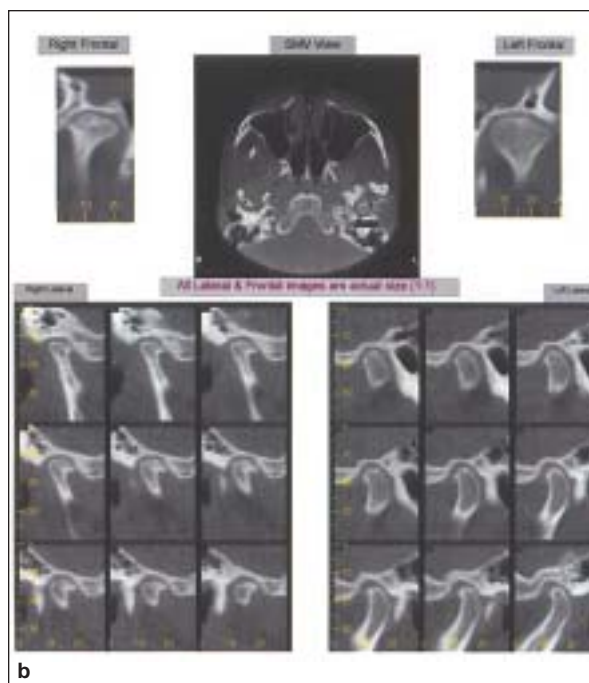
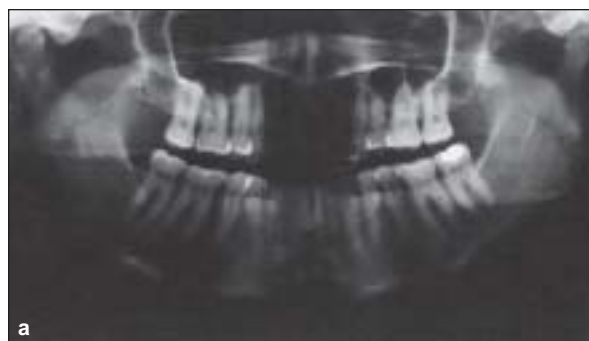With rare exceptions, OA is associated with disc displacement. It is also believed that joint overload plays a role in the development of internal derangement (ID). The relationship of time onset between ID and OA is not fully understood. It seems more likely that ID precedes OA; however, it is possible that the causative event simultaneously initiates both conditions.

Trauma to the face may also cause or aggravate OA. Repetitive loading associated with parafunction is possibly an etiologic factor, but a clear relationship has not been established. Genetic and metabolic factors that could influence the threshold for tissue damage may also be important factors in the development of OA.

Signs and Symptoms

Patients usually complain of pain and tenderness in the joint, jaw muscle fatigue, stiffness and tiredness, reduced range of motion, and joint noises during mandibular movement. Pain is aggravated by wide opening of the jaw, mastication, and parafunction, and can radiate from the joint to the temple, ears, side of neck, and upper shoulder. A history of changing occlusion and acquired facial skeletal deformity (open bite, asymmetry) may also be signs of OA.

These signs and symptoms are similar to those of other TMDs with subtle but very significant exceptions. Generally, OA is unilateral, although bilateral involvement does occur. In these cases, one side usually shows greater severity. OA is generally characterized by morning jaw stiffness, and the symptoms appear to worsen during the day. Pain over the joint and crepitation are often present. Radiographic evidence is frequently visible.



Figs 1a and 1b (a) Orthopantomogram showing structural changes in both joints. (b) Axial cuts and coronal reconstructions showing reduced joint spaces, subchondral sclerosis, and the presence of osteophytes (all lateral and frontal images are actual size [1:1]). (Images courtesy of Dr Michael Pharoah, University of Toronto.)

There is, however, a poor correlation between radiographic findings and clinical symptoms. Because OA affects the articular cartilage first, early changes such as reduced joint space—indicating loss of the articular cartilage and/or perforation of the disc—may not be detected in radiographs. The most common early change in the condyle is subchondral bone sclerosis; however, substantial changes in mineralized tissues are required for detection. As the disease progresses, flattening and marginal lipping of the condyle and flattening of the articular eminence can be observed. In the late stages, the changes are in the form of erosion of the cortical plate and/or osteophyte formation.

Signs and symptoms improve with time in most individuals. The nature of OA suggests variable symptomatic progressions, which usually burnout in 12 to 24 months. On the other hand, pathologic changes in the TMJ progress with time at a rate that varies among patients.

Clinical Management

A detailed history, head and neck evaluation, and general physical examination are essential for diagnosis. Imaging of the TMJ is necessary to establish the presence of pathology and stage of disease, in order to select the appropriate treatment and assist in prognosis.

Because adaptive mechanisms seem to play a major role in the natural course of TMJ degenerative disorders, treatment should seek to promote a joint condition that is most likely to repair any damage. The goal of nonsurgical management is to reestablish the balance between degradative and repair processes within the affected tissues.

Therapeutic strategies include symptomatic treatment, control or reduction of predisposing factors, and treatment of pathologic sequelae. Surgical management should only be considered after reasonable nonsurgical efforts and when the patient's quality of life is significantly affected.

Recommended References

- Abubaker AO. TMJ arthritis. In: Laskin DM, Greene CS, Hylander WL (eds). *TMDs: An Evidence-Based Approach to Diagnosis and Treatment*. Chicago: Quintessence, 2006:229–240.
- Zarb GA, Carlsson GE. Osteoarthritis/osteoarthritis. In: Zarb GA, Carlsson GE, Sessle BJ, Mohl ND (eds). *Temporomandibular Joint and Masticatory Muscle Disorders*, ed 2. Copenhagen: Munksgaard, 1994:298–314.

A previous version of this paper appeared in *Int J Prosthodont* 2007;20:357–358.

Literature Abstract

Oral cancer screening in a high-risk underserved community—Vancouver Downtown Eastside

The purpose of this clinical study was to assess the need for oral cancer screenings and patients' acceptance of screening and follow-up treatment in a medically underserved community. Two hundred four eligible patients were recruited at a free dental clinic in Downtown Eastside (DTES) Vancouver between September 2004 and April 2006. This community was chosen because its demographics suggest that the members were at a high risk for developing oral cancer due to poor access to care and a high-risk lifestyle. Eligible patients were residents of the DTES, mentally sound, English or Mandarin speaking, and were excluded if they required multiple tooth extractions or were intoxicated at the time of examination. Patients were clinically examined using a head and neck intraoral visual screening test. Any abnormalities were recorded in the patients' dental records. Patients also participated in a personal interview where a trained employee asked questions about demographics, health history, and tobacco and drug use. Data were analyzed using descriptive statistics. Participants were mainly middle-aged (mean = 47.4 years), male, Caucasian, unemployed, and had a low yearly income of less than \$12,000. Ninety-eight percent ($n = 200$) of eligible patients agreed to be screened; 61% (119) needed further assessment due to a significant clinical anomaly. Sixteen percent (31) had leukoplakia with 77% of those 31 patients having it in high-risk sites (tongue, floor of the mouth, and soft palate). However, less than half of patients with suspicious lesions (12 out of 31) consented to a biopsy. Two of the patients biopsied were diagnosed with squamous cell carcinoma and eight patients were diagnosed with precancerous leukoplakia. These cancer and precancer diagnoses in the DTES are relatively high compared to the general population. Cancer incidence in the DTES may be underrepresented considering the low acceptance of biopsies. Demographic data compared with 2001 census information from the DTES showed that women, the Chinese community, and the elderly are all underrepresented in the clinical study when compared with the frequency of these groups in the community ($P < .0001$ for all groups). These groups may be receiving oral care elsewhere or not at all. The results of this clinical study suggest that the incidence of specific cancers is higher in the DTES and there is a need for oral cancer screenings in this high-risk population. This study suggests that the acceptance of screening is high in this community and the acceptance of follow-up treatment is low. Finally, it recommends a need for oral health care outreach to underrepresented groups.

Poh CF, Hislop TG, Currie B, et al. *J Health Care Poor Underserved* 2007;18:767–778. **References:** 21. **Reprints:** Dr Catherine F. Poh, Faculty of Dentistry, University of British Columbia, 2199 Wesbrook Mall, Vancouver, BC, Canada V6T 1Z3. Email: cpoh@interchange.ubc.ca—Alvin G. Wee, UNMC Dept Otolaryngology, Omaha, NE

Copyright of International Journal of Prosthodontics is the property of Quintessence Publishing Company Inc. and its content may not be copied or emailed to multiple sites or posted to a listserv without the copyright holder's express written permission. However, users may print, download, or email articles for individual use.