

# The Immediately Loaded Single Implant–Retained Mandibular Overdenture: A 36-Month Prospective Study

Glen Liddelow, BDS<sup>c</sup>, MScD, DClinDent, FRACDS<sup>a</sup>/Patrick Henry, BDS<sup>c</sup>, MSD, DDSchc, FRACDS<sup>b</sup>

**Purpose:** The aim of this study was to ascertain whether simplifying mandibular overdenture treatment by using single-stage surgery and immediate prosthetic loading of a single implant will achieve acceptable implant success rates, functional improvement, and increased patient satisfaction. As part of this study, the Mk III Brånemark implant with an oxidized surface was compared to the classic machined Mk III Brånemark implant. **Materials and Methods:** Thirty-five patients (mean age: 68 years) with problematic mandibular dentures were treated. The primary complaints among the patients referred to the clinic for treatment were poor retention of the mandibular denture, instability, denture sores, and phonetic problems. Initially, patients were placed randomly into the “machined surface” or “oxidized surface” groups. A single implant was placed in the mandibular midline with high initial stability. A ball attachment was placed and the retentive cap incorporated into the existing denture. Reviews took place at 3, 12, and 36 months posttreatment. Clinical assessments, radiographs made with custom film holders, and stability measurements by both manual and resonance frequency analysis methods were recorded. All complications, failures, maintenance, and reasons for dropout were noted. Visual analog scale questionnaires were used to record patient satisfaction (analysis of variance:  $P < .05$ ).

**Results:** Three of eight machined-surface implants failed, representing an unacceptably high failure rate (37.5%). The machined surface was therefore discontinued for this study. One machined and two oxidized-surface implants did not achieve sufficient primary stability to be immediately loaded, so they were treated with a two-stage delayed loading protocol. The 25 immediately loaded oxidized-surface implants were all classified as surviving at the 36-month recall. Patient satisfaction was very high with a significant increase in all comfort and functional parameters.

**Conclusions:** Within the limitations of this study and research design, it appears that over a 3-year observation period, the immediately loaded single implant–retained mandibular overdenture, using an oxidized-surface implant and the existing prosthesis in a small group of prosthetically maladaptive patients, can provide a beneficial treatment outcome with a minimal financial outlay. *Int J Prosthodont* 2010;23:13–21.

Demographic growth, in absolute numbers, is projected to outpace the decline in edentulism.<sup>1</sup> Hence, the need for dentures will not diminish over the next quar-

ter century, and those in need of dentures are most likely to be among society's poorest and least advantaged.<sup>2</sup>

With prolonged life expectancy, chronic illness is the major health care problem in Western society. Consequently, management rather than the curing of a chronic disorder is the primary challenge facing all health care professions.<sup>2</sup> Edentulism is a chronic condition and therapy is palliative, aimed at improving function and quality of life.<sup>3</sup>

Fortunately, most complete denture wearers are able to adapt and cope with their disability effectively, without any significant disturbance to their quality of life.

<sup>a</sup>Prosthodontist, The Brånemark Center, West Perth, Western Australia.

<sup>b</sup>Director, The Brånemark Center, West Perth, Western Australia.

**Correspondence to:** Dr Glen Liddelow, The Brånemark Centre, 64 Havelock Street, West Perth 6005, Western Australia. Fax: 61 8 9321 0336. Email: gliddelo@cylle.uwa.edu.au

Nonetheless, other denture wearers suffer substantially from chronic dysfunction, pain, low self-esteem, and reduced quality of life. For these patients, dentures supported by implants would offer relief, comfort, and optimism, especially if in the mandible.<sup>2</sup> There is an increased appreciation within the health care professions for the need to incorporate patient preferences into the treatment decision-making process. The interest has broadened beyond survival into the areas of psychosocial function and perceived health. Patient-based measures, therefore, become an important outcome of treatment.<sup>3</sup>

Two randomized trials by Awad et al<sup>4,5</sup> in Canada compared posttreatment satisfaction in a middle-aged<sup>4</sup> (35 to 65 years) cohort of patients receiving new complete dentures and two-implant bar-retained mandibular overdentures with a new complete maxillary denture. The second study<sup>5</sup> followed the same protocol; however, the patients were in the elderly category (65 to 75 years) and the overdenture design was that of two nonsplinted implants with ball attachments. Both groups of overdenture patients showed significantly higher levels of general satisfaction than the patients receiving conventional dentures. A trial by Geertman et al<sup>6,7</sup> included 151 dissatisfied denture patients randomly allocated to receive new complete dentures or implant-retained mandibular overdentures. The overdenture group rated their ability to chew hard and tough foods significantly higher than did the conventional denture group 1 year posttreatment.

Positive outcomes included psychosocial outcomes, such as satisfaction and oral health-related quality of life, as well as functional outcomes, such as chewing ability.<sup>6-8</sup>

Numerous studies attest to the favorable implant survival rates when using overdentures in the edentulous mandible.<sup>9-11</sup> However, few have detailed long-term maintenance data.<sup>12-14</sup> Prosthetic maintenance may include component fracture, denture relining, and prosthesis replacement. Maintenance requirements appear to be greatest in the first year of use and may be attachment specific.<sup>12</sup> Use of a single implant placed in the midline symphysis to retain an overdenture and using a two-stage delayed loading approach has been documented by both Cordioli et al in 1997<sup>15</sup> and Krennmair and Ulm in 2001.<sup>16</sup> Both concluded that in the short- to medium-term, this treatment modality had merit, particularly for elderly patients experiencing difficulties with conventional mandibular complete dentures.

The purpose of this study was to ascertain whether simplifying mandibular overdenture treatment by using single-stage surgery and the immediate prosthetic loading of a single implant will achieve acceptable implant success rates, functional improvement, and in-

creased patient satisfaction. As part of this study, the Mk III Brånemark implant with an oxidized surface (TiUnite, Nobel Biocare) was compared to the classic machined (turned) Mk III Brånemark implant (Nobel Biocare).

## Materials and Methods

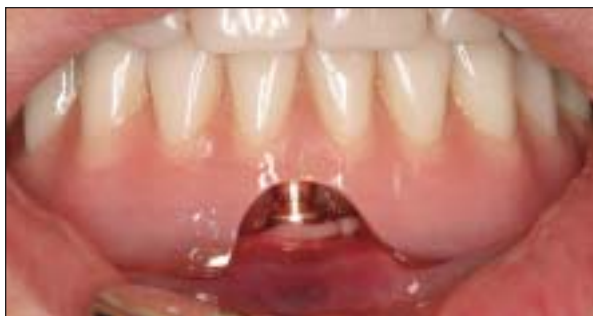Thirty-five completely edentulous subjects (10 men, 25 women) ranging from 50 to 89 years of age (mean: 68 years) who had been completely edentulous in the mandible for at least 1 year were included in this study. All patients signed an informed consent form in accordance with the Declaration of Helsinki. Ethical approval for the project was granted by The Human Research Ethics Committee of The University of Western Australia, Perth, Australia. The primary complaints among the patients referred to the clinic for treatment related to poor retention of the mandibular denture, instability, denture sores, and phonetic problems.

Inclusion criteria dictated that the patient be completely edentulous for at least 12 months, maladaptive to their mandibular prosthesis, and have sufficient bone for an implant of at least 10-mm length and 4-mm diameter. Exclusion criteria included conditions precluding surgery, logistic or physical reasons that could affect follow-up, psychiatric problems, drug or alcohol abuse, disorders to the implant site related to a history of radiation therapy, neoplasia, or bone augmentation.

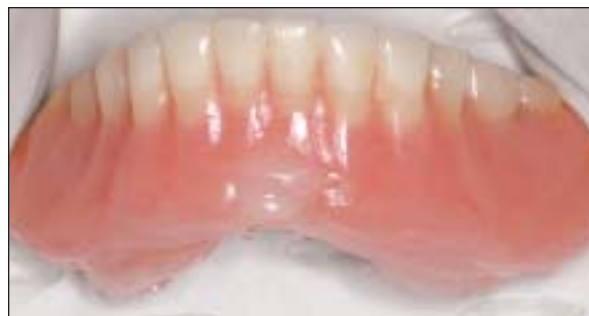The components used were regular platform Brånemark Mk III implants with a diameter of 4 mm. All implants were identical except for the surface treatment, which consisted of either a traditional machined (turned) surface or an oxidized surface. The Nobel Biocare 3.5-mm-diameter ball attachment with a plastic cap and rubber O-ring provided the prosthetic anchorage.

The implant surface received was chosen randomly by drawing identical envelopes from a box just prior to implant installation. The type of surface to be received was enclosed in the envelope.

The surgical and prosthetic procedures are detailed elsewhere.<sup>17</sup> An implant of at least 10 mm in length was inserted in the midline symphysis region of the mandible after adequate presurgical diagnostics to ensure a prosthetically driven implant placement. Initial stability required at least 45 Ncm of insertion torque and a resonance frequency analysis (RFA) (Osstell, Integration Diagnostics) implant stability quotient (ISQ) reading of at least 60. If stability was achieved, the ball attachment was connected ensuring 2 mm of abutment collar height above the mucosa, and tightened to 32 Ncm with a torque wrench (Nobel Biocare). Insufficient stability dictated placement of a cover screw and soft tissue closure for a conventional two-stage protocol.



**Fig 1a** Complete relief of the denture from touching the ball attachment and immediate surgical region.



**Fig 1b** Tissue conditioner relining of the surgical region immediately after implant placement (labial view).

### Prosthetic Procedures

The first 15 patients treated had their retentive element immediately secured to their denture with autopolymerizing acrylic resin (GC Unifast, GC Dental). This resulted in some tissue proliferation and a delayed healing response in 6 patients. Subsequent patients had their denture relieved around the ball attachment (Fig 1a) and relined with a thickly mixed tissue conditioner (Viscogel, Dentsply) (Fig 1b). This change in protocol resulted in greater postoperative comfort and uneventful healing.

All patients were limited to a soft diet for 6 weeks and instructed to leave the denture out at night. Chlorhexidine 0.2% mouthwashes (Savacol, Colgate) were employed for 1 week postoperatively. A soft toothbrush was used for plaque control measures after the first week. Reviews were scheduled at 1, 2, and 6 weeks, 3 and 6 months, and 1, 2, and 3 years after implant placement.

The implants were assessed individually to fulfill the requirements for Grade 1 quality of success, advocated by Roos et al,<sup>18</sup> as follows:

- Absence of mobility was assessed at 3, 12, and 36 months by removal and reattachment of the abutment together with a retorquing of the abutment screw to 32 Ncm without a simultaneous counteracting of the force. Mobility or sensation (pain) was regarded as a sign of lost osseointegration.
- RFA was performed at 3, 12, and 36 months while the abutment was removed.
- Periapical radiographs were obtained at insertion, and 3, 12, and 36 months postoperatively. The distance

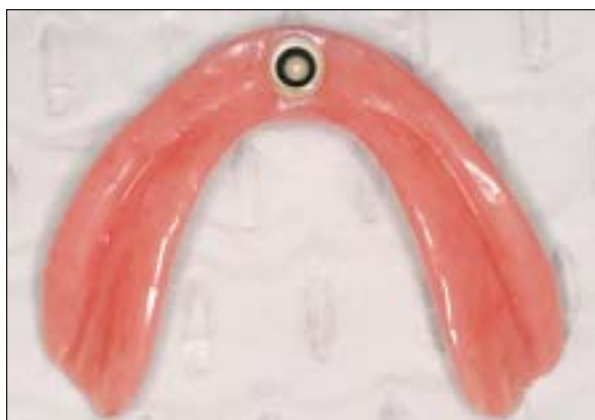from the collar of the implant to the most coronal point where the bone was in contact with the implant was measured with the aid of a graduated 7× magnification loupe.

- Soft tissue was inspected visually with the abutment removed with regard to color and morphology. Soft tissue problems such as infections, persistent pain, paresthesia, and discomfort were noted.

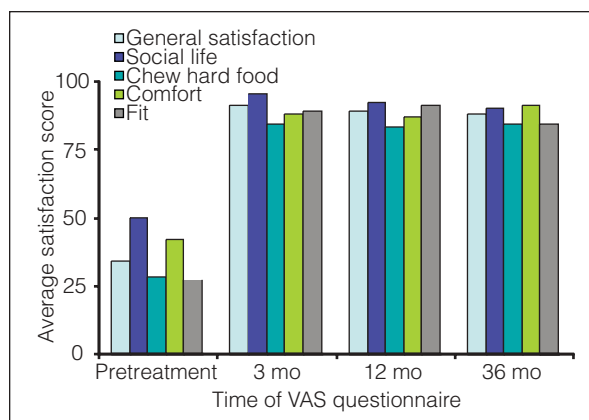
In this way, each individual implant was tested and could be defined as either a failure, failing, or surviving.

Self-administered questionnaires that followed the visual analog scale (VAS) method were filled out by patients preoperatively and at each scheduled recall to assess oral comfort and function.<sup>19,20</sup> There were 10 questions covering five categories: general satisfaction, social life, mastication of hard food, comfort, and fit. Data were entered into a spreadsheet (Microsoft Excel version 10, Microsoft) and all statistical analyses were performed using statistical software (SPSS version 12, SPSS). One-way repeated-measures analysis of variance (ANOVA) was used to determine differences between means ( $P < .05$ ).

A denture reline impression (Extrude, Kerr) was made 6 weeks after implant placement to incorporate the retentive element (plastic cap with O-ring ref, DCB 113-0, Nobel Biocare) and reline the entire intaglio surface of the denture with high-strength heat-polymerized acrylic resin (Implacryl, Vertex), as illustrated in Fig 2. The denture was reinserted and subjected to a conventional relining evaluation and occlusal adjustment. One author carried out all surgical and prosthetic procedures.



**Fig 2** Denture with retentive element.



**Fig 3** Patient-reported improvement in comfort and function from pretreatment to 36 months (oxidized group).

**Table 1** Details of Patients with Failed Machined Implants

Patient	Age (y)	Sex	Bone shape*	Bone quality*	Implant length (mm)	Abutment length (mm)	Unicortical or bicortical stability	Smoking history	Initial RFA ISQ	Medical history
1	60	F	C	2	13	5.5	B	20/day	68	Asthmatic, chronic back pain
2	64	M	C	3	18	4	U	Nonsmoker	75	NAD
3	69	F	D	2	13	4	B	6–10/day	81	NAD

F = female; M = male; B = bicortical; U = unicortical; NAD = no abnormality detected.

\*Bone shape and quality graded according to Lekholm and Zarb.<sup>21</sup>

## Results

In total, 35 patients had 35 implants inserted. Three implants did not fulfill the requirement for sufficient implant stability, ie, did not have an insertion torque greater than 45 Ncm or an RFA of 60 ISQ or greater. These implants had a cover screw placed and the soft tissue closed. The implants were uncovered, ball attachment placed, and the prosthesis relined 3 months later. These implants (1 machined and 2 oxidized) successfully integrated and were all in function at the 36-month follow-up. However, they have not been included in the statistical analysis since they were not immediately loaded.

One patient died 18 months after implant placement from unrelated causes. Another patient elected to receive a maxillary fixed implant-supported prosthesis, also 18 months after implant placement. Three additional implants were then placed in the mandible to support a fixed mandibular prosthesis, since the loading on a single implant overdenture was considered too great opposing the maxillary fixed prosthesis. All remaining patients were available for the 36-month follow-up examination.

The remaining 23 immediately loaded oxidized implants were all tested individually at the 36-month re-

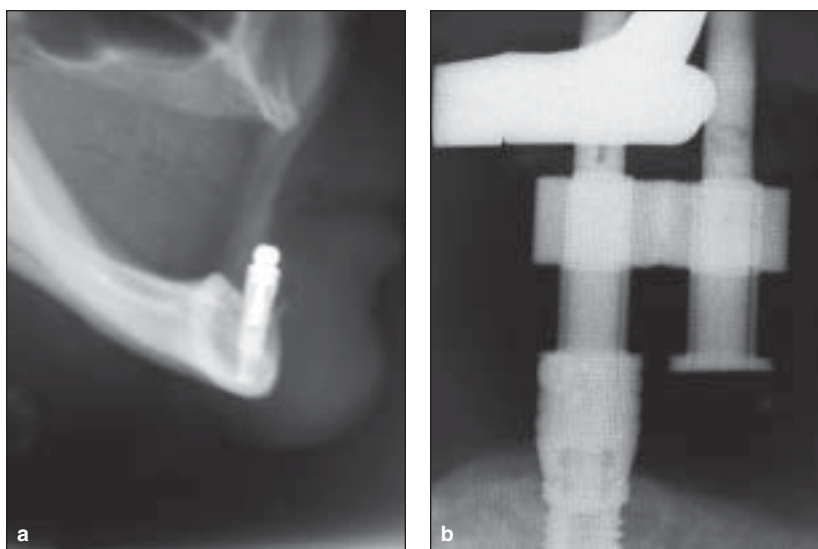
call, yielding a survival rate of 100%, according to Roos et al.<sup>18</sup>

In contrast, the machined implants experienced three failures from seven immediately loaded implants. Table 1 outlines the details of the patients in whom these failures occurred. Two implants failed within 6 weeks and the other failure occurred at 8 weeks due to pain on percussion and attempted rotation. However, the patient did not wish the implant to be touched until the implant had essentially exfoliated. Consequently, considerable bone loss occurred at the site. This patient was subsequently successfully treated using two implants and a ball attachment overdenture. These failures occurred early in the study when only eight machined implants had been placed. It was therefore decided to abandon use of the machined implants on ethical grounds due to an unacceptably high failure rate (42.9%), when correlated with accepted criteria for assessment of implant performance.<sup>18,22</sup> Table 2 provides the details of the immediately loaded implants.

The VAS questionnaires filled out by all patients at pretreatment, and 3, 12, and 36 months after implant placement showed a marked improvement in all parameters of oral comfort and prosthesis function. Maintenance of this satisfaction level continued through the 36-month recall (Fig 3).

**Table 2** Details of Immediately Loaded Implants Placed

Length (mm)	Machined		Oxidized	
	Placed	Failed	Placed	Failed
10	0	0	1	0
11.5	1	0	9	0
13	2	2	7	0
15	2	0	4	0
18	2	1	4	0
Total	7	3 (42.9%)	25	0 (0%)

**Figs 4a and 4b** (a) Lateral cephalometric radiograph and (b) periapical radiograph showing superimposition of the genial tubercles.**Table 3** Mean (SD) Bone Loss from Baseline to 36 Months for Both Groups

	3 mo (mm)		12 mo (mm)		36 mo (mm)	
	Left	Right	Left	Right	Left	Right
Machined	1.42 (1.47)	1.80 (1.20)	1.88 (1.11)	2.15 (0.66)	2.12 (0.66)	2.30 (0.74)
Oxidized	0.32 (0.51)	0.49 (0.50)	0.58 (0.52)	0.69 (0.52)	0.87 (0.68)	0.91 (0.65)

SD = standard deviation.

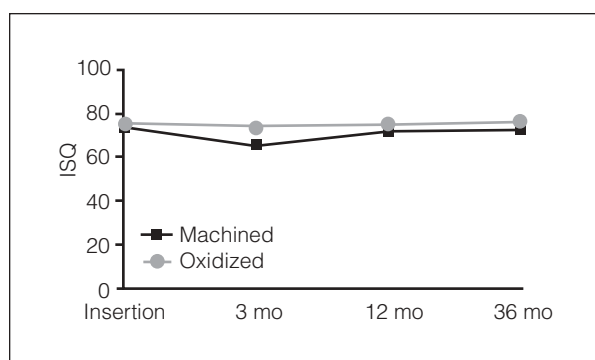
ANOVA was completed for each group with two degrees of freedom. A significant improvement ( $P > .05$ ) in all parameters was noted from pretreatment to all posttreatment recalls. No significant differences were seen between posttreatment recall periods.

Radiographic follow-up was difficult in this study due to the clinical problems associated with film placement that directly impinged on the lingual frenum coupled with superimposition of the genial tubercles and the marginal bone (Figs 4a and 4b). Periapical radiographs were obtained at insertion, and 3, 12, and 36 months postoperatively. The distance from the collar of the implant to the most coronal point where the bone was in contact with the implant was measured. The left and right measurements were made with the aid of a 7×

magnification loupe (Table 3). Approximately 48% of the oxidized-surface group had quantitatively assessable radiographs. No peri-implant radiolucency was noted.

There was a significant increase in bone loss over time for both groups ( $P = .001$ ). Bone loss in the oxidized group was only significant between 0 and 36 months ( $P < .05$ ). The bone loss from 3 months to 12 months was clinically measurable but not statistically significant ( $P = .247$ ). For the machined group, bone loss was statistically significant between 0 and 3 months, 0 and 12 months, and 0 and 36 months ( $P < .05$ ).

Comparing groups showed significantly more bone loss in the machined groups. However, due to the size of the machined group, the derived statistics are unreliable.



**Fig 5** Mean ISQ values with the abutment removed at various recall intervals. The difference between groups is significant only at 3 months ( $P = .007$ ).

Three denture base fractures occurred at the site of implant attachment. These occurred within 3 months of attaching the retentive cap with autopolymerizing acrylic resin at the time of surgery. No denture base fractures were recorded after the protocol was changed to a heat-cured reline. At the 3-year follow-up, no ball attachment retentive caps had failed and no rubber O-rings required replacement. No discernable wear of the ball attachment was detected and abutment screw loosening did not occur.

RFA was carried out on all implants at insertion and each recall visit by removing the ball attachment and collar, followed by attachment of an implant-level transducer facing labiolingually (Fig 5).

The results showed a generally high mean initial ISQ value of  $72.25 \pm 3.4$  for the machined group and  $74.76 \pm 5.6$  for the oxidized group. Maintenance of this high value up to the 36-month review was noted for both groups (ISQ =  $72.5 \pm 3.0$  for the machined group, ISQ =  $75.5 \pm 4.2$  for the oxidized group). The machined group showed a statistically significant drop in ISQ at the 3-month recall ( $P = .007$ ) (Fig 5). The stability recovered by 12 months. Many oxidized implants showed a small increase in ISQ value after 3 months, although this was not statistically significant ( $P = .630$ ). There was no statistical difference between values at baseline, 3, 12, and 36 months for the oxidized implants ( $P = .311$ ).

Plaque control was acceptable for most patients and considered relatively simple by the patients themselves. Soft tissue health was acceptable in all patients with no evidence of mucosal enlargement at the 6-week and 12- and 36-month observation times. Calculus buildup that impeded seating of the retentive cap was encountered on two occasions and was controlled by more diligent oral hygiene.

Smoking habits were noted for all patients. In the immediately loaded machined implant group, 3 of 8 patients smoked; 7 of 25 patients in the oxidized group were smokers.

## Discussion

The treatment outcomes for a mandibular overdenture using single-stage surgery and immediate prosthetic loading of a single oxidized-surface implant were excellent. While the study may be of limited duration, it provides sound support for the hypothesis that the single-implant mandibular overdenture can provide improved retention, stability, masticatory performance, and confidence for the maladaptive complete denture wearer.

The three failures encountered in the machined-surface group showed no significant differences in terms of initial implant stability, implant size, bone parameters, age, or medical history to suggest a higher risk for failure. Two of the three patients were smokers. Strietzel et al<sup>23</sup> suggested that the determining effect of smoking appears to be more pronounced when the implant used has a machined surface. However, more research is required in this area.

Of interest in this study are the ISQ values that remained high and even increased despite being above the range of 67 to 70 (considered to be the value that most functioning implants attain).<sup>23</sup> This may be attributed to the higher bone density in the anterior mandible. A small but significant drop in ISQ was recorded at the 3-month recall in the machined group; this was not recorded in the oxidized group. This is in accordance with the studies of Glauser et al,<sup>24-26</sup> who showed a drop in the initial stability of machined implants followed by similar values at the 1-year follow-up. However, oxidized implants maintained their initial stability values. This study showed a similar trend in accordance with Glauser et al. The maintenance of initial stability in oxidized implants may explain their higher success rates in this study.

In general, implant overdentures have a less controlled loading when compared to fixed prostheses.<sup>27</sup> It may be postulated that forces, both axial and lateral, generated by an overdenture on a single implant have the potential to be greater than those produced by a multiple implant-retained overdenture. A recent study by Maeda et al<sup>28</sup> examined the biomechanical rationale of a single implant-retained mandibular overdenture using an in vitro model. The model revealed statistically significantly smaller lateral forces to the ball abutments for single- compared to two-implant overdentures with molar loading. A higher load was observed when the denture was loaded in the midline region. No significant difference in three-dimensional denture base movement was observed between single- and two-implant overdentures in the midline and molar regions. They concluded that overall, the single-implant overdenture had similar biomechanical effects to a two-implant overdenture in terms of lateral forces to the abutment and denture base movements under molar

functional loads. However, the authors did stress the *in vitro* nature of the model and the need for follow-up studies performed in a clinical setting.

The overall oral hygiene compliance for this group of patients was considered acceptable. However, on two occasions patients had calculus formation around the ball attachment that prevented seating of the attachment. The lack of dead space associated with this attachment mechanism and the relining procedure are thought to contribute to the favorable tissue response. Geriatric patients frequently possess impaired manual skills and reduced visual acuity. They are likely to have difficulties following cleaning instructions and may have to rely on care providers for plaque control. While plaque control in this patient cohort was considered acceptable, it may not continue with advancing age. The single ball attachment located in a readily accessible area of the mouth is the simplest available retention device to clean. The overdenture itself can be easily removed and washed by a care provider since it is similar to conventional dentures from a cleaning perspective.

Prosthetic problems were relatively few compared to other studies,<sup>14,29,30</sup> with all attachments functioning well at the 36-month review. Relines were not necessary. Unsplinted implants have been associated with greater problems than splinted implants in some studies,<sup>29,30</sup> and less in others.<sup>11,31</sup> Very few unscheduled maintenance appointments were needed in this study. This may be due in part to implant placement. The traditional position for mandibular overdentures using two implants is for implant placement in the canine region. The resulting implant position is posterior to the incisal edge and has the potential to create bending moments about the implant by acting as a fulcrum. In addition, if the implants are not placed parallel, the off-axis insertion and removal places greater wear and tear on the componentry. This study placed the implant in the most anterior position possible, and the single attachment minimized off-axis considerations.

This study used plastic caps with a vertical spacer and rubber O-rings. The inherent resiliency with this attachment may allow more movement and hence, less strain and potential for wear. A denture with this type of attachment is primarily tissue borne and implant retained. However, the retentive cap used in this study is substantially larger, resulting in a reduced amount of denture base around the attachment (particularly in the frequently encountered narrow labiolingual dimension of the anterior mandible). From a prosthodontic perspective, if the implant is not placed in the ideal position, an unfavorable overbulking of the denture base would result.

Three denture base fractures occurred due to a small labiolingual dimension circumferentially around the retentive cap, subsequent to fixation of the cap with

autopolymerizing acrylic resin. Following the change to a heat-polymerized acrylic resin laboratory-fabricated reline protocol, no fractures occurred up to the 36-month review. No specific reinforcement material was used around the retentive element and a conventional acrylic resin reline material for complete dentures was used. Denture tooth wear was within normal limits for this patient group with the exception of one patient who demonstrated severe wear within a year and again at 36 months, necessitating tooth replacement. The fit, stability, and comfort of the denture bases for this patient were still acceptable, and implant parameters were favorable.

One notable aspect of this study was that no advanced prosthodontic denture construction was required since all dentures had been made previously by the referring clinicians, with the requirement to fulfill the minimal guidelines on denture adequacy.<sup>32</sup> This study aimed to provide significant improvement in mandibular denture function at a low cost. It was therefore important to establish that the procedure had a broad range of applicability within the general dental community, rather than one confined to specialist or university practice. Another aspect of modifying the patient's existing denture was that of attempting to define the treatment impact to be solely originating from placement of the implant. Randomized controlled clinical trials that have compared satisfaction of implant-retained overdentures to conventional dentures have constructed new dentures as a part of the trial.<sup>4,5</sup> Satisfaction scores increased in both the implant and conventional denture groups, albeit to a greater extent in the implant group. By using the patients' existing dentures with which they were already accustomed to functioning, the effect of the implant was tested with fewer confounding variables.

The success criteria used in this study<sup>18</sup> specified no more than 1 mm of marginal bone resorption during the first year of loading and no more than 0.2 mm of resorption per year thereafter. Since this could not be measured quantitatively in all implants, the term "success" could not be applied. However, each implant was tested individually for mobility, adverse symptoms, and peri-implant pathosis, so the implants can be categorized as surviving using these criteria.

Bone levels in the present study were significantly different between the two surfaces, with mean bone loss for the oxidized group less than 1 mm for the entire 36-month recall period and bone resorption at a mean of 0.13 mm per year after the first year of loading. The machined implant, within the very small sample size, showed a mean 2 mm of bone loss in the first year, compared with the oxidized-surface bone loss of 0.63 mm, and 0.1 mm bone resorption per year up to the 36-month recall. It appears that the implant surface

may not have a significant role to play in maintenance of osseointegration with respect to bone levels. However, in the initial healing phases, the oxidized surface shows a distinct advantage.

All patients except one with a machined-surface implant who had an early failure prior to receiving the retentive cap, and hence did not experience any functional improvement, stated that they would have the treatment again if required. This is in agreement with other studies involving implant-retained overdentures and patient satisfaction.<sup>33-35</sup> Quantitatively measured satisfaction levels in this study were significantly improved at the 3-month time period, with this satisfaction maintained up to the 36-month recall. Conversely, a decrease in satisfaction was observed by Timmerman et al.<sup>33</sup> The lack of component problems may account for this difference.

Fitzpatrick,<sup>36</sup> in a 2006 review of the standard of care for the edentulous mandible, stated that it is generally accepted that principles of prosthodontic treatment demand clinicians to pursue the safest, least invasive, least costly, and least complex treatment solution to meet the reasonable needs and expectations of edentulous patients. Mechanical and biologic stability, longevity, and low maintenance for the life of the prosthetic device are required.

The present 36-month prospective study on the immediately functioning single-implant overdenture shows excellent survival rates using an oxidized-surface implant and dramatically improved patient-reported satisfaction levels in patients with a history of prosthetic maladaptation. The hypothesis that two implants are twice as effective as one cannot be answered from this study. However, the satisfaction levels reported by the patients through VAS questionnaires would indicate that a ceiling level of satisfaction is imminent. Further trials randomly comparing two-implant overdentures with single-implant overdentures are therefore appropriate, paying particular attention to patient satisfaction. The results of this study suggest that the single-implant overdenture may be a more conservative and affordable implant treatment option. With more extensive trials and long-term favorable results, the McGill consensus statement<sup>37</sup> may well be challenged.

This report on 36 months of follow-up for the single implant-retained mandibular overdenture using oxidized-surface implants indicates that it is a positive treatment modality, which should make it advantageous for completely edentulous patients with limited resources to benefit from an implant-assisted prosthesis. It may well be considered the entry-level treatment option for rehabilitation of the edentulous mandible in selected patients, especially the underprivileged geriatric groups.

## Conclusion

Within the limitations of this study and its research design, it appears that the immediately loaded single implant-retained mandibular overdenture, using an oxidized-surface implant and the existing prosthesis in a small group of prosthetically maladaptive patients, can provide a beneficial treatment outcome with a minimal financial outlay over a 36-month observation period.

## Acknowledgments

This work was carried out in partial fulfillment of an MScD at the University of Western Australia. Professors John McGeachie and Marc Tennant's encouragement is gratefully acknowledged. Nobel Biocare supplied the implants and their associated prosthetic componentry. The authors wish to thank Dr Estee Kruger for the statistical analysis and the staff at the Brånemark Center, Perth, Australia, and the Oral Health Centre of Western Australia for their support and cooperation.

## References

1. Mojon P. The world without teeth: Demographic trends. In: Feine JS, Carlsson GE (eds). *Implant Overdentures: The Standard of Care for Edentulous Patients*. Chicago: Quintessence, 2003:3-14.
2. MacEntee MI. The impact of edentulism on function and quality of life. In: Feine JS, Carlsson GE (eds). *Implant Overdentures: The Standard of Care for Edentulous Patients*. Chicago: Quintessence, 2003:23-28.
3. Locker D. Patient-based assessment of the outcomes of implant therapy: A review of the literature. *Int J Prosthodont* 1998;11:453-461.
4. Awad MA, Lund JP, Dufresne E, Feine JS. Comparing the efficacy of mandibular implant-retained overdentures and conventional dentures among middle-aged edentulous patients: Satisfaction and functional assessment. *Int J Prosthodont* 2003;16:117-122.
5. Awad MA, Lund JP, Shapiro SH, et al. Oral health status and treatment satisfaction with mandibular implant overdentures and conventional dentures: A randomized clinical trial in a senior population. *Int J Prosthodont* 2003;16:390-396.
6. Geertman ME, Boerrigter EM, Van't Hof MA, et al. Two-center clinical trial of implant-retained mandibular overdentures versus complete dentures-chewing ability. *Community Dent Oral Epidemiol* 1996;24:79-84.
7. Geertman ME, van Waas MA, van't Hof MA, Kalk W. Denture satisfaction in a comparative study of implant-retained mandibular overdentures: A randomized clinical trial. *Int J Oral Maxillofac Implants* 1996;11:194-200.
8. Feine JS, Heydecke G. Implant overdentures versus conventional dentures. In: Feine JS, Carlsson GE (eds). *Implant Overdentures: The Standard of Care for Edentulous Patients*. Chicago: Quintessence, 2003:37-46.
9. Engquist B, Bergendal T, Kallus, T, Linden U. A retrospective multicenter evaluation of osseointegrated implants supporting overdentures. *Int J Oral Maxillofac Implants* 1988;3:129-134.
10. Johns RB, Jemt T, Heath MR, et al. A multicenter study of overdentures supported by Brånemark implants. *Int J Oral Maxillofac Implants* 1992;7:513-522.
11. Bergendal T, Engquist B. Implant-supported overdentures: A longitudinal prospective study. *Int J Oral Maxillofac Implants* 1998;13:253-262.

12. Attard NJ, Zarb GA. Long-term treatment outcomes in edentulous patients with implant overdentures: The Toronto study. *Int J Prosthodont* 2004;17:425-433.
13. Meijer HJ, Raghoobar GM, Van't Hof MA. Comparison of implant-retained mandibular overdentures and conventional complete dentures: A 10-year prospective study of clinical aspects and patient satisfaction. *Int J Oral Maxillofac Implants* 2003;18:879-885.
14. Payne AG, Solomons YF. The prosthodontic maintenance requirements of mandibular mucosa- and implant-supported overdentures: A review of the literature. *Int J Prosthodont* 2000;13:238-243.
15. Cordioli G, Majzoub Z, Castagna S. Mandibular overdentures anchored to single implants: A five-year prospective study. *J Prosthet Dent* 1997;78:159-165.
16. Krennmair G, Ulm C. The symphyseal single-tooth implant for anchorage of a mandibular complete denture in geriatric patients: A clinical report. *Int J Oral Maxillofac Implants* 2001;16:98-104.
17. Liddel GJ, Henry PJ. A prospective study of immediately loaded single implant-retained mandibular overdentures: Preliminary one-year results. *J Prosthet Dent* 2007;97(suppl):S126-S137 [erratum 2008;99:167].
18. Roos J, Sennerby L, Lekholm U, Jemt T, Gröndahl K, Albrektsson T. A qualitative and quantitative method for evaluating implant success: A 5-year retrospective analysis of the Brånemark implant. *Int J Oral Maxillofac Implants* 1997;12:504-514.
19. Feine JS, de Grandmont P, Boudrias P, et al. Within-subject comparisons of implant-supported mandibular prostheses: Choice of prosthesis. *J Dent Res* 1994;73:1105-1111.
20. De Grandmont P, Feine JS, Taché R, et al. Within-subject comparisons of implant-supported mandibular prostheses: Psychometric evaluation. *J Dent Res* 1994;73:1096-1104.
21. Lekholm U, Zarb GA. Patient selection and preparation. In: Brånemark P-I, Zarb GA, Albrektsson T (eds). *Tissue Integrated Prosthesis: Osseointegration in Clinical Dentistry*. Chicago: Quintessence, 1985:199-209.
22. Albrektsson T, Zarb GA, Worthington P, Eriksson AR. The long-term efficacy of currently used dental implants: A review and proposed criteria of success. *Int J Oral Maxillofac Implants* 1986;1:11-25.
23. Strietzel FP, Reichart PA, Kale A, Kulkarni M, Wegner B, Küchler I. Smoking interferes with the prognosis of dental implant treatment: A systematic review and meta-analysis. *J Clin Periodontol* 2007;34:523-544.
24. Glauser R, Portmann M, Ruhstaller P, Lundgren AK, Hammerle C, Gottlow J. Stability measurements of immediately loaded machined and oxidized implants in the posterior maxilla. A comparative clinical study using resonance frequency analysis. *Appl Osseointegration Res* 2001;2:27-29.
25. Glauser R, Lundgren AK, Gottlow J, et al. Immediate occlusal loading of Brånemark TiUnite implants placed predominantly in soft bone: 1-year results of a prospective clinical study. *Clin Implant Dent Relat Res* 2003;5(suppl 1):47-56.
26. Glauser R, Sennerby L, Meredith N, et al. Resonance frequency analysis of implants subjected to immediate or early functional occlusal loading. Successful vs. failing implants. *Clin Oral Implants Res* 2004;15:428-434.
27. Brånemark P-I. Possibilities and limitations in the clinical aspect of osseointegration. In: Schepers E (ed). *Overdentures on Oral Implants. Proceedings of the Symposium on Implant Supported Overdentures (EOTC)*. Leuven: University Press, 1991:11-13.
28. Maeda Y, Horisaka M, Yagi K. Biomechanical rationale for a single implant-retained mandibular overdenture: An in vitro study. *Clin Oral Implants Res* 2008;19:271-275.
29. Mericske-Stern R. Clinical evaluation of overdenture restorations supported by osseointegrated titanium implants: A retrospective study. *Int J Oral Maxillofac Implants* 1990;5:375-383.
30. Walton JN, MacEntee MI, Glick N. One-year prosthetic outcomes with implant overdentures: A randomized clinical trial. *Int J Oral Maxillofac Implants* 2002;17:391-398.
31. Gotfredsen K, Holm B. Implant-supported mandibular overdentures retained with ball or bar attachments: A randomized prospective 5-year study. *Int J Prosthodont* 2000;13:125-130.
32. California Dental Association. *Quality Evaluation for Dental Care: Guidelines for the Assessment of Clinical Quality and Professional Performance*. Los Angeles: The California Dental Association, 1997.
33. Timmerman R, Stoker GT, Wismeijer D, Oosterveld P, Vermeeren JI, van Waas MA. An eight-year follow-up to a randomized clinical trial of participant satisfaction with three types of mandibular implant-retained overdentures. *J Dent Res* 2004;83:630-633.
34. Naert I, Gizani S, Vuylsteke M, van Steenberghe D. A 5-year randomized clinical trial on the influence of splinted and unsplinted oral implants in the mandibular overdenture therapy. Part I: Peri-implant outcome. *Clin Oral Implants Res* 1998;9:170-177.
35. Naert I, Gizani S, Vuylsteke M, van Steenberghe D. A 5-year prospective randomized clinical trial on the influence of splinted and unsplinted oral implants in the mandibular overdenture therapy. Prosthetic aspects and patient satisfaction. *J Oral Rehabil* 1999;26:195-202.
36. Fitzpatrick B. Standard of care for the edentulous mandible: A systematic review. *J Prosthet Dent* 2006;95:71-78.
37. Feine JS, Carlsson GE, Awad MA, et al. The McGill consensus statement on overdentures. Mandibular two-implant overdentures as first choice standard of care for edentulous patients. Montreal, Quebec, May 24-25, 2002. *Int J Oral Maxillofac Implants* 2002;17:601-602.

Copyright of International Journal of Prosthodontics is the property of Quintessence Publishing Company Inc. and its content may not be copied or emailed to multiple sites or posted to a listserv without the copyright holder's express written permission. However, users may print, download, or email articles for individual use.