

# Retrospective Clinical Study of Single-Retainer Cantilever Anterior and Posterior Glass-Ceramic Resin-Bonded Fixed Dental Prostheses at a Mean Follow-up of 6 Years

Irena Sailer, PD Dr Med Dent<sup>a</sup>/Tom Bonani, Dr Med Dent<sup>b</sup>/Urs Brodbeck, Dr Med Dent<sup>c</sup>/  
Christoph Hans Franz Hämmerle, Prof Dr Med Dent<sup>d</sup>

**Purpose:** To retrospectively evaluate the 6-year survival rates and technical/biologic complication rates of single-retainer glass-ceramic resin-bonded fixed dental prostheses (RBFDPs). **Materials and Methods:** Forty patients with 49 anterior/posterior glass-ceramic RBFDPs were included. The RBFDPs replaced 11 maxillary/mandibular central incisors, 18 lateral incisors, 18 premolars, and 2 molars. Patients willing to participate were clinically and radiologically examined. The technical outcome was assessed with modified United States Public Health Service criteria. Fracture and/or chipping of the restoration, occlusal wear, marginal adaptation, marginal discoloration, shape, surface texture, and esthetic integration were recorded. Tooth vitality and postoperative sensitivity were tested. The following biologic parameters were assessed at test and control teeth: probing pocket depth, gingival recession, attachment loss, bleeding on probing, furcation involvement, and periodontal mobility. Statistical analysis was performed with exact 95% confidence intervals to relative frequencies and the paired *t* test. **Results:** Twenty-eight patients with 35 RBFDPs participated. The mean follow-up of the RBFDPs was 6 years. Twelve patients with 14 RBFDPs were not willing to participate or not available. No catastrophic failures occurred. The 6-year survival rate of the examined RBFDPs was 100%. No debonding was recorded. Chipping of the ceramic was found in 5.7% of the RBFDPs. Biologic outcomes were similar at test and control teeth. **Conclusion:** Glass-ceramic RBFDPs exhibited promising clinical outcomes in both anterior and posterior regions. *Int J Prosthodont* 2013;26:443–450. doi: 10.11607/ijp.3368

The approach to replace single missing maxillary or mandibular teeth with resin-bonded fixed dental prostheses (RBFDPs) dates back to the 1970s.<sup>1,2</sup> The main indications of the RBFDPs were splinting of periodontally compromised anterior teeth or replacement of missing teeth.<sup>1,2</sup> RBFDPs have several advantages over other treatment options. The main advantage of RBFDPs is the low invasiveness

compared to conventional FDPs, as no or only little abutment tooth preparation is needed. In a recent laboratory study, Edelhoff and Sorensen showed that 25% to 50% less tooth substance is removed for an RBFDP compared with a conventional complete-coverage metal-ceramic reconstruction.<sup>3,4</sup> Furthermore, this treatment option caused less patient morbidity. By means of RBFDPs, surgical interventions for the replacement of single teeth such as implants can be avoided. Finally, the treatment costs associated with RBFDPs are considerably lower than for conventional FDPs or single-tooth implants.<sup>5</sup>

As reported in the literature, the main problem associated with RBFDPs was debonding. In a systematic review by Pjetursson et al,<sup>6</sup> RBFDPs showed a 19.2% cumulative rate of debonding during 5 years of observation. The debonding most frequently occurred at metal-ceramic RBFDPs fabricated with perforated cast metal frameworks.<sup>6</sup> The use of nonperforated cast metal frameworks improved the poor performance of the RBFDP.<sup>6</sup> Still, the adhesive cementation of metal-ceramic RBFDPs remains a challenge.

<sup>a</sup>Chairwoman, Division of Fixed Prosthodontics and Occlusion, University of Geneva; Formerly Associate Professor, Clinic of Fixed and Removable Prosthodontics and Dental Material Science, University of Zürich, Switzerland.

<sup>b</sup>Private Practice, Konstanz, Germany.

<sup>c</sup>Private Practice, Zürich, Switzerland.

<sup>d</sup>Professor and Chair, Clinic of Fixed and Removable Prosthodontics and Dental Material Science, Center of Dental Medicine, University of Zürich, Zürich, Switzerland.

**Correspondence to:** Dr Irena Sailer, Division of Fixed Prosthodontics and Occlusion, School of Dental Medicine, University of Geneva, 19 rue Barthelémy-Menn, CH-1205 Geneva, Switzerland. Fax: +41 (0)22 379 40 52. Email: irena.sailer@unige.ch

©2013 by Quintessence Publishing Co Inc.

After the advancement of ceramic materials, the first all-ceramic RBFDPs were made in the early 1990s.<sup>7</sup> One of the benefits of ceramic is that the adhesive cementation of this material is well established and predictable.<sup>8</sup> The first ceramic RBFDPs exhibited very promising clinical survival rates of 92.3% at 5 years.<sup>9</sup> Debonding was seldom a complication for all-ceramic FDPs,<sup>9</sup> yet, due to their brittleness, all-ceramic RBFDPs exhibited a high risk for fracture compared with conventional metal-ceramic RBFDPs.<sup>9</sup> It has been shown that clinical stability could be improved by changing the design of the reconstructions from two-retainer to single-retainer cantilever RBFDPs.<sup>9</sup> A clinical study showed that all-ceramic anterior RBFDPs exhibited significantly better survival rates when they were designed as cantilever RBFDPs.<sup>9</sup> Nevertheless, due to the specific material properties of ceramics, the all-ceramic RBFDPs might only be appropriate for the replacement of missing anterior teeth.

Today, little information is available on the outcomes of anterior all-ceramic RBFDPs, and no data are available on posterior all-ceramic RBFDPs. Furthermore, data on glass-ceramic RBFDPs generally are lacking in the literature.

Therefore, the purpose of this retrospective clinical study was to assess the 5-year survival rates and technical and biologic complication rates of single-retainer cantilever glass-ceramic RBFDPs replacing single anterior and posterior teeth.

## Materials and Methods

### *Patients and Reconstructions*

The patients included in this study were part of a group of 40 patients (24 women, 16 men) treated with at least one glass-ceramic RBFDP in the anterior or posterior region of the maxilla or mandible. The RBFDPs were made out of one of two glass-ceramics (Empress, e.max Press, Ivoclar Vivadent). All patients were treated in one private practice from 1994 to 2006. The age of the patients ranged from 10 to 61 years.

The inclusion criteria for the RBFDPs were:

- single tooth gap in anterior (incisor) and/or posterior (premolar, molar) regions
- patient's desire for minimally invasive treatment
- patient's desire for all-ceramic tooth-borne reconstruction
- periodontally healthy neighboring teeth
- interocclusal space adequate for the retainer in horizontal and vertical dimensions

- presence of an abutment tooth distally of the gap in posterior regions
- no obvious signs of bruxism

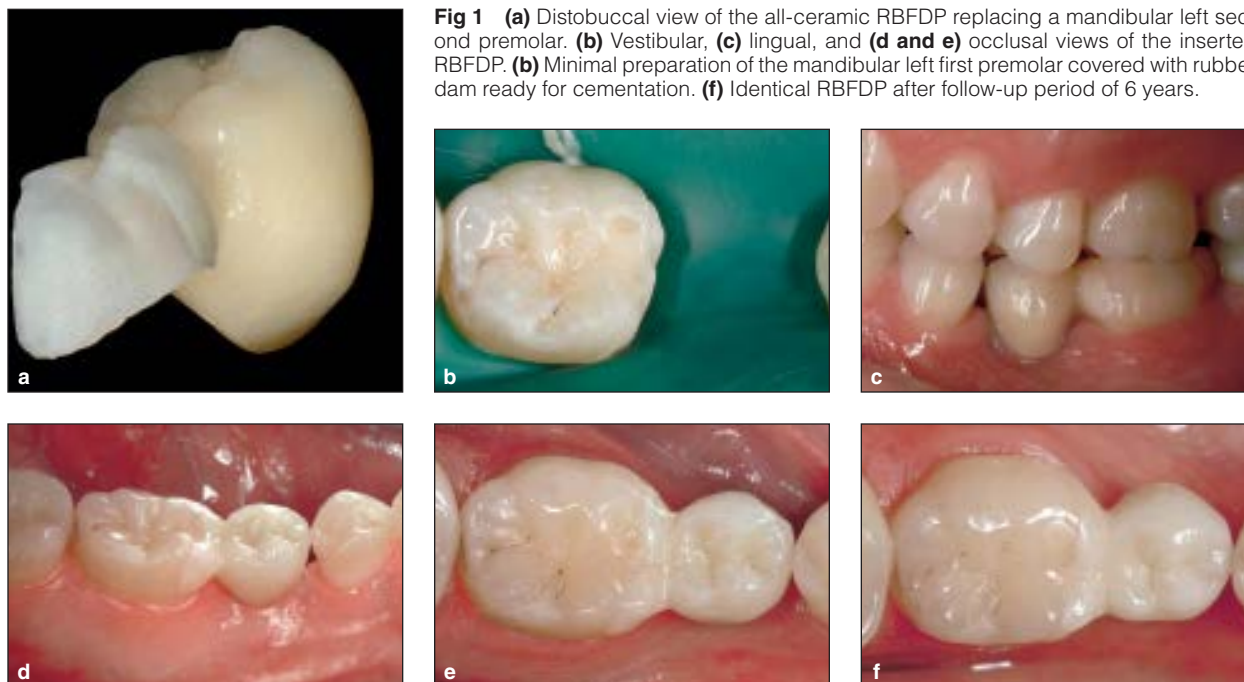
Prior to the fabrication of the RBFDPs, patients were thoroughly informed about the clinical procedures, the advantages and limitations of all-ceramic RBFDPs, and the present insufficiency of scientific evidence. Furthermore, treatment alternatives (conventional FDPs, single-tooth implants) were discussed with the patients.

The 40 patients interested in the RBFDPs provided informed consent and were treated with 49 cantilever single-retainer glass-ceramic RBFDPs. The RBFDPs replaced central incisors, lateral incisors, premolars (Fig 1), and two molars.

### *Prosthodontic Procedures*

All patients were subjected to dental hygienic pre-treatment prior to the restorative treatment phase. In the anterior region, the choice of abutment tooth was made after judging the amount of space in horizontal and vertical dimensions during centric occlusion and function. No preparation of the anterior abutment teeth was performed. In the posterior region, the tooth distal to the gap was chosen as the abutment tooth. Minimal inlay tooth preparation was performed following the shape and size of pre-existing cavities. Impressions were taken with a polyether impression material (Permadyne, 3M ESPE). No provisional reconstruction was needed in the anterior region. In the posterior regions, cavities were filled with a provisional composite (Fermit, Ivoclar Vivadent).

The impressions were poured with Class IV stone (GC Fujirock EP, GC) in the dental laboratory, and full anatomical wax casts (Schuler Dental) of the desired RBFDP were manually made. The wax casts were embedded (IPS PressVest, IPS PressVest Speed, Ivoclar Vivadent) and subjected to burn out for the pressing procedure. Finally, the RBFDP was pressed out of one of the two glass-ceramics using the lost-wax technique. The framework dimensions were adjusted to the manufacturer's recommendations for the glass-ceramics. The minimal dimensions of the connector for framework retainers were 16 mm<sup>2</sup> for the anterior region and 20 mm<sup>2</sup> for the posterior region. In anterior regions, the RBFDPs were veneered (IPS e.max Ceram for e.max, Empress Esthetic Veneer Materials for Empress, Ivoclar Vivadent). In posterior regions, the RBFDPs were adjusted to the color of the neighboring teeth with the corresponding ceramic colors (IPS Empress Universal Shades and Stains, Ivoclar Vivadent).



**Fig 1** (a) Distobuccal view of the all-ceramic RBFDP replacing a mandibular left second premolar. (b) Vestibular, (c) lingual, and (d and e) occlusal views of the inserted RBFDP. (b) Minimal preparation of the mandibular left first premolar covered with rubber dam ready for cementation. (f) Identical RBFDP after follow-up period of 6 years.

Forty-six RBFDPs (93.9%) were made of a lithium disilicate-reinforced glass-ceramic (IPS e.max Press, Ivoclar Vivadent) and 3 (6.1%) of a leucite-reinforced glass-ceramic (IPS Empress, Ivoclar Vivadent). One dental laboratory fabricated the RBFDPs.

All FDPs were adhesively bonded to the abutment teeth using one of the following resin cements: Tetric Flow (Ivoclar Vivadent) was used as a luting agent for 33 (67.3%) restorations, Tetric Ceram (Ivoclar Vivadent) for 7 (14.3%), Rely-X (3M ESPE) for 4 (8.2%), Panavia F (KURARAY) for 3 (6.1%), HFO (Optident) for 1 (2.0%), and Variolink (Ivoclar Vivadent) for 1 (2.0%). Prior to cementation, the RBFDPs were etched with hydrofluoric acid (Porcelain Etch Gel, Pulpdent) and silanized (Monobond, Ivoclar Vivadent).

Furthermore, abutment teeth were acid etched (Total Etch, 37% phosphoric acid, Ivoclar Vivadent) and subsequently pretreated with the bonding agents (Syntac, Ivoclar Vivadent) corresponding to the respective cements according to manufacturers' instructions.<sup>10,11</sup>

After the insertion of the RBFDPs, the patients were recalled based on their individual needs. Patients with high activity for caries were recalled twice a year. Patients with a low risk for caries and/or good oral hygiene were recalled once a year.

### **Clinical Follow-up Examination**

The RBFDPs were examined for technical and biologic outcomes (failures or complications). The technical outcome of the reconstructions was examined using modified United States Public Health Services (USPHS) criteria (Table 1).<sup>12</sup> An outcome was rated "A" when no problems were found, "B" when small but clinically acceptable defects were found, "C" when the defects reached a level that was no longer clinically acceptable, and "D" when the RBFDP had to be replaced due to the defect (Table 1). The biologic outcome was analyzed at test (abutment) and control teeth (analogous, contralateral, not crowned) by determining probing pocket depth (PPD), gingival recession (MG), attachment loss (AL), bleeding on probing (BOP), furcation involvement (according to Rateitschak et al<sup>13</sup>), and periodontal mobility (according to Flemming<sup>14</sup>). Finally, radiographs and clinical photographs of the abutment teeth were taken. One investigating clinician performed all follow-up examinations using magnification loupes with  $\times 2.5$  magnification (TP 710, SandyGrendel, SwissLoups).<sup>15</sup>

**Table 1** Overview of the Tested Parameters of the USPHS Assessment

Parameter	Rating			
	A	B	C	D
Fracture	No fracture of the restoration			Fracture of the restoration
Chipping of ceramic	No chipping	Chipping, but polishing possible	Chipping, no polishing possible	New reconstruction is needed
Quality of reconstruction/tooth interface	Probe did not catch	Probe did catch, no gap, exposed enamel is polishable	Probe did catch, with gap, exposed cement is not polishable	New reconstruction is needed
Marginal adaptation	No cement joint	Cement joint > 50 µm without degradation	Cement joint > 50 µm with degradation	New reconstruction is needed
Marginal discoloration	No marginal discoloration	Slight discoloration visible, but polishable	Distinct discoloration visible, not polishable	New reconstruction is needed
The configuration of the contour	Correct contour, tight proximal contacts	Slightly under- or overcontoured, weak proximal contacts	Distinctly under- or overcontoured, no proximal contacts	New reconstruction is needed
Occlusion	Perfect occlusion and articulation	Minimal deviation in occlusion and articulation, correction achieved by grinding	Distinct deviation in occlusion and articulation, transversal and sagittal slide > 1 mm	New reconstruction is needed
Occlusal wear	No wear facets on restoration and opposing teeth	Small wear facets (diameter < 2 mm) on restoration and/or opposing teeth	Large wear facets (diameter > 2 mm) on restoration and/or opposing teeth	New reconstruction is needed
Surface texture	Smooth, glazed, or glossy surface	Slightly rough, dull surface, polishable	Deep pores, rough, unevenly distributed pits, not polishable	New reconstruction is needed
Color	Perfect match of color	Minimal mismatch in shade	Distinct difference in shade	New reconstruction is needed
Assessment of tooth vitality	Distinct positive feedback on the tooth vitality or negative feedback with endodontically treated teeth	Delayed reaction	Negative feedback but not with endodontically treated teeth	New reconstruction is needed
Postoperative sensitivity	No restrictions in postoperative sensitivity	Minimal restrictions in postoperative sensitivity	Distinct restrictions in postoperative sensitivity, the patient wants a new reconstruction	New reconstruction is needed

## Statistical Analysis

Descriptive statistics were applied to the data. The 5-year survival rate of RBFDPs was computed by dividing the number of RBFDPs without any fractures by the total number of clinically examined RBFDPs. Failure and complication rates were calculated by dividing the number of observed events (failures or complications) by the total number of analyzed RBFDPs. The exact 95% confidence intervals (CIs) for relative frequencies were obtained. For the comparison of PPD, MG, AL, and BOP between test and control teeth, the paired *t* test was used. Data were analyzed by SPSS version 17.0 (SPSS, IBM). The level of statistical significance was set at  $\alpha = .05$ .

## Results

Twenty-eight patients with 35 RBFDPs were examined. The mean clinical service time of the RBFDPs was 6 years (range: 0.31 to 13.5 years, median: 5.96 years). Twelve patients with 14 RBFDPs (replacing 1 maxillary central incisor, 5 maxillary lateral incisors, 1 mandibular central incisor, 2 mandibular lateral incisors, 2 maxillary premolars, 2 mandibular premolars, and 1 molar) did not participate in the follow-up examination for different reasons. One patient had passed away, 1 had emigrated, and 8 did not wish to participate. Furthermore, in 1 patient the RBFDP had been removed and replaced with an implant. The patient reported that this treatment was performed on

his wishes and that the RBFDP had no complications before the removal. In another patient, one RBFDP was lost because the abutment tooth had to be extracted for periodontal reasons.

No catastrophic fracture of a clinically examined glass-ceramic RBFDP occurred. Furthermore, none of the RBFDPs had to be removed due to technical or biologic complications (95% CI: 0.00%, 10.00%). The examined RBFDP, therefore, had a 5-year survival rate of 100% (95% CI: 90%, 100%).

### Technical Outcomes

No debonding of an RBFDP was found. Minor technical complications encompassed chipping of the ceramic (found in two RBFDPs). In the first patient, the chipping occurred at an anterior RBFDP replacing a lateral incisor. The chipping had occurred at the incisal edge of the pontic and was observed after 5.4 years of service. This problem was unnoticed by the patient. The second chipping was found at a posterior RBFDP of another patient after 5.7 years of service. This fixed partial denture replaced a premolar and was fixed to the adjacent first molar. The chipping had occurred at the distolingual cusp of the pontic and, again, had not been noticed by the patient before the recall visit.

The rate for chipping of the ceramic, therefore, was 5.7% (95% CI: 0.70%, 19.2%). In both cases, the rough surfaces were meticulously polished.

Minor occlusal wear of the ceramic (B rating) was found in 74.3% (95% CI: 59.9%, 89.6%) of the reconstructions. Occlusal wear rated C was found in 5.7% (95% CI: 0.7%, 19.2%).

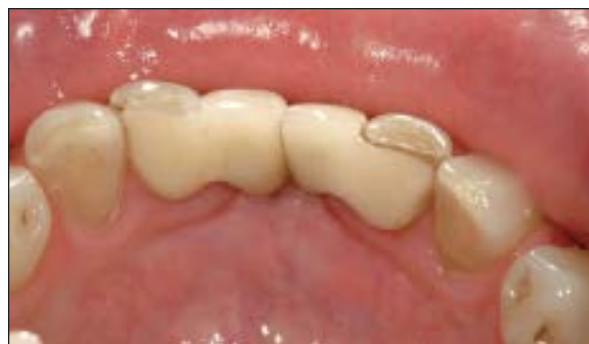Most of the reconstructions showed a fair marginal adaptation with slightly visible but polishable marginal discoloration. Clinically acceptable marginal gaps (B rating) were found in 68.6% (95% CI: 50.7%, 83.2%) of the RBFDPs. In 2.9% (95% CI: 0.1%, 14.9%) of the RBFDPs, the margins were discolored (Fig 2).

The proximal contacts were tight, and in cases of minimal deviation from the ideal occlusion and articulation, a correction was achieved by grinding. A slightly rough surface with a minimal mismatch in shade was also often found.

The detailed information on the technical outcomes of the RBFDPs is given in Table 2. The location of the technical complications is given in Table 3.

### Biologic Outcomes

In general, no differences in biologic outcomes were found when test and control teeth were compared. All abutment teeth showed a distinct positive feedback



**Fig 2** Lingual view of two all-ceramic RBFDPs replacing mandibular left and right central incisors. Distinct marginal discoloration is visible at the abutment tooth. The follow-up period of the RBFDPs was 6.9 years.

on the tooth vitality. No restrictions in postoperative sensitivity were recorded. Detailed information on the biologic outcomes of the evaluated RBFDPs is given in Table 4.

The mean PPD (mPPD) of the abutment teeth was 2.4 mm (range: 1.33 to 3.88); the mPPD of the control teeth was 2.3 mm (range: 1.5 to 3.83). Mean gingival recession of 0.6 mm was found at both the abutment and control teeth. A mean loss of attachment (mAL) of 2.5 mm (range: 1.25 to 4.25) was found at the abutment teeth. The respective mAL of the control teeth was 2.4 mm (range: 1.25 to 3.88). Finally, the same amount of mBOP was found at the test and control teeth.

No posterior abutment tooth exhibited a furcation involvement bigger than grade I (not more than 3 mm in a horizontal direction, according to Rateitschak et al<sup>13</sup>). No abutment tooth mobility exceeding grade I was found at the test teeth (according to Flemming<sup>14</sup>).

## Discussion

The anterior and posterior glass-ceramic cantilever RBFDPs exhibited very good survival rates and low complication rates in the present retrospective study. Only minor technical complications such as polishable chipping of the ceramic or marginal discoloration were found. Furthermore, the RBFDPs also exhibited excellent biologic integration. No difference in the biologic outcomes of the abutment teeth were found compared with untreated control teeth.

Different survival rates of RBFDPs have been reported in the literature, indicating that the outcome of this kind of reconstruction is influenced by many clinical and technical factors. The main factor

**Table 2** USPHS Rating of the Respective Parameters Found at the RBFDPs (n = 35)

Parameter	Rating			
	A (%)	B (%)	C (%)	D (%)
Fracture	100.0 (90.0, 100.0)	*	*	*
Chipping of ceramic	94.3 (80.4, 99.3)	5.7 (0.7, 19.2)	*	*
Quality of reconstruction/tooth interface	31.4 (16.9, 49.3)	68.6 (50.7, 83.2)	*	*
Marginal adaptation	20.0 (8.4, 36.9)	77.1 (59.9, 89.6)	2.9 (0.1, 14.9)	*
Marginal discoloration	8.6 (1.8, 23.1)	88.6 (73.3, 96.8)	2.9 (0.1, 14.9)	*
The configuration of the contour	85.7 (69.7, 95.2)	14.3 (4.8, 30.3)	*	*
Occlusion	57.1 (39.4, 73.7)	42.9 (26.3, 60.7)	*	*
Occlusal wear	20.0 (8.4, 36.9)	74.3 (56.7, 87.5)	5.7 (0.7, 19.2)	*
Surface texture	20.0 (8.4, 36.9)	80.0 (63.1, 91.6)	*	*
Color	25.7 (12.5, 43.3)	68.6 (50.7, 83.2)	5.7 (0.7, 19.2)	*
Assessment of tooth vitality	91.4 (76.9, 98.2)	8.6 (1.8, 23.1)	*	*
Postoperative sensitivity	100.0 (90.0, 100.0)	*	*	*

\*0% (0.0, 10.0).†

†Percent of events (95% CI for the true relative frequencies).

**Table 3** No. and Location of Technical Complications\* (n = 35)

	Total (B/C)	Maxilla		Mandible	
		Anterior	Posterior	Anterior	Posterior
Chipping of ceramic	2 (2/0)	1 (1/0)			1 (1/0)
Marginal adaptation	28 (27/1)	4 (4/0)	7 (7/0)	11 (10/1)	6 (6/0)
Marginal discoloration	32 (31/1)	5 (5/0)	7 (7/0)	12 (12/0)	8 (7/1)
Occlusal wear	28 (26/2)	3 (3/0)	6 (4/2)	12 (12/0)	7 (7/0)

\*The total number of complications includes all problems rated B or C (USPHS criteria). The individual number of problems rated B or C is given in parentheses for each location.

**Table 4** Biologic Outcomes of the Tested RBFDPs (n = 35)

	Abutment tooth		Reference tooth		P
	Mean ± SD	95% CI	Mean ± SD	95% CI	
PPD	2.4 ± 0.5	2.2, 2.5	2.3 ± 0.5	2.1, 2.4	.455
MG	-0.6 ± 0.6	-0.8, -0.4	-0.6 ± 0.6	-0.8, -0.3	.705
AL	2.5 ± 0.9	2.2, 2.8	2.4 ± 0.8	2.1, 2.7	.288
BOP	0.2 ± 0.2	0.13, 0.26	0.2 ± 0.2	0.17, 0.31	.259

PPD = pocket probing depth in mm; MG = gingival recession in mm; AL = attachment level in mm; BOP = bleeding on probing (absent, 0 or present, 1).

influencing the outcomes of both all-ceramic and metal-ceramic RBFDPs was the design of the RBFDP with respect to the number of retainers, ie, one retainer (cantilever) vs two or more. Both all-ceramic and metal-ceramic RBFDPs exhibited better outcomes

when they were designed as one-retainer cantilever fixed partial dentures. One study of metal-ceramic cantilever RBFDPs showed an overall success rate of 94% after a mean observation time of 36.2 months.<sup>16</sup> Another study showed a 100% survival rate of

metal-ceramic cantilever RBFDPs after a mean observation time of 35 months.<sup>17</sup> A third investigation of metal-ceramic cantilever RBFDPs showed a success rate of 94.8% after a mean follow-up of 51.7 years.<sup>18</sup> In comparison, one long-term study on anterior ceramic cantilever RBFDPs reported a 10-year survival rate of 94.4%. The same study also showed that the ceramic RBFDPs exhibited lower survival rates when they were cemented to two adjacent abutment teeth (two-retainer design).<sup>19</sup>

A systematic review of the overall literature, however, estimated a rather low survival rate of RBFDPs of 87.7%.<sup>6</sup> The review indicated that the survival rates of anterior RBFDPs exceeded the rates for posterior RBFDPs. However, this review predominantly included literature on metal-ceramic RBFDPs.<sup>6</sup> Studies reporting on all-ceramic RBFDPs in anterior and/or posterior regions are scarce. The survival rates of the all-ceramic cantilever RBFDPs in the present study were very promising in both anterior and posterior regions. It has to be considered, though, that this study was retrospective. Only a few of the initially treated patients were clinically examined, which limits the interpretation of the results. Therefore, randomized controlled clinical studies are needed to further analyze the present observations of all-ceramic cantilever RBFDPs.

A number of studies showed that the longevity of RBFDPs was influenced by clinical and technical factors such as the design of the abutment tooth preparation, the type of cement used for fixation, and the surface pretreatment of the tooth and reconstruction.<sup>20,21</sup> In addition, the type of material for the RBFDP, eg, the type of casting alloy or ceramic, appears to be an important factor.<sup>20</sup>

The technical outcomes found in the present retrospective study are in accordance with the results of other studies. Catastrophic fracture of a ceramic RBFDP did not occur in the present study. In another study on ceramic RBFDPs, the number of fractures for the all-ceramic RBFDPs also was rather low.<sup>22</sup> One further study reported a 7.7% fracture rate of the RBFDPs.<sup>9</sup> Debonding was the main technical complication occurring in the studies on RBFDPs,<sup>6</sup> but this complication did not occur in the present study. Furthermore, the rates for chipping of the veneering ceramic and marginal deficiency were low in the present study.

The replacement of canines with all-ceramic RBFDPs may be critical with respect to the longevity due to the type of load that occurs in this region. During the occlusal/lateral movements of the arches, high tensile load is induced to the retainer and/or the connector area of the RBFDP.<sup>23,24</sup> This may lead to

increased risk for fracture of the RBFDP during canine guidance. Studies on all-ceramic RBFDPs replacing canines are therefore needed.

Hence, in case of single-tooth gaps in the anterior and possibly also in the posterior region, the question of whether an implant or an RBFDP is indicated should be further elucidated.

An RBFDP may be a valid alternative in situations where implant treatment is not medically indicated. Absolute contraindications for implantations are, eg, immune-suppression, active treatment of malignancy, drug abuse, or psychiatric illness.<sup>25</sup> Furthermore, various "relative" contraindications such as diabetes or cardiovascular diseases were reported.<sup>26</sup> Finally, in cases of lack of interproximal space for an implant, an all-ceramic RBFDP may be a good alternative. One example is a crowded mandibular anterior dentition. Another indication for RBFDPs are young patients with congenitally missing teeth who have not completed their facial growth. In that case, the RBFDP may be an acceptable temporary solution. After completed facial growth, the cantilever can be easily removed and replaced by an implant if desired. A recently presented study showed that single-implant restorations in the anterior maxilla may present small degrees of infraposition over the long term due to the ankylosis of the implant and the continuously slow growth of the arches.<sup>27</sup>

The main challenge in carrying out long-term studies is the compliance of patients in participating in follow-up examinations. In the present retrospective study, 70% of the initially treated patients participated. Therefore, conclusions have to be drawn with caution.

Today, all-ceramic RBFDPs are judged as semi-final reconstructions since very few studies reporting their outcomes are available. To further elucidate the indications, limitations, and long-term outcomes of the RBFDPs, randomized controlled clinical studies are needed in the future.

## Conclusion

The anterior and posterior glass-ceramic RBFDPs exhibited very promising clinical outcomes at 5 years of follow-up. This treatment, therefore, might be a good alternative to single-implant crowns in the future. However, specifically in the canine and posterior region, data supporting the present results are lacking. For this reason, the present outcomes should be judged with caution. Before RBFDPs can be recommended as a final treatment option, studies using a randomized prospective controlled design are definitely needed.

## Acknowledgments

The authors thank biostatistician Dr Malgorzata Roos and study monitor Mrs Gisela Müller for their support with the statistical data analysis and manuscript preparation. The authors reported no conflicts of interest related to this study.

## References

- Rochette AL. Attachment of a splint to enamel of lower anterior teeth. *J Prosthet Dent* 1973;30:418–423.
- Howe DF, Denehy GE. Anterior fixed partial dentures utilizing the acid-etch technique and a cast metal framework. *J Prosthet Dent* 1977;37:28–31.
- Edelhoff D, Sorensen JA. Tooth structure removal associated with various preparation designs for posterior teeth. *Int J Periodontics Restorative Dent* 2002;22:241–249.
- Edelhoff D, Sorensen JA. Tooth structure removal associated with various preparation designs for anterior teeth. *J Prosthet Dent* 2002;87:503–509.
- Bragger U, Krenander P, Lang NP. Economic aspects of single-tooth replacement. *Clin Oral Implants Res* 2005;16:335–341.
- Pjetursson BE, Tan WC, Tan K, Bragger U, Zwahlen M, Lang NP. A systematic review of the survival and complication rates of resin-bonded bridges after an observation period of at least 5 years. *Clin Oral Implants Res* 2008;19:131–141.
- Kern M, Knode H, Strubb JR. The all-porcelain, resin-bonded bridge. *Quintessence Int* 1991;22:257–262.
- Blatz MB. Adhesive cementation of high-strength ceramics. *J Esthet Restor Dent* 2007;19:238–239.
- Kern M. Clinical long-term survival of two-retainer and single-retainer all-ceramic resin-bonded fixed partial dentures. *Quintessence Int* 2005;36:141–147.
- Foitzik M, Lennon AM, Attin T. Successful use of a single-retainer all-ceramic resin-bonded fixed partial denture for replacement of a maxillary canine: A clinical report. *Quintessence Int* 2007;38:241–246.
- Komine F, Tomic M. A single-retainer zirconium dioxide ceramic resin-bonded fixed partial denture for single tooth replacement: A clinical report. *J Oral Sci* 2005;47:139–142.
- Bayne SC, Schmalz G. Reprinting the classic article on USPHS evaluation methods for measuring the clinical research performance of restorative materials. *Clin Oral Investig* 2005;9:209–214.
- Rateitschak KH, Wolf HF. *Farbatlant der Zahnmedizin—Parodontologie*. Stuttgart: Georg Thieme, 1984.
- Flemming TF. *Parodontologie. Ein Kompendium*. Stuttgart: Georg Thieme, 1993.
- Christensen GJ. Magnification in dentistry: Useful tool or another gimmick? *J Am Dent Assoc* 2003;134:1647–1650.
- Hussey DL, Linden GJ. The clinical performance of cantilevered resin-bonded bridgework. *J Dent* 1996;24:251–256.
- Chan AW, Barnes IE. A prospective study of cantilever resin-bonded bridges: An initial report. *Aust Dent J* 2000;45:31–36.
- Botelho MG, Nor LC, Kwong HW, Kuen BS. Two-unit cantilevered resin-bonded fixed partial dentures: A retrospective, preliminary clinical investigation. *Int J Prosthodont* 2000;13:25–28.
- Kern M, Sasse M. Ten-year survival of anterior all-ceramic resin-bonded fixed dental prostheses. *J Adhes Dent* 2011;13:407–410.
- van Dalen A, Feilzer AJ, Kleverlaan CJ. The influence of surface treatment and luting cement on in vitro behavior of two-unit cantilever resin-bonded bridges. *Dent Mater* 2005;21:625–632.
- el-Mowafy O, Rubo MH. Resin-bonded fixed partial dentures: A literature review with presentation of a novel approach. *Int J Prosthodont* 2000;13:460–467.
- Fleigel JD III, Salmon CA, Piper JM II. Treatment options for the replacement of missing mandibular incisors. *J Prosthodont* 2011;20:414–420.
- Pospiech P, Rammelsberg P, Goldhofer G, Gernet W. All-ceramic resin-bonded bridges. A 3-dimensional finite-element analysis study. *Eur J Oral Sci* 1996;104:390–395.
- Koutayas SO, Kern M, Ferrareso F, Strub JR. Influence of framework design on fracture strength of mandibular anterior all-ceramic resin-bonded fixed partial dentures. *Int J Prosthodont* 2002;15:223–229.
- Hwang D, Wang HL. Medical contraindications to implant therapy. Part I: Absolute contraindications. *Implant Dent* 2006;15:353–360.
- Hwang D, Wang HL. Medical contraindications to implant therapy. Part II: Relative contraindications. *Implant Dent* 2007;16:13–23.
- Andersson B, Bergenblock S, Furst B, Jemt T. Long-term function of single-implant restorations: A 17- to 19-year follow-up study on implant infraposition related to the shape of the face and patients' satisfaction [epub ahead of print]. *Clin Implant Dent Relat Res* 2011 Aug 11.w

### Literature Abstract

#### Toothbrushing for critically ill mechanically ventilated patients: A systematic review and meta-analysis of randomized trials evaluating ventilator-associated pneumonia

This systematic review evaluated the effect of toothbrushing on the occurrence of ventilator-associated pneumonia (VAP) in mechanically ventilated critically ill adults. The authors searched studies published between 1980 and April 2012 in EMBASE, MEDLINE, CINAHL, the Cochrane Central Register of Controlled Trials, the Cochrane Database of Systematic Reviews, clinical trials.gov, and controlled-trials.com. The inclusion criteria for the studies were: (1) randomized controlled parallel group or factorial trial, (2) mechanically ventilated critically ill adult patients (18 years or older), (3) any oral care strategy involving toothbrushing compared with any other strategy or control with or without toothbrushing, and (4) primary outcome was VAP. The results showed: (1) a trend toward lower VAP rates with toothbrushing in four trials with 828 patients, and one other trial that reported fewer cases of VAP per 1,000 ventilator days, (2) the only trial with low risk of bias showed that VAP rates were significantly reduced with toothbrushing, (3) VAP rate was similar when comparing electric and manual toothbrushing, (4) co-administration of chlorhexidine with toothbrushing did not have significant effect on VAP rate, and (5) toothbrushing did not significantly influence length of ICU stay, ICU mortality, or hospital mortality.

Alhazzani W, Smith O, Muscedere J, Medd J, Cook D. *Crit Care Med* 2013;41:646–655. **References:** 65. **Reprints:** Dr D Cook.  
 Email: debcook@mcmaster.ca—Simon Ng, Singapore



Copyright of International Journal of Prosthodontics is the property of Quintessence Publishing Company Inc. and its content may not be copied or emailed to multiple sites or posted to a listserv without the copyright holder's express written permission. However, users may print, download, or email articles for individual use.