

# Noninvasive Restoration of Severe Erosion by Means of CAD/CAM Indirect Composite Occlusal Restorations: A Technical Note

Ulf Schepke, DDS<sup>a</sup>/Marco S. Cune, DDS, PhD<sup>b</sup>

The use of new materials and computer-aided design/computer-aided manufacturing techniques can help dental practitioners efficiently treat dental erosion in a predictable manner. If the vertical dimension of occlusion has to be increased, the static and dynamic occlusion need to be reorganized. This article presents and documents a practical, digital approach to such treatment and discusses possible merits as they relate to treatment time, ease of treatment, and predictability. *Int J Prosthodont* 2014;27:134–136. doi: 10.11607/ijp.3768

Dental wear can be described as the multifactorial noncarious loss of dental hard substance, involving attrition, abrasion, erosion,<sup>1</sup> and abfraction.<sup>2</sup> Progressive erosive tooth wear can be clinically difficult to diagnose at an early stage, and patients are often unaware of the problem because there is no pain or esthetic injury. In severe situations, it seems preferable to increase the vertical dimension of occlusion (VDO) with dental composite materials when contemplating restorative repair. This can be obtained either directly with composite resin materials or indirectly with occlusal restorations produced by the dental technician. For both restorative approaches, the desired diagnostic tooth arrangement would have to be transferred to the permanent restorations, which is time consuming and may be inaccurate. This challenge could be solved by using computer-aided design/computer-aided manufacturing (CAD/CAM), as presented in this clinical report.

<sup>a</sup>Lecturer, University of Groningen, University Medical Center Groningen, Center for Dentistry and Oral Hygiene, Department of Fixed and Removable Prosthodontics and Biomaterials, Groningen, The Netherlands.

<sup>b</sup>Professor, University of Groningen, University Medical Center Groningen, Center for Dentistry and Oral Hygiene, Department of Fixed and Removable Prosthodontics and Biomaterials, Groningen; St. Antonius Hospital, Prosthodontics and Special Dental Care, Nieuwegein, The Netherlands.

**Correspondence to:** Dr U. Schepke, UMC Groningen/Center for Dentistry and Oral Hygiene, Department of Fixed and Removable Prosthodontics and Biomaterials, Building 3216, Room 205, A. Deusinglaan 1, 9713 AV Groningen. Email: u.schepke@umcg.nl

©2014 by Quintessence Publishing Co Inc.

## Clinical Report

A 31-year-old man with an unremarkable medical history presented with concerns about the appearance of his maxillary anterior teeth (Fig 1). He admitted to excessive consumption of soft drinks. Clinical examination revealed group guidance and partly compensated loss of VDO. Old gypsum dental casts, taken elsewhere approximately 1 year earlier, were digitally compared with new ones obtained after the initial treatment. Severe loss of enamel and dentin between 2000 and 2011 was noticeable in the anterior region of the maxilla and prompted active restorative treatment (Fig 2).

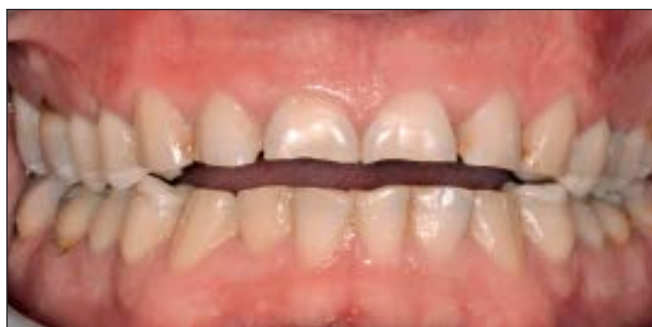The initial treatment consisted of diet education, oral hygiene instruction, removal of impacted third molars, caries treatment, and replacement of ill-fitting restorations. In this case, the anticipated alteration of VDO should be as much as esthetically needed and as little as possible to avoid acceptance problems or orthodontic intrusion.

The initial esthetic analysis included an incisal extension of the maxillary incisors (diagnostic tooth arrangement). Comprehensive photography was used to determine the occlusal/incisal plane and prosthetic space and to communicate the findings with the dental technician (Table 1).

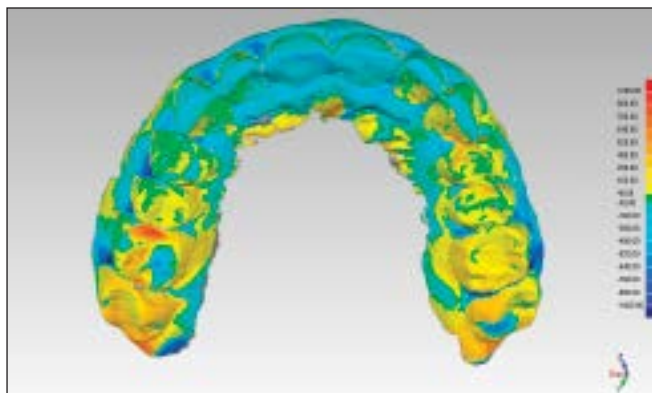
Maximum occlusion was registered, and an earbow registration was performed. Maxillary and mandibular impressions were taken with a polyether impression material (Impregum, 3M ESPE) and conventional impression trays. The casts were digitized in the dental laboratory.

The dental technician made a digital tooth arrangement, rebuilding the occlusal aspects of the molar and

**Fig 1** Frontal view in diagnostic phase with estimated increase of VDO in molar region to demonstrate loss of incisor length.



**Fig 2** Scans of casts of the maxilla 1 year before and directly after initial treatment, overlaid and analyzed with matching software. Untouched buccal surfaces were used as reference. Noticeable loss of tooth material was found in the anterior region on both labial and palatal tooth surfaces (note: addition of mesial material in maxillary right first molar was caused by new restoration being made during initial treatment).



**Table 1** Advised Photographic Documentation when Contemplating Alteration of VDO with Indirect Occlusals and Backings

Lateral view	Mouth closed in MIP to determine esthetically necessary increase of VDO. In relaxed position with interocclusal rest space to evaluate esthetic line as well as vertical and horizontal overlap. With earbow fork, parallel to occlusal plane on maxilla.
Frontal view	Mouth closed in MIP to determine esthetically necessary alteration of VDO. With earbow fork, parallel to occlusal plane on maxilla to determine facial symmetry. With diagnostic tooth arrangement in situ, with various degrees of lip elevation as part of additional esthetic analysis of anticipated shape, incisal length, and location of anterior teeth. With color sample (that should match available CAM restoration material color shades).

MIP = maximal intercuspal position.

premolar regions and the palatal aspects of the incisors and canines. This digital setup was subsequently used to produce silicone putty molds. The molds were sent to the dental office, filled chairside with tooth-colored bis-acrylic provisional composite (Protemp Crown, 3M ESPE), and tested intraorally.

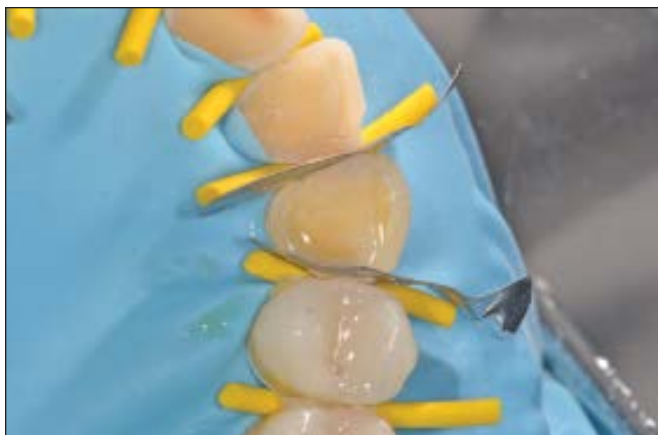This full-arch arrangement was documented and used to evaluate: (1) whether the amount of VDO correction would be acceptable to the patient, (2) the need for minor or major changes to the tooth arrangement to achieve esthetic and functional precision, and (3) the need for gingival surgery and/or orthodontics.

Rapid prototyping was used to convert the existing design into indirect CAM composite resin restorations (Ceramill COMP, AmannGirrbach). These were

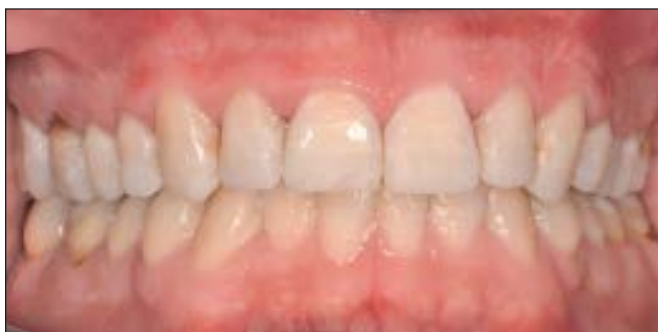silica coated (Rocatec, 3M ESPE) and cemented using a bonding agent and a resin cement (Scotch Bond Universal and RelyX Ultimate, 3M ESPE) (Figs 3 and 4).

### Discussion

There is no conclusive evidence to indicate that materials used to produce indirect resin restorations possess superior material properties compared with direct composite resins.<sup>3</sup> However, the indirect digital approach offers several advantages. The treatment becomes predictable because of the diagnostic tooth arrangement, which can be used to manufacture the permanent restorations. It saves chair time and offers additional diagnostics. Treatment can be concluded in



**Fig 3** Maxillary left canine. Restorations should be bonded individually and teeth separated from their neighboring teeth to avoid cement in approximal spaces as well as on overlapping rubber dam.



**Fig 4** Full-mouth rehabilitation from substantial erosive loss of dental hard tissues and loss of VDO. Adhesively bonded composite resin restorations directly after bonding.

three appointments. The digital setup has to be made only once and can be replicated or easily modified. In contrast to Vailati and Belser,<sup>4</sup> a full-mouth tooth arrangement at an early stage is preferred, since limited space in the molar region could influence treatment planning and clinical decision-making, including the use of orthodontic treatment or gingival correction surgeries to achieve a pleasing esthetic outcome.

It is advisable to inform the patient before treatment that labial composite resin or porcelain veneers are anticipated to finalize treatment. This may prove necessary not only to replace the lost labial hard tissues of the incisors and canines, but also because of a noticeable margin between natural teeth and milled restorations. It is suggested that the veneers should be bonded to the milled resin backings.<sup>5</sup>

### Conclusion

The use of a digital preoperative diagnostic tooth arrangement in complex dental treatment opens up the possibility of rapid prototyping without translation of the analog arrangement into a digital file. Emerging advantages of the technique described in this article include shorter treatment time as well as a time-reduced manufacturing process. The predictability of the final treatment could also be enhanced due

to easy transfer from the planning to the definitive restoration. Therefore, efficiency and quality in complex dental treatment can be positively influenced by digitalization.

### Acknowledgment

The authors thank Menno van der Veen at the Groningen Dental Laboratory for the digital tooth arrangement and fabrication of the occlusal and palatal CAD/CAM composite resin restorations. The authors reported no conflicts of interest related to this study.

### References

1. Imfeld T. Dental erosion. Definition, classification and links. *Eur J Oral Sci* 1996;104:151–155.
2. Bartlett DW, Shah P. A critical review of non-carious cervical (wear) lesions and the role of abfraction, erosion, and abrasion. *J Dent Res* 2006;85:306–312.
3. Cetin AR, Unlu N. Clinical wear rate of direct and indirect posterior composite resin restorations. *Int J Periodontics Restorative Dent* 2012;32:e87–e94.
4. Vailati F, Belser UC. Full-mouth adhesive rehabilitation of a severely eroded dentition: The three-step technique. Part 1. *Eur J Esthet Dent* 2008;3:30–44.
5. Gresnigt MM, Kalk W, Ozcan M. Clinical longevity of ceramic laminate veneers bonded to teeth with and without existing composite restorations up to 40 months. *Clin Oral Investig* 2013;17:823–832.

Copyright of International Journal of Prosthodontics is the property of Quintessence Publishing Company Inc. and its content may not be copied or emailed to multiple sites or posted to a listserv without the copyright holder's express written permission. However, users may print, download, or email articles for individual use.