

# Technical Complications and Failures of Zirconia-Based Prostheses Supported by Implants Followed Up to 7 Years: A Case Series

Lumni Kolgeci, Dr Med Dent<sup>a</sup>/Erno Mericske, Dr Med Dent<sup>b</sup>/Andreas Worni, Dr Med Dent<sup>a</sup>/  
Petra Walker, Dr Med Dent<sup>a</sup>/Joannis Katsoulis, PD Dr Med Dent, MAS<sup>c</sup>/  
Regina Mericske-Stern, Prof Dr Med Dent<sup>d</sup>

**Purpose:** To evaluate technical complications and failures of zirconia-based fixed prostheses supported by implants. **Materials and Methods:** Consecutive patients received zirconia-based single crowns (SCs) and fixed dental prostheses (FDPs) on implants in a private clinical setting between 2005 and 2010. One dentist performed all surgical and prosthetic procedures, and one master technician performed and coordinated all laboratory procedures. One-piece computer-aided design/computer-assisted manufacture technology was used to fabricate abutments and frameworks, which were directly connected at the implant level, where possible. All patients were involved in a recall maintenance program and were finally reviewed in 2012. Data on framework fractures, chipping of veneering ceramics, and other technical complications were recorded. The primary endpoint was failure of the prostheses, ie, the need for a complete remake. A life table analysis was calculated.

**Results:** A total of 289 implants supported 193 zirconia-based prostheses (120 SCs and 73 FDPs) in 127 patients (51 men, 76 women; average age:  $62.5 \pm 13.4$  years) who were reviewed in 2012. Twenty-five (13%) prostheses were cemented on 44 zirconia abutments and 168 (87%) prostheses were screw-retained directly at the implant level. Fracture of 3 frameworks (1 SC, 2 FDPs) was recorded, and significant chipping resulted in the remake of 3 prostheses (1 SC, 2 FDPs). The 7-year cumulative survival rate was  $96.4\% \pm 1.99\%$ . Minor complications comprised 5 loose screws (these were retightened), small chips associated with 3 prostheses (these were polished), and dislodgement of 3 prostheses (these were recemented). Overall, 176 prostheses remained free of technical problems. **Conclusions:** Zirconia-based prostheses screwed directly to implants are clinically successful in the short and medium term. *Int J Prosthodont* 2014;27:544–552. doi: 10.11607/ijp.3807

**G**old and other metal-based alloys used in the fabrication of tooth-implant-supported fixed dental prostheses (FDPs) are predictable and suitable for routine clinical practice. Metal-ceramic (MC)

prostheses are routinely used, have been clinically successful for many years, and, so far, seem to be superior to all-ceramic restorations.<sup>1</sup> The increasing esthetic demands of patients and the preference for metal-free restorations led to the development of a variety of ceramic materials. Due to good esthetics, favorable biologic properties, color stability, and resistance to wear, these were used to restore teeth with single crowns or veneers. However, they had limited application due to low strength properties, although adhesive cementation enhanced the mechanical stability.<sup>2,3</sup> Interest in zirconia as a restorative dental material with broad applications is increasing. The commercial market for zirconia products is growing in parallel with the development of refined and efficient computer soft- and hardware suitable for production of zirconia restorations.

<sup>a</sup>Postgraduate Student, Department of Prosthodontics, School of Dental Medicine, University of Bern, Bern, Switzerland.

<sup>b</sup>Private Practitioner, Zahnarztpraxis Bubenberg, Bern, Switzerland.

<sup>c</sup>Associate Professor, Department of Prosthodontics, School of Dental Medicine, University of Bern, Bern, Switzerland.

<sup>d</sup>Director and Chair, Department of Prosthodontics, School of Dental Medicine, University of Bern, Bern, Switzerland.

**Correspondence to:** Dr Lumni Kolgeci, Department of Prosthodontics, School of Dental Medicine, University of Bern, Freiburgstr 7, CH-3010 Bern, Switzerland.  
Email: lumni.kolgeci@zmk.unibe.ch

©2014 by Quintessence Publishing Co Inc.



Zirconia-based frameworks were eventually developed for tooth-supported single crowns (SCs) and short-span tooth-supported FDPs. Recommendations regarding the size and shape of tooth preparation were made, and good precision of fit was demonstrated.<sup>4-7</sup> Early high fracture rates were attributed to deficiencies in approximal connector designs, and a surface area of  $3 \times 3$  mm up to  $4 \times 4$  mm was recommended as a prerequisite for fabrication of multi-unit FDPs.<sup>4</sup> One study reported relatively high caries incidence at crown margins within a relatively short observation time.<sup>8</sup> There was and still is disagreement on the best way for luting these restorations to teeth or to implant abutments. A recent review concluded that various materials can be used.<sup>9</sup> Laboratory tests suggest that a specifically developed universal primer may provide a better long-term bonding to zirconia.<sup>10</sup> Until recently, computer-aided design/computer-assisted manufacture (CAD/CAM) systems did not have the capacity to produce long-span prostheses, and restorations with more than five units were not recommended.<sup>5,6,8</sup>

Significant chipping of the veneering porcelain in the clinical application of zirconia-based restorations also has been reported.<sup>11</sup> Thus, there is still a reluctance to integrate zirconia-based restorations into daily practice. The number of clinical studies reporting on zirconia-based FDPs is growing, but the number of patients included in these studies is rather small.<sup>4,5,12-16</sup> These studies have identified various problems, such as veneer chipping, fracture of veneering material, loss of retention, and loss of vitality of abutment teeth. From a clinical point of view, the mechanical stability of the material is still considered to be a risk factor. Nevertheless, one study claims similar outcomes to MC prostheses.<sup>17</sup>

Concurrent with the application of zirconia for tooth-supported prostheses, most implant systems began to offer prefabricated and custom-made, individually milled abutments with comparable technical and biologic outcomes<sup>18-20</sup> to titanium abutments. CAD/CAM technologies for processing material have evolved over time. Initially, the recommended coping thickness was 0.6 mm. Insufficient support for the veneering porcelain was identified as contributing to the problem of chipping, and, subsequently, a double scan technique involving a scan of the tooth preparation and anatomical contour of the envisaged final tooth form was recommended to fabricate an adequately supporting framework. Recommended firing protocols were initially the same as for MC prostheses but were gradually modified to accommodate the investigated thermal expansion and heat diffusion properties of zirconia.<sup>21</sup> These modifications resulted in prolonged heating and cooling cycles being recommended.

The aim of this case series was to evaluate technical complications and failures of zirconia-based fixed prostheses supported by implants.

## Materials and Methods

### *Patients and Implants*

From early 2005 to the end of 2010 (6 years), patients with partial edentulism or edentulous jaws were consecutively admitted for implant placement and zirconia-based prosthetic treatment. All surgical and prosthetic treatments were carried out in the same clinical setting at a private practice, and the patients were regularly followed after completion of the implant/prosthetic therapy. The treatment and quality management met the standards of the Declaration of Helsinki.

Patients were eligible to receive the prostheses with the new technology if they had completed the consent form and confirmed that they were willing to have zirconia-based prostheses placed instead of conventional restorations. They also were informed that they should participate regularly in a maintenance program. All treatment costs were borne by the patients.

One dentist selected and informed the patients and performed all clinical procedures, ie, surgery and prosthodontic work. Patients of all age groups who required implant surgery at differing levels of complexity were included, unless they fell under the following exclusion criteria:

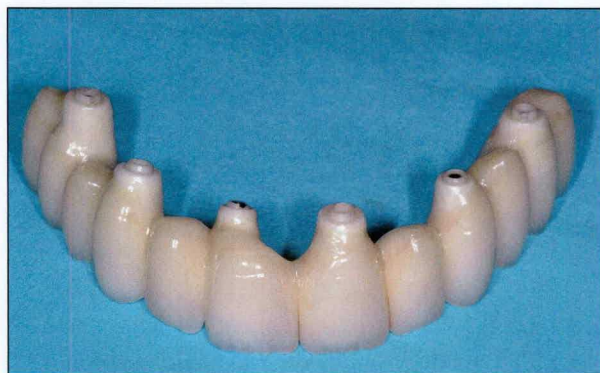- Regular medications with corticosteroids
- Poorly controlled diabetes
- Heart attack/stroke within the previous 6 months
- Any disease that would contraindicate implant placement under local anesthesia
- Psychiatric problems
- Unrealistic patient expectations
- Pregnancy
- Radiographic investigations contraindicated
- Radiotherapy, chemotherapy treatment in the previous 7 years

Smokers were informed about a possible associated negative influence on treatment outcomes, and a smoking-cessation program was recommended.

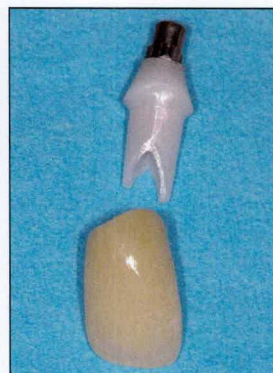Nobel Replace tapered implants (Nobel Biocare) were placed in all patients. The standard surgical instrumentation protocol recommended by the manufacturers was adhered to.

Six weeks' healing time postimplant placement in the mandible and 8 to 10 weeks in the maxilla were observed. This was extended to a minimum of 4 months if implants were placed in combination with local bone augmentation techniques and 6 months

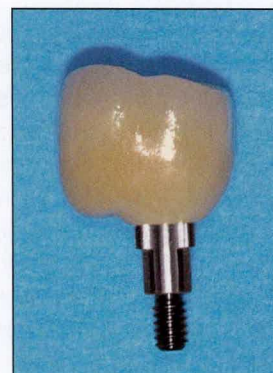



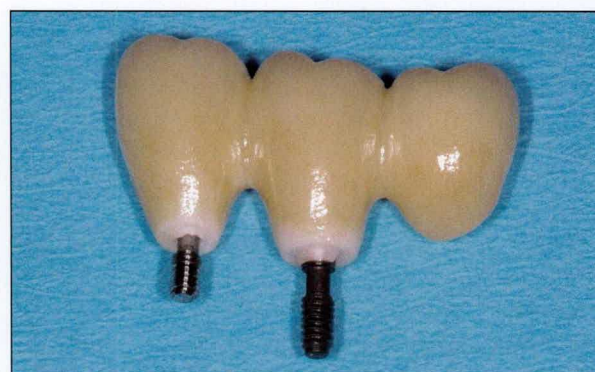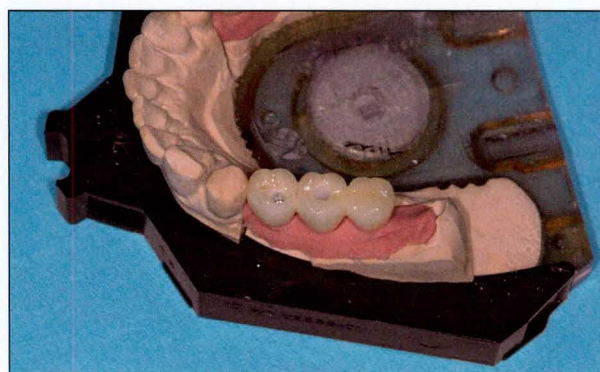
**Fig 1** Symmetrically distributed implants in a one-piece 12-unit FDP.



**Fig 2** Zirconia abutment with engaging titanium insert and zirconia-based single crown, cement retained.



**Fig 3** Screw-retained single crown with engaging titanium insert at implant level.



**Figs 4a and 4b** Three-unit cantilever FDP with screw-retained non-engaging retention, at implant level.

after sinus floor elevations involving a lateral window access. Bio-Oss was used as the graft material and Bio-Gide barrier membranes (Geistlich) were used, where indicated. A diagnostic tooth setup served for planning and fabrication of radiographic and surgical splints for presurgical analysis and predictable implant placement. In complex situations, three-dimensional (3D) planning software was used (NobelGuide, Nobel Biocare). Implants were immediately placed in the extraction sockets, especially in patients of advanced age. Deep crown or root fracture and advanced attachment loss were a few reasons for extraction.

### Prosthetic Procedures

The prosthetic indications were SCs and FDPs of 3 to 12 units. Implants were evenly distributed in the edentulous spaces to avoid framework segmentation and to utilize cross-arch stabilization, where possible. The zirconia frameworks were fabricated for direct screw retention to the implants, without abutment interposition if implant alignment was suitable (Fig 1). This enabled the prosthesis to be removed, if indicated,

and individual, unconnected implants to be monitored. Where correction of the crown/implant axis was required—particularly in the anterior zone of the maxilla—custom-made zirconia abutments were used and the prostheses cemented (Fig 2). Crowns and short-span FDPs were cemented onto the zirconia abutments, when indicated, with Panavia F (Kuraray Noritake Dental). SC abutments were engaged to the implant with an interposing anti-rotational titanium insert, whereas FDPs were nonengaging, with direct contact among the zirconia, implant shoulder, and fixation screw (Figs 3 and 4).

Implant placement was planned for direct screw access. This was facilitated with a diagnostic setup and surgical guide. In simple situations with favorable bone conditions, single or panoramic radiographs were considered appropriate. For more demanding implant sites, computed or cone beam tomographs were obtained and computer-assisted planning was utilized with the NobelGuide (Nobel Biocare) software. Stiff polyether impression material (Impregum, 3M ESPE) was used in open trays with screw-retained unsplinted impression copings. The laboratory



technician fabricated a resin pattern or wax form for scanning, and the framework design was checked and completed by means of the computer software. Thus, a WAX/CAM technology was used. The electronic data were then sent to the Procera milling center (Nobel Biocare).

This CAD/CAM technology had the capacity to produce substructures of both small and large dimensions and direct screw retention. Three feldspathic veneering materials were used throughout the study.

## Maintenance

All patients were included in a regular maintenance care program involving two scheduled visits per year following provision of the definitive prosthesis. A hygienist administered the maintenance program under the supervision of the dentist. Patients were recalled by phone, letters, or electronic messaging. These maintenance visits included monitoring of caries and periodontal problems, debridement procedures, instruction and motivation to maintain good oral hygiene, as well as radiographic monitoring according to the individual risks of the patient. If technical problems or any complications were detected or reported by the patients, they were, if possible, immediately seen by the dentist, and the corrective treatment was performed, or they received an additional appointment with the dentist as soon as practical for the corrective treatment. Any other unscheduled visits also were recorded.

## Data Collection

The dentist and hygienist saw all available patients throughout 2012 at their recall session, and the patients were informed about the study goal. Two independent investigators, who had not been involved in the treatment, collected all clinical, radiologic, and technical data. Observation times ranged from 2 to 7 years.

The primary endpoint was the survival of the zirconia prosthesis, and the outcome measure was fracture of the framework or the need to remake the prosthesis for other reasons. The secondary endpoint was technical complications requiring corrective treatment. Chipping of the veneering material requiring the dentist to remake the prosthesis occurred due to the following:

- Chipping of large size
- Chipping of small size but well visible in esthetic area
- Chipping—either of large or small size—interfering with a stable occlusal contact. Small chipping, which was polished, was registered as a minor complication.

Further corrective treatment without the need of remaking the prosthesis included tightening loose screws and recementing dislodged prostheses. Loss of the prosthesis due to implant loss also was reported as well as peri-implant tissue affections. A distinction was made between peri-implant mucosal inflammation and infection of the peri-implant tissues exhibiting suppuration, bleeding on probing, and increased probing depths ( $> 5$  mm). The treatment for mucosal inflammation consisted of a strict hygiene regime, whereas peri-implant infections required a flap for open debridement, combined with laser application of the exposed implant section.

## Statistical Analysis

Detailed data on complications and failures of patients who were participating in the recall maintenance session in 2012 were reported in the study.

Descriptive statistics were used for patients' demographics, implant distribution, type of zirconia reconstructions, and all associated complications. A life table analysis<sup>22</sup> was performed for the primary endpoint. The interval and the cumulative survival rates and associated standard error were calculated. A Kaplan-Meier survival curve illustrates with a 95% confidence interval the probability that no primary or secondary endpoint event occurred. The individual curves for the primary and secondary endpoints also are illustrated.

## Results

One hundred and twenty-seven (93%) of the original cohort (51 men, 76 women; average age:  $62.5 \pm 13.4$  years) were available in 2012 for examination and data collection. From that sample, 289 implants (148 maxilla, 141 mandible) supported 193 zirconia-based prostheses, consisting of a total of 429 units (including pontics, cantilevers, and abutments). The percentages of the various veneering materials were 5% NobelRondo (Nobel Biocare), 22% Creation (Willi Geller), and 73% Cerabien (Kuraray Noritake Dental). The mean observation time was  $3.3 \pm 1.7$  years, with a range of 2 up 7.6 years.

Ten patients with 11 prostheses dropped out before the end of 2012: 4 for unknown reasons, 3 had moved away, 1 returned to the family dentist, and 2 had passed away. Table 1 provides an overview of the implants and the type of prosthesis for the remaining 127 patients.

Up to 2012, six patients had experienced a technical failure that required their prostheses to be remade, while 12 prostheses had required treatment of technical complications. Fractures of the framework (two FDPs, one SC) and extensive chipping (one FDP



**Table 1** Overview of Zirconia-Based Fixed Dental Prostheses (FDPs)

	Cement-retained	Screw-retained	Total	Maxilla	Mandible
<b>Implants and prostheses</b>					
Implants	44	245	289	148 (56*/92)	141 (14*/127)
Prostheses	25	168	193	103	90
Units	104 <sup>†</sup>	325	429	230	199
<b>Type of prosthesis</b>					
Single crowns	12	108	120	58	62
FDP 3–4 units	8	47	55	29	26
FDP 5–12 units	5	13	18	16	2

\*Anterior implants from canine to canine.

<sup>†</sup>Including 44 abutments.**Table 2** Complications and Failures: Year After Delivery (n = 127)

Event	1st year	2nd year	3rd year	4th year	≥ 5th year	Total
Chipping/polishing	1/1*	–	1	1	–	4
Chipping/remake	1	2	–	–	–	3 <sup>†</sup>
Fracture framework	1	1	–	1*	–	3 <sup>†</sup>
Screw loosening	4	1	–	–	–	5
Decementation	1	1	1	–	–	3

\*Two complications of the same FDP.

<sup>†</sup>Complete failures.

and two SCs) were the reasons for complete technical failures. The fractures occurred in a five-unit FDP, in a four-unit FDP, and in an SC, all screw-retained. No cantilevers were present.

Chipping that required remakes occurred in a screw-retained three-unit FDP, and in two SCs, one cemented, one screw-retained. Minor technical complications requiring corrective treatment comprised small chipping with subsequent polishing, screw loosening with subsequent retightening, and loss of retention with subsequent recementation. One SC became loose because of a separation between the zirconia framework and the titanium insert. The crown was removed, a new titanium insert placed and the crown repositioned, and the abutment screw was retightened. Loosening of an abutment supporting a cemented restoration was not observed. Table 2 gives an overview of complications and failures of the prostheses.

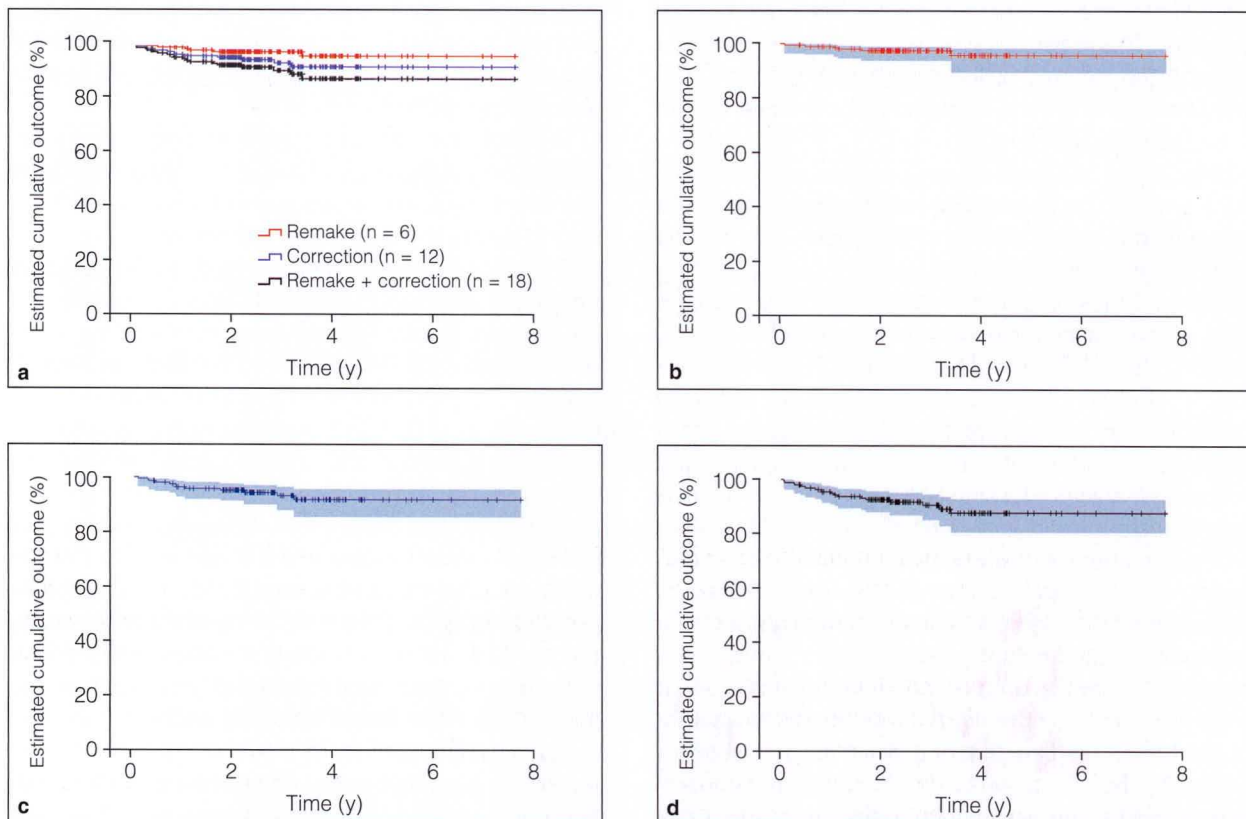
Extensive chipping of a four-unit FDP was observed in its second year and ascribed to the veneering material. The chipping occurred within the layered ceramic material. One female patient with a five-unit screw-retained FDP supported by two implants (three pontics) experienced two fractures. She was diagnosed with heavy bruxism. Finally, an additional implant was placed and a new restoration made by fabricating a titanium framework with acrylic resin veneering

material. One screw-retained four-unit FDP in the anterior mandible fractured after 22 months. The failure was ascribed to incorrect handling of the framework, which was modified with burs to create more space for hygiene access. This resulted in weakening of the wall and approximal connector regions.

Table 3 represents a life table analysis with censored data, the interval and cumulative survival rate of the zirconia prostheses, and the associated standard errors. The 7-year cumulative survival rate was 96.4% ± 1.99%. Figure 5a (Kaplan-Meier survival curve) depicts the probability of technical failures (red curve), of corrective treatments (blue curve), and all events combined (black curve). Figures 5b to 5d show the related 95% confidence intervals of each single curve. Most events occurred in the first 3 years after delivery of the prostheses (Table 2). No wear of the zirconia in direct contact with the implant shoulder was observed at a macroscopic level if FDPs were removed during a recall session. Three patients lost an implant, but their zirconia prostheses (two SCs, one FDP) were not affected by technical problems. These patients received new implants and zirconia-based restorations. Treatment of biologic problems associated with peri-implant tissues and loss of implants are listed in Table 4. The structural integrity of the associated prostheses was not affected.

**Table 3** Life Table Analysis: Technical Failures

Interval (y)	Prostheses at risk	Drop out	Censored	Failed	Probability of survival (%)	Estimated cumulative survival (%)	Standard error (%)
0-1	204	1	1	2	99.0	99.0	0.71
> 1-2	201	3	3	3	98.5	97.5	1.21
> 2-3	155	4	40	0	100	97.5	1.21
> 3-4	85	2	69	1	98.9	96.4	1.99
> 4-5	56	1	29	0	100	96.4	1.99
> 5-6	37	0	19	0	100	96.4	1.99
> 6+	18	0	0	0	100	96.4	1.99



**Fig 5** (a) Probability of no events is depicted in relation to failures with need of remake, to corrective treatments without the need of remake, and to the combination of all events. The dash markings indicate the censored data. (b) Complete failures and remake: probability of no events and related confidence interval of 95% (*shadow around curve*). The dash markings indicate the censored data. (c) Corrective treatments: probability of no events and related confidence interval of 95% (*shadow around curve*). The dash markings indicate the censored data. (d) All events: probability of no events and related confidence interval of 95% (*shadow around curve*). The dash markings indicate the censored data.

**Table 4** Biologic Complications and Failures

Year	Mucosal inflammation	Peri-implant infection	Implant loss
1	Maxillary cement-retained SC	Mandibular screw-retained SC	1 (mandibular screw-retained SC)
2	-	-	1 (maxillary cement-retained SC)
3	Maxillary screw-retained 3-unit FDP Maxillary cement-retained SC	Maxillary screw-retained 4-unit FDP	1 (screw-retained 3-unit FDP)
4	-	Maxillary screw-retained SC Maxillary cement-retained 3-unit FDP	-
5	Mandibular screw-retained 3-unit FDP	-	-
6	-	Mandibular screw-retained 3-unit FDP	-

SC = single crown; FDP = fixed dental prosthesis.



## Discussion

This is the first private practice–based report on the broad use of zirconia frameworks for implant-supported prostheses in a large number of patients. Only 7% of patients were lost to follow-up over the 7 years, and patient compliance with regular maintenance was excellent.

However, the use of only one type of CAD/CAM technology and a lack of comparison with conventional MC and gold/acrylic prostheses could be considered limitations. Comparison with other studies is not possible. This especially relates to the protocol of connecting the zirconia-based prostheses directly to the implants, although the concept has been described in a narrative review.<sup>23</sup>

The 7-year cumulative survival rate was  $96.4\% \pm 1.99\%$ , which is considered satisfactory, taking into account the use of new and developing technology and the associated clinician and technician learning required. Crack propagation and fractures in the core and veneering material have been identified as risk factors, especially with the use of soft-milled zirconia.<sup>11,24</sup> However, relatively few such failures occurred in the current study, even though the majority (73%) were screwed directly to the supporting implants and were not considered a significant problem. Two previous studies have reported on short- and long-span FDPs cemented on titanium abutments. No framework fractures occurred after 3 to 5 years.<sup>25,26</sup> It could be assumed that ceramic material screwed directly to osseointegrated implants results in a stiff entity, and, therefore, technical problems might more easily occur than with zirconia fitting directly on teeth. Conversely, it has been claimed that the solid implant support might be beneficial for zirconia-based prostheses, due to decreased stress and strain levels under occlusal load compared to tooth support.<sup>4</sup>

The concept of direct screw retention is based on optimum planning of the implant axis to provide parallel alignment for the prosthesis. With the Procera technology, this resulted in a flat-to-flat contact zone between the implant shoulder and zirconia frameworks. However, the ideal biologic and mechanical implant-abutment/implant-prosthesis connection form is clinically disputed and has been investigated in laboratory studies.<sup>27–29</sup> Biologic results are not reported in detail in the present study and were not a major complication. Internal connection is often recommended due to its supposed beneficial effect on crestal bone stability<sup>30</sup> through more efficient marginal seal and stress distribution. This was disputed in a recent laboratory study.<sup>31</sup> Another laboratory study identified substantial fractures of the zirconia abutments in the inner conical part of the internal implant connection.<sup>32</sup> This may be

due to a lack of a defined vertical stop, and, therefore, support during screw tightening. Furthermore, in spite of proper implant alignment in long-span prostheses, direct screw access is not feasible with an internal connection.

In the present study, the majority of SCs and FDPs were attached to the prostheses by direct screw retention at the implant level, and an abutment was not used. This may reduce inaccuracy in the laboratory procedures. A previous study comparing long-span WAX- or CAD/CAM-fabricated frameworks showed a high precision of fit for large one-piece (10 to 12 units) zirconia frameworks fitting on six maxillary Nobel Replace implants,<sup>33</sup> with marginal gaps below 100  $\mu\text{m}$  and averaging 30  $\mu\text{m}$ .

Screw loosening was a rare, insignificant event occurring only in the early phase of the study (first year: four times, second year: once). No screw fractures occurred during the entire observation period.

Fracture of zirconia frameworks is not a significant problem in short-term observations, while chipping of the veneering material has been identified as a frequent reason for failure with either tooth or implant support.<sup>34–36</sup> No clear relationship between the type of prosthesis (SC, FDP, cemented, or screw-retained, maxilla or mandible) and chipping could be identified in the present study. Only one FDP with chipping had a cantilever unit. One could, however, assume that screw retention or cantilevers might increase stress in the zirconia framework and increase the chipping problem. No clear differentiation was made regarding the fracture/chipping mode of the veneering material in previous clinical studies. Clinically, however, a visible difference between chipping within the layered material or chipping from the core material can be observed. Although fractured veneering material has been analyzed<sup>24,34,37</sup> it is unknown whether the type of CAD/CAM system, the veneering material itself, or the stage of the milled zirconia (green stage, soft milled, pre- or densely sintered, etc) has an influence. The studies mentioned above also concluded that layered veneering is more stable than overpressing, while one systematic review reported on the advantages of overpressing.<sup>38</sup>

NobelRondo veneering porcelain was associated with an early failure of a multi-unit FDP in the present study. This material was subsequently withdrawn from the market due to reported extensive chipping. Standard feldspathic ceramics were then used for veneering in a furnace (Programat P510, Ivoclar) with recommended<sup>39</sup> modified preheating and cooling cycles, with little resultant chipping incidence. In addition, frameworks were modified with an anatomical contour to ensure adequate support for the veneer. Research also has identified possible phase changes



in the structure of the zirconia, which may result in fracture, both during firing<sup>21,40</sup> and as a result of age degradation.

Currently, systematic reviews generally report more technical problems with implant-supported compared to tooth-supported FDPs. However, the type of connection used at the implant level should be distinguished in systematic reviews as it may influence clinical outcomes.

## Conclusions

The up to 7-year outcome of 193 zirconia-based prostheses, including 55 that reached a clinical service time of 5 years, indicates that zirconia-based prostheses screwed directly to implants are clinically successful in the short and medium term. Framework fractures were rare, although framework integrity was reliant on adequate design and processing. Chipping of the veneering porcelain was minimized with modified heating and cooling cycles.

## Acknowledgments

Our sincere thanks go to the MDT Remzi Kolgeci—Manager Dental Laboratory Bubenber, Bern, Switzerland—who performed all of the laboratory work. The authors reported no conflicts of interest related to this study.

## References

1. Pjetursson BE, Sailer I, Zwahlen M, Hammerle CH. A systematic review of the survival and complication rates of all-ceramic and metal-ceramic reconstructions after an observation period of at least 3 years. Part I: Single crowns. *Clin Oral Implants Res* 2007;18(suppl 3):73–85.
2. Sadan A, Blatz MB, Lang B. Clinical considerations for densely sintered alumina and zirconia restorations: Part 1. *Int J Periodontics Restorative Dent* 2005;25:213–219.
3. Sadan A, Blatz MB, Lang B. Clinical considerations for densely sintered alumina and zirconia restorations: Part 2. *Int J Periodontics Restorative Dent* 2005;25:343–349.
4. Vult von Steyern P, Kokubo Y, Nilner K. Use of abutment-teeth vs. dental implants to support all-ceramic fixed partial dentures: An in-vitro study on fracture strength. *Swed Dent J* 2005;29:53–60.
5. Larsson C, Vult von Steyern P, Sunzel B, Nilner K. All-ceramic two- to five-unit implant-supported reconstructions. A randomized, prospective clinical trial. *Swed Dent J* 2006;30:45–53.
6. Bahat Z, Mahmood DJ, Vult von Steyern P. Fracture strength of three-unit fixed partial denture cores (Y-TZP) with different connector dimension and design. *Swed Dent J* 2009;33:149–159.
7. Abduo J, Lyons K, Swain M. Fit of zirconia fixed partial denture: A systematic review. *J Oral Rehabil* 2010;37:866–876.
8. Sailer I, Feher A, Filser F, Gauckler LJ, Luthy H, Hammerle CH. Five-year clinical results of zirconia frameworks for posterior fixed partial dentures. *Int J Prosthodont* 2007;20:383–388.
9. Komine F, Blatz MB, Matsumura H. Current status of zirconia-based fixed restorations. *J Oral Sci* 2010;52:531–539.
10. Attia A, Kern M. Long-term resin bonding to zirconia ceramic with a new universal primer. *J Prosthet Dent* 2011;106:319–327.
11. Al-Amleh B, Lyons K, Swain M. Clinical trials in zirconia: A systematic review. *J Oral Rehabil* 2010;37:641–652.
12. Wolfart S, Harder S, Eschbach S, Lehmann F, Kern M. Four-year clinical results of fixed dental prostheses with zirconia substructures (Circon): End abutments vs. cantilever design. *Eur J Oral Sci* 2009;117:741–749.
13. Tinschert J, Schulze KA, Natt G, Latzke P, Heussen N, Spiekermann H. Clinical behavior of zirconia-based fixed partial dentures made of DC-Zirkon: 3-year results. *Int J Prosthodont* 2008;21:217–222.
14. Raigrodski AJ, Chiche GJ, Potiket N, et al. The efficacy of posterior three-unit zirconium-oxide-based ceramic fixed partial dental prostheses: A prospective clinical pilot study. *J Prosthet Dent* 2006;96:237–244.
15. Edelhoff D, Florian B, Florian W, Johnen C. HIP zirconia fixed partial dentures—Clinical results after 3 years of clinical service. *Quintessence Int* 2008;39:459–471.
16. Beuer F, Edelhoff D, Gernet W, Sorensen JA. Three-year clinical prospective evaluation of zirconia-based posterior fixed dental prostheses (FDPs). *Clin Oral Investig* 2009;13:445–451.
17. Sailer I, Gottnerb J, Kanelb S, Hammerle CH. Randomized controlled clinical trial of zirconia-ceramic and metal-ceramic posterior fixed dental prostheses: A 3-year follow-up. *Int J Prosthodont* 2009;22:553–560.
18. Zembic A, Bosch A, Jung RE, Hammerle CH, Sailer I. Five-year results of a randomized controlled clinical trial comparing zirconia and titanium abutments supporting single-implant crowns in canine and posterior regions. *Clin Oral Implants Res* 2013;24:384–390.
19. van Brakel R, Meijer GJ, Verhoeven JW, Jansen J, de Putter C, Cune MS. Soft tissue response to zirconia and titanium implant abutments: An in vivo within-subject comparison. *J Clin Periodontol* 2012;39:995–1001.
20. van Brakel R, Cune MS, van Winkelhoff AJ, de Putter C, Verhoeven JW, van der Reijden W. Early bacterial colonization and soft tissue health around zirconia and titanium abutments: An in vivo study in man. *Clin Oral Implants Res* 2011;22:571–577.
21. Swain MV. Unstable cracking (chipping) of veneering porcelain on all-ceramic dental crowns and fixed partial dentures. *Acta Biomater* 2009;5:1668–1677.
22. Cutler SJ, Ederer F. Maximum utilization of the life table method in analyzing survival. *J Chronic Dis* 1958;8:699–712.
23. Guess PC, Att W, Strub JR. Zirconia in fixed implant prosthodontics. *Clin Implant Dent Relat Res* 2012;14:633–645.
24. Baldassarri M, Zhang Y, Thompson VP, Rekow ED, Stappert CF. Reliability and failure modes of implant-supported zirconium-oxide fixed dental prostheses related to veneering techniques. *J Dent* 2011;39:489–498.
25. Larsson C, Vult von Steyern P, Nilner K. A prospective study of implant-supported full-arch yttria-stabilized tetragonal zirconia polycrystal mandibular fixed dental prostheses: Three-year results. *Int J Prosthodont* 2010;23:364–369.
26. Larsson C, Vult von Steyern P. Five-year follow-up of implant-supported Y-TZP and ZTA fixed dental prostheses. A randomized, prospective clinical trial comparing two different material systems. *Int J Prosthodont* 2010;23:555–561.
27. Ribeiro CG, Maia ML, Scherrer SS, Cardoso AC, Wiskott HW. Resistance of three implant-abutment interfaces to fatigue testing. *J Appl Oral Sci* 2011;19:413–420.
28. Gracis S, Michalakis K, Vigolo P, Vult von Steyern P, Zwahlen M, Sailer I. Internal vs. external connections for abutments/reconstructions: A systematic review. *Clin Oral Implants Res* 2012;23(suppl 6):202–216.



29. Freitas-Junior AC, Almeida EO, Bonfante EA, Silva NR, Coelho PG. Reliability and failure modes of internal conical dental implant connections. *Clin Oral Implants Res* 2013;24:197–202.
30. Penarrocha-Diago MA, Flichy-Fernandez AJ, Alonso-Gonzalez R, Penarrocha-Oltra D, Balaguer-Martinez J, Penarrocha-Diago M. Influence of implant neck design and implant-abutment connection type on peri-implant health. Radiological study [epub ahead of print]. *Clin Oral Implants Res* 2012. doi: 10.1111/j.1600-0501.2012.02562.x.
31. Michalakakis K, Calvani P, Muftu S, Pissiotis A, Hirayama H. The effect of different implant-abutment connections on screw joint stability [epub ahead of print]. *J Oral Implantol* 2012. DOI: 10.1563/AID-JOI-D-11-00032.
32. Truninger TC, Stawarczyk B, Leutert CR, Sailer TR, Hammerle CH, Sailer I. Bending moments of zirconia and titanium abutments with internal and external implant-abutment connections after aging and chewing simulation. *Clin Oral Implants Res* 2012;23:12–18.
33. Katsoulis J, Mericske-Stern R, Rotkina L, Zbaren C, Enkling N, Blatz MB. Precision of fit of implant-supported screw-retained 10-unit computer-aided-designed and computer-aided-manufactured frameworks made from zirconium dioxide and titanium: An in vitro study [epub ahead of print]. *Clin Oral Implants Res* 2012. doi: 10.1111/clr.12039.
34. Lohbauer U, Amberger G, Quinn GD, Scherrer SS. Fractographic analysis of a dental zirconia framework: A case study on design issues. *J Mech Behav Biomed Mater* 2010;3:623–629.
35. Schley JS, Heussen N, Reich S, Fischer J, Haselhuhn K, Wolfart S. Survival probability of zirconia-based fixed dental prostheses up to 5 yr: A systematic review of the literature. *Eur J Oral Sci* 2010;118:443–450.
36. Triwatana P, Nagaveroj N, Tulapornchai C. Clinical performance and failures of zirconia-based fixed partial dentures: A review literature. *J Adv Prosthodont* 2012;4:76–83.
37. Guess PC, Bonfante EA, Silva NR, Coelho PG, Thompson VP. Effect of core design and veneering technique on damage and reliability of Y-TZP-supported crowns. *Dent Mater* 2013;29:307–316.
38. Heintze SD, Rousson V. Survival of zirconia-and metal-supported fixed dental prostheses: A systematic review. *Int J Prosthodont* 2010;23:493–502.
39. Zhang Z, Guazzato M, Sornsuwan T, et al. Thermally induced fracture for core-veneered dental ceramic structures [epub ahead of print]. *Acta Biomater* 2013. doi: 10.1016/j.actbio.2013.05.009.
40. Oilo M, Gjerdet NR, Tvinnereim HM. The firing procedure influences properties of a zirconia core ceramic. *Dent Mater* 2008;24:471–475.

### Literature Abstract

#### Folate intake and the risk of oral cavity and pharyngeal cancer: A pooled analysis within the International Head and Neck Cancer Epidemiology Consortium

Folate is necessary in DNA synthesis and repair. Thus, this retrospective study aimed to determine whether there was an association between the amount of folate intake and risk of oral cavity and pharyngeal cancers (OPCs). Individual-level data from 10 case-control studies involving 5,127 cases (13,249 controls) of OPC, were selected from a total of 25,478 cases (37,111 controls) within the International Head and Neck Cancer Epidemiology (INHANCE) Consortium. OPC cases were separated according to three categories of anatomical sites: the oral cavity, the oropharynx, and the oral cavity, pharynx unspecified or overlapping. Cases were more likely cigarette smokers and alcohol drinkers than controls. They were deemed suitable if data regarding folate intake was available for at least 80% of the subjects who had taken the food frequency questionnaire. To obtain an estimate of folate and energy intake, validated study-specific food composition tables were utilized. Folate intake sources include natural sources, folate-fortified food products, and folate supplementation. The association was then obtained by estimating odds ratios (ORs) and the corresponding 95% confidence interval (CI) and using unconditional logistic regression model for each case-control study. There was evidence of an inverse association between OPC risk and folate intake (0.65, 95% CI: 0.43–0.99), which was more evident in oral cavity cancer (OR = 0.57, 95% CI: 0.43–0.75). In heavy alcohol drinkers with low folate intake, versus never/light drinkers with high folate intake, the highest OPC risk was found (OR = 4.05, 95% CI: 3.43–4.79). Researchers found 11.1% of OPC cases could be attributable to biologic interaction amongst heavy drinkers. An OR of 2.73 was also noted for tobacco users with a low folate intake, compared to those with no tobacco intake coupled with an intermediate/high total folate intake. This study then suggests that total folate intake, with inclusion of supplements and fortified food, is inversely related to risk of OPC. A suggestion that high levels of folate intake may then protect against risk of OPC is made. However, this study was unable to distinguish the effect of folate on OPC risk relating to intake of fortified foods or supplements. It was also subjected to recall bias and possible changes in dietary habits postinterview. The association with human papillomavirus, a relevant risk factor for OPC, also was not considered.

**Galeone C, Edefonti V, Parpinel M, Leoncini E, Matsuo K, Talamini R, Olshan AF, Zevallos JP, Winn DM, Jayaprakash V, Moysich K, Zhang ZF, Morgenstern H, Levi F, Bosetti C, Kelsey K, McClean M, Schantz S, Yu GP, Boffetta P, Lee YC A, Hashibe M, La Vecchia C, Boccia S.** *Int J Cancer* 2014 Jun 26 [epub ahead of print]; doi: 10.1002/ijc.29044. **References:** 55. **Reprints:** Stefania Boccia, Genetic Epidemiology and Public Health Genomics Unit, Section of Hygiene, Institute of Public Health, Università Cattolica del Sacro Cuore, L. go F. Vito, 1–00168 Rome, Italy. Fax: 139-(0)-6- 35001522. Email: sboccia@rm.unicatt.it—*Sheralyn Quek, Singapore*



Copyright of International Journal of Prosthodontics is the property of Quintessence Publishing Company Inc. and its content may not be copied or emailed to multiple sites or posted to a listserv without the copyright holder's express written permission. However, users may print, download, or email articles for individual use.