

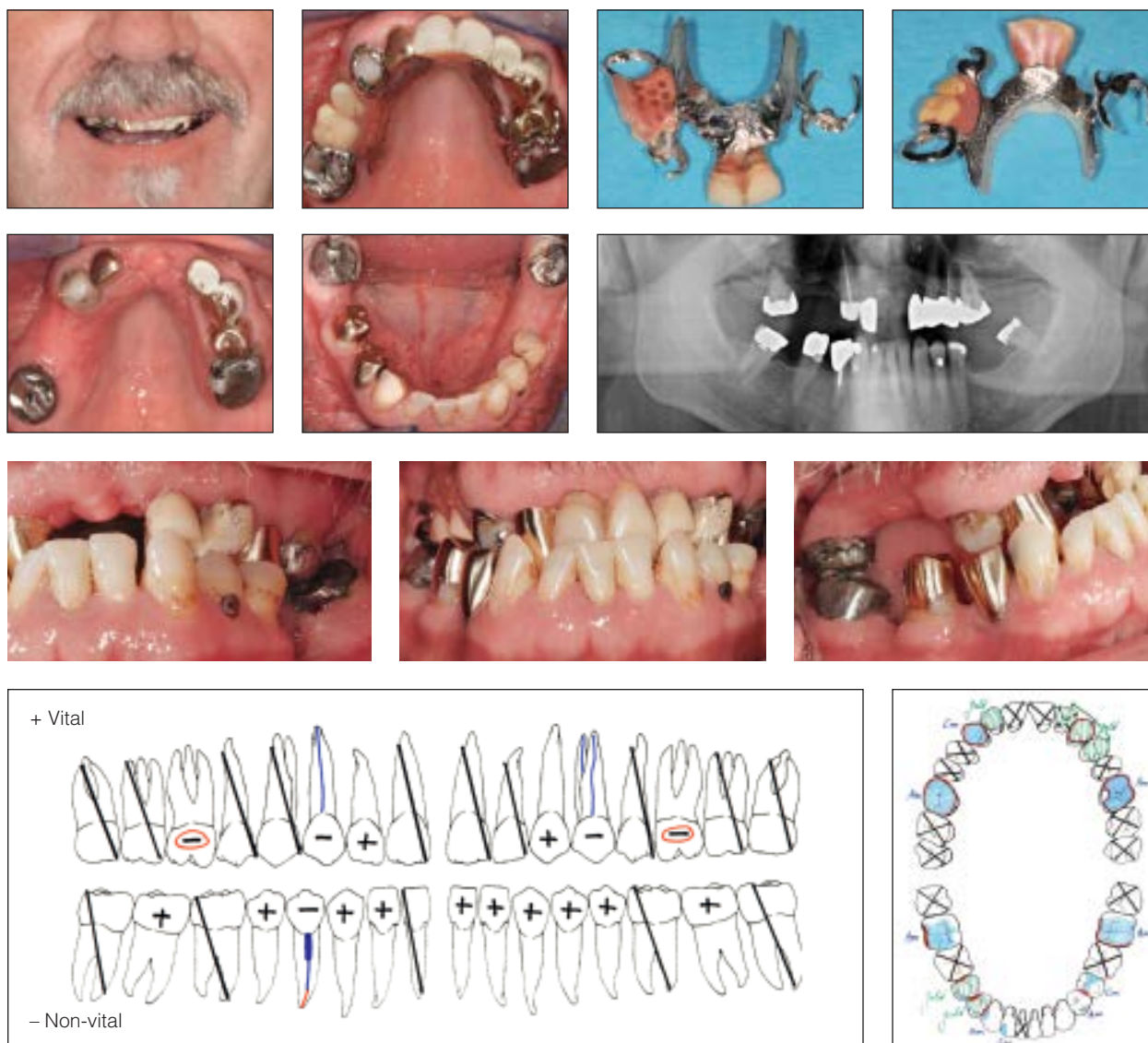
## Case History 2

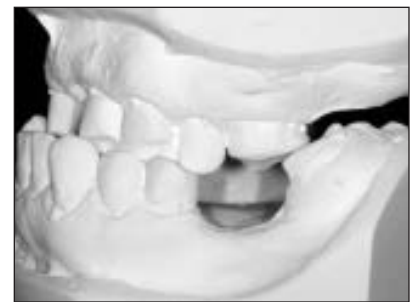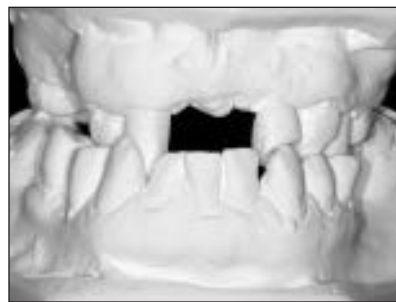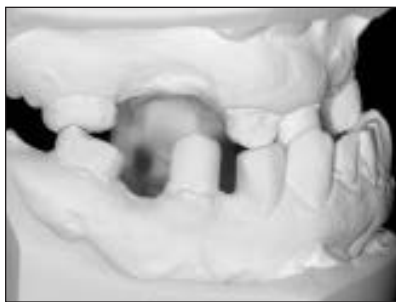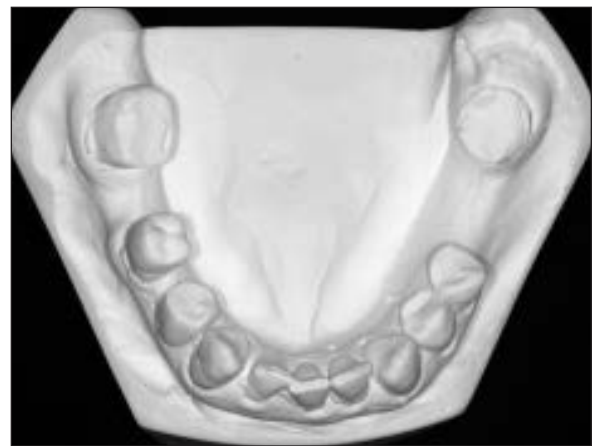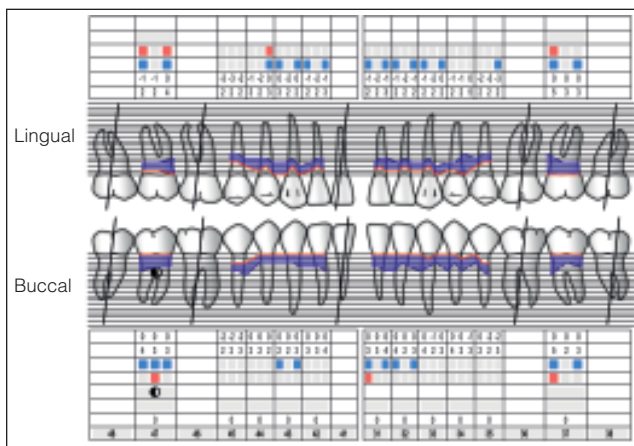
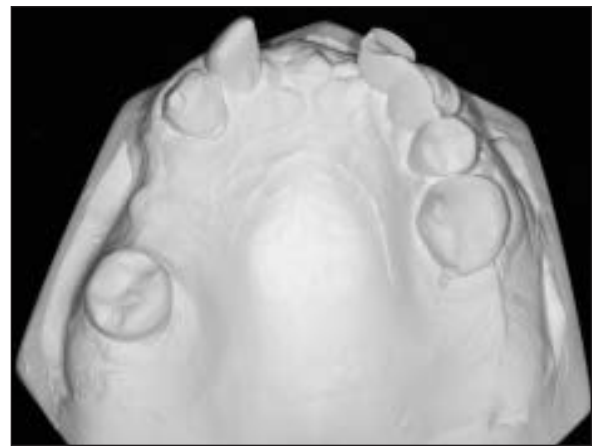
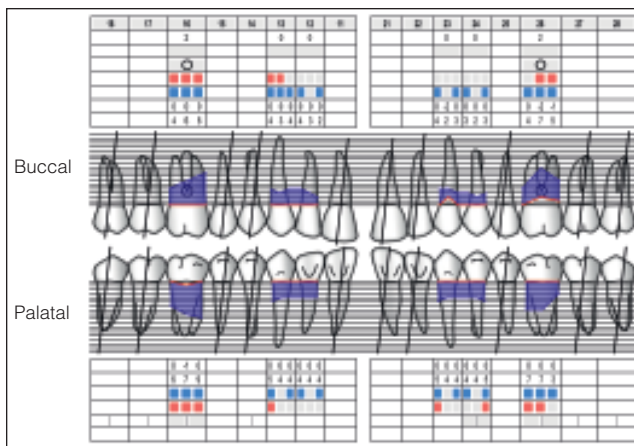
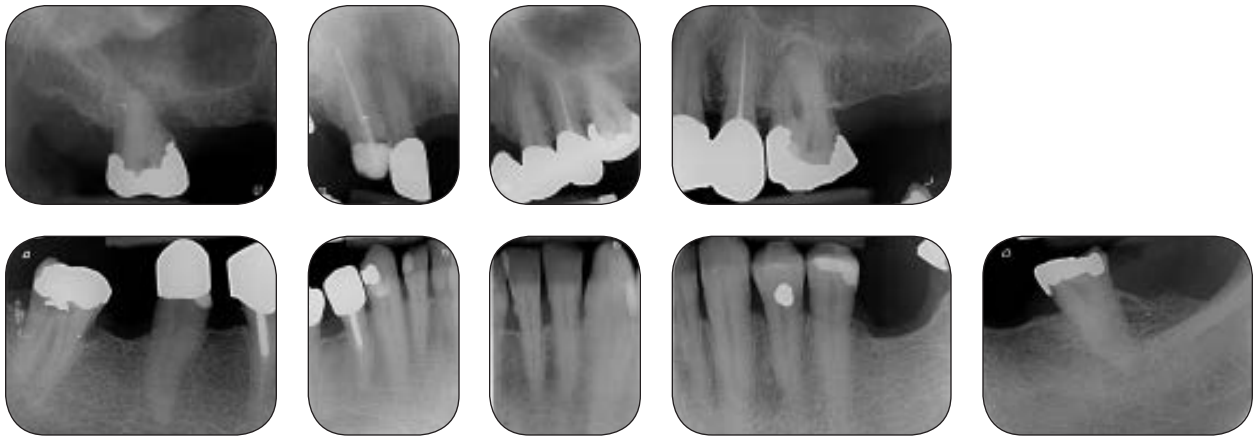
This patient, RL, is a healthy, asymptomatic, and recently retired 60-year-old male. His past international sales job precluded regular dental care; he now requests optimal dental treatment to make up for his many years of oral health neglect. He is dissatisfied with the appearance of his teeth and what he describes as an “over closed bite.”

His medical history reveals no significant findings and he reports no problems with his choice of foods

or their mastication. He has emphasized that, above all, he would like to undergo the best treatment possible since he now has both the time and the money to seriously address his oral health needs.

He recently read about a popular dental implant therapy called “Teeth in a Day” in his local newspaper and wondered whether he would be a good candidate for the technique because he would like to avoid prolonged dental treatment.





Copyright of International Journal of Prosthodontics is the property of Quintessence Publishing Company Inc. and its content may not be copied or emailed to multiple sites or posted to a listserv without the copyright holder's express written permission. However, users may print, download, or email articles for individual use.