

Dimensional ridge alterations following tooth extraction. An experimental study in the dog

Mauricio G. Araújo^{1,2} and Jan Lindhe²

¹Department of Periodontology, State University of Maringa, Maringa, Brazil;

²Department of Periodontology, Sahlgrenska Academy at Göteborg University, Göteborg, Sweden

Araújo MG, Lindhe J: Dimensional ridge alterations following tooth extraction. An experimental study in the dog. J Clin Periodontol 2005; 32: 212–218. doi: 10.1111/j.1600-051X.2005.00642.x. © Blackwell Munksgaard, 2005.

Abstract

Objective: To study dimensional alterations of the alveolar ridge that occurred following tooth extraction as well as processes of bone modelling and remodelling associated with such change.

Material and Methods: Twelve mongrel dogs were included in the study. In both quadrants of the mandible incisions were made in the crevice region of the 3rd and 4th premolars. Minute buccal and lingual full thickness flaps were elevated. The four premolars were hemi-sected. The distal roots were removed. The extraction sites were covered with the mobilized gingival tissue. The extractions of the roots and the sacrifice of the dogs were staggered in such a manner that all dogs contributed with sockets representing 1, 2, 4 and 8 weeks of healing. The animals were sacrificed and tissue blocks containing the extraction socket were dissected, decalcified in EDTA, embedded in paraffin and cut in the buccal–lingual plane. The sections were stained in haematoxyline–eosine and examined in the microscope.

Results: It was demonstrated that marked dimensional alterations occurred during the first 8 weeks following the extraction of mandibular premolars. Thus, in this interval there was a marked osteoclastic activity resulting in resorption of the crestal region of both the buccal and the lingual bone wall. The reduction of the height of the walls was more pronounced at the buccal than at the lingual aspect of the extraction socket. The height reduction was accompanied by a ‘horizontal’ bone loss that was caused by osteoclasts present in lacunae on the surface of both the buccal and the lingual bone wall.

Conclusions: The resorption of the buccal/lingual walls of the extraction site occurred in two overlapping phases. During phase 1, the bundle bone was resorbed and replaced with woven bone. Since the crest of the buccal bone wall was comprised solely of bundle this modelling resulted in substantial vertical reduction of the buccal crest. Phase 2 included resorption that occurred from the outer surfaces of both bone walls. The reason for this additional bone loss is presently not understood.

Key words: bundle bone; modelling; remodelling; wound healing

Accepted for publication 5 May 2004

The alveolar process is a tooth dependent tissue that develops in conjunction with the eruption of the teeth. Further, the volume as well as the shape of the alveolar process is determined by the form of the teeth, their axis of eruption and eventual inclination (Schroeder 1986). Subsequent to the removal of all teeth in the adult individual, the alveolar processes will undergo atrophy

(e.g. Atwood 1957, Hedegård 1962, Tallgren 1972). The amount of hard tissue reduction varied considerably between subjects as reported by e.g. Atwood (1962), Carlsson & Persson (1967) and Tallgren (1972).

Clinical and/or radiographic studies by e.g. Johnson (1963, 1969), Pietrokovski & Massler (1967), Lekovic et al. (1997, 1998), Camargo et al. (2000),

Schropp et al. (2003) have demonstrated that marked alterations of the height and width of the alveolar ridge will occur following single or multiple tooth extractions. The healing process following tooth removal apparently resulted in more pronounced resorption on the buccal than on the lingual/palatal aspects of the ridge. Pietrokovski & Massler (1967) studied the amount of

tissue that was lost after unilateral tooth extraction and used plaster casts models for the dimensional assessments. The authors concluded that the buccal bone plates both in the maxilla and the mandible were resorbed considerably more than the corresponding palatal/lingual bone walls and that the center of the ridge, as a consequence, shifted palatally/lingually.

Further, the process that resulted in tissue reduction seemed to be more pronounced during the initial phase of wound healing than during later periods following tooth removal. Johnson (1969) reported that most of the dimensional alterations – horizontal as well as vertical – of the alveolar ridge took place during the first 3 months of healing. In a recent clinical study Schropp et al. (2003) estimated bone healing and soft-tissue contour changes following single-tooth extraction. They included 46 patients in their study and made assessment 3, 6 and 12 months following the removal of one premolar or one molars. Schropp et al. (2003) stated that “approximately two thirds of this reduction ‘... the width of the alveolar ridge ...’ occurred within the first 3 months after tooth extraction”.

The process of healing that occurred following tooth removal was monitored in biopsies sampled from extraction sites in man (e.g. Boyne 1966, Amler 1969, Evian et al. 1982) as well as experimental animals (e.g. Huebsch & Hansen 1969, Kuboki et al. 1988, Lin et al. 1994). In a recent study in the dog, Cardaropoli et al. (2003) studied bone modelling and remodelling that occurred within the extraction socket following the removal of the distal root of mandibular premolars. From the examination of mesio-distal sections it was observed that (i) woven bone filled the extraction socket after one month, (ii) a cortical ridge including woven and lamellar bone had formed after 3 months, (iii) after the 3 month interval woven bone was gradually replaced with lamellar bone and marrow. In the study referred to no information was provided regarding bone tissue alteration that occurred outside the extraction socket.

The objective of the present experiment in the dog was to study some dimensional alterations of the alveolar ridge that occurred following tooth extraction as well as processes of bone modelling and remodelling associated with such change.

Material and Methods

The research protocol was approved by the ethical committee of the University of Maringa. Twelve mongrel dogs about 1-year-old and weighting about 10 kg each were used in the study. During surgical procedures, the animals were anaesthetized with intravenously administered Pentothal Natrium® (30 mg/ml; Abbot Laboratories, Chicago, IL, USA). Throughout the experiment the animals were fed a soft-pellet diet.

In both quadrants of the mandible incisions were made in the crevice region of the 3rd and 4th mandibular premolars. Minute buccal and lingual full thickness flaps were elevated to disclose the marginal alveolar bone. The four premolars were hemi-sectioned. The pulp of each mesial root was extirpated and the canal filled with guttapercha. The distal roots were carefully removed using elevators and forceps. The extraction sites were covered with the mobilized gingival tissue and stabilized with interrupted sutures (Fig. 1). The dogs were placed on a plaque control regimen that included tooth cleaning three times per week.

The extractions of the roots were staggered in a randomized way and in such manner that at sacrifice all dogs contributed with extraction sites representing 1, 2, 4 and 8 weeks of healing. The animals were sacrificed with an overdose of Pentothal Natrium® and perfused, through the carotid arteries, with a fixative containing a mixture of 5% glutaraldehyde and 4% formaldehyde (Karnovsky 1965). The mandibles were removed and tissue blocks containing the extraction socket of the distal root of each premolar were dissected and placed in the fixative. Each block was decalcified in EDTA, dehydrated in increasing concentrations of ethanol, embedded in paraffin and cut in the buccal-lingual plane. The sections were stained

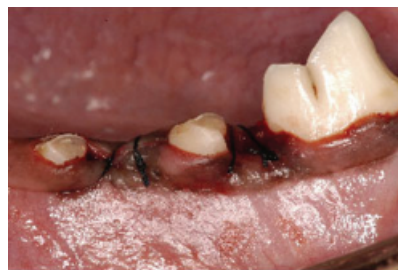

Fig. 1. Clinical view of the experimental sites immediately after root extraction and placement of sutures.

in haematoxyline–eosine. Sections representing the central portion (in mesial-distal direction) of each extraction socket were selected and examined in the microscope.

Histological examination

The tissue within the extraction socket was examined using a Leitz® DM-RBE Microscope (Leica, Wetzlar, Germany) equipped with an image system (Q-500 MC®; Leica).

Histometric measurements

The height of the cortical bone walls was determined in the following way (Fig. 2): a line parallel to the long axis of the root was drawn in the center of the socket (C–C) to separate the buccal and lingual compartments. Subsequently, horizontal lines (L and B) perpendicular to C–C were drawn to connect the most coronal portions of the buccal and lingual bone crest to C–C. The vertical distance between the buccal and lingual intersections with C–C was measured and expressed in mm.

The width of the buccal and lingual bone walls was determined at three different levels; A, B and C (Fig. 2) and expressed in mm. The levels were located at 1, 3, and 5 mm, respectively, apical of the buccal and lingual bone crest.

Mean values and standard deviations were calculated for each variable, site and group.

Results

All extraction sockets healed uneventfully. Overt signs of soft-tissue inflammation (swelling and redness) were seen in sites representing 1 week of healing,

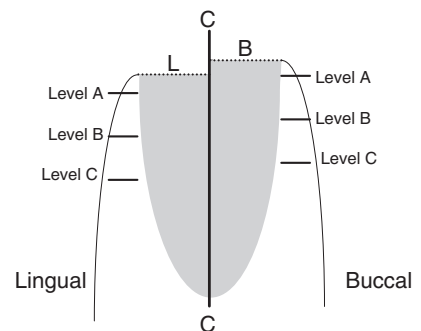


Fig. 2. Schematic drawing representing the location where the histometric measurements were performed. For detailed information, see text.

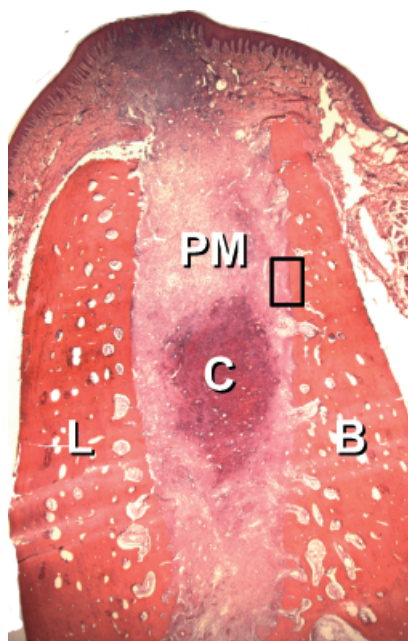


Fig. 3. Overview of the extraction site after 1 week of healing. Note the large amounts of provisional matrix and, in the center of the socket, remaining blood clot. BC, blood clot; B, buccal; L, lingual; PM, provisional matrix. H&E staining; original magnification $\times 16$.

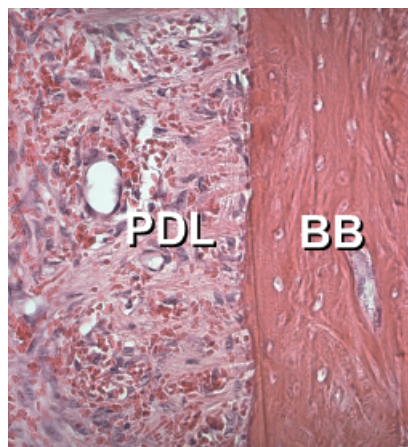


Fig. 4. Higher magnification of outlined area in Fig. 3. The bundle bone covered the socket wall. Lateral to the bundle bone a severed periodontal ligament can be identified. BB, bundle bone; PDL, severed periodontal ligament; original magnification $\times 200$.

but the mucosa covering the sockets after 2, 4 and 8 weeks of healing were considered to be clinically healthy.

One week of healing (Fig. 3)

The connective tissue of the mucosa covering the extraction site exhibited

Table 1. Width of the bone tissue at the buccal and lingual walls of the extraction sites

	1 week		2 weeks		4 weeks		8 weeks	
	buccal	lingual	buccal	lingual	buccal	lingual	buccal	lingual
Level A	0.6 (0.1)	1.4 (0.2)	0.6 (0.1)	1.3 (0.3)	0.7 (0.2)	1.3 (0.1)	0.5 (0.1)	1.2 (0.1)
Level B	1.3 (0.1)	2.0 (0.3)	1.1 (0.3)	1.9 (0.4)	1.1 (0.2)	1.6 (0.1)	1.1 (0.1)	1.7 (0.3)
Level C	2.0 (0.0)	2.8 (0.8)	1.9 (0.4)	2.7 (0.7)	2.0 (0.4)	2.9 (0.3)	1.6 (0.1)	2.7 (0.5)

The measurements (mm) were made at different levels (A, B, C; Fig. 1) and time intervals. Mean (SD).

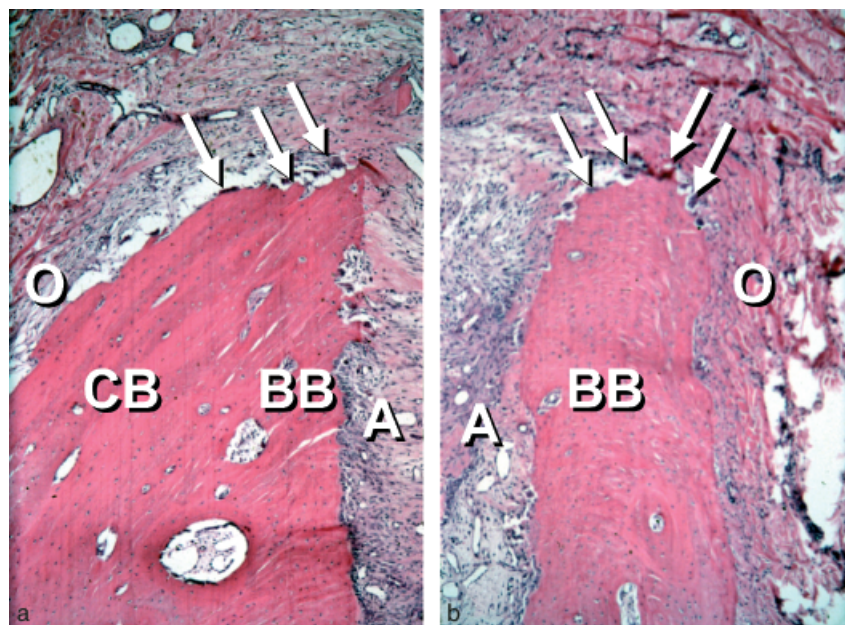


Fig. 5. One week of healing. The crestal region of the lingual (a) and buccal (b) walls. The buccal bone crest is made exclusively of bundle bone while the lingual crest is comprised of a mixture of cortical bone and bundle bone. Note the presence of osteoclasts in the crestal regions of both walls (arrows). A, inner surface of the bone wall; BB, bundle bone; CB, cortical bone; O, outer surface of the bone wall; arrows, osteoclasts. H&E staining; original magnification $\times 50$.

modest signs of inflammation. Thus, areas could be identified which were poor in their collagen content but rich in vascular structures and inflammatory cells.

The marginal portion of the lingual bone wall of the extraction socket was markedly wider than the corresponding portion of the buccal wall (Fig. 3). At Level A (Table 1) the lingual wall was 1.4 ± 0.2 mm (SD) wide while the corresponding width of the buccal wall was 0.6 ± 0.1 mm. The matching dimensions at Level B were 2.0 ± 0.3 and 1.3 ± 0.1 mm, respectively.

Both the buccal and lingual bone walls contained large numbers of well-defined bone marrow spaces. The inner surfaces of the socket walls were lined with bundle bone (Fig. 4). In all areas of the socket, multinucleated cells (osteoclasts) could occasionally be observed

on the surface of this bundle bone. A severed periodontal ligament that included fibroblasts, distinctly orientated collagen fibers, vascular structures and inflammatory cells resided lateral to the bundle bone.

The crestal regions of the bone walls were comprised solely of bundle bone (Fig. 5a, b), the height of which was more pronounced at the buccal (≥ 1 mm) than at the lingual wall (< 0.5 mm). A large number of osteoclasts were present on the outer surface of the crestal region of both bone walls.

The internal portion of the extraction socket was occupied by coagulum, granulation tissue, provisional matrix and small amounts of newly formed bone. The coagulum resided in the most central portion of the socket and exhib-

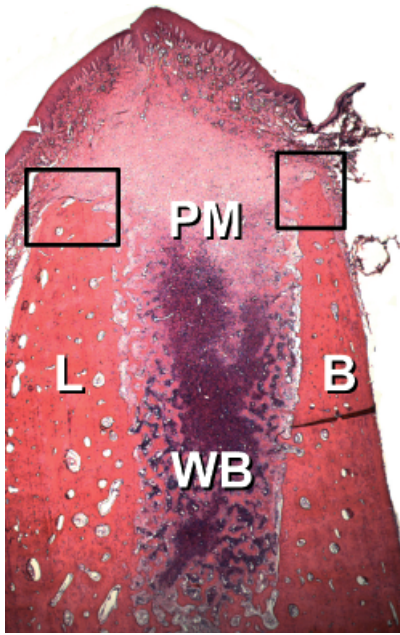


Fig. 6. Overview of the extraction site after 2 weeks of healing. Note the large amounts of woven bone are presented in the lateral and apical portions of the socket. B, buccal; L, lingual; PM, provisional matrix; WB, woven bone. H&E staining; original magnification $\times 16$.

ited signs of lysis. The granulation tissue that included a large number of vessels, few fibroblasts and inflammatory cells occupied a portion of the more coronal segments of the socket. The provisional matrix was the dominating tissue within the socket and included fibroblasts, newly formed vessels and collagen fibers. In the apical portions of the socket, small islands of newly formed woven bone were present around vascular units close to the bundle bone.

Two weeks of healing (Fig. 6)

The mucosa of the site was devoid of inflammatory cells but included a fibroblast rich connective tissue. The crestal region of the lingual hard-tissue wall was at this interval devoid of bundle bone while at the corresponding region of the buccal wall, bundle bone occupied an area that was 0.3 ± 0.1 mm high (Fig. 7a, b). The outer portions of the crestal region of both bone walls were lined with osteoclasts. Several osteoclasts were also found on the outer surface of the buccal and lingual bone walls apical of the crestal region.

Large amounts of newly formed bone occurred in the apical and lateral

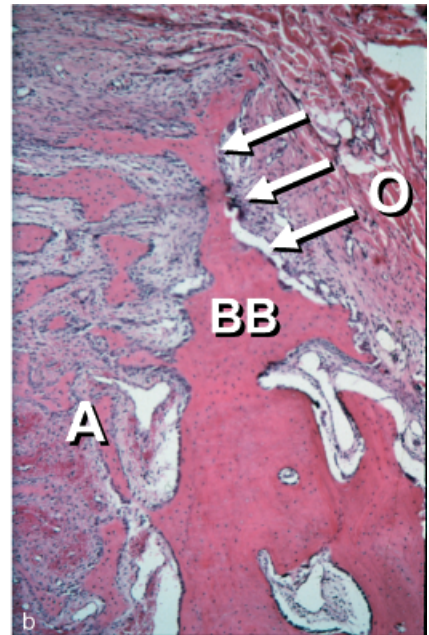
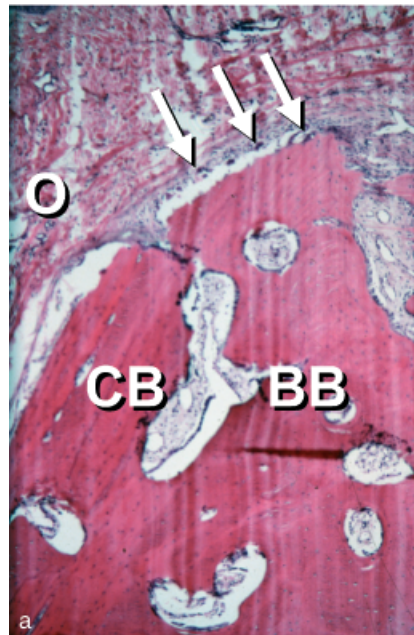


Fig. 7. Two weeks of healing. The crestal region of the lingual (a) and buccal (b) walls. Note the large number of osteoclasts present on the outer surface of the crestal regions. A, inner surface of the wall; BB, bundle bone; CB, cortical bone; O, outer surface of the wall; arrows, osteoclasts. H&E staining; original magnification $\times 50$.

portions of the extraction socket. Provisional matrix tissue resided in the central and marginal compartments of the experimental site. At this interval, no periodontal ligament tissue could be identified lateral to the socket walls. The surface of the woven bone was lined with densely packed osteoblasts and included a primitive bone marrow. Most of the surface of the remaining bundle bone was in direct continuity with trabeculae of woven bone.

Four weeks of healing (Fig. 8)

No bundle bone could be found in the crestal region of the bone walls. Further, in the crestal region of the buccal wall, a large portion of the lamellar bone had apparently been replaced with woven bone. The surface of this newly formed tissue exhibited signs of remodelling. A multitude of osteoclasts could be observed on the outer surface of both the buccal and the lingual bone walls apical of the crestal regions.

The lingual bone wall was at this interval between 1.3 ± 0.1 mm (Level A) and 1.6 ± 0.1 mm (Level B) wide. The corresponding dimensions of the buccal wall were 0.7 ± 0.2 and 1.1 ± 0.2 mm, respectively (Table 1).

Provisional matrix tissue was presented in the most central portions of

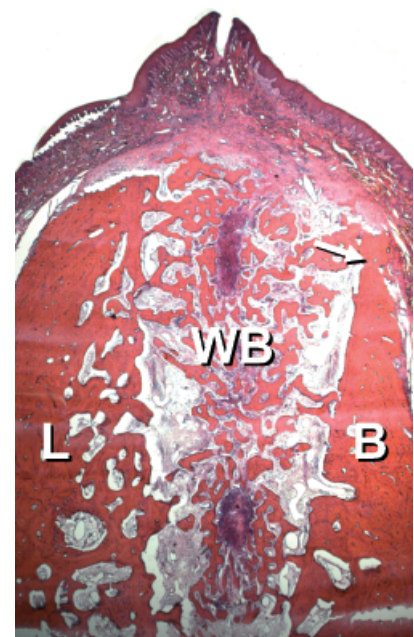


Fig. 8. Overview of the extraction site after 4 weeks of healing. Note the extraction site at this interval is dominated by newly formed woven bone. The bundle bone of the crestal region of the buccal wall was resorbed and partially replaced by woven bone. Note also that the marginal portion of the old buccal wall (arrow) is "apical" to its lingual counterpart. B, buccal; L, lingual; WB, woven bone; arrow, marginal portion of the old buccal wall. H&E staining; original magnification $\times 16$.

the socket. Mineralized tissue and bone marrow occupied the remaining segments of the site. The mineralized tissue portion was mainly comprised of woven bone, which appeared to be in the process of both modelling and remodelling. The bone marrow was either of primitive (loose connective tissue, inflammatory cells and large vessels) or mature (large adipocytes, few inflammatory cells, small amounts of collagen fibers and vascular units) character. Large portions of the bundle bone had apparently been replaced by lamellar bone and marrow.

Eight weeks of healing (Fig. 9)

The lingual bone wall was also at this interval considerably wider than the buccal wall. Further, the crest of the buccal bone was located about 2 mm apical to the crest of the lingual hard tissue wall. A wide zone of mineralized tissue bridged the buccal and lingual bone walls of the extraction socket. This bridge that had an oblique orientation included woven bone as well as lamellar bone. Numerous osteoclasts were found both on the outer surface of the crestal and on more apical regions of the buccal bone (Fig. 10). Scattered osteoclasts were found in the corresponding locations of the lingual bone wall. The internal portion of the socket region was occupied by bone marrow but included few trabeculae of mineralized tissue that were comprised of woven bone and lamellar bone.

Alterations of the height of the bone crest during healing

At the 1-week interval, the buccal bone crest was found to be located on the average 0.3 ± 0.2 mm (SD) "coronal" to the lingual crest, while at the 2-, 4-, and 8-week intervals the buccal crest was consistently located "apical" of its lingual counterpart (Fig. 11). Thus, after 2 weeks of healing the distance between intercept B and intercept L (Fig. 2) was 0.3 ± 0.1 mm. The corresponding distances after 4 and 8 weeks of healing were 0.9 ± 0.3 and 1.9 ± 0.2 mm.

Alterations of the width of the bone crest during healing

The width of the buccal and lingual bone walls at Levels A, B, and C is described in Table 1.

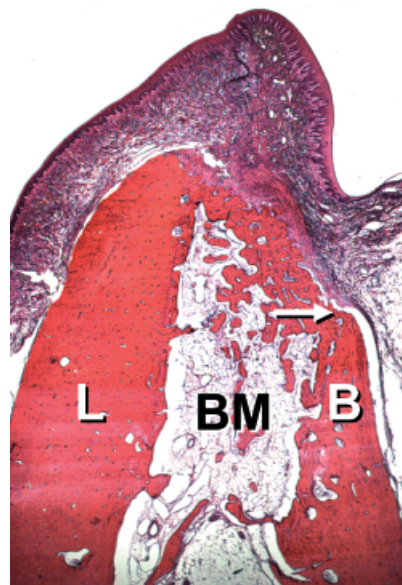


Fig. 9. Overview of the extraction site after 8 weeks of healing. The entrance of the socket is sealed by a hard tissue ridge that is comprised of woven bone and lamellar bone. The central portion of the socket is dominated by bone marrow. Note that the marginal portion of the buccal wall (arrow) is about 2 mm "apical" of the marginal termination of the lingual wall. B, buccal; BM, bone marrow; L, lingual; arrow, marginal portion of the buccal wall. H&E staining; original magnification $\times 16$.

At all four examination intervals and at each of the three levels, the buccal bone wall was thinner than the lingual bone wall. Further, the width of both the buccal and the lingual bone walls was greater at Level B than at Level A and greater at Level C than at Level B.

Discussion

The present experiment demonstrated that marked dimensional alterations occurred during the early phase – 8 weeks – following the extraction of mandibular premolars. Thus, in this interval there was a marked osteoclastic activity resulting in resorption of the crestal region of both the buccal and the lingual bone wall. The reduction of the height of the walls was more pronounced at the buccal than at the lingual aspect of the extraction socket.

The observation that following tooth extraction the amount of vertical bone loss became more pronounced on the buccal than on the lingual socket wall is in agreement with previous clinical

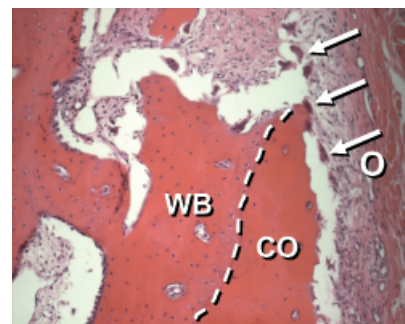


Fig. 10. Eight weeks of healing at the crestal buccal bone wall. Note the large number of osteoclasts (arrows) that are present on the surface of the old cortical bone. The woven bone is in the process of remodelling. CO, old cortical bone; WB, newly formed woven bone; O, outer surface of the wall; arrows, osteoclasts; dotted line, borderline between the woven bone and the old cortical bone. H&E staining; original magnification $\times 200$.

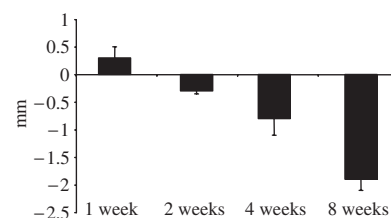


Fig. 11. Histogram describing the vertical distance between the buccal and lingual intersections with C-C (Fig. 2). At 1 week the buccal crest was located "coronal" of the lingual crest, but after 2, 4, and 8 weeks of healing the buccal crest was consistently "apical" of its lingual counterpart.

studies (e.g. Johnson 1963, 1969, Pietrovski & Massler 1967, Schropp et al. 2003). The current findings are also in agreement with data recently published by Botticelli et al. (2004). They assessed dimensional alterations that occurred in the alveolar ridge during a 4-month period following implant placement in fresh extraction sockets. The distance between the implant surface and the buccal and lingual/palatal bone walls was measured at baseline and at re-entry after 4 months. The authors concluded, "during the 4-month interval following tooth extraction the buccal bone dimension had undergone horizontal resorption that amounted to about 56%. The corresponding reduction of the lingual/palatal bone wall was 30%".

In preparation for removal of the distal roots, crevice incisions were made

and minute full thickness flaps were elevated at both the buccal and lingual aspects of the alveolar process. It is well known that such surgical trauma that includes the separation of the periosteum and the rupture of its connective tissue attachment at the bone surface will induce an acute inflammatory response which in turn will mediate resorption of the surface layer of the alveolar bone in the exposed area (e.g. Wilderman 1963, Staffileno et al. 1966, Wood et al. 1972, Bragger et al. 1988). In specimens representing 1 and 2 weeks of healing in the present experiment, osteoclasts were indeed present in the exposed area of the alveolar ridge, which exhibited signs of surface resorption. There are reasons to suggest that this hard-tissue resorption may in part explain the dimensional alterations that occurred during the first weeks of healing following tooth removal.

In the current experiment, the alteration of the level of the buccal bone crest over time was determined using the lingual crest as reference. Since during the course of healing there was also marked resorption of the lingual bone, the change reported for the buccal bone crest is most likely underestimated. The relative reduction of the height of the buccal bone wall between the 1- and 8-week intervals was 2.2 ± 0.2 mm, i.e. about $45 \mu\text{m/day}$. This rate of bone resorption is similar to that reported from experiments evaluating modelling and remodelling events at fracture sites in the long bones of dogs. Thus, Schenk & Hunziker (1994) stated that "In adult canine bone, the osteoclastic resorption rate is about $50\text{--}60 \mu\text{m/day}$. . .". In this context it should be realized that in the 8-week specimens of the current experiment, a large number of osteoclasts could be identified both on the buccal and on the lingual bone walls. In other words, the process of modelling was at the end of this study not completed. This is in agreement with findings from similar experiments presented by Cardaropoli et al. (2003). They studied dynamics of bone tissue formation in tooth extraction sites in the dog and reported that between 2 and 6 months of healing substantial portions of woven bone within the extraction socket were replaced with lamellar bone and marrow.

The tooth is anchored to the jaws via the bundle bone into which the periodontal ligament fibers invest. Following the removal of a tooth, the bundle bone

at the site obviously will lose its function and disappear. In the 1-week specimens of the current sample, it was observed that the crestal region of the buccal hard tissue wall was made up exclusively of bundle bone while the corresponding region of the lingual bone was comprised of a combination of bundle bone and lamellar bone. Bundle bone, inside the socket as well as in the crestal regions could be found in the experimental sites at 1 and 2 weeks but was not present in specimens representing 4–8 weeks of healing. This is in agreement with Cardaropoli et al. (2003) who demonstrated that already 2 weeks following the removal of a mandibular premolar, most of the bundle bone at the mesial and distal aspects of the extraction socket had been replaced with woven bone. Hence, the early resorption of the bundle bone may in part explain the marked reduction of the height of the buccal wall that occurred between week 1 and week 4 of healing.

Between 4 weeks and 8 weeks of healing there was not only pronounced alteration of the tissue within the extraction socket but also substantial additional alteration of the dimensions of the alveolar process of the extraction site. Thus in this interval (i) a cortical ridge was formed that sealed the entrance of the extraction site and (ii) woven bone was to a large extent replaced by lamellar bone and marrow. During this second month of healing there was a further reduction of (i) the height of the buccal bone wall as well as (ii) the width of both the buccal and lingual walls.

From the data presented in this study it may be concluded that the resorption of the buccal/lingual walls of the extraction site occurred in two overlapping phases. During phase 1, the bundle bone that lost its function following the removal of the tooth, was resorbed and replaced with woven bone. Since the crest of the buccal bone wall was comprised solely of bundle bone this modelling resulted in substantial vertical reduction of the buccal crest. Phase 2 included resorption that occurred from the outer surfaces of both bone walls. The reason for this additional bone loss is presently not understood. It is suggested, however, that following elevation of the mucoperiosteal flap in conjunction with tooth extraction, the blood vessels to the bone walls were severed. The reduced blood

supply (for a review see Schenk & Hunziker 1994) may have caused death of the osteocytes and as a consequence necrosis of the surrounding mineralized tissue of the bone walls. During phase 2 of healing this necrotic bone may therefore gradually have been eliminated through surface resorption orchestrated by osteoclasts in the periosteum. Since the buccal bone plate was considerably thinner than the lingual plate, this "horizontal resorption" may also cause "vertical reduction" of the buccal wall. Given that, however, marked dimensional alteration of the extraction also occurs following tooth removal without flap elevation, other factors must be involved in bone resorption that takes place in phase 2 of modelling. Such factors may include (i) adaptation to continued lack of function at the extraction site, (ii) tissue adjustment to meet "genetically" determined demands regarding ridge geometry in the absence of teeth.

References

- Amler, M. H. (1969) The time sequence of tissue regeneration in human extraction wounds. *Oral Surgery, Oral Medicine and Oral Pathology* **27**, 309–318.
- Atwood, D. A. (1957) A cephalometric study of the clinical rest position of the mandible. Part II. The variability in the rate of bone loss following the removal of occlusal contacts. *Journal of Prosthetic Dentistry* **7**, 544–552.
- Atwood, D. A. (1962) Some clinical factors related to the rate of resorption of residual ridges. *Journal of Prosthetic Dentistry* **12**, 441–450.
- Botticelli, D., Berglundh, T. & Lindhe, J. (2004) Hard tissue alterations following immediate implant placement in extraction sites. *Journal of Clinical Periodontology* **31**, in press.
- Boyne, P. J. (1966) Osseous repair of the postextraction alveolus in man. *Oral Surgery, Oral Medicine and Oral Pathology* **21**, 805–813.
- Bragger, U., Pasqualli, L. & Kornman, K. S. (1988) Remodeling of interdental alveolar bone after periodontal flap procedure assessed by means of computer-assisted densitometer image analysis (CADIA). *Journal of Clinical Periodontology* **15**, 558–564.
- Camargo, P. M., Lekovic, V., Weinlaender, M., Klokkevold, P. R., Kenney, E. B., Dimitrijevic, B., Nedic, M., Jancovic, S. & Orsini, M. (2000) Influence of bioactive glass on changes in alveolar process dimensions after exodontia. *Oral Surgery, Oral Medicine, Oral pathology, Oral Radiology and Endodontics* **90**, 581–586.
- Cardaropoli, G., Araújo, M. & Lindhe, J. (2003) Dynamics of bone tissue formation in tooth extraction sites. An experimental study in

- dogs. *Journal of Clinical Periodontology* **30**, 809–818.
- Carlsson, G. E. & Persson, G. (1967) Morphologic changes of the mandible after extraction and wearing of dentures. A longitudinal, clinical, and X-ray cephalometric study covering 5 years. *Odontologisk Revy* **18**, 27–54.
- Evian, C. I., Rosenberg, E. S., Cosslet, J. G. & Corn, H. (1982) The osteogenic activity of bone removed from healing extraction sockets in human. *Journal of Periodontology* **53**, 81–85.
- Hedegård, B. (1962) Some observations on tissue changes with immediate maxillary dentures. *Dental Practitioner* **13**, 70–78.
- Huebsch, R. F. & Hansen, L. S. (1969) A histopathologic study of extraction wounds in dogs. *Oral Surgery, Oral Medicine and Oral Pathology* **28**, 187–196.
- Johnson, K. (1963) A study of the dimensional changes occurring in the maxilla after tooth extraction. Part I. Normal healing. *Australian Dental Journal* **8**, 428–433.
- Johnson, K. (1969) A study of the dimensional changes occurring in the maxilla following tooth extraction. *Australian Dental Journal* **14**, 241–244.
- Karnovsky, M. J. (1965) A formaldehyde-glutaraldehyde fixative of high osmolarity for use in electron microscopy. *Journal of Cell Biology* **27**, 137A–138A.
- Kuboki, Y., Hashimoto, F. & Ishibashi, K. (1988) Time-dependent changes of collagen crosslinks in the socket after tooth extraction in rabbits. *Journal of Dental Research* **67**, 944–948.
- Lekovic, V., Camargo, P. M., Klokkevold, P. R., Weinlaender, M., Kenney, E. B., Dimitrijevic, B. & Nedic, M. (1998) Preservation of alveolar bone in extraction sockets using bioabsorbable membranes. *Journal of Periodontology* **69**, 1044–1049.
- Lekovic, V., Kenney, E. B., Weinlaender, M., Han, T., Klokkevold, P., Nedic, M. & Orsini, M. (1997) A bone regenerative approach to alveolar ridge maintenance following tooth extraction. Report of 10 cases. *Journal of Periodontology* **68**, 563–570.
- Lin, W. L., McCulloch, C. A. & Cho, M. I. (1994) Differentiation of periodontal ligament fibroblasts into osteoblasts during socket healing after tooth extraction in the rat. *Anatomical Records* **1240**, 492–506.
- Petrokovski, J. & Massler, M. (1967) Alveolar ridge resorption following tooth extraction. *Journal of Prosthetic Dentistry* **17**, 21–27.
- Schenk, R. K. & Hunziker, E. B. (1994) Histologic and ultrastructural features of fracture healing. In: Brighton, C. T., Friedlaender, G. & Lane, J. M. (eds). *Bone Formation and Repair*, pp. 117–146. Rosemont, IL, USA: American Academy of Orthopaedic Surgeons.
- Schroeder, H. E. (1986) *The periodontium*. Berlin Heidelberg: Springer-Verlag.
- Schropp, L., Wenzel, A., Kostopoulos, L. & Karring, T. (2003) Bone healing and soft tissue contour changes following single-tooth extraction: a clinical and radiographic 12-month prospective study. *The International Journal of Periodontics & Restorative Dentistry* **23**, 313–323.
- Staffileno, H., Levy, S. & Gargiulo, A. (1966) Histologic study of cellular mobilization and repair following a periosteal retention operation via split thickness mucogingival flap surgery. *Journal of Periodontology* **37**, 117–131.
- Tallgren, A. (1972) The continuing reduction of the residual alveolar ridges in complete denture wearers: a mixed longitudinal study covering 25 years. *Journal of Prosthetic Dentistry* **27**, 120–132.
- Wilderman, M. N. (1963) Repair after a periosteal retention procedure. *Journal of Periodontology* **34**, 487–503.
- Wood, D. L., Hoag, P. M., Donnenfeld, O. W. & Rosenberg, D. L. (1972) Alveolar crest reduction following full and partial thickness flaps. *Journal of Periodontology* **43**, 141–144.

Address:
 Mauricio G Araújo
 Department of Dentistry
 State University of Maringa
 Av. Mandacarú, 1550
 CEP 87.080 Maringa
 PR-Brazil
 E-mail: odomar@hotmail.com

This document is a scanned copy of a printed document. No warranty is given about the accuracy of the copy. Users should refer to the original published version of the material.