

# Management of inter-dental/ inter-implant papilla

Laura Zetu<sup>1\*</sup> and Hom-Lay Wang<sup>2</sup>

<sup>1</sup>Private practice, Jackson; <sup>2</sup>Department of Periodontics/Prevention/Geriatrics, School of Dentistry, University of Michigan, Ann Arbor, MI, USA

Zetu L, Wang H-L. Management of inter-dental/inter-implant papilla. *J Clin Periodontol* 2005; 32: 831–839. doi: 10.1111/j.1600-051X.2005.00748.x. © Blackwell Munksgaard, 2005.

## Abstract

**Objectives:** The aims of this paper are to review and compare existing techniques for creation of interdental/interimplant papillae, to address factors that may influence its appearance and to present an approach that authors developed that could help clinicians to manage and recreate the interproximal papillae.

**Methods:** Papers related to interdental and interimplant papillae published over the last 30 years were selected and analyzed.

**Results:** Thorough treatment planning is essential for maintenance of the height of the interproximal papillae following tooth removal. The key for achieving an esthetically pleasing outcome is the clinicians' ability of properly managing/creating interdental/interimplant papillae. Bone support is the foundation for any soft tissue existence, techniques such as socket augmentation, orthodontic extrusion, guided bone regeneration, onlay graft and distraction osteogenesis are often used for this purpose. Soft tissue grafts as well as esthetic mimic restorations can also be used to enhance the esthetic outcomes.

**Conclusions:** An esthetic triangle is developed to address the foundations that are essential for maintaining/creating papilla. These include adequate bone volume, proper soft tissue thickness as well as esthetic appearing restorations.

Key words: bone grafts; dental implants; esthetic; guided bone regeneration; interdental/inter-implant papillae; monocortical bone graft; papillae; soft-tissue grafts

Accepted for publication 17 November 2004

Inter-dental papilla is the gingival portion, which occupies the space between two adjacent teeth. Morphologically, the papillae had been described first in 1959 by Cohen (1959). Before this time, interdental papilla was considered as a gingival trait having a pyramidal shape and functioning as a deflection of the interproximal food debris. Now it is clear that the physiology of the papilla is more complex. It not only acts as a biological barrier in protecting the periodontal structures, but also plays a critical role in the aesthetics. Hence, it is very important to respect papillary integrity during all dental procedures and to minimize as much as possible its disappearance.

Over the past 30 years, replacing missing teeth with dental implants

became a viable solution to fixed or removable prosthodontics (Brånemark et al. 1977, Adell et al. 1981, Esposito & Worthington 2003). Better understanding of the osseointegration process makes implant rehabilitation no longer a vehicle to restore lost masticatory and phonetic function, but it has become a multi-million industry driven by the bone augmentation, soft-tissue management and aesthetic restoration. Patients have come to expect aesthetically pleasing restorative treatments and have questioned the disappearance of inter-implant papillae (so-called "black triangles disease"). Therefore, many soft- and hard-tissue management techniques were developed to overcome this problem.

Numerous studies have attempted to determine the condition in which papilla would appear and ways to regenerate it. The aims of this review are to evaluate the factors that influence inter-dental/inter-implant papillae, to discuss and

compare techniques that are currently available and to present the approach that the authors developed that could help clinicians to manage/regenerate the inter-proximal papillae.

## Anatomy of the Inter-dental/Inter-implant Papilla

In order to understand the factors involved in maintaining the dental papilla, a systematic review of the anatomy is to be included. Gingiva is that part of the mucosa that has an intimate rapport with the dental elements, the interdental space and the alveolar bone. Topographically, the gingiva has been divided into three classic categories: free, attached and inter-dental gingiva. In fact, this subdivision is not needed since we describe gingiva as an anatomical and functional complex with a different shape and topography resulting from the

\*Formerly, Resident, Department of Periodontics/Prevention/Geriatrics, School of Dentistry, University of Michigan, Ann Arbor, MI, USA.

tissue adaptation around teeth (Schroeder & Listgarten 1997). Inter-dentally, the gingiva that occupies the space coronal to the alveolar crest is known as interdental gingiva. In the incisor area, it has a pyramidal shape with the tip located immediately beneath the contact point, it is narrower and it is referred to as a dental papilla. In the posterior region, it is broader and was formerly described as having a concave col or bridge shape (Cohen 1959). Moreover, the col is a valley-like depression, which connects the buccal and lingual papilla and takes the form of the inter-proximal contact. The borders of dental papilla are superiorly the base of the contact point between two adjoining teeth, inferiorly the alveolar crest and lateral borders delineated by the concave mesial and distal marginal gingiva of adjacent teeth (Fig. 1a and b). The inter-dental gingiva is attached to the tooth by connective tissue and junctional epithelium (JE) (Gargiulo et al. 1961) and it is lined in a coronal position by sulcular epithelium (Schroeder & Listgarten 1997).

### Factors Influencing the Presence of Papilla

#### Availability of underlying osseous support

The foundation for the gingival support is the underlying contour of the osseous crest. Ochsenein (1986) described the position of the inter-dental bone in relation to the radicular bone, which was named ‘positive architecture’. This term refers to the situations in which the osseous crest follows the shape of the cemento-enamel junctions (CEJs), has a scalloped contour and the position of the inter-proximal bone is more coronal than the radicular bone. In the posterior areas, the inter-dental bone forms a tent-shaped ‘col’ that is relatively flat bucco-lingually, while the anterior inter-dental bone has a pyramidal shape (Ochsenein 1986). Gargiulo et al. (1961) measured the distance from the CEJ to the alveolar bone and they found that an average of 2 mm comprised this distance (Gargiulo et al. 1961). When the authors looked at the differences of the osseous scallop from the facial to the inter-proximal, a range of 1.01–3.10 mm was described (Gargiulo et al. 1961). Therefore, it was hypothesized that the existence of this discrepancy of approximately 1.5 mm in bone height can be an important predictor for papillary appearance although it can-

not entirely explain the presence of the papilla (Spear 1999). Following this concept, it became evident that the soft tissue may play a crucial role in establishing the entire height of papilla. From the concept of biologic width, which, in natural teeth, defines the distance between the most extent of the gingival sulcus and the crest of the alveolar bone (Gargiulo et al. 1961), we learn that this space is occupied by gingival fibres, hemidesmosomes and connective tissue in direct contact with the tooth structure. This creates a natural seal around teeth protecting them from microbial invasion and traumatic insult. When comparing the depth of the dentogingival tissues between different tooth surfaces, Vacek et al. (1994) found that there were no significant differences

between the locations (mesial, distal, facial and lingual) for connective tissue or epithelial attachment (Vacek et al. 1994) (Table 1). Thus, the mere existence of a constant value of 2 mm of gingival tissue above the alveolar crest fails to explain by itself the 5 mm height (Tarnow et al. 1992, Salama et al. 1998) of the gingival scallop found in the case of the inter-dental papilla. However, Becker et al. (1997) measured the mean height from the alveolar crest to the inter-proximal bone and found that there is a statistically significant difference between individuals regarding the anatomical gingival scalloped contours (Becker et al. 1997). The authors emphasized the concept that a more pronounced gingival scallop had a higher level of

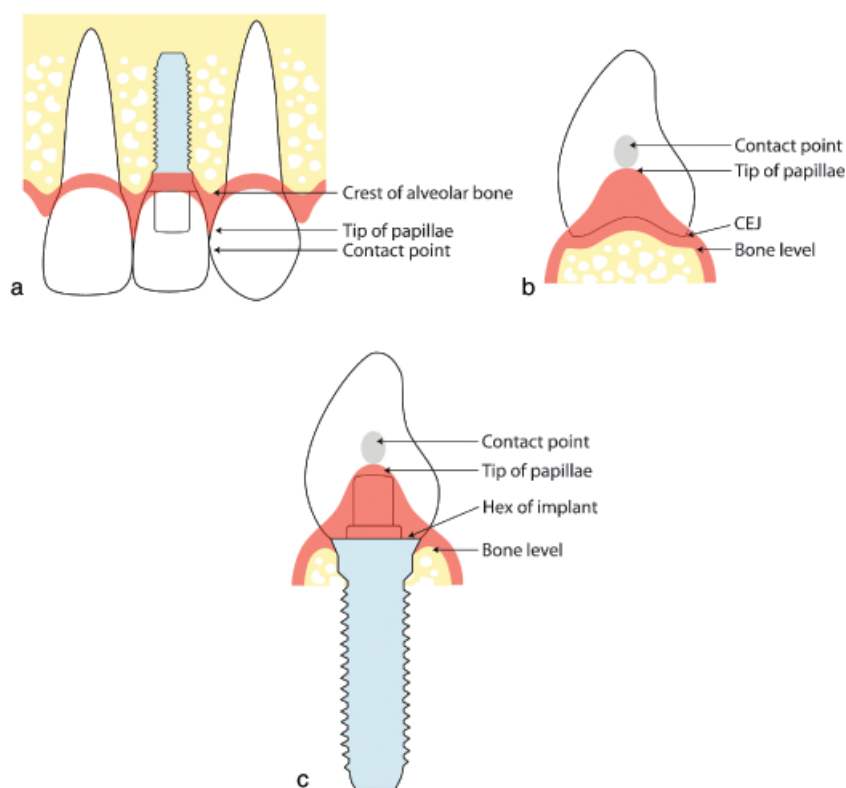


Fig. 1. (a) Inter-dental/Inter-implant papillae; (b) inter-proximal view of inter-dental papilla in natural tooth; (c) inter-proximal view of inter-dental papilla in implant.

Table 1. Biologic width around natural teeth and dental implants

	Teeth		Implants, Cochran (1997)
	Gargiulo et al. (1961)	Vacek et al. (1994)	
Sulcus depth (mm)	0.69	1.34	0.16
Junctional epithelium (mm)	0.97	1.14	1.88
Connective tissue (mm)	1.07	0.77	1.05
BW (mm)	2.04	1.91	3.08

the inter-dental bone when compared with a flatter gingival scallop (4.1 *versus* 2.1 mm). The concept of biological width has been applied to dental implants as well, with an epithelial attachment of approximately 2 mm (Cochran 1997) (Table 1). However, since most of the dental implants have a flat platform at the top, the implant is almost always positioned below the inter-implant bone crest (Fig. 1c). The location of the implant platform inter-dentally places the inter-proximal biologic width subcrestally, which differs from the one in natural teeth, which always forms supracrestally. Therefore, the inter-implant tissue lacks the crestal support which exists between an implant and a natural tooth or two adjacent implants.

Thus, it became obvious that other key factors, besides the bone level, may be involved in the papillary presence/absence. It was emphasized that the presence of adjacent tooth attachment and the volume of the gingival embrasure influence the papillary existence (Spear 1999, Kois 2001). Tarnow et al. (1992) examined the existence of interdental papillae in humans. The authors found that when the distance from the contact point to the alveolar bone was less or equal to 5 mm, the papilla was present in 98% of the times, while at 6 mm it dropped to 56% and at 7 mm it was only present 27% of the times. Hence, the authors concluded that the vertical height from the base of the contact to the crest of the bone is a key determining factor in maintaining the papillary between teeth.

When assessing the form and volume of the gingival embrasure occupied by the inter-proximal papilla, a certain lateral bone distance has to exist between the roots of two adjacent teeth in order to maintain the integrity status of the

dental papilla (Tal 1984, Heins & Wieder 1986). Teeth with root proximity (less than 0.5 mm inter-dental distance) possess very thin bone (Heins & Wieder 1986). In return, thin cancellous bone has a greater risk for resorption, decreasing the inter-proximal bone height and implicitly the papillary disappearance. Tal (1984) studied the inter-proximal distance of roots and the prevalence of infrabony defects. The author reported that only when the distance between roots was  $\geq 3.1$  mm, two separate infrabony defects were noted (Table 2). Therefore, it was speculated that for each individual root it would take at least 1.5 mm horizontal bone component to be lost in order to develop a vertical defect. This finding correlates with Waerhaug's opinion that there is a relatively consistent radius of destruction (1.78 mm) initiated by the advancing plaque front, which predisposes narrow areas of bone to horizontal bone loss and wider regions to vertical bone resorption (Waerhaug 1979a). Hence, it is easy to maintain inter-proximal bone height to facilitate the foundation of papillae. This implies that a minimal of 3 mm inter-dental distance may be needed in maintaining papillae. It was also suggested, that when root proximity is present, parallelism of the roots using orthodontic methods might be beneficial to support the inter-proximal gingival architecture (Salama & Salama 1993).

Concluding, the presence or absence of the papilla is influenced by more than one factor (e.g. crestal alveolar bone height, dimension of the inter-proximal space both horizontally and vertically, size and shape of the contact area) (Table 2). This calls for a judicious evaluation of the distance from the FGM to the osseous crest before any

extraction or osseous intervention is to be performed. Therefore, the inter-proximal area poses more challenges if this evaluation will not be performed prior to any interventional treatment (Kois 2001).

Replacing missing teeth with dental implants recently has become a suitable treatment option for the partially edentulous patient. Techniques used in the development of implant recipient site have been developed, with an important emphasis on the hard and soft tissues (Spear et al. 1997), ideally resulting in peri-implant tissues that are more resistant to mechanical forces while providing an aesthetic pleasing outcome. Similar to natural teeth, resorption of the inter-implant bone results in loss of inter-implant papillae. Difficulty remains when trying to maintain or create the papilla between two adjacent implants. Choquet & Hermans (2001) investigated the presence or absence of the inter-proximal papillae adjacent to single-tooth implants to determine if there is a correlation between the distance from the base of the contact point to the alveolar crest. When the distance between the contact point and crest of the bone was less than 5 mm the papilla was present in 100% of the times. However, the occurrence of the papilla had a frequency below 50% when the distance was more than 5 mm. It has been suggested in the literature (Adell et al. 1986) that a minimum of 1.25–1.5 mm of clearance has to be maintained between the implant fixture and adjacent teeth for proper osseointegration and decreased risk of damaging the adjacent teeth. This is based primarily on the periodontal ligament width of adjacent teeth, although it failed to consider other important aspects such as maintaining the integrity of the papilla (Saadoun et al. 1999). A direct relationship has been demonstrated to exist between the existence of a minimum mesiodistal distance of 3 mm of bone between implants and maintenance of the adequate papilla (Tarnow et al. 1992). The amount of crestal bone loss was 1.04 mm when the inter-implant distance is less than 3 mm, while only 0.45 mm bone loss was noted in the area with a distance of more than 3 mm (Tarnow et al. 2000). The range and average of tissue height were evaluated between two adjacent implants by Tarnow et al. (2003). Mean height of tissue was found to be 3.4 mm between two adjacent implants with a wide range of

Table 2. Factors which influence presence/absence of the inter-dental/inter-implant papilla

Crestal alveolar bone height
Vertical: 1.0–3.0 mm (Gargiulo et al. 1961)
2.1–4.1 mm (Becker et al. (1997)
Horizontal: 3.0 mm (Tal 1984)
Dimension of interproximal space (distance from contact point to the alveolar crest)
Natural tooth: <5 mm (Tarnow et al. 1992)
Single implant: <5 mm (Choquet & Hermans 2001)
Two implants: <3.5 mm (Tarnow et al. 2003)
Soft tissue appearance (e.g., scallop; thick or thin biotype)
Flat is better than pronounced and high scallop (Salama et al. 1995, Kois 2001)
Thick biotype is better than thin biotype (Kois 2001)
Minimal buccal plate thickness
> 1.8 mm in anterior implant (Spray et al. 2000)
Contact areas (e.g., triangular <i>versus</i> square)
Square is better than triangular (Kois 2001)

variations from 1 to 7 mm. The most frequently probed heights were 2 mm in 16.9% of the cases, 3 mm 35.3% of the cases and 4 mm in 37.5% of the cases. According to the authors, a limitation exists when formation of the inter-implant papilla is expected. This implies that a rigorous treatment plan is critical in the anterior area where aesthetics is a major concern.

#### Soft-tissue assessment

The key to an aesthetically pleasant smile is proper management of the soft tissues around natural teeth or implants. Aesthetic soft-tissue contours are described by a harmoniously scalloped gingival line, the avoidance of an abrupt change in clinical crown length between adjacent teeth, a convex buccal mucosa of sufficient thickness and distinct papilla (Ono et al. 1998). The shape or the contour of the gingiva is highly variable and depends on the location and size of the inter-proximal contact area, volume of this space, size and shape of the present teeth in the arch. Bergstrom (1984) investigated the topographical features within the maxillary papillary gingiva between the lateral and central incisors in healthy young adults. The author described the length of the papilla from its base to the contact point in relation to the length of the crown of the central incisor. The authors found a ratio of 0.5 indicating that a healthy papilla reaches halfway to the incisal edge of the maxillary incisor. When the surface area of the papilla was measured in relation to the labial surface area of the lateral incisor, the ratio was close to 0.25, indicating that the papillary surface under healthy conditions amounts to about 1/4 of the labial surface of the lateral incisor crown (Bergstrom 1984). When the tooth shape is taken into consideration, square-shaped teeth may have a more favourable aesthetic outcome than ovoid or triangular-shaped teeth because of a longer inter-proximal contact and implicitly a less amount of papilla to fill in the space (Kois 2001). A triangular/taper shape has the inter-proximal contact area positioned more incisally, so higher risk of inter-proximal recession exists, which can create the presence of inter-proximal black triangles (Kois 2001).

The existing position of the inter-dental gingiva illustrates the level at which the gingiva is attached to the tooth. Gingival scallop has been cate-

gorized as flat, scalloped and pronounced according to the osseous anatomy (Becker et al. 1997). Teeth with a free gingival margin located more apical than ideal and a flat gingival scallop may present a compromised situation after tooth extraction. According to Salama & Salama (1993) these teeth may benefit from "orthodontic extrusion" when the supporting inter-proximal bone follows the extruded tooth and provides support for the papilla regeneration (Salama et al. 1995). The opposite situation when there is moderate coronal gingival overgrowth and a pronounced scallop may be beneficial for the aesthetic purposes of papillary conservation. Kois (2001) described the gingival biotype as being thick or thin. A thick gingival biotype implies more fibrotic tissue, more vascularization and thicker underlying hard tissue which in turn is more resistant to recession and often results in pocket formation in the presence of the bacterial insult. Thin gingival tissue has less underlying osseous support and less blood supply, which predisposes to recession after tooth extraction (Kois 2001). Highly scalloped cases with a friable gingiva require careful, atraumatic tooth extraction and flapless implant placement, which is advantageous because it minimizes bone loss and gingival recession (Garber et al. 2001). This approach, however, is quite challenging because of lack of visibility and the possible existence of a thin labial plate of bone. It requires careful planning and flawless surgical execution. As a compromised solution, it may be optimal to extract the hopeless tooth, perform hard- and soft-tissue grafting and place the implant 3–6 months later.

Maintaining facial bone is equally important as well, in order to prevent future dehiscences and implicit recession around implants. Teeth positioned too far facially often result in thin or no buccal bone, which will create a collapse in the gingival architecture after tooth extraction. According to Salama et al. (1996) these teeth are not good candidates for orthodontic extrusion since there is no existent facial bone. Opposite to this, teeth located too far labially have the advantage of a thicker bone and implicitly less resorption after extraction. Spray et al. (2000) examined the relationship between the amount of vertical bone loss and facial bone thickness. The authors proposed the term of "critical bone thickness" representing

the facial plate thickness at which chances of bone gain or bone loss are minimal. The largest chances for bone resorption were observed when the facial thickness was less than 1.4 mm, while the possibility of bone gain was seen at a 2 mm thickness. This is why the authors concluded that 2 mm is a critical thickness for the integrity of facial plate after stage 2.

#### Inter-dental Space Concerns: a Tooth or a Tissue Problem?

Gingival tissues have been designed to provide a framework for the body defense against the disease. For this reason, it is advocated that the dental papilla can provide a seal to withstand the microbial invasion and its loss may promote food impaction or aesthetic deformities. True loss of a previously existing inter-dental papilla can be accounted for in the periodontal disease process. Periodontitis is defined as an inflammatory disease of the supporting tissues of teeth and it is caused by the microorganisms which have the ability to invade and colonize the periodontal tissues. Thus, the first step in creating a harmonious relationship between tooth and gingival tissue is the elimination of marginal inflammation of the periodontal tissues. Reddened, inflamed inter-dental tissue draws the attention of the observer because of the contrast with the tooth colour and adjoining tissue. Rolled gingival margins encourage more rapid growth of plaque and disappearance of the healthy triangular look of the papilla. Similar to the natural counterpart, soft-tissue changes in implants play an important role in assessing the success rate in the aesthetic area. Cochran et al. (2002) reported that soft-tissue changes (e.g., recession) of approximately 1 mm take place in the first year after the restorative therapy is performed on a one-stage implant. This has to be taken into consideration when implant treatment planning in the aesthetic region is performed and maybe a longer term provisional restoration should be kept in place to help obtaining better esthetics in the anterior aesthetic zone (Cochran et al. 2002).

In cases of gingival overgrowth the gingiva covers the enamel and the sulcus depth will increase, thereby facilitating bacteria accumulation and decreasing the cleansing ability or plaque removal. Osseous resective procedures have been

developed to reshape the dentoalveolar architecture to create a more favourable environment for periodontal maintenance and health (Oschenbein 1986). In aesthetic crown-lengthening surgery, patient biotypes (Pontoriero & Carnevale 2001) can play an important role in the amount of rebound healing of the newly established gingival margin. Individual variation in gingival thickness will modify final tissue healing levels post-operatively. "Thick" tissue biotypes have the greatest chance to rebound in a coronal direction (Pontoriero & Carnevale 2001).

Frustrating to patients and dentists alike is the presence of spaces produced by the loss of inter-dental papillae to periodontal disease and surgical therapy. The loss of inter-dental papilla can create phonetic problems, as well as cosmetic deficiencies (the black triangle disease). A papillary deficiency could result from surgical excision, traumatic tooth extraction, apically positioned flap and many others (Table 3). Identifying the aetiology of the "black triangle disease" may involve more than one approach. First, it is advisable to evaluate the papilla height and compare it with the adjacent papilla. If there are no discrepancies in the vertical dimension, then the problem is most likely the tooth shape or the angulation of the tooth root (Kokich 1996). A divergence of the roots means in most of the cases an increase in the gingival embrasure volume, which can pose a problem in future aesthetic reconstruction of the papilla. Decreasing the gingival embrasure is best achieved with restorative or orthodontic treatment. Orthodontic treatment in conjunction with tooth stripping can be performed to reduce the volume of the gingival embrasure.

Lack of advanced understanding of the process of papillary loss (Table 3) has made surgical intervention, orthodontics or restorative treatment options more challenging especially in cases where soft tissue is the problem. In order to assess progressive degrees of

inter-dental/inter-implant papillary loss or regeneration, several classification systems have been proposed. Nordland & Tarnow (1998) developed a classification system for the loss of papillary height, which used as reference points the facial and inter-proximal CEJs of natural teeth and the inter-dental contact point (Nordland & Tarnow 1998). A class I papillary loss was defined when the tip of the papilla was found between the contact point and the inter-proximal CEJ (with no visual appearance of the inter-proximal CEJ). A class II papillary loss involves the presence of the tip of the papilla at or apical to the inter-proximal CEJ but coronal to the facial CEJ while a class III has papilla disappearance at or below the level of the facial CEJ (Nordland & Tarnow 1998). This classification may be of importance for clinicians when trying to evaluate the success of different treatment modalities existent to enhance soft-tissue aesthetics. Similar to the natural counterpart, an index system to assess the

degree of recession and regeneration of the papillary contour around single implant restorations has been developed by Jemt (1997). The index system designates five different levels of the amount of papillary presence, which is measured from a reference line that passes through the highest gingival curvature of the implant restoration on the facial side and the adjacent permanent tooth (Jemt 1997). An index score 0 had been assigned when papilla was absent. Index score 1 was assessed when less than half of the papillary height was present. Index score 2 means that at least half of the height of the papilla is present but does not reach the contact point. Index score 3 was designated when the papilla filled the entire proximal space and an index score 4 was given if the papillae were hyperplastic and overfilled the restoration (Jemt 1997).

Unfortunately, there are situations when ideal aesthetics cannot be achieved with any of the treatments mentioned above. In this situation, the patient

Table 3. Causes of papillary loss

Absolute causes
Periodontal disease
Osseous surgery
Traumatic tooth extraction
Relative causes
Gingival biotype (e.g., thin <i>versus</i> thick)
Increase in gingival embrasure because of root divergence

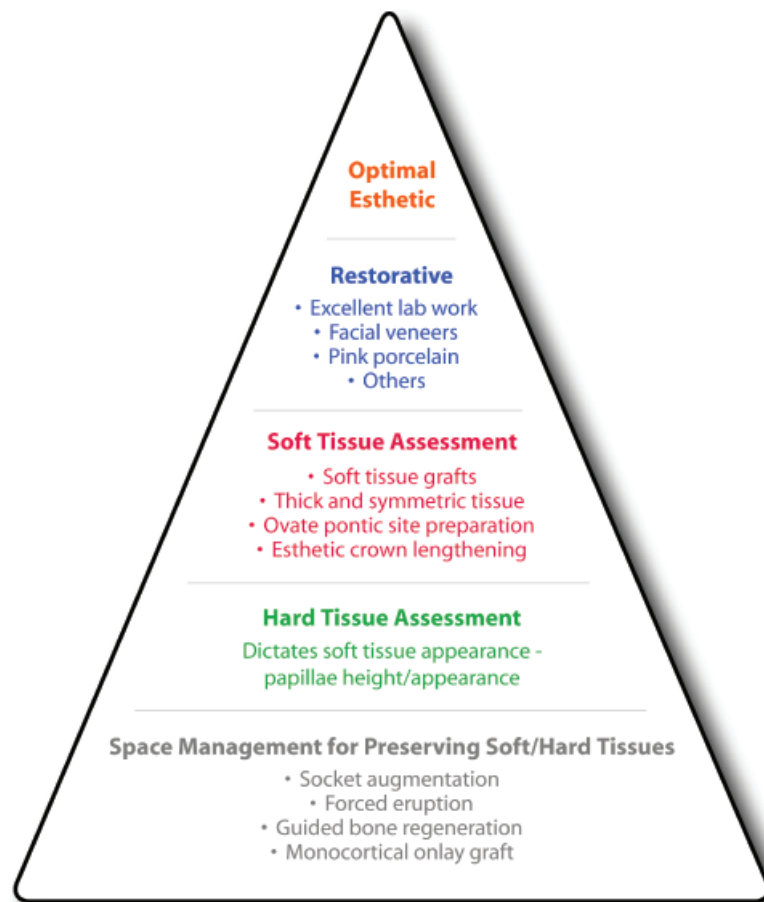


Fig. 2. Aesthetic triangle as a reference guide for treatment planning of aesthetic problems.

should be informed and a compromised solution should be recommended.

Aesthetic triangle to facilitate papillae existence was developed by the authors to manage aesthetic problems around natural teeth and dental implants (Fig. 2). The base of the triangle is the hard-tissue assessment and implicates the foundation for the adjacent tissue (papillae) height, since bone dictates the soft-tissue expression. The second layer of the aesthetic triangle contains the soft-tissue assessment by ways of examining the tissue thickness, symmetry to determine if soft-tissue grafts or ovate pontic site development is needed. Finally, the tip of the triangle will comprise existing restorative procedures to correct aesthetic problems (pink porcelain, veneers, etc.).

### Bone Support for Preservation of the Papillary Height

As previously discussed, bone loss may lead to compromised dental implant placement and aesthetic problems in the inter-dental papillary area. A ridge deficiency will necessitate the overbuilding of prosthetic tooth structure, prosthetic gingiva, or acceptance of a black triangle (Kois 1998). Consequently, phonetics can be affected where the space allows passage for the air or saliva.

Socket augmentation (i.e., ridge preservation technique) has been developed when a tooth is extracted atraumatically and the space is maintained by means of a bone substitute with or without a membrane. These modern techniques focus on rebuilding the alveolar ridge while maintaining the soft-tissue surroundings. Iasella et al. (2003) evaluated the horizontal and vertical bone resorption in 24 patients randomly selected to receive either extraction alone or ridge preservation using tetracycline hydrated freeze-dried bone allograft (FDBA) and a collagen membrane. Both groups lost ridge width, although an improvement was seen in the ridge preservation group. Most of the resorption occurred from the buccal and in maxillary sites. Regarding the vertical changes, the ridge preservation group gained an average height of 1.3 mm of bone, compared with the extraction alone group, which lost an average of 0.9 mm of bone height, differences being statistically significant of 2.2 mm between groups

*Table 4.* Tissue height needed from the contact point to the crestal bone level in order to maintain papillae in different clinical situations

Contact point-alveolar bone crest	100% papillae appearance (mm)	Author
Inter-dental papillae	≤5	Tarnow et al. (1992)
	<4.5	Kois (2001)
Implant-tooth papillae	<4.5	Salama et al. (1998, 2002), Salama (2001)
	<3.5	Tarnow et al. (2003)
Implant-implant	<5.5	Salama et al. (2004)
Implant-pontic	<6.5	Salama et al. (2004)
Tooth-pontic	<6	Salama et al. (2004)
Pontic-pontic		

(Iasella et al. 2003). Controlling and conserving the hard-tissue height by means of socket augmentation can help in achieving better soft-tissue aesthetics (papillary presence).

Preservation of the papillary height can be achieved via forced orthodontic extrusion, which is aimed at increasing the vertical osseous dimension at the inter-proximal sites while preserving adjacent soft-tissue (papilla) height. Salama & Salama (1993) recommended the slow eruption technique to advance the periodontal attachment apparatus including the alveolar bone more coronally for the correction of hard- and soft-tissue discrepancies. One potential drawback of using this method is the possibility of losing the level of the proximal alveolar bone support, since orthodontic extrusion tends to level the bone and even create the inverse architecture.

Guided bone regeneration (GBR) or bone augmentation to create bone volume that is needed for supporting the papilla appearance has also been recommended. These techniques include but are not limited to GBR to augment horizontal and minimal vertical bone height (Wang & Al-Shammari 2002), onlay grafting (Cordaro et al. 2002), distraction osteogenesis (McAllister & Gaffaney 2003) and combinations of soft- and hard-tissue grafting (Nemcovsky & Artzi 1999). Table 4 lists minimal distances needed from the contact point to the alveolar crestal bone level in order to maintain papillae among all clinical situations.

### Soft-tissue Manipulation for Preservation of the Papillary Height

During the past years, maintenance of the inter-dental papilla following tooth extraction has gained more attention. Advanced understanding of the anatomy and disease progression in the maxillary

anterior segment has made surgical intervention of papillary reconstruction a viable alternative at the time of implant placement. Restricting flap elevation can minimize the amount of bone resorption (Wilderman et al. 1970), thus helping in the preservation of the inter-dental papilla. Jemt (1997) using a proposed index score (described above) reported that 58% of the papillae adjacent to single-implant restorations regenerated to some extent after 1–3 years without any clinical manipulation of the soft tissues. The author speculated that these changes may be in part because of plaque accumulation in the inter-proximal areas, which may stimulate the hyperplastic, inflamed tissues to mature and be recognized as papillae.

Various soft-tissue surgical procedures have been introduced in an attempt to re-create the papillae (Aubert et al. 1994, Azzi et al. 1998, 2001). Takei et al. (1985) described the ‘‘papilla preservation technique’’ in an attempt to correct the deficient inter-proximal papillae contours between multiple teeth and it is primarily used as an aesthetically driven procedure. Different techniques for papilla preservation have been described, most of them emphasizing limiting the vertical releasing incisions in the papillary area (Nemcovsky & Artzi 1999). A papillary reconstruction technique using a palatal split thickness flap has also been proposed by Beagle (1992). The tissues obtained from the area lingual to the papilla are folded coronally to fill the inter-proximal space. Other variations may include the ‘‘T’’ shape incision and the double finger incision. Tinti & Benfenati (2002) described a ‘‘ramping suture’’ technique in which the healing abutments are used to ‘‘tent up’’ a full-thickness flap with a modified vertical mattress suture. Recently, Misch et al. (2004) introduced the split-finger flap technique to preserve/promote papillae formation. The

rationale for this technique is that unlike other techniques, the papilla is formed with tissue from both the facial and palatal aspects, which further enhances papillary support and appearance. A sulcular incision is made 2–3 mm to the palatal side with a loop design adjacent to the implant location. The incisions are then joined facially with a semicircular incision at the preplanned free tissue margin of the implant crown. The facial “fingers” are elevated to the desired inter-implant height for papillae. The middle “palatal finger” is then split and is reflected to the respective mesial and distal sides. The soft-tissue maintains its elevated position with a perimucosal extension or a final prosthetic abutment that is extended through the soft tissue. A modified vertical mattress suture is used to suture each papilla. Procedures such as this may help reduce the problem of the “black triangle”, in the open anterior inter-proximal space, however, their predictability remains to be determined.

Soft-tissue grafting procedures have been successfully used to augment tissues around teeth as well as implants. Partial reconstruction of the inter-dental papillae by means of plastic procedures in combination with subepithelial connective tissue grafts has been described (Nemcovsky 2001). Unfortunately, these are limited procedures since they do not address the reason why the papillae disappear.

Since soft-tissue collapse can occur following bone resorption, additional steps to the above mentioned procedures can be taken to maintain the tissues height. For example, papilla preservation can be initiated prior to tooth extraction with inter-disciplinary treatment planning. An immediate tooth replacement using an ovate pontic bonded to the adjacent teeth may help in moulding the papillary height and gingival embrasure form (Spear 1999). Ideally, the restorative dentist will fabricate an immediate tooth replacement using an ovate pontic bonded to the adjacent teeth. The concept of the ovate pontic allows for a natural-appearing emergence profile of the replacement and an ease of oral hygiene performance (Spear 1999). The pontic should extend initially 2.5 mm below the free gingival margin. This will allow the pontic to be situated within 1 mm of the facial and inter-proximal bone and will give support to the surrounding facial gingiva and the inter-dental papilla. After a

4-week healing period, the height of the pontic should be adjusted to extend approximately 1.5 mm below the tissue (Spear 1999). Occasionally, there can be a soft-tissue residual deficiency even after the meticulous attention to delicate extraction, bone grafting and immediate placement of an ovate pontic.

### Restorative Attempt to Correct the Aesthetic Challenge

Jemt (1999) proposed a technique of preserving the inter-dental papillae by means of placing a provisional temporary crown at the time of second-stage surgery. The provisional crowns were used to guide the soft tissue into the inter-dental space faster than healing abutments alone (Jemt 1999). Jemt & Lekholm (2003) compared the inter-proximal tissue volume around the implant-supported single crowns in function for 2 years *versus* papillary volume around implants which were placed in grafted bone. The authors reported that a significant buccal and inter-proximal resorption of the bone graft was seen 2 years after the implant placement, which may have a negative impact on the aesthetic outcome in the inter-proximal area. However, the inter-dental papillae were reported to have increased significantly ( $p < 0.05$ ) in volume during the first year, almost completely filling up the embrasure areas after 2 years of crown placement. The author's conclusion was that the placement of the abutment cylinder and the crown seemed to play a more important role for re-establishing the inter-proximal tissue volume at the implant-supported single crowns.

Unfortunately, there are some situations when all methods of hard and soft-tissue augmentation fail. In this case, compromised aesthetics by means of prosthetic techniques can be utilized to create the illusion of papillae. Alteration in the position of the contact point or the volume of the inter-proximal space with the addition of pink porcelain baked onto the implant restoration can mask the loss of gingival tissues. Ceramic veneering for the missing teeth and resin veneering for the gingival are technically possible as well. However, no presently available spectrum of ceramic shades exists to guarantee an aesthetically satisfactory gingival.

Many surgical and prosthetic procedures exist to augment soft-tissue

contours and try to reconstruct the inter-dental papillae, although to date no effort has been made to organize this body of literature into a coherent treatment approach. It is quite evident that little scientific literature exists in this area and there is a strong need for further research in establishing the long-term success of the papillary regeneration techniques.

### Conclusions

Thorough treatment planning is essential for maintenance of the height of the inter-proximal papillae following tooth removal. Once the potential problems are known, additional procedures can be performed or anticipated. It has been proven that by maintaining or trying to correct the height of bone in the inter-proximal area, an aesthetic reconstruction of the papilla can be achieved. Periodontal plastic procedures can be used to enhance the ultimate outcome. In aesthetically compromised cases, restorative intervention can mask the loss of tissues but rarely can they achieve ideal aesthetics. Implementing all these techniques into clinical practice may alleviate the challenge which lays upon the dental practitioners in dealing with inter-dental/implant papilla appearance. An aesthetic triangle is developed to address the foundations that are essential for maintaining/creating papilla. These include adequate bone volume, proper soft-tissue thickness as well as aesthetic appearing restorations.

### Acknowledgements

This study was partially supported by the University of Michigan, Periodontal Graduate Student Research Fund. The authors do not have any financial interests, either directly or indirectly, in the products listed in the study.

### References

- Adell, R., Lekholm, U., Branemark, P. I., Lindhe, J., Rockler, B., Eriksson, B., Lindvall, A. M., Yoneyama, T. & Sbordone, L. (1986) Marginal tissue reactions at osseointegrated titanium fixtures. *Swedish Dental Journal* **28** (Suppl.), 175–181.
- Adell, R., Lekholm, U., Rockler, B. & Brånemark, P.-I. (1981) A 15-year study of osseointegrated implants in the treatment of the edentulous jaw. *International Journal of Oral Surgery* **10**, 387–416.

- Aubert, H., Bertrand, G., Orlando, S., Benguigui, F. & Acocella, G. (1994) Deep rotated connective tissue flap for the reconstruction of the interdental papilla. *Minerva Stomatologica* **43**, 351–357.
- Azzi, R., Etienne, D. & Carranza, F. (1998) Surgical reconstruction of the interdental papilla. *International Journal of Periodontics Restorative Dentistry* **18**, 466–473.
- Azzi, R., Takei, H. H., Etienne, D. & Carranza, F. A. (2001) Root coverage and papilla reconstruction using autogenous osseous and connective tissue grafts. *International Journal of Periodontics Restorative Dentistry* **21**, 141–147.
- Beagle, J. R. (1992) Surgical reconstruction of the interdental papilla: case report. *International Journal of Periodontics Restorative Dentistry* **12**, 145–151.
- Becker, W., Ohsenbein, C., Tibbetts, L. & Becker, B. E. (1997) Alveolar bone anatomic profiles as measured from dry skulls. Clinical ramifications. *Journal of Clinical Periodontology* **24**, 727–731.
- Bergstrom, J. (1984) The topography of papillary gingiva in health and early gingivitis. *Journal of Clinical Periodontology* **11**, 423–431.
- Brånemark, P. I., Hansson, B. O., Adell, R., Breine, U., Lindström, J., Hallén, O. & Öhman, A. (1977) *Osseointegrated implants in the treatment of the edentulous jaw. Experience from a 10-year period*. Göteborg: Almqvist & Wiksell International.
- Choquet, V. & Hermans, M. (2001) Clinical and radiographic evaluation of the papilla level adjacent to single-tooth dental implants. A retrospective study in the maxillary anterior region. *Journal of Periodontology* **72**, 1364–1371.
- Cochran, D. L. (1997) Biologic width around titanium implants. A histometric analysis of the implanto-gingival junction around unloaded and loaded nonsubmerged implants in a canine model. *Journal of Periodontology* **68**, 186–198.
- Cochran, D. L., Buser, D., ten Bruggenkate, C. M., Weingart, D., Taylor, T. M., Bernard, J. P., Peters, F. & Simpson, J. P. (2002) The use of reduced healing times on ITI implants with a sandblasted and acid-etched (SLA) surface: early results from clinical trials on ITI SLA implants. *Clinical Oral Implants Research* **13**, 144–153.
- Cohen, B. (1959) Morphological Factors in the pathogenesis of the periodontal disease. *British Dental Journal* **7**, 31–39.
- Cordaro, L., Amade, D. S. & Cordaro, M. (2002) Clinical results of alveolar ridge augmentation with mandibular block bone grafts in partially edentulous patients prior to implant placement. *Clinical Oral Implants Research* **13**, 103–111.
- Esposito, M. & Worthington, H. V. (2003) Interventions for replacing missing teeth: different types of dental implants. *Cochrane Database Systematic Review* (3): CD003815.
- Garber, D., Salama, M. & Salama, H. (2001) Immediate total tooth replacement. *Compendium Continuing Education Dentistry* **22**, 210–218.
- Gargiulo, A. W., Wentz, F. M. & Orban, B. (1961) Dimensions and relations of the dentogingival junction in humans. *Journal of Periodontology* **32**, 261–267.
- Heins, P. & Wieder, S. (1986) A histological study of the width and the nature of interradicular spaces in human adult pre-molars and molars. *Journal of Dental Research* **65**, 948–951.
- Iasella, J. M., Greenwell, H., Miller, R. L., Hill, M., Drisko, C., Bohra, A. A. & Scheetz, J. P. (2003) Ridge preservation with freeze-dried bone allograft and a collagen membrane compared to extraction alone for implant site development: a clinical and histological study in humans. *Journal of Periodontology* **74**, 990–999.
- Jemt, T. (1997) Regeneration of the gingival papillae after single-implant treatment. *International Journal of Periodontics Restorative Dentistry* **17**, 326–333.
- Jemt, T. (1999) Restoring the gingival contour by means of Provisional Resin Crowns after single-implant treatment. *International Journal of Periodontics Restorative Dentistry* **19**, 21–29.
- Jemt, T. & Lekholm, U. (2003) Measurements of buccal tissue volumes at single-implant restorations after local bone grafting in maxillas: a 3-year clinical prospective study case series. *Clinical Implant Dental Relations Research* **5**, 63–70.
- Kois, J. C. (1998) Esthetic extraction site development: the biologic variables. *Contemporary Esthetics Restorative Practice* **2**, 10–18.
- Kois, J. C. (2001) Predictable single tooth peri-implant esthetics. Five diagnostic keys. *Compendium Continuing Education Dentistry* **22**, 199–208.
- Kokich, V. G. (1996) Esthetics: the orthodontic-periodontic restorative connection. *Seminar Orthodontics* **2**, 21–30.
- McAllister, B.S. & Gaffaney, T. E. (2003) Distraction osteogenesis for vertical bone augmentation prior to oral implant reconstruction. *Periodontology* **2000** **33**, 54–66.
- Misch, C. E., Al-Shammari, K. F. & Wang, H. L. (2004) Creation of interimplant papillae through a split-finger technique. *Implant Dentistry* **13**, 20–27.
- Nemcovsky, C. E. (2001) Interproximal papilla augmentation procedure: a novel surgical approach and clinical evaluation of 10 consecutive procedures. *International Journal of Periodontics Restorative Dentistry* **21**, 553–559.
- Nemcovsky, C.E. & Artzi, Z. (1999) Split palatal flap. I. A surgical approach for primary soft tissue healing in ridge augmentation procedures: technique and clinical results. *International Journal of Periodontics Restorative Dentistry* **19**, 175–181.
- Nordland, W. P. (1998) Periodontal plastic surgery: esthetic gingival regeneration. *Journal of California Dental Association* **17**, 29–32.
- Nordland, W. P. & Tarnow, D. P. (1998) A classification system for loss of papillary height. *Journal of Periodontology* **69**, 1124–1126.
- Oschenbein, C. (1986) Osseous resection in periodontal surgery. *Journal of Periodontology* (Suppl.) **57**, 15–26.
- Ono, Y., Nevins, M. & Cappetta, E. G. (1998) The need for keratinized tissue for implants. In: Nevins, M. & Mellonig, J. T. (eds). *Implant Therapy. Clinical Approaches and Evidence of Success*, Vol. 2, pp. 227–237. Chicago: Quintessence.
- Pontoriero, R. & Carnevale, G. (2001) Surgical crown lengthening: a 12-month clinical wound healing study. *Journal of Periodontology* **72**, 841–848.
- Salama, H. (2001) Orthodontics vs restorative materials in treatment plans. *Contemporary Esthetics and Restorative Practice* **5**, 20–30.
- Salama, H. & Salama, M. (1993) The role of orthodontic extrusive remodeling in the enhancement of soft and hard tissue profiles prior to implant placement: a systematic approach to the management of extraction site defects. *International Journal of Periodontics Restorative Dentistry* **13**, 312–333.
- Salama, H., Salama, M. & Kelly, J. (1996) The orthodontic-periodontal connection in implant site development. *Practical Periodontics and Aesthetic Dentistry* **8**, 923–932.
- Salama, H., Salama, M. A., Garber, D. & Adar, P. (1995) Developing optimal peri-implant papillae within the esthetic zone. Guided soft tissue augmentation. *Journal of Esthetic Dentistry* **7**, 125–129.
- Salama, H., Salama, M. A., Garber, D. & Adar, P. (1998) The interproximal height of bone: a guidepost to predictable aesthetic strategies and soft tissue contours in anterior tooth replacement. *Practical Periodontics Aesthetic Dentistry* **10**, 1131–1141; quiz 1142.
- Salama, H., Salama, M. & Garber, D. (2002) Guidelines for aesthetic restorative options and implant site enhancement: the utilization of orthodontic extrusion. *Practical Procedures Aesthetic Dentistry* **14**, 125–130.
- Salama, H., Salama, M., Garber, D. & Adar, P. (2004) The inter-proximal height of bone: a guidepost to esthetic strategies and soft tissue contours in anterior tooth replacement. Submitted to *The Journal of Practical Periodontics and Aesthetic Dentistry*, Anthology edition, adapted from the www.goldsteingarber.com.
- Saadoun, A., LeGall, M. & Touti, B. (1999) Selection and ideal tridimensional implant position for soft tissue aesthetics. *Practical Periodontics Aesthetic Dentistry* **11**, 1063–1072.
- Schroeder, H. E. & Listgarten, M. A. (1997) The gingival tissues: the architecture of periodontal protection. *Periodontology* **2000** **13**, 91–120.
- Spear, F. M. (1999) Maintenance of the interdental papilla following anterior tooth removal. *Practical Periodontics and Aesthetic Dentistry* **11**, 21–28; quiz 30.
- Spear, F. M., Mathews, D. M. & Kokich, V. G. (1997) Interdisciplinary management of single-tooth implants. *Seminar Orthodontics* **3**, 45–72.

- Spray, J. R., Black, C. G., Morris, H. & Ochi, S. (2000) The influence of bone thickness on facial marginal bone response: stage 1 placement through stage 2 uncovering. *Annals of Periodontology* 2000 **5**, 119–128.
- Takei, H. H., Han, T. J., Carranza, F. A. Jr., Kenney, E. B. & Lekovic, V. (1985) Flap technique for periodontal bone implants. Papilla preservation technique. *Journal of Periodontology* **56**, 204–210.
- Tal, H. (1984) Relationship between the interproximal distance of roots and the prevalence of infrabony pockets. *Journal of Periodontology* **55**, 604–607.
- Tarnow, D., Elian, N., Fletcher, P., Froum, S., Magner, A., Cho, S. C., Salama, M., Salama, H. & Garber, D. A. (2003) Vertical distance from the crest of bone to the height of the interproximal papilla between adjacent implants. *Journal of Periodontology* **74**, 1785–1788.
- Tarnow, D. P., Cho, S. C. & Wallace, S. S. (2000) The effect of inter-implant distance on the height of inter-implant bone crest. *Journal of Periodontology* **71**, 546–549.
- Tarnow, D. P., Magner, A. W. & Fletcher, P. (1992) The effect of distance from the contact point to the crest of bone on the presence or absence of the interproximal dental papilla. *Journal of Periodontology* **63**, 995–996.
- Tinti, C. & Benfenati, S. P. (2002) The ramp mattress suture: a new suturing technique combined with a surgical procedure to obtain papillae between implants in the buccal area. *International Journal of Periodontics Restorative Dentistry* **22**, 63–69.
- Vacek, J. S., Gher, M. E., Assad, D. A., Richardson, A. C. & Giambarsesi, L. I. (1994) The dimensions of the human dentogingival junction. *International Journal of Periodontics Restorative Dentistry* **14**, 154–165.
- Waerhaug, J. (1979a) The angular bone defect and its relationship to trauma from occlusion and downgrowth of subgingival plaque. *Journal of Clinical Periodontology* **6**, 61–82.
- Wang, H. L. & Al-Shammari, K. (2002) HVC ridge deficiency classification: a therapeutically oriented classification. *International Journal of Periodontics Restorative Dentistry* **22**, 335–343.
- Wilderman, M. N., Pennel, B. M., King, K. & Barron, J. M. (1970) Histogenesis of repair following osseous surgery. *Journal of Periodontology* **41**, 551–565.

Address:  
 Dr. Hom-Lay Wang  
 Department of Periodontics/Prevention/  
 Geriatrics  
 University of Michigan  
 School of Dentistry  
 1011 North University Avenue  
 Ann Arbor, MI 48109-1078, USA  
 E-mail: homlay@umich.edu

This document is a scanned copy of a printed document. No warranty is given about the accuracy of the copy. Users should refer to the original published version of the material.