

# Mesenchymal stem cells and platelet-rich plasma enhance bone formation in sinus grafting: a histomorphometric study in minipigs

Francesco Pieri<sup>1</sup>, Enrico Lucarelli<sup>2</sup>, Giuseppe Corinaldesi<sup>1</sup>, Giovanna Iezzi<sup>3</sup>, Adriano Piattelli<sup>3</sup>, Roberto Giardino<sup>4</sup>, Massimo Bassi<sup>5</sup>, Davide Donati<sup>2</sup> and Claudio Marchetti<sup>1</sup>

<sup>1</sup>Department of Odontostomatological Sciences, University of Bologna, Bologna, Italy; <sup>2</sup>Bone Regeneration Laboratory, Research Institute Codivilla-Putti, Rizzoli Orthopaedic Institute, University of Bologna, Bologna, Italy; <sup>3</sup>Dental School, University of Chieti-Pescara, Chieti, Italy; <sup>4</sup>Department of Experimental Surgery, Research Institute Codivilla-Putti, Rizzoli Orthopaedic Institute, University of Bologna, Bologna, Italy; <sup>5</sup>Division of Maxillofacial Surgery, M. Bufalini Hospital, Cesena, Italy

Pieri F, Lucarelli E, Corinaldesi G, Iezzi G, Piattelli A, Giardino R, Bassi M, Donati D, Marchetti C. Mesenchymal stem cells and platelet-rich plasma enhance bone formation in sinus grafting: a histomorphometric study in minipigs. *J Clin Periodontol* 2008; 35: 539–546. doi: 10.1111/j.1600-051X.2008.01220.x.

## Abstract

**Objectives:** Autologous, allogenic, and alloplastic materials for sinus augmentation have specific drawbacks, which has stimulated an ongoing search for new materials and tissue-engineering constructs. We investigated whether mesenchymal stem cells (MSCs) and platelet-rich plasma (PRP) seeded on a fluorohydroxyapatite (FH) scaffold can improve bone formation and bone-to-implant contact (BIC) in maxillary sinus grafting.

**Material and Methods:** Bilateral sinus augmentation procedures were performed in eight minipigs. MSCs, PRP, and FH scaffold (test site) or FH alone (control site) were grafted in each maxillary sinus. Distal to the osteotomy, one dental implant per sinus was placed in the grafting material through the facial sinus wall. The animals were killed 3 months after grafting, and block sections of the implant sites were harvested and prepared for histomorphometric analysis.

**Results:** After 12 weeks, a significant increase in bone formation occurred in the test sites compared with the control sites (42.51% versus 18.98%;  $p = 0.001$ ). In addition, BIC was significantly greater in the test sites compared with the control sites in the regenerated area (23.71% versus 6.63%;  $p = 0.028$ ).

**Conclusions:** These findings show that sinus augmentation with MSCs–PRP, combined with FH may enhance bone formation and osseointegration of dental implants compared with FH alone in minipigs.

Key words: dental implants; platelet-rich plasma; sinus grafting; stem cells; tissue engineering

Accepted for publication 1 February 2008

Maxillary sinus grafting has become the most common procedure in implant reconstructive surgery (Jensen et al. 1998).

## Conflicts of interest and sources of funding statement

The authors declare that there are no conflicts of interest in this study. No external funding, apart from the support of the authors' institution, was provided for this study.

This technique increases the alveolar bone height in the maxillary sinus before the placement of endosseous implants. Presently, autogenous bone grafts are considered to be the “gold standard”, although their disadvantages (low availability of intra-oral bone tissue, high surgery costs, and post-operative morbidity) have stimulated the search for alternative sources (van den Bergh et al. 2000, Nkenke et al. 2004). Various osteoconductive materials have been

used to augment the sinus floor, but these materials are cell-free (Nasr et al. 1999) and require more time for bone healing (Degidi et al. 2006). Therefore, researchers are very interested in a tissue-engineering procedure that uses autologous mesenchymal stem cells (MSCs) combined with an osteoconductive scaffold as a live bone substitute (Gronthos et al. 2006).

The goal of tissue engineering in the craniofacial region is to develop a

biological substitute that promotes tissue regeneration (Mao et al. 2006). The usual biological substitute consists of stem cells, growth factors, and an appropriate scaffold. Stem cells are the most suitable cell source for developing engineered tissues. MSCs are a population of multipotent, non-haematopoietic, marrow-derived cells, which are easily expanded in culture and differentiate into cells with an osteogenic phenotype (Friedenstein et al. 1970, Bruder et al. 1998).

Recent findings that MSCs can regenerate critical-size bone defects when combined with bone substitutes (De Kok et al. 2005, Dallari et al. 2006) and improve bone allograft integration (Lucarelli et al. 2003) have increased interest in their clinical application. Platelets are an easily accessible, inexpensive, and safe source of growth factors. Platelets are collected in a small volume of plasma called platelet-rich plasma (PRP), which plays a fundamental role in haemostasis and is a natural source of growth factors and adhesive glycoproteins (Pryor et al. 2005, Christgau et al. 2006). The use of PRP for sinus augmentation has been proposed as a way to reduce the time required for graft consolidation and maturation, and to improve trabecular bone density (Kassolis et al. 2000).

Using a minipig model, we evaluated whether the combination of MSCs, PRP, and a fluorohydroxyapatite (FH) scaffold improves the pattern of bone formation and bone-to-implant contact (BIC), compared with FH alone, in a sinus augmentation procedure with simultaneous implant placement. We hypothesized that the osteogenic effects of the MSCs and PRP would lead to increased bone regeneration and apposition to the implant surface.

## Material and Methods

### Minipig animal model

The study was performed according to Italian and European laws on animal experimentation and Animal Welfare Assurance Regulation #A5424-01 of the National Institutes of Health (NIH; Rockville, MD, USA). Eight adult minipigs, aged 18–21 months and weighing 38–43 kg, were used in this study.

### Preparation of PRP

Platelets were obtained from the venous blood of each minipig. Blood was drawn

from the jugular vein into a bag containing citrate phosphate dextrose (CPD); 100 ml CPD contained 327 mg citric acid monohydrate, 2.63 g sodium citrate dihydrate, 2.55 g glucose monohydrate, and 251 mg sodium dihydrogen phosphate dihydrate) as an anticoagulant (1 ml CPD/7 ml blood). The blood was centrifuged twice: first at  $1000 \times g$  for 15 min. at 20°C to remove red blood cells, and a second time at  $3000 \times g$  for 10 min. at 20°C to obtain PRP containing  $1 \times 10^6$  platelets/ml. The platelet concentrate was activated by adding 330 µl calcium gluconate (100 mg/ml) and thrombin.

### Isolation and expansion of MSCs

From each minipig, a 10 ml bone marrow sample was aspirated from the posterior iliac crest. Mononuclear cells were isolated in a density gradient and re-suspended in  $\alpha$ -modified minimal essential medium (Sigma, St. Louis, MO, USA) containing 20% foetal calf serum (Euroclone, Wetherby, UK), 10 U/ml penicillin (Euroclone), 100 mg/ml streptomycin, and 2 mM glutamine (Euroclone). Non-adherent cells were discarded after 1 week, and adherent cells were cultured for further expansion.

### Osteogenic differentiation

After passage 1, cells morphologically resembled human MSCs. We decided to characterize functionally the cells obtained and test whether the osteogenic differentiation could be induced. At passage 3, a subset of cells was plated to test whether cells could be induced to differentiate towards the osteogenic lineage. Cells were seeded in 2% foetal calf serum (Euroclone) in six-well plates at a density of  $15\,000$  cells/cm<sup>2</sup> to reach confluence immediately. The cells were treated for 14 days with osteogenic induction medium consisting of 10 mM  $\beta$ -glycerophosphate (Sigma), 50 mg/ml (284 µM) ascorbic acid (Sigma), and 10 nM dexamethasone (Sigma). As a negative control, an equal number of wells were maintained in 2% foetal calf serum for the same duration of time. The media in both groups were completely replaced every 3 days and at the end of the 14th day, the cells were stained as follows: osteogenesis was evaluated by a colorimetric semi-quantitative assessment of Alizarin Red (Gregory et al.

2004). The plates were washed once with PBS, fixed with 70% ethanol for 1 h at room temperature, and incubated with 40 mM Alizarin Red-S (pH 4.2) (Sigma) for 10 min., at room temperature, and in the absence of light and in continuous agitation. After staining, the cultures were washed with deionized water and then with PBS for another 15 min. To quantify matrix mineralization, Alizarin Red-S stained cultures were incubated in 10% cetylpyridinium chloride (Sigma) for 15 min. to solubilize and release calcium-bound Alizarin Red-S into solution. The absorbance of the released Alizarin Red-S was measured at 562 nm. Cell density was measured in a parallel culture subsequently stained with methylene blue 1% in (4) borate buffer 0.01 M (pH 8.5) by these passages: the cell layer was fixed with 10% formal saline for at least 30 min. The fixative was removed and filtered 1% (w/v) methylene blue in borate buffer was added to each well. After 30 min., excess dye was removed and the remaining dye was washed four times with borate buffer. The dye was eluted with 1:1 (v/v) ethanol and 0.1 M HCl. The plates were then gently shaken and the absorbance was measured at 655 nm (Oliver et al. 1989).

### Cell implant

The day before the surgical procedure,  $4 \times 10^7$  cells were harvested in 1 ml of saline solution and mixed in a scaffold that consisted of 3 ml of platelet gel, 3 ml of FH, and 3 ml sterile rat tail-derived collagen (Roche, Mannheim, Germany) to give a final volume of 10 ml. The test tube was stored at 37°C and implanted the next morning.

### Experimental procedure

Before surgery, the skin was shaved and cleaned with a mixture of iodine and 70% ethanol. The floor elevation procedure and implant placement were performed identically on both sides of each animal. The facial maxillary sinus wall was exposed bilaterally through an approximately 5-cm-long extra-oral sagittal skin incision below the lower lid (Roldan et al. 2004). Access to the sinus was achieved by thinning the facial wall with a diamond bur. The membrane within the sinus was elevated carefully using blunt elevators (Friatec, Friedrichsfeld, Germany) to avoid

perforations. In one sinus of each minipig, the resultant space between Schneider's membrane and the sinus floor was filled with 3–4 ml of FH alone (0.5–1 mm particles; Aligopore; Dentsply-Friadent, Mannheim, Germany) (control site). In the other sinus, MSCs and PRP were admixed with 3 ml of FH in a 20 ml sterile syringe 15–20 min. before grafting, and the final MSCs–PRP loaded construct was implanted (test site). Two dental implants (length, 11 mm; diameter, 3.8 mm) with a grit-blasted and acid-etched surface (XiVE; Dentsply-Friadent) were placed before the cavity was completely filled with grafting materials bilaterally through the facial sinus wall. The clinical bone height was measured with a periodontal probe (Hu-Friedy UNC, Chicago, IL, USA) (mean  $3.5 \pm 0.73$ ) to aid the histologists in the evaluation of the host bone and the regenerated bone (Fig. 1). Then, the periosteum and skin flap were re-positioned and sutured in separate layers using resorbable sutures. The general condition of the animals was checked daily for 3 weeks. One month after surgery, the animals were housed in an open space until killing.

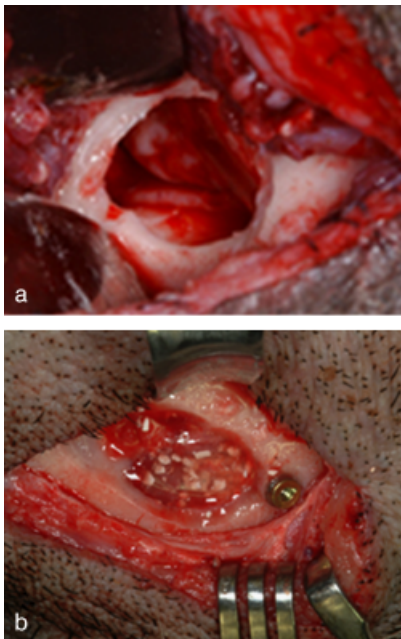


Fig. 1. (a, b) Sinus floor elevation procedure with simultaneous placement of a titanium screw implant (3.8 mm wide, 11 mm long) into the zygomatic bone in a laterocranial direction. The sinus cavity was then packed with graft material.

#### Specimen retrieval and histological processing

After 3 months of healing, the animals were euthanized pharmacologically. Immediately after killing, the soft tissues were removed to expose the sinus areas of the maxilla with one integrated implant per side. From each animal, bone blocks containing each implant were cut with an oscillating saw, fixed in 4% buffered paraformaldehyde, and embedded in glycolmethacrylate resin for histological and histomorphometric evaluation. Three 30- $\mu$ m-thick sections were prepared from each embedded implant, polished, and surface-stained according to a published protocol (Piatelli et al. 1997).

The percentage of direct contact between the mineralized bone and titanium surface (BIC) was estimated to

quantify the histomorphometric differences in bone apposition between the two experimental conditions. The part of the implant surrounded by local host bone was designated as the coronal segment, while the part surrounded by newly formed bone matrix only was designated as the apical segment. The area of newly formed bone in the augmented sinus was also determined in a reference rectangular area between the implant tip and the apical-most bottom thread at a lateral distance of 2 mm from the implant surface (McMillan et al. 1999). The evaluations were performed under a light microscope (Laborlux S; Leitz, Wetzlar, Germany) connected to a high-resolution video camera (JVC KY-F55B, 3CCD; JVC, Tokyo, Japan) interfaced with a monitor and PC equipped with a Pentium III 1200 MMX processor (Intel Corp., Santa

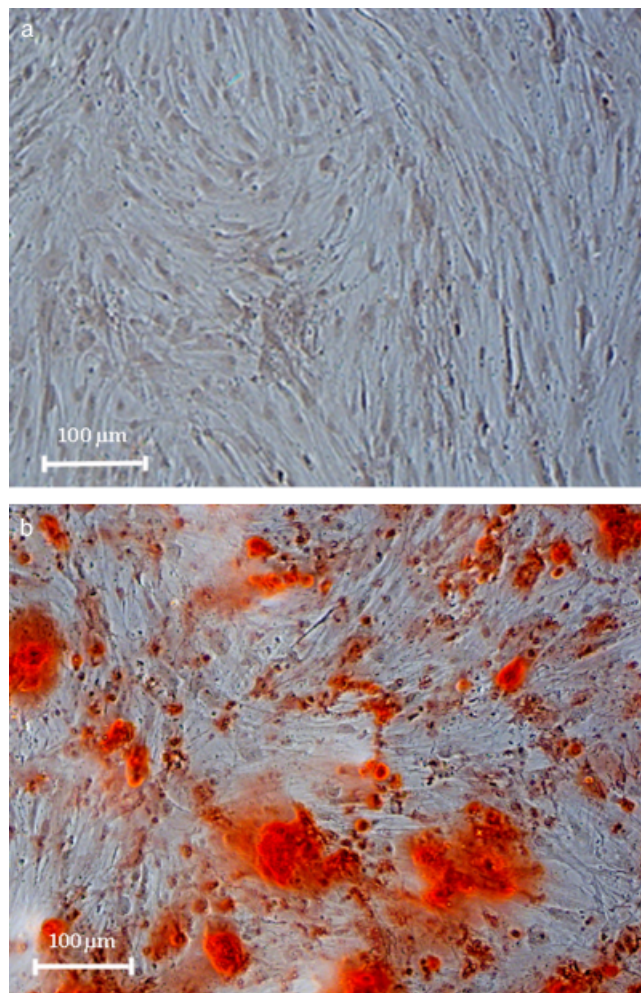


Fig. 2. Confluent mesenchymal stem cells cultured in 2% FBS were maintained under culture condition (a), or treated with osteogenic medium (b). After 14 days, osteogenic differentiation was evaluated by Alizarin Red staining.



Clara, CA, USA). This optical system was connected to a digitising pad and a histometry software package with image-capturing capability (IMAGE-PRO PLUS 4.5; Media Cybernetics Inc., Immagini & Computer Snc, Milano, Italy).

#### Statistical analysis

An experienced pathologist (P. A.) evaluated all the parameters in a blinded fashion. Using a split-mouth design, the differences in the mean amount of newly formed bone and the BIC between the control and test groups were analysed using a paired *t*-test using SPSS 11.0 software (SPSS Inc., Chicago, IL, USA). Significance was established at  $p < 0.05$ .

### Results

#### Cell collection, differentiation, and expansion

No complications were encountered upon cell collection. Cells were collected and expanded in all eight minipigs. We referred to these adherent cells that had the ability to differentiate into osteogenic lineage as MSCs (Fig. 2).

#### Clinical observations

In one of the eight animals, the membrane in both the control and the test sites was perforated during sinus elevation, and wound infection occurred 1 month after the procedure. At the time of death, both sinuses were infected and were not processed for histology. Others showed uneventful healing patterns after surgical procedures with no signs of macroscopic infection in the maxillary sinuses. Post-surgical swelling was detected at the maxilla in all animals and resolved by 1 week after surgery.

#### Histologic and histomorphometric observations

All histological sections, both from the test group and the control group, showed a similar bone structure around the coronal part of the implants, which was mainly compact in nature. In the control sites, most of the implants showed only a thin layer of newly formed bone in the immediate proximity of the host bone. However, the augmented area was often filled with FH

particles, which were embedded in loose connective tissue, with no appreciable bone formation in or around them. In contrast, the implants in the test sites appeared to be largely covered by bone along their entire surface. Also, the apical portions of the implants were surrounded predominantly by lamellar structured bone tissue. Newly formed bone was always present between the implant threads, and it connected the implant surface to the host bone and FH particles (Fig. 3). In the sites treated with MSCs-PRP, a statistically significant increase ( $p = 0.001$ ) in the amount of bone ( $42.51 \pm 7.08\%$ , mean  $\pm$  SD) was found compared with MSCs-PRP-free sites ( $18.98 \pm 0.92\%$ ) (Fig. 4).

For both types of graft, direct BIC was evident in the coronal segment of the dental implants in the host bone. Newly formed bone bridged the gap between the implant and the drill hole, and most of it was in direct contact with the implant surface. The bone deposited around the coronal part of the implants placed within MSCs-PRP free and MSCs-PRP containing grafts was mainly lamellar, and early signs of bone re-modelling were apparent (Fig. 5). No significant difference ( $p = 0.526$ ) in the percentage of BIC between the test ( $33.85 \pm 5.15\%$ ) and the control ( $32.66 \pm 2.49\%$ ) sites was observed in the implant segment placed in the basal bone (Fig. 6).

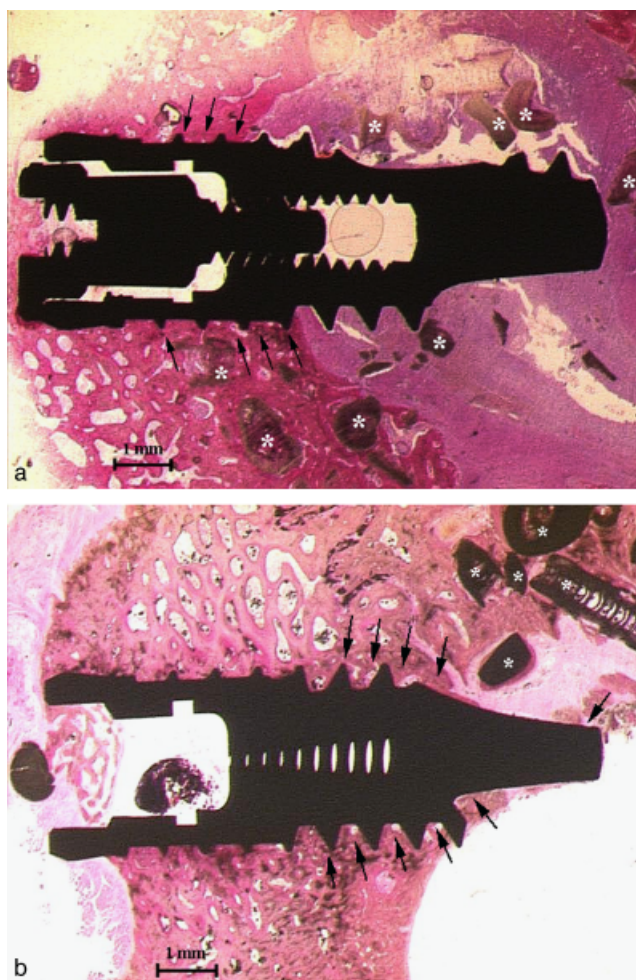


Fig. 3. Histology of bone formation. (a) In control sites, a thin layer of newly formed bone was present in close proximity to the host bone (arrows). However, osseointegration was poor at the apical part of the titanium implant, where the fluorohydroxyapatite (FH) particles (\*) were almost completely covered by soft tissue (basic fuchsin and toluidine blue; scale bar, 1 mm). (b) In test sites, homogeneous newly formed bone covered the implant surface in the augmented area (arrows). Osseointegration of the titanium implant was observed along almost its entire length. A few FH particles (\*) embedded in the bone were visible, but were far from the implant surface (basic fuchsin and toluidine blue; scale bar, 1 mm).

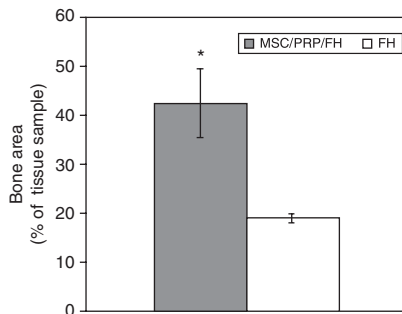


Fig. 4. Histomorphometric results for the area of newly formed bone in the control and test sites expressed as the mean percentage ( $\pm$  SD). \*statistically significant difference ( $p < 0.05$ ). MSC, mesenchymal stem cell; PRP, platelet-rich plasma; FH, fluorohydroxyapatite.

When MSCs and PRP were present, homogeneous bone could be seen in apposition to the apical segment of the implants in all cases. The test-group specimens contained trabeculae of lamellar bone, and small irregular deposits of new bone and osteoid formation closely apposed to the implant surface. This did not occur in constructs lacking MSCs-PRP, in which no bone apposition was seen on the apical portions of the implants (Fig. 7). Quantitative analysis of the samples revealed a statistically significant increase ( $p = 0.028$ ) in the BIC in the test sites compared with the control sites ( $23.71 \pm 14.31\%$  versus  $6.63 \pm 3.46\%$ ) (Fig. 8) (Table 1).

## Discussion

We investigated whether a tissue-engineered construct composed of MSCs, PRP, and FH would improve bone healing around dental implants, compared with FH alone, using a well-established experimental model for sinus floor augmentation with contemporary implant insertion.

The animal model of sinus augmentation in minipigs has been used frequently in studies because the minipig sinus has a well-defined ostium, the Schneider membrane is thin, and the size of the sinus is comparable with human sinuses (Terheyden et al. 1999, Fuerst et al. 2003, Klongnoi et al. 2006). Furthermore, minipigs have close similarities to humans in terms of platelet count, clotting parameters, metabolic rate, bone structure, and MSC characteristics (Aerssens et al. 1998, Thorwarth et al. 2005). This study also shows that the surgical procedure applied is comparable with that performed in humans. All these factors are relevant to further human clinical application.

The amount of newly formed bone following sinus augmentation was significantly enhanced in the test sites (42.51%) compared with the control sites (18.98%). These results are consistent with previous reports, which demonstrated that the transplantation of MSCs and PRP induces significant bone formation inside osteoconductive carriers in sinus augmentation procedures (Ohya et al. 2005, Ueda et al. 2005). In contrast, FH alone failed to promote significant bone formation in the current model. The small amount of newly formed bone in the control site

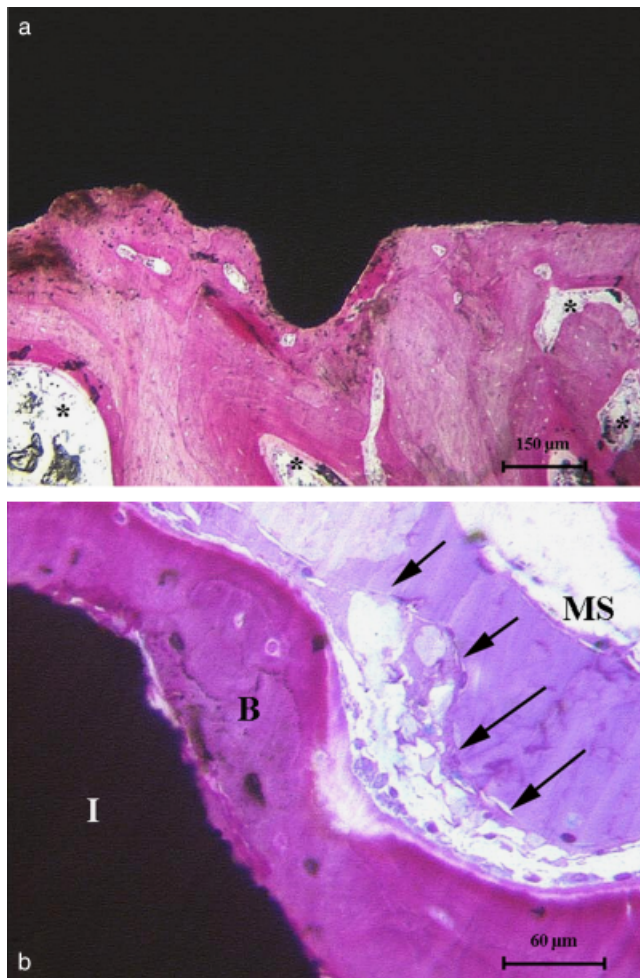


Fig. 5. Histology of the implant-bone interface at the coronal part of the titanium implant inserted into an augmented sinus. (a) Around the implant surface in the control site, the bone appears dense and mature, with small marrow spaces. Several zones contained many new cutting/filling cones building new osteons (\*) (basic fuchsin and toluidine blue; scale bar, 150  $\mu$ m). (b) Magnification of a test site from a representative specimen. An osteoblastic rim (arrows) is close to the bone (B) adjacent to the implant surface (I) (MS, marrow spaces) (basic fuchsin and toluidine blue; scale bar, 60  $\mu$ m).

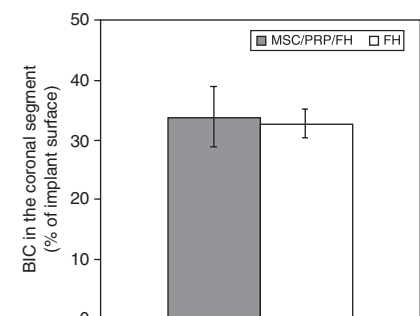


Fig. 6. Histomorphometric results of BIC in coronal segments from control and test sites, expressed as a mean percentage ( $\pm$  SD). BIC, bone-to-implant contact; MSC, mesenchymal stem cell; PRP, platelet-rich plasma; FH, fluorohydroxyapatite.



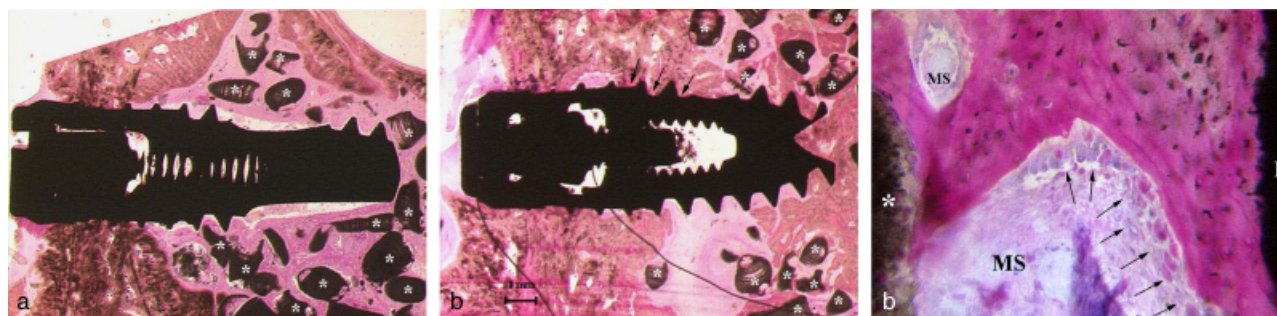


Fig. 7. Histology of the implant–bone interface at the apical part of the titanium implant inserted into an augmented sinus. (a) Overview of an implant specimen in a control site. No apposition of new bone was visible at the apical part of the implant surface. Fluorohydroxyapatite (FH) particles (\*) in the sinus floor were surrounded by connective tissue (basic fuchsin and toluidine blue; scale bar, 1 mm). (b) Overview of an implant specimen in a test site. Newly formed bone was observed along most of the implant thread, which extended to the base (arrows). The apical zone of the biopsy was composed of high-density lamellar bone with numerous interspersed FH particles (\*) almost completely covered by layers of newly formed bone (basic fuchsin and toluidine blue; scale bar, 1 mm). (c) Magnification of a test site from a representative specimen. Between the implant surface (I) and FH particles (\*), newly formed bone was always present. Osteoid bands and a rim of mature, plump osteoblasts (arrows) were seen on bone surfaces exposed to marrow spaces (basic fuchsin and toluidine blue; scale bar, 60  $\mu$ m).

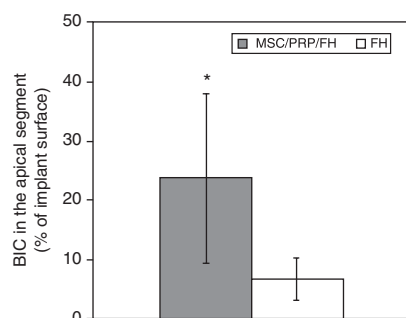


Fig. 8. Histomorphometric results of the BIC in the apical segment from control and test sites, expressed as a mean percentage ( $\pm$  SD). \*statistically significant difference ( $p < 0.05$ ). BIC, bone-to-implant contact; MSC, mesenchymal stem cell; PRP, platelet-rich plasma; FH, fluorohydroxyapatite.

was probably secondary to osteoconduction or creeping substitution, which involved the migration of minipig osteo-progenitor cells from the sinus cavity margins into the FH scaffold. Bone formation generated through this process is generally slow, and as expected, much less bone is formed in the FH-only transplant than in the transplant with MSCs and PRP. These observations compare favourably with the results reported in other studies (Fuerst et al. 2004) using the same animal model, in which sinus grafting with culture-expanded autogenous bone-derived cells and bovine hydroxyapatite resulted in significantly more bone than with bovine bone mineral alone (31.63% versus 22.5%). These prior

Table 1. Histomorphometric data (mean values and standard deviation) 3 months after sinus augmentation with MSCs–PRP in combination with FH or FH alone and simultaneous placement of a titanium implant

	MSCs/PRP/FH	FH	<i>p</i> -values MSCs/PRP/FH versus FH
Area of newly formed bone (%)	42.51 $\pm$ 7.08	18.98 $\pm$ 0.92	0.001*
Coronal bone–implant contact (%)	33.85 $\pm$ 5.15	32.66 $\pm$ 2.49	0.526
Apical bone–implant contact (%)	23.71 $\pm$ 14.31	6.63 $\pm$ 3.46	0.028*

\*Statistically significant difference (*t*-test).

studies and our findings suggest that autogenous bone-derived cells possess osteogenic potential and therefore increase bone formation in maxillary sinuses, which provides a low number of bone-forming cells.

One of the crucial points of this tissue-engineering approach is to supply the MSCs embedded within large cell-ceramic constructs, as required for sinus augmentation, with sufficient oxygen and nutrients to sustain their survival and proliferation (Schimming & Schmelzeisen 2004). Previous studies have indicated that without blood vessel ingrowth, bone formation is generated only at the surface of the construct (Abukawa et al. 2004). It is well known that MSCs are able to influence endothelial cell behaviour and vice versa (Kaigler et al. 2006). In addition, MSCs secrete vascular endothelial growth factor (VEGF), which exhibits elevated expression during osteogenesis (Mayer et al. 2005). We selected PRP as a second angiogenic factor based on

evidence that growth factors such as platelet-derived growth factor, insulin-like growth factor-I, and transforming growth factor- $\beta$  are released by the platelet gel and participate in reparative processes, including angiogenesis and osteogenesis (Marx 2004). In the present study, we postulate that the transplantation of several angiogenic inducers with MSCs combined with PRP provided an environment that promoted a greater initial angiogenic response and better consequent penetration of the cells into the depth of the scaffold, which resulted in a more rapid and sustained osteogenic response. Nevertheless, further studies are needed to confirm this hypothesis and to elucidate whether the supposed contribution of MSCs to bone formation is attributable to their angiogenic or osteogenic properties.

The literature contains no data on the influence of MSCs and PRP with an osteoconductive scaffold on the BIC of implants placed in augmented sinuses. MSCs and PRP are an effective

approach for enhancing the osseointegration of dental implants when applied to a mineral or a collagen scaffold in mandibular bone defects (Ito et al. 2006). In our study, BIC was significantly greater in the test sites in areas of newly formed bone. In addition, we observed major histological differences in terms of bone formation between the implant tip and base in the control group (6.63–32.66%). Conversely, the BIC in the MSCs–PRP group was essentially constant from the apical to the coronal part of the implant (23.71–33.85%).

Previous studies in minipigs have reported that PRP alone with bone substitute materials has little positive effect on bone regeneration in sinus lift procedures (Fuerst et al. 2003, Roldan et al. 2004). Moreover, Klongnoi et al. (2006), using the same experimental design as in the present study, demonstrated that the application of PRP combined with an FH scaffold cannot improve the osseointegration of dental implants in regenerated sinus bone compared with FH alone after 1–12 months. It is well known that seeded MSCs can provide an osteogenic cell source for new bone formation, and PRP improves expansion of MSCs and retains their differentiation and in vivo bone formation capacity (Lucarelli et al. 2003, Vogel et al. 2006). Therefore, the positive effect of MSCs and PRP on osseointegration observed in the present study suggests that the required concentration of osteogenic cells and growth factors contained in MSCs–PRP containing grafts may have been achieved. To clarify the individual contribution of MSCs and PRP to bone regeneration, a further study of sinus augmentations with PRP and FH without MSCs as positive controls is ongoing.

In conclusion, this study showed that the transplantation of MSCs and PRP in an FH scaffold, compared with FH alone, can significantly enhance bone formation in sinus lift procedures, and can significantly improve the osseointegration of endosseous implants placed in the augmented sinus. Further, in vivo studies must address the long-term behaviour of the implanted MSCs–PRP constructs under functional loading and their possible resorption.

## Acknowledgements

We thank Ms. P. Dimopoulou and Mr. Keith Smith for providing editorial assistance.

## References

- Abukawa, H., Shin, M., Williams, W. B., Vacanti, J. P., Kaban, L. B. & Troulis, M. J. (2004) Reconstruction of mandibular defects with autologous tissue-engineered bone. *Journal of Oral and Maxillofacial Surgery* **62**, 601–606.
- Aerssens, J., Boonen, S., Lowet, G. & Dequeker, J. (1998) Interspecies differences in bone composition, density, and quality: potential implications for in vivo bone research. *Endocrinology* **139**, 663–670.
- Bruder, S. P., Kraus, K. H., Goldberg, V. M. & Kadiyala, S. (1998) The effect of implants loaded with autologous mesenchymal stem cells on the healing of canine segmental bone defects. *Journal of Bone and Joint Surgery (Am)* **80**, 985–996.
- Christgau, M., Moder, D., Hiller, K.-A., Dada, A., Schmitz, G. & Schmalz, G. (2006) Growth factors and cytokines in autologous platelet concentrate and their correlation to periodontal regeneration outcomes. *Journal of Clinical Periodontology* **33**, 837–845.
- Dallari, D., Fini, M., Stagni, C., Torricelli, P., Nicoli Aldini, N., Giavaresi, G., Cenni, E., Baldini, N., Cenacchi, A., Bassi, A., Giardino, R., Fornasari, P. M. & Giunti, A. (2006) In vivo study on the healing of bone defects treated with bone marrow stromal cells, platelet-rich plasma, and freeze-dried bone allografts, alone and in combination. *Journal of Orthopaedic Research* **24**, 877–888.
- Degidi, M., Artese, L., Rubini, C., Pernotti, V., Iezzi, G. & Piattelli, A. (2006) Microvessel density and vascular endothelial growth factor expression in sinus augmentation using Bio-Oss. *Oral Diseases* **12**, 469–475.
- De Kok, I. J., Drapeau, S. J., Young, R. & Cooper, L. F. (2005) Evaluation of mesenchymal stem cells following implantation in alveolar sockets: a canine safety study. *International Journal of Oral and Maxillofacial Implants* **20**, 511–518.
- Friedenstein, A. J., Chailakhjan, R. K. & Lalykina, K. S. (1970) The development of fibroblast colonies in monolayer cultures of guinea-pig bone marrow and spleen cells. *Cell and Tissue Kinetics* **3**, 393–403.
- Fuerst, G., Gruber, R., Tangl, S., Zechner, W., Haas, R., Mailath, G., Sanroman, F. & Watzek, G. (2003) Sinus grafting with autogenous platelet-rich plasma and bovine hydroxyapatite. A histomorphometric study in minipigs. *Clinical Oral Implants Research* **14**, 500–508.
- Fuerst, G., Tangl, S., Gruber, R., Gahleitner, A., Sanroman, F. & Watzek, G. (2004) Bone formation following sinus grafting with autogenous bone-derived cells and bovine bone mineral in minipigs: preliminary findings. *Clinical Oral Implants Research* **15**, 733–740.
- Gregory, C. A., Gunn, W. G., Peister, A. & Prockop, D. J. (2004) An Alizarin red-based assay of mineralization by adherent cells in culture: comparison with cetylpyridinium chloride extraction. *Analytical Biochemistry* **329**, 77–84.
- Gronthos, S., Akintoye, S. O., Wang, C. Y. & Shi, S. (2006) Bone marrow stromal stem cells for tissue engineering. *Periodontology* **2000** **41**, 188–195.
- Ito, K., Yamada, Y., Naiki, T. & Ueda, M. (2006) Simultaneous implant placement and bone regeneration around dental implants using tissue-engineered bone with fibrin glue, mesenchymal stem cells and platelet-rich plasma. *Clinical Oral Implants Research* **17**, 579–586.
- Jensen, O. T., Shulman, L. B., Block, M. S. & Iacono, V. J. (1998) Report of the sinus consensus conference of 1996. *International Journal of Oral and Maxillofacial Implants* **13** (Suppl.), 11–45.
- Kaigler, D., Krebsbach, P. H., Wang, Z., West, E. R., Horgan, K. & Mooney, D. J. (2006) Transplanted endothelial cells enhance orthotopic bone regeneration. *Journal of Dental Research* **85**, 633–637.
- Kassolis, J. D., Rosen, P. S. & Reynolds, M. A. (2000) Alveolar ridge and sinus augmentation utilizing platelet-rich plasma in combination with freeze-dried bone allograft: case series. *Journal of Periodontology* **71**, 1654–1661.
- Klongnoi, B., Rupprecht, S., Kessler, P., Zimmermann, R., Thorwarth, M., Pongsiri, S., Neukam, F. W., Wiltfang, J. & Schlegel, K. A. (2006) Lack of beneficial effects of platelet-rich plasma on sinus augmentation using a fluorohydroxyapatite or autogenous bone: an explorative study. *Journal of Clinical Periodontology* **33**, 500–509.
- Lucarelli, E., Beccheroni, A., Donati, D., Sangiorgi, L., Cenacchi, A., Del Vento, A. M., Meotti, C., Bertoja, A. Z., Giardino, R., Fornasari, P. M., Mercuri, M. & Picci, P. (2003) Platelet-derived growth factors enhance proliferation of human stromal stem cells. *Biomaterials* **24**, 3095–3100.
- Mao, J. J., Giannobile, W. V., Helms, J. A., Hollister, S. J., Krebsbach, P. H., Longaker, M. T. & Shi, S. (2006) Craniofacial tissue engineering by stem cells. *Journal of Dental Research* **85**, 966–979.
- Marx, R. E. (2004) Platelet-rich plasma: evidence to support its use. *International Journal of Oral and Maxillofacial Surgery* **62**, 489–496.
- Mayer, H., Bertram, H., Lindenmaier, W., Korff, T., Weber, H. & Weich, H. (2005) Vascular endothelial growth factor (VEGF-A) expression in human mesenchymal stem cells: autocrine and paracrine role on osteoblastic and endothelial differentiation. *Journal of Cellular Biochemistry* **95**, 827–839.
- McMillan, P. J., Kim, J., Garrett, S. & Crigger, M. (1999) Evaluation of bone-implant integration: efficiency and precision of 3 methods. *International Journal of Oral and Maxillofacial Implants* **14**, 631–638.
- Nasr, H. F., Aichelmann-Reidy, M. E. & Yukna, R. A. (1999) Bone and bone substitutes. *Periodontology* **2000** **19**, 74–86.
- Nkenke, E., Weisbach, V., Winckler, E., Kessler, P., Schultze-Mosgau, S., Wiltfang, J. & Neukam, F. W. (2004) Morbidity of

- harvesting of bone grafts from the iliac crest for preprosthetic augmentation procedures: a prospective study. *International Journal of Oral and Maxillofacial Surgery* **33**, 157–163.
- Ohya, M., Yamada, Y., Ozawa, R., Ito, K., Takahashi, M. & Ueda, M. (2005) Sinus floor elevation applied tissue-engineered bone. Comparative study between mesenchymal stem cells/platelet-rich plasma (PRP) and autogenous bone with PRP complexes in rabbits. *Clinical Oral Implants Research* **16**, 622–629.
- Oliver, M. H., Harrison, N. K., Bishop, J. E., Cole, P. J. & Laurent, G. J. (1989) A rapid and convenient assay for counting cells cultured in microwell plates: application for assessment of growth factors. *Journal of Cell Science* **92**, 513–518.
- Piattelli, A., Scarano, A. & Quaranta, M. (1997) High-precision, cost-effective cutting system for producing thin sections of oral tissues containing dental implants. *Biomaterials* **18**, 577–579.
- Pryor, M. E., Polimeni, G., Koo, K. T., Hartman, M. J., Gross, H., April, M., Safadi, F. F. & Wikesjö, U. M. (2005) Analysis of rat calvaria defects implanted with a platelet-rich plasma preparation: histologic and histometric observations. *Journal of Clinical Periodontology* **32**, 966–972.
- Roldan, J. C., Jepsen, S., Schmidt, C., Knuppel, H., Rueger, D. C., Acil, Y. & Terheyden, H. (2004) Sinus floor augmentation with simultaneous placement of dental implants in the presence of platelet-rich plasma or recombinant human bone morphogenetic protein-7. *Clinical Oral Implants Research* **15**, 716–723.
- Schimming, R. & Schmelzeisen, R. (2004) Tissue-engineered bone for maxillary sinus augmentation. *Journal of Oral and Maxillofacial Surgery* **62**, 724–729.
- Terheyden, H., Jepsen, S., Möller, B., Tucker, M. M. & Rueger, D. C. (1999) Sinus floor augmentation with simultaneous placement of dental implants using a combination of deproteinized bone xenografts and recombinant human osteogenic protein-1. A histometric study in miniature pigs. *Clinical Oral Implants Research* **10**, 510–521.
- Thorwarth, M., Schultze-Mosgau, S., Kessler, P., Wiltfang, J. & Schlegel, K. A. (2005) Bone regeneration in osseous defects using a resorbable nanoparticulate hydroxyapatite. *Journal of Oral and Maxillofacial Surgery* **63**, 1626–1633.
- Ueda, M., Yamada, Y., Ozawa, R. & Okazaki, Y. (2005) Clinical case reports of injectable tissue-engineered bone for alveolar augmentation with simultaneous implant placement. *International Journal of Periodontics and Restorative Dentistry* **2**, 129–137.
- van den Bergh, J. P., ten Bruggenkate, C. M., Groeneveld, H. H., Burger, E. H. & Tuinzing, D. B. (2000) Recombinant human bone morphogenetic protein-7 in maxillary sinus floor elevation surgery in 3 patients compared to autogenous bone grafts. A clinical pilot study. *Journal of Clinical Periodontology* **27**, 627–636.
- Vogel, J. P., Szalay, K., Geiger, F., Kramer, M., Richter, W. & Kasten, P. (2006) Platelet-rich plasma improves expansion of human mesenchymal stem cells and retains differentiation capacity and in vivo bone formation in calcium phosphate ceramics. *Platelets* **17**, 462–469.

Address:  
 Francesco Pieri  
 Via San Vitale 59  
 40139 Bologna  
 Italy  
 E-mail: checcopieri@yahoo.it

#### Clinical Relevance

*Scientific rationale for the study:* A tissue-engineering approach using mesenchymal stem cells (MSCs) and platelet-rich plasma (PRP) has been introduced as a regenerative treatment for sinus augmentation. However, their combination with osteoconductive scaffolds may influence the effectiveness of MSCs and

PRP in enhancing bone regeneration. This study was performed to investigate whether MSCs–PRP–fluorohydroxyapatite (FH) constructs enhance bone apposition to the implant surface, compared with FH alone, in sinus augmentation.

*Principal findings:* The histomorphometric evaluation showed a significant increase in bone formation in

the augmented sinus and bone-to-implant contact after MSCs–PRP–FH implantation compared with FH alone.

*Practical implications:* MSCs and PRP, combined with FH, may represent a practical approach for enhancing bone regeneration in sinus grafting.



This document is a scanned copy of a printed document. No warranty is given about the accuracy of the copy. Users should refer to the original published version of the material.