

Immediate non-occlusal loading of single implants in the aesthetic zone: a randomized clinical trial

Laurens den Hartog¹, Gerry M. Raghoobar¹, Kees Stellingsma¹, Arjan Vissink¹ and Henny J.A. Meijer^{1,2}

¹Department of Oral and Maxillofacial Surgery, University Medical Center Groningen, University of Groningen, Groningen, The Netherlands; ²Department of Prosthodontics, Center for Dentistry and Oral Hygiene, University Medical Center Groningen, University of Groningen, Groningen, The Netherlands

den Hartog L, Raghoobar GM, Stellingsma K, Vissink A, Meijer HJA. Immediate non-occlusal loading of single implants in the aesthetic zone: a randomized clinical trial. *J Clin Periodontol* 2011; 38: 186–194. doi: 10.1111/j.1600-051X.2010.01650.x.

Abstract

Aim: This study compared the outcome of immediate non-occlusal loading with conventional loading for single implants in the maxillary aesthetic zone. It was hypothesized that immediate non-occlusal loading is not inferior to conventional loading.

Materials and Methods: Sixty-two patients with a missing maxillary anterior tooth were randomly assigned to be treated with an implant that was either restored with a non-occluding temporary crown within 24 h after implant placement (the “immediate group”) or was restored according to a two-stage procedure after 3 months (the “conventional group”). All implants were installed in healed sites. Follow-up visits were conducted after 6 and 18 months post-implant placement. Outcome measures were radiographic marginal bone-level changes, survival, soft tissue aspects (probing depth, plaque, bleeding, soft tissue level), aesthetics and patient satisfaction.

Results: No significant differences were found between both study groups regarding marginal bone loss (immediate group 0.91 ± 0.61 mm, conventional group 0.90 ± 0.57 mm), survival (immediate group 96.8%: one implant lost, conventional group 100%), soft tissue aspects, aesthetic outcome and patient satisfaction.

Conclusion: Within the limitations of this study (sample size, follow-up duration), it was demonstrated that, for single implants in the anterior maxilla, the outcome of immediate non-occlusal loading was not less favourable than conventional loading.

Key words: aesthetics; bone level; dental implant; immediate loading; single tooth; soft tissue

Accepted for publication 16 October 2010

Dental implants are commonly applied to replace missing teeth. Traditionally, implants were subjected to a load-free healing period of several months, allowing the implant to osseointegrate without being exposed to external forces. Over the last few years, the concept of immediate loading has gained attention. This concept is defined as the applica-

tion of a load by means of an occluding or a non-occluding restoration within 48 h of implant placement (Laney 2007). If the implant is loaded with a non-occluding restoration, this is also known as immediate non-occlusal loading and loading occurs from lip and tongue pressure and contact with food, but not from occlusal forces of the opposing dentition (Laney 2007).

Patients with a missing anterior tooth may benefit from immediate loading. Placement of the (temporary) implant crown immediately after implant placement reduces the overall treatment time, avoids a second-stage operation and offers immediate comfort as there is no need for a temporary removable prosthesis during the healing phase.

Besides the beneficial effects of immediate loading, this concept also has some inherent thought disadvantages. For example, immediate loading might induce micromotion and instability of the implant (Gapski et al. 2003, Trisi et al. 2009). Implant instability might result in fibrous encapsulation of the implant and failing osseointegration (Lioubavina-Hack et al. 2006). Albeit yet applied on implants placed in mandibles to support bridges or bar-retained overdentures (Esposito et al. 2009), immediate loading of maxillary single implants might involve more risk. The quality of bone is poorer in the maxilla than in the mandible in the context of achieving primary implant stability (Mesa et al. 2008, Trisi et al. 2009,

Conflict of interest and sources of funding

The authors declare that they have no conflict of interests.

This study was funded by Nobel Biocare AB, Göteborg, Sweden (grant # 2004-288).

Roze et al. 2009). Thus, implants in this region might be more susceptible to micromotion. Furthermore, force distribution to other implants by splinting is not possible for single implants.

In contrast to the mandible, well-designed clinical trials on immediate loading of single implants in the anterior maxilla are scarce (Ericsson et al. 2000, Hall et al. 2007, Den Hartog et al. 2008, Palattella et al. 2008) and there is limited evidence regarding the effect of immediate loading on peri-implant marginal bone and soft tissues responses (Glauser et al. 2006, Den Hartog et al. 2008, Grutter & Belser 2009). Therefore, the aim of this study was to compare the outcome of immediate non-occlusal loading with that of conventional loading of implants applied to replace a missing anterior maxillary tooth. It was hypothesized that immediate non-occlusal loading is not inferior to conventional loading.

Materials and Methods

Patients

Patients referred to the department of Oral and Maxillofacial Surgery (University Medical Center Groningen, University of Groningen, Groningen, the Netherlands) for anterior single-implant treatment were considered for inclusion if they fulfilled the following criteria:

- at least 18 years of age;
- one missing tooth being an incisor, canine or first pre-molar in the maxilla with adjacent natural teeth;
- adequate oral hygiene, i.e. modified plaque index score and modified sulcus bleeding index score ≤ 1 (Mombelli et al. 1987);
- mesial-distal width of inter-dental space at least 6 mm; and
- vertical occlusal dimensions allow for the creation of a non-occluding temporary crown.

Exclusion criteria were:

- ASA score \geq III (Smeets et al. 1998);
- presence of active clinical periodontal disease as expressed by probing pocket depths ≥ 4 mm and bleeding on probing;
- presence of peri-apical lesions or any other abnormalities in the maxillary anterior region as determined on a radiograph;
- smoking; and

- a history of radiotherapy to the head and neck region.

Study design

This randomized clinical trial was approved by the Institutional Review Board of the University Medical Center Groningen (UMCG IRB 2010072). Before enrolment, written and verbal information was given to the patients and written informed consent was obtained. Patients were included between January 2005 and February 2008.

A specifically designed locked computer software program was used to randomly assign patients to one of two study groups to receive an implant with an anodized surface (NobelReplace Tapered Groovy, Nobel Biocare AB, Göteborg, Sweden), which was either restored within 24 h after implant placement (''immediate group'') or was restored according to a two-stage procedure after 3 months of healing (''conventional group''). Randomization by minimization (Altman 1991) was used to balance possible prognostic variables between the treatment groups. Minimization was used for the variables age (≤ 30 years, $>31 \leq 60$ years, >60 years), location of the implant site (central or lateral incisor, canine or first premolar) and whether or not a pre-implant augmentation procedure was indicated based on a clinical and diagnostic cast assessment. The allocation result was kept in a locked computer file that was not accessible for the examiner and the practitioners. The surgeon who inserted the implants was informed about the allocation on the day of surgery, before implant surgery was started.

Interventions

All implants were placed in healed sites at least 3 months after tooth removal, allowing the extraction site to heal. Implant sites were primarily free from clinical signs of inflammation. When bone volume was insufficient for implant insertion, a bone augmentation procedure was carried out. As a grafting material, autogenous bone from the retromolar ramus or the maxillary tuberosity area was used together with anorganic bovine bone (Bio-Oss, Geistlich Pharma AG, Wolhusen, Switzerland) covered with a collagen membrane (Bio-Gide, Geistlich Pharma AG). Implants were inserted 3 months after the augmentation procedure.

The implants that were used (NobelReplace Tapered Groovy, Nobel Biocare AB) were either 13 or 16 mm in length and were 3.5 mm (narrow platform) or 4.3 mm (regular platform) in diameter. Implants were placed and restored according to the protocol as described in detail in a previous clinical report (Den Hartog et al. 2009). Briefly, a surgical template was used to install the implants at a depth of 3 mm apical to the buccal and cervical aspect of the prospective clinical crown. All implants were installed using a torque value controller (OsseoCare, Nobel Biocare AB) adjusted to an insertion torque of 45 Ncm. A manual torque controller (Nobel Biocare AB) was used to realize the proper implant depth if this torque value was reached before the implant had reached its planned position.

In the immediate group, an implant-level impression was made. A healing abutment was connected to the implants in the immediate group and a cover screw to the implants in the conventional group. Before wound closure and if necessary, in both study groups, implant dehiscences or fenestrations were covered with autogenous bone chips collected during implant bed preparation and anorganic bovine bone (Bio-Oss) overlaid with a collagen membrane (Bio-Gide). Within 24 h, a screw-retained temporary crown was placed in the immediate group. This crown was free from centric and eccentric contacts with the antagonist teeth. Patients were instructed to follow a soft diet and to avoid exerting force on the temporary restoration.

Patients in the conventional group were wearing a removable partial prosthesis that did not interfere with the wound. These implants were uncovered after 3 months and restored with a temporary crown according to the same procedure as in the immediate group.

After a temporary phase of 3 months for the conventional group and 6 months for the immediate group (to allow for 6 months post-implant placement for both study groups), a definitive crown was made consisting of an individually fabricated zirconia abutment (Procera, Nobel Biocare AB). Depending on the location of the screw access hole, crowns were either screw-retained by fusing porcelain directly to the abutment or cement-retained by means of a zirconia Procera coping (Nobel Biocare AB). Cemented-retained crowns were cemented with glass ionomer cement (Fuji

Plus cement, GC Europe, Leuven, Belgium).

All surgical procedures were performed by a single experienced oral and maxillofacial surgeon (G. M. R.). The prosthetic procedure was accomplished by two experienced prosthodontists (H. J. A. M. and K. S.), and all crowns were fabricated by one dental technician (H. S.).

Outcome measures

The primary outcome measure of this study was marginal bone-level change proximal to the implant 18 months after implant placement as measured on radiographs. Secondary outcome measures were implant survival, change in the peri-implant mucosal level, aesthetic outcome, papilla volume, amount of plaque, bleeding after probing, probing pocket depth and patient satisfaction. Both the implant and the adjacent teeth were analysed. All measurements were performed by one and the same examiner (L. d. H.). To assess the reliability of the radiographic and photographic examination, this examiner was assisted by a second examiner (E. S.). The operationalization of the variables is described below.

Radiographic and photographic assessments

After implant placement (baseline, T_0), and after 6 (T_{6m} , after definitive crown placement) and 18 months (T_{18m}), standardized digital intra-oral radiographs were taken using a long-cone paralleling technique. Standardized digital photographs (camera: Fuji-film FinePix S3 Pro, Tokyo, Japan) were gathered before implant placement (T_{pre}) and at T_{6m} and T_{18m} . The radiographic and photographic procedure has been described in detail by Meijndert et al. (2004). For calibration of the photographs, a calibrated probe was held in close contact and parallel to the long axis of a tooth adjacent to the implant. The examiner was blinded to the photographs and the radiographs taken at T_{6m} and T_{18m} . The radiographic examination could not be blinded to the radiographs collected after implant placement (baseline, T_0), as the study group could be deduced from these radiographs. Full-screen analysis of the radiographs was performed using a specifically designed software. Radiographs were calibrated according to the known diameter of the implant.

Reference points were marked and marginal bone levels proximal to the implant were measured according to the first bone-to-implant contact together with marginal bone levels of the adjacent teeth (Fig. 1). Full-screen analysis of the photographs was performed using Adobe Photoshop (Adobe Photoshop CS3 Extended, Adobe Systems Inc., San Jose, CA, USA). After calibration, mid-facial mucosal and papilla levels of the implant were measured after definitive crown placement (from T_{6m}). Mid-facial gingival levels of the adjacent teeth were measured from T_{pre} . The incisal edges of the implant crown and adjacent teeth were used as a reference.

To assess the reliability of the radiographic and photographic examination, 30 radiographs and photographs (15 from each study group) were randomly selected and were measured by two examiners and by one examiner twice with a 2-week interval. The intra-observer agreement of the photographic examination was tested earlier and reported as good, with a mean difference of 0.11 ± 0.02 mm between both times of measurements (Meijndert et al. 2004).

Clinical assessments

At T_{pre} (before implant placement), T_{6m} and T_{18m} , patients were seen for clinical data collection. Both the implant and the adjacent teeth were analysed at the

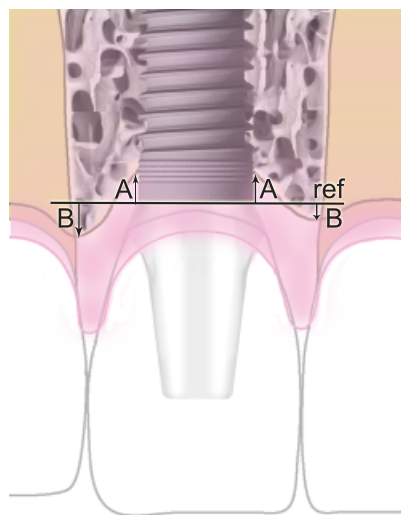


Fig. 1. Schematic drawing of the radiographic assessment. Ref, reference line; A and B, distances from the reference line to the marginal bone levels of implant and adjacent teeth.

facial aspect. The examiner was blinded for the protocol that was applied for a particular patient. Variables were: *plaque*, using the modified plaque index (Mombelli et al. 1987), *bleeding*, using the modified sulcus bleeding index (Mombelli et al. 1987), *volume of the interproximal papilla*, using the papilla index (Jemt 1997), *width of attached mucosa*, using the ‘‘attached mucosa index’’ (Cox & Zarb 1987), and *probing pocket depth*, measured to the nearest 1 mm using a manual periodontal probe (Williams Color-Coded Probe, Hu-Friedy, Chicago, IL, USA). During follow-up, implant survival was registered (defined as the existence of an implant in the oral cavity. (Laney et al. 2007)).

Aesthetic assessments

The aesthetics of the peri-implant mucosa and implant crown were determined on photographs taken at T_{18m} using the Implant Crown Aesthetic Index (ICAI) (Meijer et al. 2005) and the Pink Esthetic Score-White Esthetic Score (PES-WES) (Belser et al. 2009). The examiner was blinded to the group allocation. The inter-observer reliability was assessed according to 10 randomly selected photographs from each study group (20 in total) that were judged by two examiners and by one examiner twice with a 2-week interval. The intra-observer reliability has been reported as acceptable in earlier studies. (Meijer et al. 2005, Belser et al. 2009)

Patient satisfaction

Patient satisfaction was assessed using a self-administered questionnaire to be completed at T_{6m} and T_{18m} . The questionnaire comprised of questions or statements that could be answered on a five-point rating scale ranging from ‘‘very dissatisfied’’ and ‘‘not in agreement’’ (score 1) to ‘‘very satisfied’’ and ‘‘in agreement’’ (score 5). Responses were dichotomized into ‘‘satisfied’’ versus ‘‘not satisfied’’ and ‘‘in agreement’’ versus ‘‘not in agreement’’ using the following criteria: scores of 4 and 5 were considered as being ‘‘satisfied’’ or ‘‘in agreement’’. Topics were aesthetics, function and treatment procedure. Furthermore, patients were asked to mark their overall satisfaction on a 100 mm visual analogue scale (VAS) having end phrases ‘‘very dissatisfied’’ (0) on the left end and ‘‘very satisfied’’ (100) on the right end.

Data analysis

A non-inferiority analysis was used to compare immediate non-occlusal loading with conventional loading. Non-inferiority of immediate to conventional loading was defined as <0.5 mm mean marginal bone loss (both proximal sides combined). It was assumed that a mean marginal bone loss of 1.0 ± 0.6 mm would occur from implant placement to 18 months thereafter for implants restored according to a conventional protocol (Den Hartog et al. 2008). With a one-sided significance level of 5% and a power of 90%, a minimum of 26 patients per group was required. The number of patients per group was set at 31 to deal with withdrawal.

The intra- and inter-observer agreements for the radiographic and photographic assessments were expressed as the 95% limits of agreement (Altman 1991), representing the interval containing 95% of the differences between the observations to be compared. In addition, intra-class correlation coefficients were calculated for continuous variables and linear weighted κ for categorical variables.

For between-group comparisons of numeric and normally distributed variables (assessed using the Kolmogorov–Smirnov test), *t*-tests were used. Variables that were not normally distributed were statistically explored using Mann–Whitney tests. Friedman tests were applied for several within-group comparisons and Wilcoxon's signed-rank tests to compare two dependent conditions. Categorical variables were statistically explored with χ^2 or Fisher's exact tests.

In all analyses, a significance level of 0.05 was chosen. Data were analysed using the Statistical Package for Social Sciences (version 16.0, SPSS Inc, Chicago, IL, USA).

Results

A total of 62 patients were allocated to the study groups of this trial (Table 1 and Fig. 2). Most of the teeth that were lost had a history of trauma. All implants were placed with a minimum insertion torque of 45 Ncm. Details about the surgical and prosthetic procedures are depicted in Table 1. There were no drop-outs and all patients attended the follow-up visits (Fig. 2).

Table 1. Baseline characteristics and treatment specifications of 62 patients treated with an immediate or a conventional implant procedure

Variable	Immediate group (<i>n</i> = 31)	Conventional group (<i>n</i> = 31)
Mean age (years) \pm SD range (years)	38.4 \pm 14.0 18–66	40.1 \pm 14.4 18–67
Male/female ratio	9/22	17/14
Tooth gap position I ₁ /I ₂ /C/P ₁	14/10/4/3	18/8/3/2
Cause of tooth loss		
Fracture (crown or root)	22	15
Agenesis	6	4
Endodontic failure	1	8
Periodontal failure	—	2
Root resorption	2	2
Augmentation before implant surgery*	9	11
Implant diameter		
3.5 mm (narrow platform)	10	10
4.3 mm (regular platform)	21	21
Implant length		
13 mm	4	2
16 mm	27	29
Implant-tooth distance		
Mean \pm SD (mm)	2.16 \pm 0.66	2.17 \pm 0.77
Range	0.54–4.37	0.45–5.26
Final restoration		
Screw-retained	12	12
Cement-retained	18	19

*Implants were installed after 3 months.

SD, standard deviation.

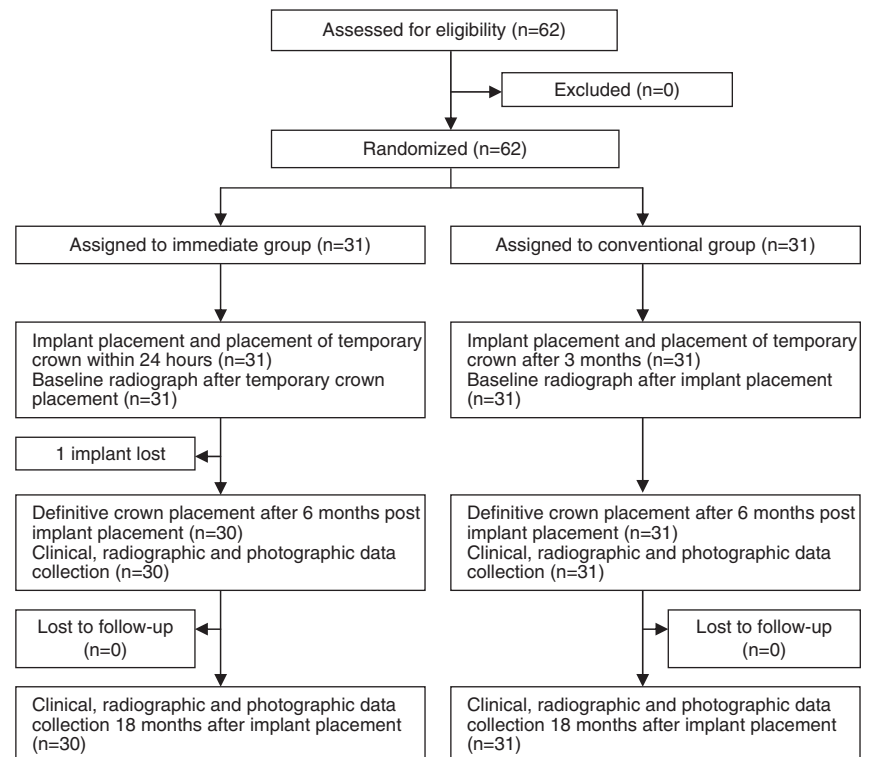


Fig. 2. Randomization, treatment procedure and follow-up of study participants.

Reliability of radiographic and photographic assessments

For the intra-observer agreement of the radiographic examination, the mean difference between the observations was 0.03 ± 0.23 mm (limits of agreement: -0.43 and 0.49 mm). For the inter-observer agreement, the mean difference for the radiographs and photographs was -0.02 ± 0.33 mm (limits of agreement: -0.68 and 0.64 mm) and -0.02 ± 0.18 mm (limits of agreement: -0.38 and 0.34 mm), respectively.

The intra-class correlation coefficients were 0.95 and 0.98 for the radiographic inter- and intra-observer agreement, respectively, and 0.99 for the photographic inter-observer agreement, all signifying high levels of agreement.

Marginal bone-level change

The mean marginal bone loss (mesial and distal implant sides combined) from implant placement (baseline, T_0) to 18 months thereafter (T_{18m}) was 0.91 ± 0.61 mm in the immediate group [95% confidence interval (CI): 0.69 – 1.13] and 0.90 ± 0.57 mm in the conventional group [95% CI: 0.70 – 1.10] ($p > 0.05$) (Table 2). In both study groups, the amount of bone loss proximal to the implant had decreased significantly after the second follow-up visit (T_{6m}) (Table 2). There were no significant differences between both the study groups regarding bone-level changes at the adjacent teeth.

Clinical outcome

One implant in the immediate group was lost 3 weeks after placement due to high mobility, resulting in an implant survival rate at T_{18m} of 96.8% for the immediate group and 100% for the conventional group ($p > 0.05$). As the implant was lost before the first follow-up visit, this implant could not be included in the radiographic and clinical data analysis.

No between-group differences in soft tissue level changes around the implants and adjacent teeth were observed (Table 2). After definitive crown placement, the level of the mid-facial peri-implant mucosa remained stable while a mean gain of the papilla level of 0.34 ± 0.49 and 0.27 ± 0.42 mm was observed in the immediate and the conventional group, respectively ($p > 0.05$) (Table 2). From T_{pre} to T_{18m} , the mid-facial

gingival level of the adjacent teeth showed a mean recession of 0.29 ± 0.44 mm in the immediate group and 0.28 ± 0.36 mm in the conventional group ($p > 0.05$), which predominantly occurred during the first evaluation period.

The clinical assessments yielded no significant differences between both the groups for probing pocket depth (Table 1), plaque index, bleeding index, papillae index and width of attached mucosa. Bleeding index scores of the adjacent teeth were significantly lower compared with the scores of the implants (Fig. 3). The volume of the distal papillae, expressed in papilla index scores, increased significantly during follow-up (Fig. 4). Plaque index scores were low at both follow-up visits. At T_{18m} , a plaque score of 1 was assigned to three implants in both the study groups. All other implants did not show any plaque. Within-group analysis revealed lower plaque scores for the adjacent teeth at T_{6m} and T_{18m} compared with the pre-operative situation (T_{pre}) ($p < 0.05$). The height of the keratinized epithelium around two implants in the conventional group was < 2 mm, whereas the height around all other implants was > 2 mm.

Aesthetic outcome

The PES/WES showed satisfactory inter-observer agreement (weighted of 0.70 for the PES and 0.64 for the WES). However, the ICAI showed only satisfactory inter-observer agreement for the assessment of the mucosa (κ -value 0.62 for the mucosa and 0.41 for the crown). Therefore, the aesthetics of the implant crowns were only evaluated using WES.

No differences were noticed regarding the aesthetics of the peri-implant mucosa (pink aesthetics) and the implant crown (white aesthetics) as measured using both aesthetic evaluation instruments ($p > 0.05$). The pink aesthetics were judged with a mean PES of 7.1 ± 1.5 (range 3–10) and 6.5 ± 1.63 (range 4–10) for the immediate and the conventional group, respectively. According to the ICAI, the pink aesthetics were satisfactory in 24 cases (80%) in the immediate group and 19 cases in the conventional group (62%), of which one case in both groups showed excellent pink aesthetics. The white aesthetics in the immediate group were judged with a mean WES of 7.8 ± 1.5 (range 4–10) and in the conventional group with a mean of 7.6 ± 1.6 (range 4–10).

Patient satisfaction

Patient satisfaction was high in both study groups and no differences were observed between the groups (Table 3). At both follow-up visits (T_{6m} and T_{18m}), one-third of the patients in the conventional group mentioned the healing time of the implant as long.

Discussion

This randomized clinical trial revealed that the treatment outcome of immediate non-occlusal loading of a single implant in the maxillary anterior zone is not less favourable than conventional loading. After 18 months of follow-up, both treatment strategies showed an equal amount of radiographic peri-implant marginal bone loss and no differences in survival, soft tissue aspects, aesthetic outcome and patient satisfaction.

Studies on immediate loading are often founded on implant survival rates. This is indeed a major outcome determining treatment success to a high extent. In our study, the survival rates were 96.8% for the immediate group (one implant failed) and 100% for the conventional group. These high survival rates were confirmed by other studies on immediately loaded implants, even when inserted into fresh extraction sockets (Den Hartog et al. 2008). We realize that the sample size of our study was too small to demonstrate whether immediate loading was non-inferior to conventional loading with respect to implant survival. Additional (long-term) studies would be helpful to draw firm conclusions regarding the potential hazardous effect of immediate loading on the process of osseointegration.

The quality of survival is another major factor for rating treatment success, particularly in aesthetically delicate areas. Therefore, this study also focused on the quality of survival, as determined using several outcome measures. We considered peri-implant marginal bone loss as a determining factor for the quality of survival and thus as our primary outcome measure. First, the level of the peri-implant marginal bone has been suggested to determine the level of the peri-implant mucosa and thus the aesthetic outcome (Bengazi et al. 1996, Chang et al. 1999, Hermann et al. 2001). Second, marginal bone loss may induce pocket formation, which could be unfavourable for the long-term health of the peri-implant tissues

Table 2. Changes in the marginal bone level and marginal soft tissue level at implant and tooth sides from baseline to 18 months

	Baseline*– T_{6m}		T_{6m} – T_{18m}		Baseline*– T_{18m}	
	imm. (n = 30) [†]	conv. (n = 31)	imm. (n = 30) [†]	conv. (n = 31)	imm. (n = 30) [†]	conv. (n = 31)
Marginal bone-level changes (mm)						
Mesial of implant	–0.73 ± 0.54	–0.79 ± 0.62	–0.13 ± 0.55	–0.13 ± 0.40	–0.87 ± 0.55	–0.91 ± 0.66
Distal of implant	–0.75 ± 0.68	–0.81 ± 0.76	–0.19 ± 0.35	–0.09 ± 0.41	–0.95 ± 0.84	–0.90 ± 0.77
Mesial tooth side	–0.20 ± 0.39	–0.25 ± 0.38	–0.02 ± 0.22	0.03 ± 0.28	–0.22 ± 0.38	–0.17 ± 0.40
Distal tooth side	–0.26 ± 0.47	–0.18 ± 0.34	0.02 ± 0.45	–0.03 ± 0.42	–0.24 ± 0.40	–0.29 ± 0.50
Implant bone loss (%) [‡]						
≤ 1 mm	71.6	62.9	96.7	100	63.3	56.5
1–2 mm	25	33.9	1.7	0	30	38.7
≥ 2 mm	3.3	3.2	1.7	0	6.7	4.8
Marginal soft tissue-level changes (mm)						
Mesial implant papilla			0.41 ± 0.49	0.19 ± 0.29		
Distal implant papilla			0.27 ± 0.49	0.35 ± 0.52		
Mid-facial of implant			0.06 ± 0.42	–0.09 ± 0.34		
Mesial tooth	–0.20 ± 0.38	–0.13 ± 0.39	–0.04 ± 0.23	–0.09 ± 0.25	–0.25 ± 0.42	–0.22 ± 0.36
Distal tooth	–0.41 ± 0.52	–0.33 ± 0.51	0.10 ± 0.30	0.00 ± 0.30	–0.32 ± 0.51	–0.33 ± 0.36

	Baseline*		T_{6m}		T_{18m}	
	imm.	conv.	imm.	conv.	imm.	conv.
Probing pocket depth (mm)						
Mesial of implant			3.07 ± 0.91	3.03 ± 0.89	3.28 ± 1.03	3.19 ± 0.91
Distal of implant			3.37 ± 0.93	3.50 ± 0.82	3.62 ± 1.12	3.81 ± 1.28
Mid-facial of implant			2.78 ± 0.58	3.07 ± 0.74	3.14 ± 0.92	3.32 ± 0.79
Proximal of teeth [‡]	2.03 ± 0.44	2.03 ± 0.51	1.81 ± 0.45	1.92 ± 0.49	1.87 ± 0.56	1.99 ± 0.60
Mid-facial of teeth	1.35 ± 0.37	1.37 ± 0.39	1.45 ± 0.70	1.40 ± 0.42	1.55 ± 0.75	1.37 ± 0.34

Plus-minus values are means ± SD.

*After implant placement for bone levels and before implant placement for gingival levels and pocket depths.

[†]One implant was lost 3 weeks after implant placement.

[‡]Mesial and distal sides combined.

Imm., immediate group; Conv., conventional group; T_{6m} , 6 months after implant placement; T_{18m} , 18 months after implant placement.

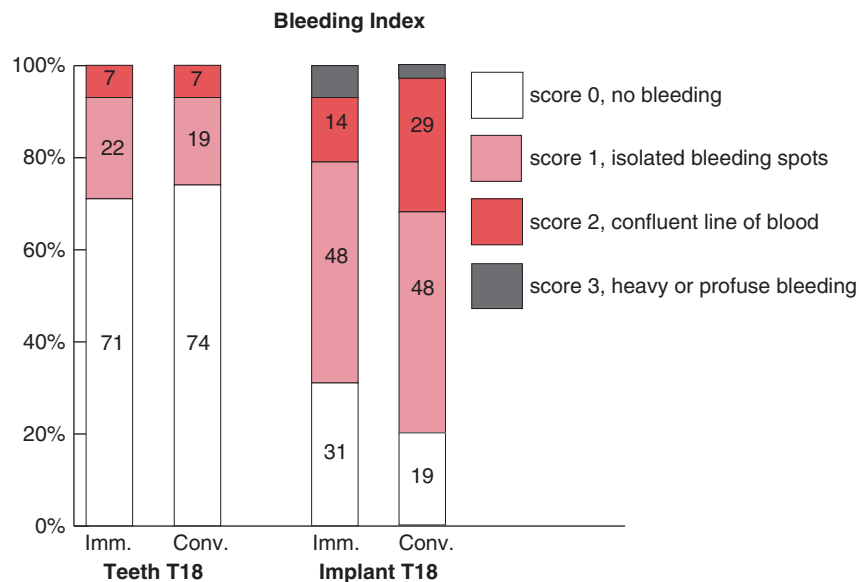


Fig. 3. Frequency distribution of bleeding index scores for implants and adjacent teeth at 18 months after implant placement. Imm., immediate group; Conv., conventional group.

(Rams et al. 1984, Heydenrijk et al. 2002). Measurement of marginal bone on peri-apical radiographs is generally

accepted as a reliable and feasible instrument to measure the true bone level at least at the proximal side of

the implant, and offers fixed reference points from the moment of implant placement to years thereafter, allowing for a longitudinal study.

No differences were observed between immediate and conventional loading regarding marginal bone loss at 6 and 18 months post-implant placement and the values we found were consistent with what has been reported in other studies on immediate and conventional single-tooth implants in the anterior zone (Hall et al. 2007, Den Hartog et al. 2008, Degidi et al. 2009). As it is known that the proximal bone level next to the adjacent teeth is highly relevant for the level of the proximal papillae of the implant (Choquet et al. 2001, Kan et al. 2003, Block et al. 2009), these bone levels were also taken into consideration as an important predictor for the aesthetic outcome. In both study groups, only a small amount of bone loss at the adjacent teeth was noticed during follow-up. It is questionable whether this amount of bone loss affected the level of the implant papillae, which gained height during follow-up. However, it should be

realized that implant therapy is not without consequences for the mid-facial level of the adjacent teeth, showing a recession of about 0.3 mm in both groups with an even standard deviation.

There is growing evidence that immediate loading of implants inserted into fresh extraction sockets would lead to more favourable soft-tissue levels compared with a delayed strategy (De Rouck et al. 2009, Block et al. 2009). These studies showed that immediate stabilization of the soft tissue after tooth removal by means of immediate implant placement and immediate placement of the temporary crown revealed 0.75–

1 mm more soft tissue preservation mid-facially. However, the reliability of this strategy should be established by more well-designed studies (Den Hartog et al. 2008). In our study, all implants were inserted into healed sites. After tooth removal, the walls of the alveolus undergo substantial resorption, affecting the soft-tissue anatomy (Schropp et al. 2003, Araujo & Lindhe 2005). It could be that for healed sites, the potential positive effect of an immediate (temporary) crown on soft tissue preservation subsided. When using the PES and ICAI as instruments to express soft-tissue aesthetics, at least

no significant difference between immediate and conventionally loaded implants was observed. The same applied to the volume of the papilla assessed with the papilla index. This index in particular could, however, be more related to the bone level of the adjacent teeth as discussed earlier. More clinical trials are needed investigating the influence of an immediately placed (temporary) crown on soft-tissue parameters.

Overall patient satisfaction was high in both study groups and patients were satisfied regarding function, aesthetics and the treatment procedure. Other studies on anterior single implants reported comparable overall satisfaction scores of 88 and higher (also using VAS) (Schropp et al. 2004, Den Hartog et al. 2008). As confirmed by other studies (Levi et al. 2003, Schropp et al. 2004), a substantial percentage of conventionally treated patients (30%) experienced the healing time of the implant as long. Although Levi et al. (2003) found that treatment time was not a critical factor for overall satisfaction, the shorter treatment time of an immediate loading strategy might serve these patients.

It is important to reach sufficient primary implant stability before performing immediate loading. However, the threshold for sufficient primary stability has not been adopted uniformly in studies on immediate single implant

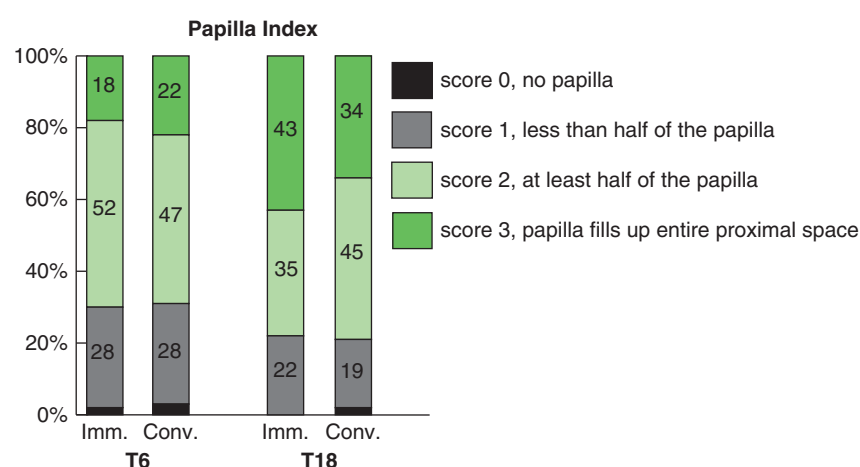


Fig. 4. Frequency distribution of papilla index scores at 6 and 18 months after implant placement. Imm., immediate group; Conv., conventional group.

Table 3. Patient satisfaction regarding function, aesthetics, treatment procedure and general satisfaction

Topic	<i>T</i> _{6m} % satisfied*		<i>T</i> _{18m} % satisfied*	
	imm. (<i>n</i> = 30) [†]	conv. (<i>n</i> = 31)	imm. (<i>n</i> = 30) [†]	conv. (<i>n</i> = 31)
Function				
Eating	97	94	100	97
Speaking	97	94	100	100
Aesthetics				
Colour of the crown	100	100	93	97
Form of the crown	93	97	100	100
Colour of the mucosa around the crown	97	90	97	87
Form of the mucosa around the crown	87	80	87	87
	% In agreement*		% In agreement*	
	imm.	conv.	imm.	conv.
Treatment procedure				
The healing time of the implant was long	NA	26		32
I did not like the visits to the dentist to make the crown	0	3	3	10
I regret that I choose this treatment	0	0	0	0
I would recommend the treatment to other patients	97	100	100	100
General satisfaction (VAS-score; mean ± SD)	91.5 ± 8.4	89.5 ± 9.5	92.7 ± 9.0	89.0 ± 9.8

*Represents per cent satisfied or in agreement on a five-point scale (4 or 5 equals satisfied or in agreement).

[†]One implant was lost 3 weeks after placement.

Imm., immediate group; Conv., conventional group; *T*_{6m}, 6 months after implant placement; *T*_{18m}, 18 months after implant placement; NA, not applicable; VAS, visual analogue scale.

loading. Furthermore, different methods were used to assess primary implant stability or the method to assess stability was not reported (Den Hartog et al. 2008). We utilized insertion torque as a diagnostic tool to express implant stability. As it has been reported that insertion torque is related to the amount of micromotion (Trisi et al. 2009), we believe that this is a viable method. In our study, all implants could be installed with a minimum insertion torque of 45 Ncm. Although a lower value was not considered as an exclusion criterion beforehand, this may introduce a higher risk of implant failure. A minimum torque value of 35 Ncm has been adopted successfully in other studies on immediate loading, even when inserted into fresh extraction sites (Wang et al. 2006, De Rouck et al. 2009).

It has been found that in addition to the anatomy of the bone (Mesa et al. 2008, Roze et al. 2009) and preparation technique (Tabassum et al. 2010), the geometry and length of the implant are factors that influence primary stability. In our study, almost all implants were 16 mm in length, the longest available for the type of implant we used. Furthermore, the implants had a rough surface topography and a tapered design, both favouring primary implant stability (O'Sullivan et al. 2004, Dos Santos et al. 2009). It might be attributed to these factors that we had no difficulties reaching sufficient primary implant stability.

In our study, temporary crowns were free from centric and eccentric contacts with the antagonist teeth. Results from single implant studies on immediate occlusal loading with a (temporary) crown in centric occlusion suggest that this might lead to comparable survival rates as immediate non-occlusal loading (Rao & Benzi 2007, Glauser et al. 2007, Schincaglia et al. 2008). However, these studies focused on tooth replacements in posterior regions in particular where implants were subjected to more vertically directed forces. In the anterior region, the lateral component of occlusal force is more dominant (Katona et al. 1993, Lin et al. 2007) and could act as a disrupting factor in the process of implant integration. We did not experience any problems in creating a non-occluding temporary crown with acceptable aesthetics and therefore recommend this more reserved strategy above an occlusal loading concept. Furthermore, a dominant role should

be ascribed to carefully instructing the patient to follow a soft diet and to avoid exerting force on the temporary restoration. Besides, it should be realized that we adopted inclusion and exclusion criteria that might have had a positive effect on the treatment outcome (for instance, only non-smokers were included).

In conclusion, this study demonstrated that immediate non-occlusal loading of a single implant in the maxillary aesthetic zone leads to a short-term treatment outcome that is not less favourable than conventional loading. As immediate loading reduces the treatment time and could offer more comfort for the patient, we recommend this strategy to be considered as an alternative to conventional loading. However, the concept of immediate non-occlusal loading should be performed according to a specified protocol with attention to adequate primary implant stability and careful patient instruction.

Acknowledgements

The authors wish to thank Henk Salier (H. S.) from dental laboratory "Gerrit van Dijk" for fabrication of the implant crowns and Eric Santing (E. S.) for his assistance in the reliability analyses.

References

Altman, D. G. (1991) *Practical Statistics for Medical Research*. London: Chapman & Hall.

Araujo, M. G. & Lindhe, J. (2005) Dimensional ridge alterations following tooth extraction. An experimental study in the dog. *Journal of Clinical Periodontology* **32**, 212–218.

Belser, U. C., Grutter, L., Vailati, F., Bornstein, M. M., Weber, H. P. & Buser, D. (2009) Outcome evaluation of early placed maxillary anterior single-tooth implants using objective esthetic criteria: a cross-sectional, retrospective study in 45 patients with a 2- to 4-year follow-up using pink and white esthetic scores. *Journal of Periodontology* **80**, 140–151.

Bengazi, F., Wennstrom, J. L. & Lekholm, U. (1996) Recession of the soft tissue margin at oral implants. A 2-year longitudinal prospective study. *Clinical Oral Implants Research* **7**, 303–310.

Block, M. S., Mercante, D. E., Lirette, D., Mohamed, W., Ryser, M. & Castellon, P. (2009) Prospective evaluation of immediate and delayed provisional single tooth restorations. *Journal of Oral and Maxillofacial Surgery* **67**, 89–107.

Chang, M., Wennstrom, J. L., Odman, P. & Andersson, B. (1999) Implant supported single-tooth replacements compared to contralateral natural teeth. Crown and soft tissue dimensions. *Clinical Oral Implants Research* **10**, 185–194.

Choquet, V., Hermans, M., Adriaenssens, P., Daele-mans, P., Tarnow, D. P. & Malevez, C. (2001) Clinical and radiographic evaluation of the papilla level adjacent to single-tooth dental implants. A retrospective study in the maxillary anterior region. *Journal of Periodontology* **72**, 1364–1371.

Cox, J. F. & Zarb, G. A. (1987) The longitudinal clinical efficacy of osseointegrated dental implants: a 3-year report. *International Journal of Oral and Maxillofacial Implants* **2**, 91–100.

De Rouck, T., Collys, K., Wyn, I. & Cosyn, J. (2009) Instant provisionalization of immediate single-tooth implants is essential to optimize esthetic treatment outcome. *Clinical Oral Implants Research* **20**, 566–570.

Degidi, M., Nardi, D. & Piattelli, A. (2009) Immediate versus one-stage restoration of small-diameter implants for a single missing maxillary lateral incisor: a 3-year randomized clinical trial. *Journal of Periodontology* **80**, 1393–1398.

Den Hartog, L., Raghoobar, G. M., Stellingsma, K. & Meijer, H. J. (2009) Immediate loading and customized restoration of a single implant in the maxillary esthetic zone: a clinical report. *Journal of Prosthetic Dentistry* **102**, 211–215.

Den Hartog, L., Slater, J. J., Vissink, A., Meijer, H. J. & Raghoobar, G. M. (2008) Treatment outcome of immediate, early and conventional single-tooth implants in the aesthetic zone: a systematic review to survival, bone level, soft-tissue, aesthetics and patient satisfaction. *Journal of Clinical Periodontology* **35**, 1073–1086.

Dos Santos, M. V., Elias, C. N. & Cavalcanti Lima, J. H. (2009) The Effects of Superficial Roughness and Design on the Primary Stability of Dental Implants. *Clinical Implant Dentistry and Related Research*, doi: 10.1111/j.1708-8208.2009.00202.x.

Ericsson, I., Nilson, H., Lindh, T., Nilner, K. & Randow, K. (2000) Immediate functional loading of Branemark single tooth implants. An 18 months' clinical pilot follow-up study. *Clinical Oral Implants Research* **11**, 26–33.

Esposito, M., Grusovin, M. G., Achille, H., Coulthard, P. & Worthington, H. V. (2009) Interventions for replacing missing teeth: different times for loading dental implants. *Cochrane Database of Systematic Reviews* CD003878.

Gapski, R., Wang, H. L., Mascarenhas, P. & Lang, N. P. (2003) Critical review of immediate implant loading. *Clinical Oral Implants Research* **14**, 515–527.

Glauser, R., Zembic, A. & Hammerle, C. H. (2006) A systematic review of marginal soft tissue at implants subjected to immediate loading or immediate restoration. *Clinical Oral Implants Research* **17** (Suppl. 2), 82–92.

Glauser, R., Zembic, A., Ruhstaller, P. & Windisch, S. (2007) Five-year results of implants with an oxidized surface placed predominantly in soft quality bone and subjected to immediate occlusal loading. *Journal of Prosthetic Dentistry* **97**, S59–S68.

Grutter, L. & Belser, U. C. (2009) Implant loading protocols for the partially edentulous esthetic zone. *International Journal of Oral and Maxillofacial Implants* **24** (Suppl.), 169–179.

Hall, J. A., Payne, A. G., Purton, D. G., Torr, B., Duncan, W. J. & De Silva, R. K. (2007) Immediately restored, single-tapered implants in the anterior maxilla: prosthodontic and aesthetic outcomes after 1 year. *Clinical Implant Dentistry and Related Research* **9**, 34–45.

Hermann, J. S., Buser, D., Schenk, R. K., Schoolfield, J. D. & Cochran, D. L. (2001) Biologic Width around one- and two-piece titanium implants. *Clinical Oral Implants Research* **12**, 559–571.

Heydenrijk, K., Meijer, H. J., van der Reijden, W. A., Raghoobar, G. M., Vissink, A. & Stegenga, B. (2002) Microbiota around root-form endosseous implants: a review of the literature. *International Journal of Oral and Maxillofacial Implants* **17**, 829–838.

Jemt, T. (1997) Regeneration of gingival papillae after single-implant treatment. *International Journal of*

- Periodontics and Restorative Dentistry* **17**, 326–333.
- Kan, J. Y., Rungcharassaeng, K., Umezu, K. & Kois, J. C. (2003) Dimensions of peri-implant mucosa: an evaluation of maxillary anterior single implants in humans. *Journal of Periodontology* **74**, 557–562.
- Katona, T. R., Goodacre, C. J., Brown, D. T. & Roberts, W. E. (1993) Force-moment systems on single maxillary anterior implants: effects of incisal guidance, fixture orientation, and loss of bone support. *International Journal of Oral and Maxillofacial Implants* **8**, 512–522.
- Laney, W. R. (2007) *Glossary of Oral and Maxillofacial Implants*. Berlin: Quintessence.
- Levi, A., Psoter, W. J., Agar, J. R., Reisine, S. T. & Taylor, T. D. (2003) Patient self-reported satisfaction with maxillary anterior dental implant treatment. *International Journal of Oral and Maxillofacial Implants* **18**, 113–120.
- Lin, C. L., Chang, S. H., Chang, W. J. & Kuo, Y. C. (2007) Factorial analysis of variables influencing mechanical characteristics of a single tooth implant placed in the maxilla using finite element analysis and the statistics-based Taguchi method. *European Journal of Oral Sciences* **115**, 408–416.
- Lioubavina-Hack, N., Lang, N. P. & Karring, T. (2006) Significance of primary stability for osseointegration of dental implants. *Clinical Oral Implants Research* **17**, 244–250.
- Meijer, H. J., Stellingsma, K., Meijndert, L. & Raghoobar, G. M. (2005) A new index for rating aesthetics of implant-supported single crowns and adjacent soft tissues—the Implant Crown Aesthetic Index. *Clinical Oral Implants Research* **16**, 645–649.
- Meijndert, L., Meijer, H. J., Raghoobar, G. M. & Vissink, A. (2004) A technique for standardized evaluation of soft and hard peri-implant tissues in partially edentulous patients. *Journal of Periodontology* **75**, 646–651.
- Mesa, F., Munoz, R., Noguerol, B., Dios Luna, J., Galindo, P. & O'Valle, F. (2008) Multivariate study of factors influencing primary dental implant stability. *Clinical Oral Implants Research* **19**, 196–200.
- Mombelli, A., van Oosten, M. A., Schurch, E. Jr. & Land, N. P. (1987) The microbiota associated with successful or failing osseointegrated titanium implants. *Oral Microbiology and Immunology* **2**, 145–151.
- O'Sullivan, D., Sennerby, L. & Meredith, N. (2004) Influence of implant taper on the primary and secondary stability of osseointegrated titanium implants. *Clinical Oral Implants Research* **15**, 474–480.
- Palattella, P., Torsello, F. & Cordaro, L. (2008) Two-year prospective clinical comparison of immediate replacement vs. immediate restoration of single tooth in the esthetic zone. *Clinical Oral Implants Research* **19**, 1148–1153.
- Rams, T. E., Roberts, T. W., Tatum, H. Jr & Keyes, P. H. (1984) The subgingival microbial flora associated with human dental implants. *Journal of Prosthetic Dentistry* **51**, 529–534.
- Rao, W. & Benzi, R. (2007) Single mandibular first molar implants with flapless guided surgery and immediate function: preliminary clinical and radiographic results of a prospective study. *Journal of Prosthetic Dentistry* **97**, S3–S14.
- Roze, J., Babu, S., Saffarzadeh, A., Gayet-Delacroix, M., Hoornaert, A. & Layrolle, P. (2009) Correlating implant stability to bone structure. *Clinical Oral Implants Research* **20**, 1140–1145.
- Schincaglia, G. P., Marzola, R., Giovanni, G. F., Chiara, C. S. & Scotti, R. (2008) Replacement of mandibular molars with single-unit restorations supported by wide-body implants: immediate versus delayed loading. A randomized controlled study. *International Journal of Oral and Maxillofacial Implants* **23**, 474–480.
- Schropp, L., Isidor, F., Kostopoulos, L. & Wenzel, A. (2004) Patient experience of, and satisfaction with, delayed-immediate vs. delayed single-tooth implant placement. *Clinical Oral Implants Research* **15**, 498–503.
- Schropp, L., Wenzel, A., Kostopoulos, L. & Karring, T. (2003) Bone healing and soft tissue contour changes following single-tooth extraction: a clinical and radiographic 12-month prospective study. *International Journal of Periodontics and Restorative Dentistry* **23**, 313–323.
- Smeets, E. C., de Jong, K. J. & Abraham-Inpijn, L. (1998) Detecting the medically compromised patient in dentistry by means of the medical risk-related history. A survey of 29,424 dental patients in The Netherlands. *Preventive Medicine* **27**, 530–535.
- Tabassum, A., Meijer, G. J., Wolke, J. G. & Jansen, J. A. (2010) Influence of surgical technique and surface roughness on the primary stability of an implant in artificial bone with different cortical thickness: a laboratory study. *Clinical Oral Implants Research* **21**, 213–220.
- Trisi, P., Perfetti, G., Baldoni, E., Berardi, D., Colagiovanni, M. & Scogna, G. (2009) Implant micromotion is related to peak insertion torque and bone density. *Clinical Oral Implants Research* **20**, 467–471.
- Wang, H. L., Ormianer, Z., Palti, A., Perel, M. L., Trisi, P. & Sammartino, G. (2006) Consensus conference on immediate loading: the single tooth and partial edentulous areas. *Implant Dentistry* **15**, 324–333.

Address:

L. den Hartog
 Department of Oral and Maxillofacial Surgery
 University Medical Center Groningen
 Hanzeplein 1
 PO Box 30.001, 9700 RB Groningen
 The Netherlands
 E-mail: l.den.hartog@kchir.umcg.nl

Clinical Relevance

Scientific rationale for the study: Dental implants are widely used to replace missing anterior teeth. Placement of the crown immediately after implant installation offers several advantages for the patient compared with a conventional loading strategy. *Principal findings:* There were no differences in short-term treatment

outcome between anterior single implants that were immediately loaded with a non-occluding temporary crown and implants that were loaded according to a conventional strategy.

Practical implications: Immediate non-occlusal loading of single implants in the anterior maxilla is a reliable strategy compared with con-

ventional loading and should be considered as an alternative to conventional loading. However, the concept of immediate non-occlusal loading should be performed according to a specified protocol.

This document is a scanned copy of a printed document. No warranty is given about the accuracy of the copy. Users should refer to the original published version of the material.