

Clinical and radiographic outcomes of the modified minimally invasive surgical technique with and without regenerative materials: a randomized-controlled trial in intra-bony defects

Pierpaolo Cortellini^{1,2} and Maurizio S. Tonetti^{2,3}

¹Private Practice, Florence, Italy; ²European Research Group on Periodontology (ERGOPero), Berne, Switzerland; ³Private Practice, Genova Italy

Cortellini P, Tonetti MS: Clinical and radiographic outcomes of the modified minimally invasive surgical technique with and without regenerative materials: a randomized-controlled trial in intra-bony defects. J Clin Periodontol 2011; 38: 365–373. doi: 10.1111/j.1600-051X.2011.01705.x.

Abstract

Aims: This three-arm study compared the clinical and radiographic efficacy of the modified minimally invasive surgical technique (M-MIST) alone and combined with enamel matrix derivative (EMD) or EMD plus bone mineral derived xenograph (BMDX), in the treatment of isolated, inter-dental intra-bony defects.

Materials and Methods: Forty-five deep isolated intra-bony defects in 45 patients were included, accessed with the M-MIST and randomly assigned to three balanced experimental groups. The M-MIST consisted of a small buccal flap without elevation of the defect-associated papilla. After removal of the granulation tissue by sharp dissection and root instrumentation the regenerative material was applied, when indicated, before obtaining primary closure with a single internal modified mattress suture. Surgery was performed with the aid of an operating microscope and microsurgical instruments. Outcomes were evaluated as pocket depth reduction, attachment level gain, radiographic bone fill and patient-related outcomes.

Results: Primary wound closure was maintained in all treated sites with the exception of one M-MIST EMD+BMDX site. No patient reported intra-operative or post-operative pain. Within group differences between baseline and 1 year were statistically significant in the three groups in terms of probing pocket depth reduction, clinical attachment level (CAL) gain and bone fill ($p < 0.0001$). Comparisons among the three groups showed no statistically significant difference in any of the measured clinical outcomes. In particular, CAL gains of 4.1 ± 1.4 mm were observed in the M-MIST control group, 4.1 ± 1.2 mm in the EMD group and 3.7 ± 1.3 mm in the EMD+BMDX one. The percentage radiographic bone fill of the intra-bony component was $77 \pm 19\%$ in the M-MIST control group, $71 \pm 18\%$ in the EMD group and $78 \pm 27\%$ in the EMD+BMDX group.

Conclusions: M-MIST with or without regenerative materials resulted in significant clinical and radiographic improvements. While this initial study did not have sufficient power to detect inter-group CAL differences < 0.96 mm, the observed outcomes were remarkably similar and warrant further investigations.

Key words: clinical trial; microsurgery; minimally invasive surgery; osseous defects; periodontal regeneration

Accepted for publication 12 January 2011

Conflict of interest and source of funding statement

The authors declare that they have no conflict of interest.

This study has been self-supported by the authors, the European Research Group on Periodontology and the Accademia Toscana di Ricerca Odontostomatologica.

Regeneration is a healing outcome that can occur when the systemic and local conditions are favourable. In periodontal regeneration, the local conditions include the presence of space for the formation of the blood clot at the interface between flap and root surface (Haney et al. 1993, Sigurdsson et al. 1994, Cortellini et al. 1995b, Tonetti et al. 1996, Wikesjö et al. 2003, Kim et al. 2004), the stability of the blood clot to maintain a continuity with the root surface avoiding formation of a long junctional epithelium (Linghorne & O'Connell 1950, Hiatt et al. 1968, Wikesjö & Nilveus 1990, Haney et al. 1993) and the soft tissue protection to avoid bacterial contamination (Selvig et al. 1992, Tonetti et al. 1993a,b, Nowzari et al. 1995, DeSanctis et al. 1996, Sanz et al. 2005).

Development of periodontal regenerative medicine in the last 25 years has followed two distinctive, though totally interlaced paths. The interest of researchers has so far focused on regenerative materials and products on one side and on novel surgical approaches on the other side.

In the area of materials and products, three different regenerative concepts have been mainly explored: barrier membranes, grafts, and wound healing modifiers, plus many combinations of the aforementioned (Cortellini & Tonetti 2000, Esposito et al. 2005, Murphy & Gunsolley 2003, Needleman et al. 2006, Palmer & Cortellini 2008, Reynolds et al. 2003).

In the area of the surgical approaches, clinical innovation in flap design and handling has radically changed surgery and has allowed a drastic limitation of inter-dental wound failure from 100% with conventional flap approaches to <10% with the more modern approaches (Cortellini et al. 1993a, 1995a,b, Tonetti et al. 2004a,b, Cortellini & Tonetti 2001, 2005, 2007a,b, 2009a).

The modified minimally invasive surgical technique (M-MIST, Cortellini & Tonetti 2009a,b) has been recently proposed and tested. The M-MIST was designed to (i) improve flap stability; (ii) maintain space for regeneration; and

(iii) preserve an increased portion of the blood supply at the level of the crest and the papilla. The surgical approach consists of a limited inter-dental incision in which only a buccal triangular flap is elevated, while the papilla is left in place, connected to the root of the crest-associated tooth with its supracrestal fibres. The palatal/lingual tissues are not involved in the surgery. A similar approach used in combination with a bioresorbable barrier, has been recently proposed by Trombelli et al. (2009).

The aim of the present three-arm randomized-controlled pilot clinical trial was to initially compare the clinical efficacy of the 'M-MIST' alone *versus* the clinical efficacy of the M-MIST combined with two well-recognized regenerative materials, enamel matrix derivative (EMD) alone and in combination with bone mineral derived xenograph (BMDX), in the treatment of isolated, inter-dental intra-bony defects.

Materials and Methods**Experimental design**

This was a parallel group, randomized, controlled clinical trial comparing the efficacy of three treatment modalities in 45 intra-bony defects. A single defect was treated in each patient. All the experimental sites were accessed with the M-MIST (Cortellini & Tonetti 2009b) and carefully debrided. EDTA was applied on the instrumented and dried root surfaces. EMD (Emdogain, Institute Straumann AG, Basel, Switzerland) was applied to the debrided root surface in one group (15 defects); EMD+BMDX (BioOss, Geistlich, Switzerland) in another group (15 defects). The third group (15 defects) did not receive the application of any regenerative material/device. Flaps were sutured with modified internal mattress sutures. Patients were enrolled in a stringent post-operative supportive care programme with weekly recalls for 6 weeks, and then included in a 3-month periodontal supportive care programme for 1 year. Clinical and radiographic outcomes were evaluated at 1 year.

Study population

Patients with advanced periodontal disease, in general good health, presenting with at least one isolated deep, predominantly inter-dental intra-bony defect were considered eligible for this study. Patients

were included after completion of cause-related therapy consisting of scaling and root planing, motivation and oral hygiene instructions. Flap surgery for pocket elimination in sites different from the experimental ones was performed, when indicated, before the regenerative treatment. All subjects gave written informed consent. Inclusion/exclusion criteria were as reported previously (Cortellini & Tonetti 2009b). Patients were enrolled 3 months after completion of periodontal therapy, when baseline clinical measurements were recorded.

Sample size and randomization

The primary outcome of the study was clinical attachment level (CAL) gain at 12 months. Changes in probing pocket depths (PPDs) and percentage fill of the radiographic intra-bony component of the defect were secondary outcomes. Sample size was set at 15 subjects/treatment arm based on logistic considerations, the results of a previously reported case series (Cortellini & Tonetti 2009b) and the pilot nature of this trial.

After verification of the entry criteria, 45 subjects gave informed consent and were enrolled into the study. Subjects were assigned a patient number and were randomly assigned to one of the three treatment regimens. Assignment was performed by a clinical research support infrastructure (ERGOPerio, Genova, Italy) using a custom made programme based on balanced random permuted blocks. Furthermore, to reduce the chance of unfavourable splits among groups in terms of key prognostic factors, the randomization process balanced average CAL and PPDs. To conceal assignment, opaque envelopes were assigned to the specific subject and were opened during surgery after defect debridement and EDTA application. Every defect, therefore, received EDTA at the end of defect/root instrumentation.

Clinical measurements at baseline and at 1-year follow-up visit

The following clinical parameters were evaluated at baseline before regenerative therapy and at the 1-year follow-up visit by a single calibrated clinician (M. S. T.). Full-mouth plaque scores (FMPS) were recorded as the percentage of total surfaces (four aspects per tooth) with the presence of plaque (O'Leary et al. 1972). Bleeding on probing (BOP) was assessed dichotomously and full-

mouth bleeding scores (FMBS) were then calculated (Cortellini et al. 1993a).

PPD and recession of the gingival margin (REC) were recorded to the nearest millimetre at the deepest location of the selected inter-proximal site. All measurements and BOP were taken with a pressure sensitive manual periodontal probe at 0.3 N (Brodontic probe equipped with a PCP-UNC 15 tip, Hu-Friedy, Chicago, IL, USA). CAL were calculated as the sum of PPD and REC.

Periapical radiographs were taken at baseline and 1 year as described previously (Tonetti et al. 1993b). The baseline radiographic defect angle; the distance between the cemento-enamel junction and the bottom of the defect (X-ray CEJ-BD); the distance between the cemento-enamel junction and the inter-dental bone crest (X-ray CEJ-BC) were performed on high-resolution scanned radiographs (8 bit, 1200 dpi) using the program ImageJ (NIH, Bethesda, MD, USA). The radiographic infra-bony component (X-ray INFRA) was calculated as (CEJ-BD) – (CEJ-BC).

Primary closure of the flaps and early healing events were evaluated at completion of surgery and at weekly recalls for a period of 6 weeks.

Clinical characterization of the intra-bony defects

Defect morphology was characterized after flap elevation and debridement in terms of distance between CEJ-BD and total depth of the intra-bony component of the defect (INFRA), essentially as described previously (Cortellini et al. 1993b). The defects were described as 1-, 2-, 3-wall or combination defects.

Surgical and patient outcomes

Surgical time was measured with a chronograph, starting at delivery of local anaesthesia through the completion of sutures. Primary closure of the flap was checked with magnification at the end of surgery and weekly for 6 weeks. The presence of a discontinuity in the soft tissues was registered as wound failure. Patients were asked at the end of surgery to report about intra-operative pain and personal feeling of the hardship of the procedure. A visual-analog scale (VAS) 10 cm long was used to indicate the intensity (0 = no pain/hardship; 10 = unbearable pain/hardship). Patients were asked at week 1 for their experience with post-opera-

tive pain and discomfort using a standard questionnaire; pain intensity was quantified with a VAS essentially as described (Cortellini et al. 2001, Tonetti et al. 2002).

Surgical approach (M-MIST)

All the surgical procedures were performed as described previously (Cortellini & Tonetti 2009b, supporting information Video clip S1) with the aid of an operating microscope (Global Protege, St. Louis, MO, USA) at a magnification of $\times 4$ to $\times 16$ (Cortellini & Tonetti 2001, 2005). The defect-associated inter-dental papilla was surgically approached either with a diagonal incision following the pattern of the simplified papilla preservation flap when the width of the inter-dental space was 2 mm or narrower (Cortellini et al.

1999) or with a horizontal incision according to the modified papilla preservation technique at inter-dental sites wider than 2 mm (Cortellini et al. 1995a). Flap elevation was limited to the buccal flap. No inter-dental and/or lingual intra-sulcular incisions were performed. The supracrestal inter-dental tissues, therefore (i) remained attached to the root cement of the crest-associated tooth with its supracrestal fibres, (ii) maintained continuity with the palatal tissue and (iii) were not elevated or displaced. After removal of the granulation tissue by careful dissection and root debridement, the root surface was chemically conditioned with a 2 min. application of an EDTA gel (Preph-Gel, Institute Straumann AG). The randomization envelope was opened and treatment continued based on the assignment.

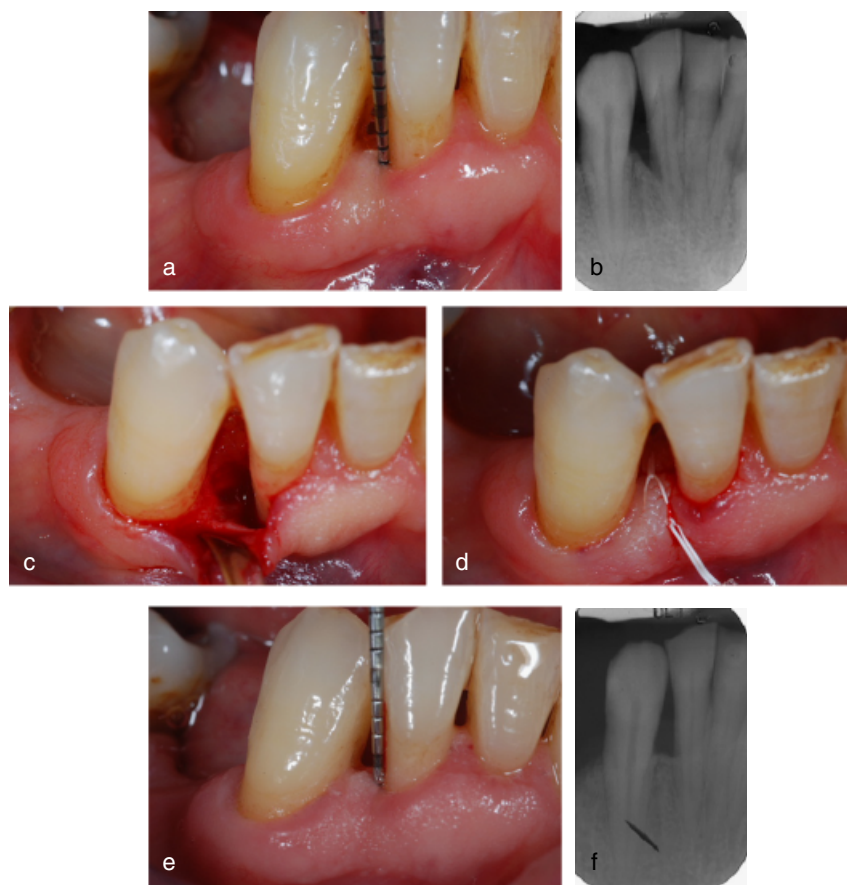

Fig. 1. (a) Site treated with modified minimally invasive surgical technique (M-MIST) alone. Lower right lateral incisor presenting with a pre-operative probing pocket depth (PPD) of 6 mm and a clinical attachment level (CAL) of 11 mm. (b) Pre-operative radiograph showing the presence of an inter-dental intra-bony defect. (c) Elevation of a M-MIST buccal flap and defect debridement. Note the untouched inter-dental papilla. (d) Primary closure of the defect-associated papilla was obtained with an internal modified mattress suture. (e) The 1-year photograph shows a 3 mm residual PPD and a CAL of 8 mm. No gingival recession occurred. (f) Complete radiographic resolution of the intra-bony component at 1 year.

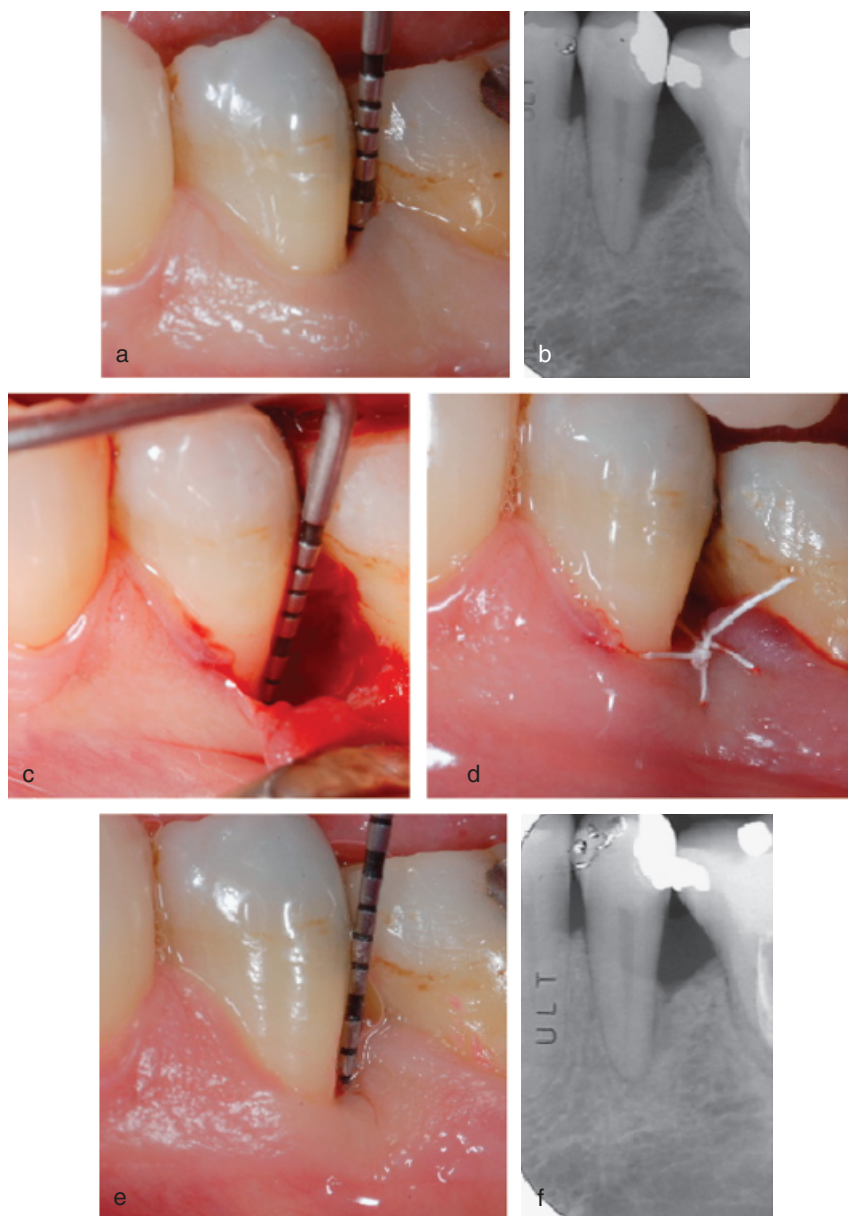


Fig. 2. (a) Site treated with modified minimally invasive surgical technique (M-MIST) and enamel matrix derivative (EMD). Lower left second bicuspid presenting with a pre-operative probing pocket depth (PPD) of 8 mm and a clinical attachment level (CAL) of 9 mm. (b) Pre-operative radiograph showing the presence of a deep inter-dental intra-bony defect. (c) After the elevation of a tiny buccal flap the defect has been debrided. Note the untouched inter-dental papilla. (d) EMD has been applied on the air-dried root surface and primary closure has been provided with an internal modified mattress suture. (e) The 1-year photograph shows a 2 mm residual PPD and a CAL of 5 mm. (f) The 1-year radiograph shows the almost complete resolution of the intra-bony defect.

A single modified internal mattress suture was positioned at the defect-associated inter-dental area (6-0 or 7-0 e-PTFE Gore-tex, WL Gore & Associates, Flagstaff, AZ, USA). In the control group, that did not receive any regenerative materials, the suture was tightened to reach primary closure of the defect-associated papilla (Fig. 1, Cortellini & Tonetti 2001, 2005, 2007a, b).

In the two test groups that received additional regenerative materials the suture was left loose. In the EMD test group, EMD was applied on the rinsed and air-dried root surface (Fig. 2). In the EMD + BMDX test group the xenograph was mixed with EMD on a sterile plate. EMD was applied on the rinsed and air-dried root surface and the mixture of EMD and BMDX was positioned

into the defect with a sterile instrument with no attempt to tightly pack the material into the defect or to overfill it (Fig. 3). When the regenerative materials were properly in place the suture was tightened to reach primary closure of the defect-associated papilla.

The post-operative regimen was as described previously (Tonetti et al. 2002, Cortellini & Tonetti 2007a, 2009b). Patients were requested to avoid brushing, flossing and chewing in the treated area. At week 1, sutures were removed and patients resumed careful toothbrushing with a soft toothbrush (Vitis Surgical, Barcelona, Spain). Patients resumed inter-dental cleaning after 3–4 weeks. At week 4, patients performed full oral hygiene and resumed mastication in the treated area. Weekly prophylaxis was delivered for 6 weeks. At the end of the ‘early healing phase’, patients were placed on a 3-month recall system for 1 year.

Data analysis

CAL gains, residual PPD, position of the gingival margin and radiographic bone gain were the outcome variables. Data within each group were expressed as means \pm standard deviation of 15 defects in 15 patients. All calculations were performed using the software Stata version 11.1 (College Station, TX, USA). Post hoc power analysis was calculated using the program G*Power 3.1 (Faul et al. 2007).

Comparisons between baseline and 1 year measurements within each group were performed applying the paired Student *t*-test ($\alpha = 0.05$). Comparisons among the experimental groups at baseline and at 1 year were performed applying the analysis of variance (ANOVA). Radiographic percentage fill of the baseline intra-bony component of the defect was calculated as follows: Bone fill% = (X-ray bone gain)/(X-ray INFRA) \times 100.

Results

Experimental population and surgical approach

Forty-five subjects were enrolled in this three-arm randomized-controlled clinical trial. The M-MIST alone was applied in 15 subjects (mean age 48.9 ± 7.9 , range 34–59 years, six females, one smoker). The M-MIST+EMD was applied in

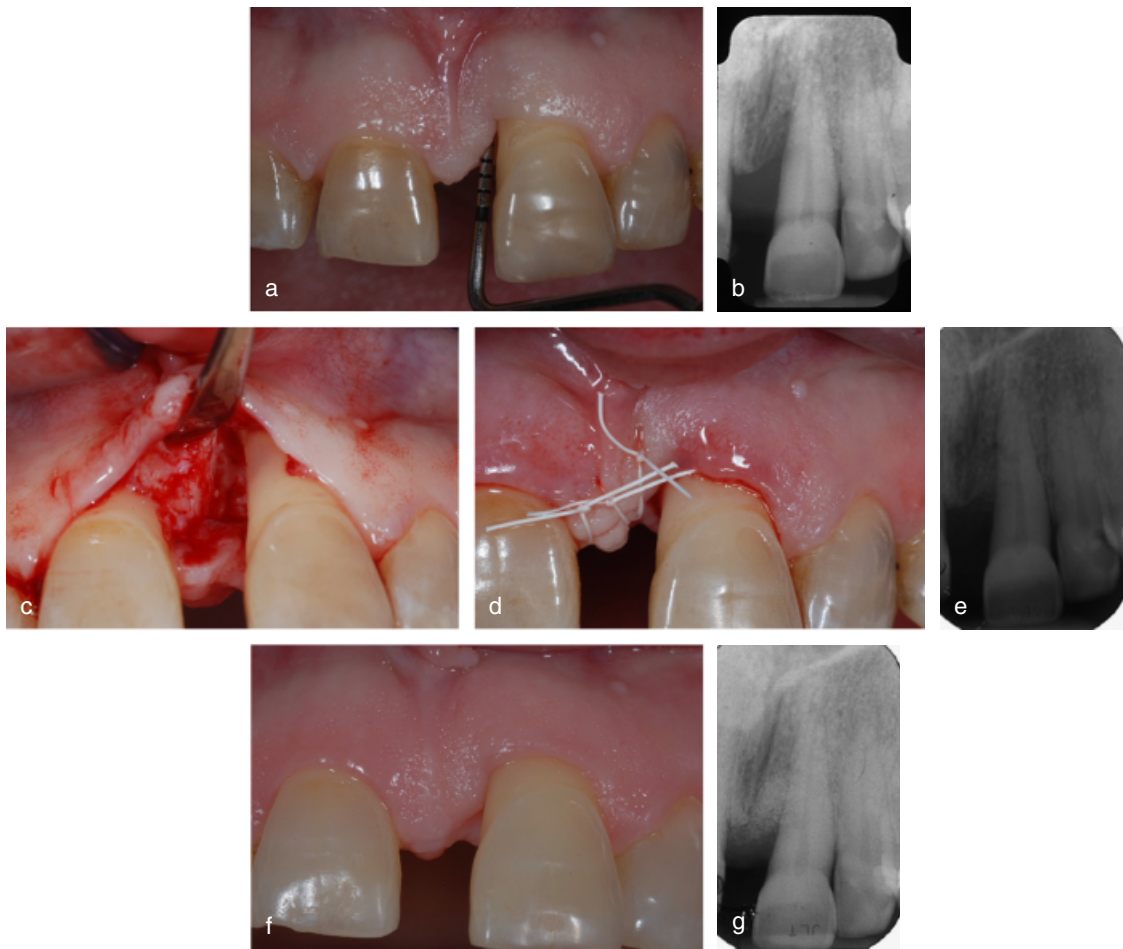


Fig. 3. (a) Site treated with modified minimally invasive surgical technique (M-MIST) and enamel matrix derivative (EMD) plus bone mineral derived xenograft (BMDX). Upper left central incisor presenting with a pre-operative probing pocket depth (PPD) of 11 mm and a clinical attachment level (CAL) of 13 mm. (b) Pre-operative radiograph showing the presence of a deep inter-dental intra-bony defect. (c) After the elevation of a buccal flap the 2-wall defect has been debrided. Note the untouched inter-dental papilla. (d) EMD+BMDX has been applied on the air-dried root surface and primary closure of the wide inter-dental papilla has been obtained with an internal modified mattress suture and an additional passing suture. (e) Post-operative radiograph showing the BMDX grafted to fill the intra-bony component of the defect. (f) The 1-year photograph shows the nice preservation of the inter-dental soft tissues. (g) The 1-year radiograph shows the complete resolution of the intra-bony defect. BMDX particles are clearly detectable within the bone structure.

15 subjects (mean age 47.2 ± 8.5 , range 34–64 years, eight females, two smokers). The M-MIST EMD+BMDX was applied in 15 subjects (mean age 53.5 ± 11.9 , range 28–71 years, seven females, two smokers). No subject discontinued participation in the study and no data points were missing for analysis (Fig. 4).

Baseline subject and defect characteristics are described in Table 1. The defect morphology of the three groups was well matched in terms of width of the defect and number of residual bony walls. The defects were mainly combinations of 3-, 2- and 1-wall components. A 1-wall component was present in the majority of sites (nine sites in the M-MIST group and 10 sites in the other two). No differences were detected in

any of the baseline clinical measurements among the three groups.

Post-operative course and early healing phase

The surgical time was rather short for all the three procedures. The shortest was recorded by M-MIST alone (average time 52.9 ± 5.6 min., minimum 45', maximum 63'), followed by the M-MIST EMD (average time 54.2 ± 7.4 min., minimum 42', maximum 67'). Slightly more time was required for M-MIST EMD+BMDX that accounted for 58.9 ± 6.2 min., on average (minimum 45', maximum 63'). The difference among groups reached statistical significance ($p = 0.036$, ANOVA).

Primary closure was obtained in all treated sites at completion of surgery. All the treated sites remained closed during the 6 weeks of early healing period with the exception of one M-MIST EMD+BMDX site that presented at suture removal (week 1) with a slight discontinuity of the inter-dental wound on the side of the defect-associated tooth. Few BMDX granules were surfacing the soft tissues and were carefully removed. At week 2 the gap appeared closed. No oedema or haematoma was noted in any of the treated sites.

None of the patients reported intra-operative pain or personal feeling of hardship of the procedure at the end of surgery. At 1 week none of the patients reported having experienced post-operative pain. Slight discomfort was

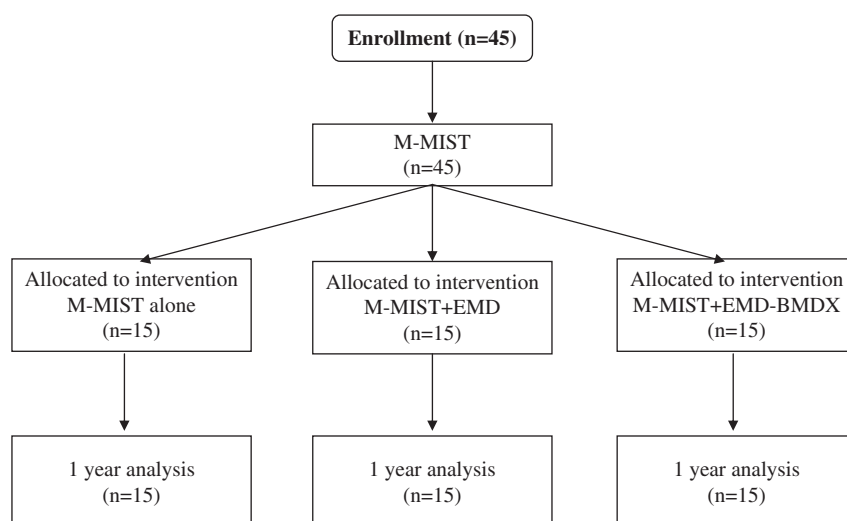


Fig. 4. Consort diagram showing the study layout.

Table 1. Baseline patient and defect characteristics of the three experimental groups ($N = 45$)

| | M-MIST ($N = 15$) | M-MIST EMD ($N = 15$) | M-MIST EMD+BMDX ($N = 15$) | Significance (p) |
|--------------------|---------------------|-------------------------|------------------------------|----------------------|
| FMPS (%) | 13.6 ± 4.9 | 12.5 ± 3.7 | 14.4 ± 6.0 | 0.659 |
| FMBS (%) | 10.3 ± 4.4 | 10.4 ± 3.4 | 10.7 ± 4.1 | 0.964 |
| PPD (mm) | 7.5 ± 1.6 | 7.8 ± 0.9 | 7.3 ± 1.2 | 0.521 |
| REC (mm) | 2.1 ± 1.4 | 2.1 ± 1.4 | 2.9 ± 1.8 | 0.307 |
| CAL (mm) | 9.6 ± 2.0 | 9.9 ± 1.3 | 10.1 ± 2.4 | 0.758 |
| INFRA (mm) | 5.2 ± 1.1 | 5.3 ± 1.0 | 5.2 ± 1.4 | 0.935 |
| CEJ-BD (mm) | 10.5 ± 2.4 | 10.5 ± 1.5 | 10.9 ± 2.2 | 0.852 |
| CEJ-BC (mm) | 5.3 ± 1.8 | 5.2 ± 1.6 | 5.7 ± 1.8 | 0.733 |
| 3 wall | 2.8 ± 1 | 2.9 ± 0.8 | 2.9 ± 0.9 | 0.897 |
| 2 wall | 1.5 ± 0.9 | 1.5 ± 0.5 | 1.5 ± 0.8 | 0.963 |
| 1 wall | 0.9 ± 0.8 | 0.9 ± 0.7 | 0.8 ± 0.7 | 0.961 |
| X-ray angle (deg.) | 35.2 ± 7.2 | 30.4 ± 5.4 | 32.8 ± 9.1 | 0.218 |

BMDX, bone mineral derived xenograph; CAL, clinical attachment level; CEJ-BC, cemento-enamel junction and the inter-dental bone crest; CEJ-BD, cemento-enamel junction and the bottom of the defect; EMD, enamel matrix derivative; FMBS, full-mouth bleeding scores; FMPS, full-mouth plaque scores; M-MIST, modified minimally invasive surgical technique; PPD, probing pocket depth; REC, recession of the gingival margin.

reported by three patients of the M-MIST group (average VAS value 10.7 ± 2.1), by two patients of the M-MIST EMD (average VAS value 11.5 ± 0.7) group and by four patients of the M-MIST EMD+BMDX one (average VAS value 12.3 ± 3.1). Few patients needed pain control medications (ibuprofen): three patients from the control group (average number of 600mg pills 0.4 ± 0.7 , maximum 2), four patients from the EMD group (average 0.3 ± 0.6 , maximum 2), four patients from the EMD+BMDX group (average 0.5 ± 1 , maximum 3).

1-year clinical outcomes

At 1 year, the three groups presented with low levels of FMPS and FMBS, shallow residual pockets, significant amounts of CAL gains and limited

increase in gingival recession (Table 2). Differences between baseline and 1 year were statistically significant in the three groups in terms of PPD reduction ($p < 0.0001$ for all groups, t -test) as well as in terms of CAL gain ($p < 0.0001$ for all groups, t -test). Minor changes in the position of the gingival margin occurred between baseline and 1 year in the three groups (average recession increase of 0.3 mm): the difference between baseline and 1 year was not statistically significant in the M-MIST and in the M-MIST EMD+BMDX groups, while reached statistical significance in the M-MIST EMD one ($p = 0.02$).

Comparisons among the three groups showed no statistically significant difference in any of the measured clinical outcomes (ANOVA, Table 2). In particular, CAL gains of 4.1 ± 1.4 mm

were observed in the M-MIST control group, 4.1 ± 1.2 mm in the EMD group and 3.7 ± 1.3 mm in the EMD+BMDX one.

The frequency distribution of gains in CAL is reported in Table 3. None of the sites gained < 2 mm of attachment, while 73.3% of the M-MIST group, 60% of the EMD group and 46.6% of the EMD+BMDX group gained 4 mm or more.

Bone changes were measured on scanned radiographs (Table 4). The three groups gained a substantial amount of bone at 1 year as compared with baseline. The percentage bone fill of the intra-bony component was $77 \pm 19\%$ in the M-MIST control group, $71 \pm 18\%$ in the EMD group and $78 \pm 27\%$ in the EMD+BMDX group. Differences among groups were not statistically significant.

Table 2. Clinical outcomes at 1 year ($N = 45$)

| | M-MIST ($N = 15$) | M-MIST EMD ($N = 15$) | M-MIST EMD+BMDX ($N = 15$) | Significance (p) |
|----------------|---------------------|-------------------------|------------------------------|----------------------|
| FMPS (%) | 10.2 \pm 4.4 | 9.9 \pm 4.0 | 10.6 \pm 4.8 | 0.925 |
| FMBS (%) | 7.0 \pm 5.2 | 5.7 \pm 3.0 | 7.0 \pm 3.6 | 0.605 |
| PPD (mm) | 3.1 \pm 0.6 | 3.4 \pm 0.6 | 3.3 \pm 0.6 | 0.327 |
| REC (mm) | 2.4 \pm 1.4 | 2.3 \pm 1.4 | 3.1 \pm 2.1 | 0.354 |
| CAL (mm) | 5.5 \pm 1.6 | 5.7 \pm 1.7 | 6.4 \pm 2.4 | 0.397 |
| Delta PPD (mm) | 4.4 \pm 1.6 | 4.4 \pm 1.2 | 4.0 \pm 1.3 | 0.657 |
| Delta REC (mm) | -0.3 \pm 0.6 | -0.3 \pm 0.5 | -0.3 \pm 0.7 | 1 |
| CAL gain (mm) | 4.1 \pm 1.4 | 4.1 \pm 1.2 | 3.7 \pm 1.3 | 0.639 |

BMDX, bone mineral derived xenograph; CAL, clinical attachment level; EMD, enamel matrix derivative; FMBS, full-mouth bleeding scores; FMPS, full-mouth plaque scores; M-MIST, modified minimally invasive surgical technique; PPD, probing pocket depth; REC, recession of the gingival margin.

Table 3. Frequency distribution of CAL gains at 1 year ($N = 45$)

| CAL changes (mm) | No. of sites | | |
|------------------|--------------|-----------------|----------------------|
| | M-MIST (15) | M-MIST EMD (15) | M-MIST EMD+BMDX (15) |
| 0-1 | 0 | 0 | 0 |
| 2-3 | 4 | 6 | 8 |
| 4-5 | 9 | 7 | 6 |
| ≥ 6 | 2 | 2 | 1 |

BMDX, bone mineral derived xenograph; CAL, clinical attachment level; EMD, enamel matrix derivative; M-MIST, modified minimally invasive surgical technique.

Table 4. Baseline radiographic measurements and 1-year radiographic outcomes ($N = 45$)

| | M-MIST ($N = 15$) | M-MIST EMD ($N = 15$) | M-MIST EMD+BMDX ($N = 15$) | Significance (p) |
|----------------|---------------------|-------------------------|------------------------------|----------------------|
| CEJ-BD 0 (mm) | 9.0 \pm 1.7 | 9.3 \pm 2.0 | 10.5 \pm 2.1 | 0.102 |
| INFRA (mm) | 4.7 \pm 1.0 | 4.7 \pm 1.3 | 4.5 \pm 1.3 | 0.128 |
| CEJ-BD 1 (mm) | 5.5 \pm 1.3 | 6.0 \pm 1.5 | 7.2 \pm 2.1 | 0.025 |
| Bone gain (mm) | 3.5 \pm 1.0 | 3.3 \pm 1.2 | 3.3 \pm 1.1 | 0.815 |
| Bone fill (%) | 77 \pm 19 | 71 \pm 18 | 78 \pm 27 | 0.603 |

BMDX, bone mineral derived xenograph; CEJ-BD, cemento-enamel junction and the bottom of the defect; EMD, enamel matrix derivative; M-MIST, modified minimally invasive surgical technique.

Discussion

In this trial the modified minimally invasive technique alone resulted in pocket depth reductions, CAL gains and radiographic bone fill better than the reported ranges with access flap surgery in intra-bony defects (Tu et al. 2008). In particular, these cases expressed a very high clinical healing potential that resulted in the almost complete resolution of the intra-bony defects (77 \pm 19% radiographic bone fill), good amounts of CAL gains (4.1 \pm 1.4 mm) and stability of the gingival margin. Wound failure was observed in only one instance (2.2%) treated with EMD+BMDX, and complications and morbidity were minimal.

The additional application of regenerative materials (EMD or EMD+BMDX) did not improve the results as

expected from the current literature utilizing more conventional papilla-preservation surgery (Trombelli & Farina 2008). While the power of this initial study to detect a true difference was limited to a difference of 0.96 mm, the fact that the outcomes among the three groups could not be discriminated is interesting and raises a series of hypotheses that focus on the intrinsic healing potential of the surgical approach. The M-MIST was designed to optimize wound and blood clot stability, flap margin blood perfusion and provide a stable space for regeneration (Cortellini & Tonetti 2009a,b). The importance of these factors has been systematically assessed in pre-clinical studies and specific solutions have been introduced in periodontal regenerative surgery by progressively evolving flap designs (Cortellini

et al. 1994, Cortellini et al. 1999, Cortellini & Tonetti 2001, 2007a,b, 2009a,b).

As indicated previously, the M-MIST is not always applicable (Cortellini et al. 2009b). When a defect wraps around the lingual aspect of a tooth, elevation of the inter-dental soft tissues becomes necessary and a MIST becomes the preferred approach.

Independent full-scale clinical trials are needed to confirm the results of the present study. It is also important to determine the exact nature of the healing observed following application of M-MIST as the clinical healing observed in this study does not necessarily equate to periodontal regeneration. If such research will confirm these results and provide histological evidence of periodontal regeneration, M-MIST may become the procedure of choice for the treatment of inter-dental intra-bony defects.

Acknowledgements

This study was partly supported by the Accademia Toscana di Ricerca Odontostomatologica, Firenze, Italy and the European Research Group on Periodontology (ERGOperio), Berne, Switzerland.

References

- Cortellini, P., Pini-Prato, G. & Tonetti, M. (1994) Periodontal regeneration of human infrabony defects (V). Effect of oral hygiene on long-term stability. *Journal of Clinical Periodontology* **21**, 606-610.
- Cortellini, P., Pini Prato, G. & Tonetti, M. S. (1995a) The modified papilla preservation technique. A new surgical approach for interproximal regenerative procedures. *Journal of Periodontology* **66**, 261-266.
- Cortellini, P., Pini Prato, G. & Tonetti, M. S. (1995b) Periodontal regeneration of human intrabony defects with titanium reinforced membranes. A controlled clinical trial. *Journal of Periodontology* **66**, 797-803.
- Cortellini, P., Pini Prato, G. & Tonetti, M. S. (1999) The simplified papilla preservation flap. A novel

- surgical approach for the management of soft tissues in regenerative procedures. *International Journal of Periodontics and Restorative Dentistry* **19**, 589–599.
- Cortellini, P., Pini-Prato, G. P. & Tonetti, M. S. (1993a) Periodontal regeneration of human infrabony defects I Clinical Measures. *Journal of Periodontology* **64**, 254–260.
- Cortellini, P., Pini-Prato, G. P. & Tonetti, M. S. (1993b) Periodontal regeneration of human infrabony defects. II Re-entry procedures and bone measures. *Journal of Periodontology* **64**, 261–268.
- Cortellini, P. & Tonetti, M. S. (2000) Focus on intrabony defects: guided tissue regeneration. *Periodontology 2000* **22**, 104–132.
- Cortellini, P. & Tonetti, M. S. (2001) Microsurgical approach to periodontal regeneration. Initial evaluation in a case cohort. *Journal of Periodontology* **72**, 559–569.
- Cortellini, P. & Tonetti, M. S. (2005) Clinical performance of a regenerative strategy for intrabony defects. Scientific evidence and clinical experience. *Journal of Periodontology* **76**, 341–350.
- Cortellini, P. & Tonetti, M. S. (2007a) A minimally invasive surgical technique (MIST) with enamel matrix derivate in the regenerative treatment of intrabony defects: a novel approach to limit morbidity. *Journal of Clinical Periodontology* **34**, 87–93.
- Cortellini, P. & Tonetti, M. S. (2007b) Minimally invasive surgical technique (MIST) and enamel matrix derivative (EMD) in intrabony defects. (I) Clinical outcomes and morbidity. *Journal of Clinical Periodontology* **34**, 1082–1088.
- Cortellini, P. & Tonetti, M. S. (2009a) Minimally invasive surgical technique and enamel matrix derivative (EMD) in intrabony defects: 2. Factors associated with healing outcomes. *International Journal of Periodontics and Restorative Dentistry* **29**, 256–265.
- Cortellini, P. & Tonetti, M. S. (2009b) Improved wound stability with a modified minimally invasive surgical technique in the regenerative treatment of isolated interdental intrabony defects. *Journal of Clinical Periodontology* **36**, 157–163.
- Cortellini, P., Tonetti, M. S., Lang, N. P., Suvan, J. E., Zucchelli, G., Vangsted, T., Silvestri, M., Rossi, R., McClain, P., Fonzar, A., Dubravec, D. & Adriaens, P. (2001) The simplified papilla preservation flap in the regenerative treatment of deep intrabony defects: clinical outcomes and postoperative morbidity. *Journal of Periodontology* **72**, 1702–1712.
- DeSanctis, M., Clauser, C. & Zucchelli, G. (1996) Bacterial colonization of barrier material and periodontal regeneration. *Journal of Clinical Periodontology* **23**, 1039–1046.
- Esposito, M., Grusovin, M. G., Coulthard, P. & Worthington, H. V. (2005) Enamel matrix derivative (Emdogain) for periodontal tissue regeneration in intrabony defects. *Cochrane Database Systematic Review* **CD003875**.
- Faul, F., Erdfelder, E., Lang, A.-G. & Buchner, A. (2007) G*Power 3: a flexible statistical power analysis program for the social, behavioral, and biomedical sciences. *Behavior Research Methods* **39**, 175–191.
- Haney, J. M., Nilveus, R. E., McMillan, P. J. & Wikesjo, U. M. E. (1993) Periodontal repair in dogs: expanded polytetrafluoroethylene barrier membrane support wound stabilisation and enhance bone regeneration. *Journal of Periodontology* **64**, 883–890.
- Hiatt, W. H., Stallard, R. E., Butler, E. D. & Badget, B. (1968) Repair following mucoperiosteal flap surgery with full gingival retention. *Journal of Periodontology* **39**, 11–16.
- Kim, C. S., Choi, S. H., Chai, J. K., Cho, K. S., Moon, I. S., Wikesjo, U. M. E. & Kim, C. K. (2004) Periodontal repair in surgically created intrabony defects in dogs. Influence of the number on bone walls on healing response. *Journal of Periodontology* **75**, 229–235.
- Linghorne, W. J. & O'Connell, D. C. (1950) Studies in the regeneration and reattachment of supporting structures of teeth. I. Soft tissue reattachment. *Journal of Dental Research* **29**, 419–428.
- Murphy, K. G. & Gunsolley, J. C. (2003) Guided tissue regeneration for the treatment of periodontal intrabony and furcation defects. A systematic review. *Annals of Periodontology* **8**, 266–302.
- Needleman, I. G., Worthington, H. V., Tucker, R. J. & Giedrys-Leeper, E. (2006) Guided tissue regeneration for periodontal infrabony defects. *Cochrane Database Systematic Review* **CD001724**.
- Nowzari, H., Matian, F. & Slots, J. (1995) Periodontal pathogens on polytetrafluoroethylene membrane for guided tissue regeneration inhibit healing. *Journal of Clinical Periodontology* **22**, 469–474.
- O'Leary, T. J., Drake, R. B. & Naylor, J. E. (1972) The plaque control record. *Journal of Periodontology* **43**, 38.
- Palmer, R. M. & Cortellini, P. & Group B of European Workshop on Periodontology. (2008) Periodontal tissue engineering and regeneration: consensus report of the sixth European workshop on periodontology. *Journal of Clinical Periodontology* **35** (Suppl.), 83–86.
- Reynolds, M. A., Aichelmann-Reidy, M. E., Branch-Mays, G. L. & Gunsolley, J. C. (2003) The efficacy of bone replacement grafts in the treatment of periodontal osseous defects. A systematic review. *Annals of Periodontology* **8**, 227–264.
- Sanz, M., Tonetti, M. S., Zabalegui, I., Sicilia, A., Blanco, J., Rebelo, H., Rasperini, G., Merli, M., Cortellini, P. & Suvan, J. E. (2005) Treatment of intrabony defects with enamel matrix proteins or barrier membranes: results from a multicenter practice-based clinical trial. *Journal of Clinical Periodontology* **75**, 726–733.
- Selvig, K., Kersten, B., Chamberlain, A., Wikesjo, U. M. E. & Nilveus, R. (1992) Regenerative surgery of intrabony periodontal defects using e-PTFE barrier membranes. Scanning electron microscopic evaluation of retrieved membranes vs. clinical healing. *Journal of Periodontology* **63**, 974–978.
- Sigurdsson, T. J., Hardwick, R., Bogle, G. C. & Wikesjo, U. M. E. (1994) Periodontal repair in dogs: space provision by reinforced ePTFE membranes enhances bone and cementum regeneration in large supraalveolar defects. *Journal of Periodontology* **65**, 350–356.
- Tonetti, M. S., Cortellini, P., Lang, N. P., Suvan, J. E., Adriaens, P., Dubravec, D., Fonzar, A., Fourmoussis, I., Rasperini, G., Rossi, R., Silvestri, M., Topoll, H., Walkamm, B. & Zytbutz, M. (2004b) Clinical outcomes following treatment of human intrabony defects with GTR/bone replacement material or access flap alone. A multicenter randomized controlled clinical trial. *Journal of Clinical Periodontology* **31**, 770–776.
- Tonetti, M. S., Fourmoussis, I., Suvan, J., Cortellini, P., Bragger, U. & Lang, N. P. (2004a) Healing, post-operative morbidity and patient perception of outcomes following regenerative therapy of deep intrabony defects. *Journal of Clinical Periodontology* **31**, 1092–1098.
- Tonetti, M. S., Lang, N. P., Cortellini, P., Suvan, J. E., Adriaens, P., Dubravec, D., Fonzar, A., Fourmoussis, J., Mayfield, L., Rossi, R., Silvestri, M., Tiedemann, C., Topoll, H., Vangsted, T. & Walkamm, B. (2002) Enamel matrix proteins I the regenerative therapy of deep intrabony defects. A multicentre randomized controlled clinical trial. *Journal of Clinical Periodontology* **29**, 317–325.
- Tonetti, M. S., Pini-Prato, G. P. & Cortellini, P. (1996) Factors affecting the healing response of intrabony defects following guided tissue regeneration and access flap surgery. *Journal of Clinical Periodontology* **23**, 548–556.
- Tonetti, M., Pini-Prato, G. & Cortellini, P. (1993a) Periodontal regeneration of human infrabony defects. IV. Determinants of the healing response. *Journal of Periodontology* **64**, 934–940.
- Tonetti, M. S., Pini-Prato, G. P., Williams, R. C. & Cortellini, P. (1993b) Periodontal regeneration of human infrabony defects. III. Diagnostic strategies to detect bone gain. *Journal of Periodontology* **64**, 269–277.
- Trombelli, L. & Farina, R. (2008) Clinical outcomes with bioactive agents alone or in combination with grafting or guided tissue regeneration. *Journal of Clinical Periodontology* **35** (Suppl.), 117–135. Review.
- Trombelli, L., Farina, R., Franceschetti, G. & Calura, G. (2009) Single-flap approach with buccal access in periodontal reconstructive procedures. *Journal of Periodontology* **80**, 353–360.
- Tu, Y. K., Tugnait, A. & Clerehugh, V. (2008) Is there a temporal trend in the reported treatment efficacy of periodontal regeneration? A meta-analysis of randomized-controlled trials. *Journal of Clinical Periodontology* **35**, 139–146.
- Wikesjo, U. M. E., Lim, W. H., Thomson, R. C., Cook, A. D. & Hardwick, W. R. (2003) Periodontal repair in dogs: gingival tissue occlusion, a critical requirement for guided tissue regeneration. *Journal of Clinical Periodontology* **30**, 655–664.
- Wikesjo, U. M. E. & Nilveus, R. (1990) Periodontal repair in dogs: effect of wound stabilisation on healing. *Journal of Periodontology* **61**, 719–724.

Supporting Information

Additional Supporting Information may be found in the online version of this article:

Video Clip S1. A modified minimally invasive surgical procedure on an upper right lateral incisor, performed without additional use of regenerative materials/products.

Please note: Wiley-Blackwell is not responsible for the content or functionality of any supporting materials supplied by the authors. Any queries (other than missing material) should be directed to the corresponding author for the article.

Address:

Pierpaolo Cortellini
Via Carlo Botta 16
50136 Firenze
Italy

E-mail: studiocortellini@cortellini.191.it

Clinical Relevance

Scientific rationale for the study: To compare the efficacy of M-MIST to M-MIST with the additional use of regenerative materials in the treatment of intra-bony defects.

Principal findings: M-MIST alone resulted in excellent clinical and radiographic improvements. Addition of regenerative materials did not provide further improvements. The procedure produced very limited

patient discomfort and wound failure was limited to only one case.

Practical implications: Clinical and radiographic healing following use of M-MIST needs to be confirmed in large multicentre trials.

This document is a scanned copy of a printed document. No warranty is given about the accuracy of the copy. Users should refer to the original published version of the material.