

Oral Manifestations of a Child With Chronic Vomiting

Seong-Oh Kim, DDS, PhD Ji-Youn Kwak, DDS
Byung-Jai Choi, DDS, PhD Jae-Ho Lee, DDS, PhD

ABSTRACT

Perimolysis is a type of intrinsic erosion—an irreversible dental demineralization linked to chronic regurgitation—which causes teeth to be more susceptible to dental caries. The purpose of this case report was to study a 35-month-old chronic vomiting child who visited the Department of Pediatric Dentistry in Yonsei Dental Hospital, Seoul, South Korea, for an evaluation of and treatment for the loss of tooth structure of his primary teeth. To prevent further destruction of the teeth and maintain occlusal height, all the posterior teeth were restored with stainless steel crowns and all the anterior teeth were restored with resin veneer crowns after pulpal treatment under general anesthesia. Therefore, when a child suffering from chronic vomiting visits a pediatric dental clinic, it is prudent to: (1) perform all possible dental treatment to control vomiting's adverse influences on the oral structures; and (2) refer the patient to a pediatrician to determine the cause of vomiting. (*J Dent Child* 2005;72:49-51)

KEYWORDS: VOMITING, EROSION, PERIMOLYSIS

Dental erosion is an irreversible loss of the dental hard tissue, which is caused by a chemical process in the absence of bacteria. It can appear as a secondary manifestation of a systemic disease.^{1,2} Vomiting is a relatively common condition in infants and children.³ Acute infections, emotional stress, gastrointestinal disorders, genitourinary disease, and neurological disease can play a role in vomiting. The cause of this vomiting varies, according to the patient's age.^{4,5} Because chronic vomiting has numerous medical complications, it is important to evaluate the patient's growth and development.^{6,7} Moreover, a complete physical examination is imperative.

Gastric acid is a strong acid with a pH of 1.0 and has bactericidal effects. Along with pepsin, it digests protein and protects the duodenum from bacteria.⁸ Perimolysis, a type of intrinsic dental erosion, is an irreversible dental demineralization linked to chronic regurgitation.^{9,10} When it occurs, the pH falls below the critical level of 5.5,^{1,11} resulting in tooth decalcification and greater susceptibility to dental caries.¹²

Dr. Kim is assistant professor, Dr. Kwak is a lecturer, Dr. Choi is professor, and Dr. Lee is associate professor, all in the Department of Pediatric Dentistry and Oral Science Research Center, College of Dentistry, Yonsei University, Seoul, South Korea.

Correspond with Dr. Lee at leejh@yumc.yonsei.ac.kr

CASE REPORT

A 35-month-old boy visited the Department of Pediatric Dentistry in Yonsei Dental Hospital, Seoul, South Korea, for evaluation and treatment of his primary teeth. He was born after a normal full-term pregnancy. Five months after birth, he was diagnosed with gastroesophageal reflux. At 12 months of age, he had septicemia and pneumonia. At 18 months, he underwent surgery for intussusception and no genopathy was found.

The patient showed a delay in physical development. He could not balance his head on his neck at 18 months, sit on the floor without aid at 24 months, or stand erect without aid at 35 months. His pediatrician did a complete physical examination and diagnosed him as having a developmental disorder. At the time of his first visit to the authors' dental hospital, the patient was receiving physical treatment for the delayed development and verbal communication was not possible.

Due to dysphagia, the patient was only able to ingest approximately 240 ml of bottle-fed milk at one time, 5 to 8 times per a day. At the time of his visit, he was 84 cm in height and weighed 10.5 kg (under the fifth percentile on the normal growth chart for South Korean children), which was underdeveloped compared to normally developed boys at his age.

The parents reported that the patient vomited more than 10 times a day for unknown reasons. According to his mother, he vomited severely whenever he was frightened, lost his tem-

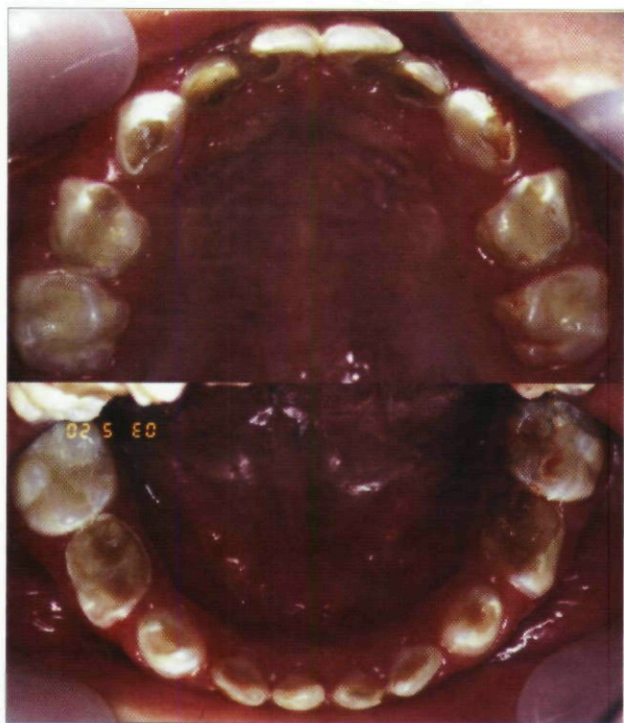

Figure 1. Both arches showing erosions on all 4 first primary molars and moderate to severe dental caries.

per, had to do things that he did not want to do, and scolded by others. Because his pediatrician and parents overlooked the adverse influence of vomiting on his dentition and paid no attention to his oral hygiene, his first visit to a dental clinic was delayed.

An intraoral examination showed moderate to severe dental caries on all of his teeth in both arches, with erosions on all 4 first primary molars and on the lingual surfaces of the maxillary anterior teeth (Figure 1). The patient's oral hygiene status was quite poor, and his gums bled easily as a result of generalized gingivitis. Chronic vomiting was assumed to contribute to the dental erosion and inflammation.

Intraoral radiographs revealed flat occlusal surfaces of the primary first molars (Figure 2). Due to a lack of cooperation, the dental treatment was performed under general anesthesia. The preoperative evaluations (urinalysis, chest radiograph, electrocardiogram, routine chemistry, routine hematology, and special hematology) were performed and revealed no abnormalities. All the posterior primary molars were restored using stainless steel crowns to prevent further tooth erosion and a loss of vertical occlusal height. Pulp therapy was performed on all teeth with pulpitis, and all anterior primary teeth were restored with resin veneer crowns. The effects of the chronic vomiting on the teeth and the

importance of applying regular topical fluoride and oral hygiene care were emphasized to the parents.

DISCUSSION

The causes of dental erosion can be classified into intrinsic and extrinsic factors.^{3,9,13} Intrinsic factors include chronic vomiting with regurgitation, anorexia nervosa, bulimia, pregnancy, alcoholism, gastrointestinal disorders, and gastroesophageal reflux.¹⁴ Extrinsic factors include acidic materials floating in the air, the chlorination of swimming pools, strong acidic internal medicines, and frequent drinking of acidic beverages, such as soft drinks and fruit juices.

The major causes of chronic vomiting of infants without an organic lesion are regurgitation and rumination. Regurgitation means to cast up partially digested food caused by the physiological immaturity of the gastroesophagus. In most cases, it disappears within a year after birth and does not have complications. A rumination disorder is a mental disorder occurring in infancy, typically manifested by the age of 3 to 6 months, that is characterized by the repeated regurgitation of food and is usually accompanied by weight loss or a failure to gain weight.^{15,16} The most common causes of chronic vomiting in ages 2 and older are functional factors without other physical defects.¹⁷

The child in this case had no physical defects requiring surgery to control the vomiting, but had a general decrease of muscle tonicity, underdevelopment, and emotional disturbances. Therefore, it is believed that the disease had progressed from rumination to functional vomiting.

In this case, to prevent further destruction of his teeth and maintain occlusal height, all the posterior primary teeth were restored using stainless steel crowns under general anesthesia. The regular application of topical fluoride in the clinic was prescribed instead of an in-home application using a mouthguard containing fluoride⁵ due to management problems.

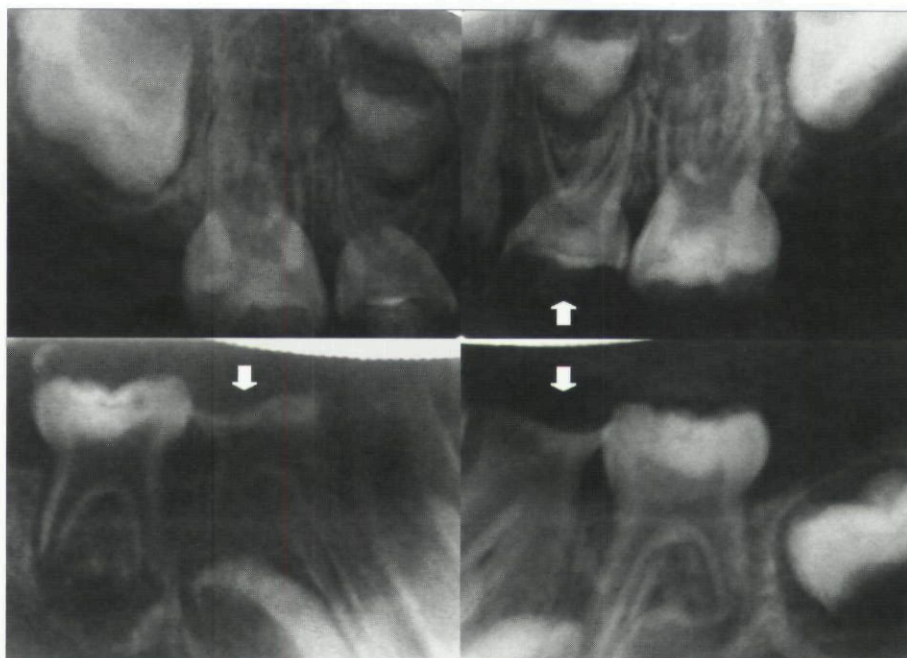


Figure 2. Intraoral radiograph examinations showing the flat occlusal surfaces of first primary molars.

CONCLUSIONS

Chronic vomiting has adverse effects on the teeth, oral soft tissue, esophagus, pharynx, physical growth, and electrolytic balance.^{18,19} Among these, the erosion of teeth causes irreversible damages such as a loss of vertical occlusal height and increased susceptibility to dental caries.²⁰ Most pediatricians and parents, however, overlook these adverse influences on the teeth of chronic vomiting patients. Therefore, in the case of a child with chronic vomiting, it is recommended that:

1. all possible dental treatments—including prosthetic, conservative, and preventive approaches—be performed to control the adverse influences of vomiting on the oral structure;
2. the patient be referred to a pediatrician for the appropriate management of vomiting.

REFERENCES

1. Järvinen V, Meurman JH, Hyvärinen H, Rytömaa I, Murtomaa H. Dental erosion and upper gastrointestinal disorders. *Oral Surg Oral Med Oral Pathol* 1988; 65:298-303.
2. Bartlett DW, Evans PF, Smith BG. Oral regurgitation after reflux provoking meals: A possible cause of dental erosion? *J Oral Rehabil* 1997;24:102-108.
3. Dahshan A, Patel H, Delaney J, Wuerth A, Thomas R, Tolia V. Gastroesophageal reflux disease and dental erosion in children. *J Pediatr* 2002;140:474-478.
4. Linnett V, Seow WK. Dental erosion in children: A literature review. *Pediatr Dent*. 2001;23:37-43.
5. Cameron AC, Widmer RP. *Handbook of Pediatric Dentistry*. 2nd ed. Sydney, Australia: Mosby Co; 2003: 230-231.
6. Palumbo M, Dolen WK, Good RA. A 16-month-old with persistent vomiting. *Ann Allergy* 2003;90:380-382.
7. Cowan MR, Abramo TJ, Wiebe RA. A 7-month-old with bilious vomiting. *Ann Emerg Med*. 1995;25:551-553.
8. O'Sullivan EA, Curzon MEJ, Roberts GJ, Milla PJ, Stringer MD. Gastroesophageal reflux in children and its relationship to erosion of primary and permanent teeth. *Eur J Oral Sci* 1998;106:765-769.
9. Imfeld T. Dental erosion. Definition, classification, and links. *Eur J Oral Sci* 1996;104:151-155.
10. House RC, Grisius R, Bliziotis MM, Licht JH. Perimolysis: Unveiling the surreptitious vomiter. *J Oral Surg* 1981;51:152-155.
11. Ali DA, Brown RS, Rodriguez LO, Moody EL, Nasr MF. Dental erosion caused by silent gastroesophageal reflux disease. *J Am Dent Assoc* 2002;133:734-737.
12. Tinanoff N, Kanellis MJ, Vargas CM. Current understanding of the epidemiology, mechanisms, and prevention of dental caries in preschool children. *Pediatr Dent* 2002;24:543-551.
13. White DK, Hayes RC, Benjamin RN. Loss of tooth structure associated with chronic regurgitation and vomiting. *J Am Dent Assoc* 1978;97:833-835.
14. Schroeder PL, Filler SJ, Raminetz B, Lazarchik DA, Vaezi MF, Richter JE. Dental erosion and acid reflux disease. *Ann Intern Med* 1995;122:809-815.
15. Luiselli JK, Haley S, Smith A. Evaluation of a behavioral medicine consultative treatment for chronic, ruminative vomiting. *J Behav Ther Exp Psychiatry* 1993;24:27-35.
16. Rast J, Johnston JM. Social versus dietary control of ruminating by mentally retarded persons. *Am J Ment Defic* 1986;90:464-467.
17. Changhui-Hong. *Pediatrics*. 7th ed. Seoul, South Korea: Deahan Textbook Company; 2001:437-440, 1238.
18. Simmons MS, Thompson DC. Dental erosion secondary to ethanol-induced emesis. *Oral Surg Oral Med Oral Pathol* 1987;64:731-733.
19. Levin PA, Falko JM, Dixon K, Gallop EM, Saunders W. Benign parotid enlargement in bulimia. *Ann Intern Med* 1980;93:827-829.
20. Taylor G, Taylor S, Abrams R, Mueller W. Dental erosion associated with asymptomatic gastroesophageal reflux. *J Dent Child* 1992;59:182-185.

Copyright of Journal of Dentistry for Children is the property of American Society of Dentistry for Children. The copyright in an individual article may be maintained by the author in certain cases. Content may not be copied or emailed to multiple sites or posted to a listserv without the copyright holder's express written permission. However, users may print, download, or email articles for individual use.