

Dental Abnormalities in Children Submitted to Antineoplastic Therapy

Nilza N.F. Lopes, DDS Antonio S. Petrilli, MD, PhD Eliana M.M. Caran, MD, PhD
Cristiane M. França, DDS, PhD Israel Chilvarquer, DDS, MSC, PhD
Henrique Lederman, MD, PhD

ABSTRACT

Purpose: The purpose of this study was to assess, by panoramic radiographs, the prevalence of morphological dental changes in children with cancer who were submitted for chemotherapy alone or concomitant radiotherapy of the head and neck.

Methods: All patients admitted between March, 1996 and February, 2004 were analyzed and 137 were included in this retrospective, nonrandomized, institutional study. The rates of microdontia, taurodontia, anodontia, macrodontia, blunt root, and tapered root were assessed.

Results: The patients were distributed into 2 groups: (1) those with lymphoproliferative neoplasias (61%); and (2) those with solid tumors (39%). Their mean age when treatment began was 5 years and 6 months. Dental abnormalities were found in 39 (29%) patients, while 98 (72%) patients did not present any abnormality. The abnormalities found were: (1) microdontia (7%; N=10); (2) anodontia (6%; N=8); (3) taurodontia (14%; N=19); (4) macrodontia (5%; N=7); (5) blunted root (2%; N=2); and (6) tapered root (4%; N=5). Of these patients: 22% (N=30) presented 1 abnormality; 4% (N=6) presented 2 abnormalities; and 2% (N=3) presented 3 abnormalities.

Conclusion: Taurodontia was the most frequent abnormality found in children and adolescents who underwent antineoplastic treatment, and its rate was significantly higher than those found for the healthy Brazilian population. This study's results show that it is necessary for the odontologist to systematically research the dental changes that occur among this special group of patients. (*J Dent Child* 2006;73:140-145)

KEYWORDS: DENTAL ABNORMALITIES, ONCOLOGY, CHILDREN,
CANCER, RADIOTHERAPY, CHEMOTHERAPY

The treatment with chemotherapy and radiation to the head and neck may cause lesions that mainly affect the developing tissues. Oral and dental tissues may be affected in a way that interferes with one's quality of life.¹ The degree of severity of dental changes depends on the: (1) tooth's stage of histogenesis; (2) treatment type used; and (3) irradiation dose and area.²⁻⁴

Generally, the treatment of a child with cancer includes many therapeutic modalities, often associating chemo and radiotherapy, making it hard to distinguish which causes what later on. Although many studies on the disturbances in dental development in cancer patients have been published,²⁻⁷ this type of publication is rare in Brazil.⁸

Roughly 50% of the Brazilian population is under 20 years of age, resulting in an estimated 11,000 new cancer cases per year.⁹ With the increased life expectancy of patients under 5 years of age, it is important to study the late dental effects in children who undergo cancer treatment so that early diagnosis and specialized dental treatment can be made. Based on this data, the authors used panoramic radiographs to assess the presence of morphological dental changes in children with cancer who had undergone chemotherapy or concomitant chemoradiotherapy at the Pediatric Oncology Institute, Group of Support to Teenagers and Children with

Dr. Lopes is head of the Dental Service, Dr. Petrilli is Director, Dr. Caran is pediatric oncologist, and Dr. Lederman is professor of Radiology, Diagnostic Department, all at the Pediatric Oncology Institute, GRAACC, Medical School of São Paulo, Federal University of São Paulo, São Paulo, Brazil; Dr. França is oral pathologist and professor, Biodentistry Post Graduation Program, Ibirapuera University, São Paulo; and Dr. Chilvarquer is associate professor, Dental School, University of São Paulo, São Paulo.
Correspond with Dr. Lopes at nnflopes@terra.com.br

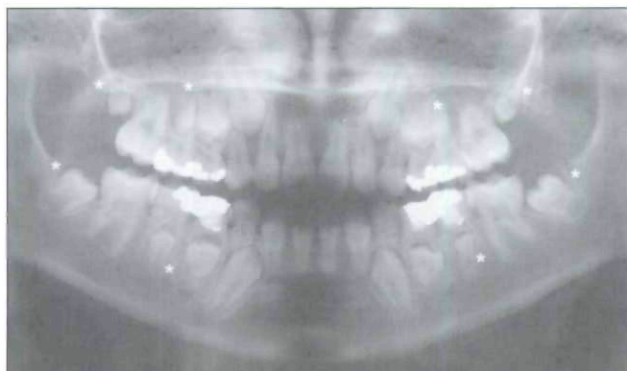


Figure 1. Representative panoramic radiograph of a 2-year-old patient at diagnosis who received chemotherapy and 1,800 cGy. Notice microdontia of maxillary and mandibular second premolars and second molars (asterisks).

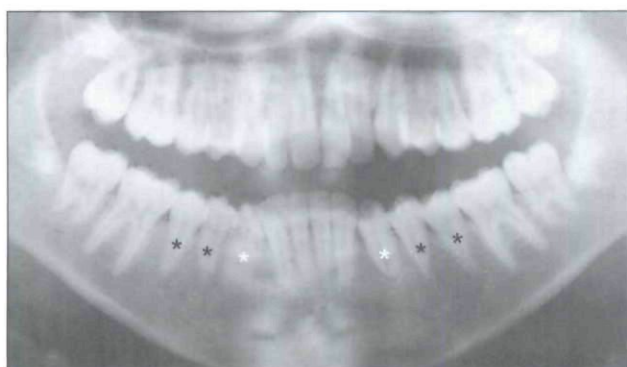


Figure 3. Representative panoramic radiograph of 6-year-old patient at diagnosis who received chemotherapy and 6,750 cGy. Notice tapering of mandibular first and second premolars (dark asterisks) and blunted canine (light asterisks).

Cancer (GRAACC), Medical School of São Paulo, Federal University of São Paulo, (IOP/GRAACC-UNIFESP/EPM) São Paulo, Brazil, from 1996 to 2004.

METHODS

This retrospective, nonrandomized study assessed the dental changes found in children with cancer who underwent chemotherapy or concomitant radiotherapy. This study was approved by the Research Ethics Committee of the Hospital São Paulo, Federal University of São Paulo.

From 1996 to 2004, 137 cancer patients from the IOP/GRAACC-UNIFESP/EPM who fulfilled the eligibility criteria were admitted to the study.

The eligibility criteria were patients:

1. with a malignant neoplasia who underwent chemotherapy or concomitant head and neck radiotherapy;
2. who had not received treatment for at least 1 year when the study began;
3. younger than age 12; or
4. with incomplete permanent dentition at the time of the antineoplastic treatment.

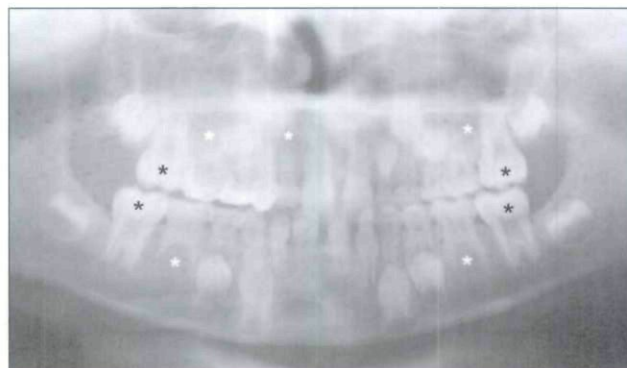

Figure 2. Representative panoramic radiograph of 7-year-old patient at diagnosis who received chemotherapy and 2,100 cGy. Notice hypodontia of mandibular and maxillary second premolars and right lateral incisor (light asterisks) and taurodontia (dark asterisks) of mandibular and maxillary first molars.

PATIENTS

According to the type of malignant neoplasia, the patients were distributed into 2 groups—those with: (1) lymphoproliferative neoplasias (leukemia and lymphoma); and (2) solid tumors. They were further distributed by age, ranging from: (1) 0 to 6 years old; or (2) 6 to 12 years old. Finally, they were also distributed into another 2 groups, according to the type of treatment they received—patients who underwent: (1) chemotherapy; or (2) concomitant head and neck radiotherapy.

ANALYSIS OF THE PANORAMIC RADIOGRAPHS

Panoramic radiographs were taken annually from all patients who met the eligibility criteria. The radiographs obtained were assessed by three independent examiners who looked for changes in: (1) shape (microdontia, macrodontia, taurodontia); (2) number (anodontia); and (3) root (thinning of the root, root stunting).

The following definitions were used:

1. Microdontia—teeth whose dimensions are below the normal standards. The tooth is small when compared with the opposite tooth (Figure 1).¹⁰

Table 1. Examiner Agreement for Each Dental Abnormality Found

Abnormality	Agreement	
	%	Confidence interval
Microdontia	98	(93.73; 99.55)
Hypodontia	100	(97.84; 100.00)
Taurodontia	88	(80.88; 92.60)
Macrodontia	82	(75.06; 88.44)
Blunted root	96	(90.71; 98.38)
Tapered root	96	(90.71; 98.38)

Table 2. Distribution of Dental Abnormalities According to Diagnosis*

Diagnosis	Microdontia	Macrodontia	Taurodontia	Hypodontia	Tapered roots	Blunted roots	Total
Lymphoproliferative neoplasias	4 (5%)	5 (6%)	8 (10%)	3 (4%)	2 (2%)	1 (1%)	23/83
Solid tumors	6 (11%)	2 (4%)	11 (20%)	5 (9%)	3 (6%)	1 (2%)	28/54

P* = .71.Table 3. Distribution of Dental Abnormalities According to Age Group***

Age group (ys)	Microdontia	Macrodontia	Taurodontia	Hypodontia	Tapered roots	Blunted roots	Total
<6	9 (13%)	5 (7%)	13 (19%)	3 (4%)	1 (1%)	1 (1%)	32/69
≥6	1 (2%)	2 (3%)	6 (9%)	5 (7%)	4 (6%)	1 (2%)	19/68

P* = .16.Table 4. Distribution of Dental Abnormalities According to Treatment***

Treatment	Microdontia	Macrodontia	Taurodontia	Hypodontia	Tapered roots	Blunted roots	Total
Chemotherapy	7 (8%)	4 (4%)	12 (13%)	5 (5%)	2 (2%)	0	30/92
Chemoradiotherapy	3 (7%)	3 (7%)	7 (16%)	3 (7%)	3 (7%)	2 (5%)	21/45

**P* = .71.

2. Macrodontia—teeth whose dimensions exceed the normal standards, large tooth when compared with the opposite tooth.¹⁰
3. Taurodontia—teeth that present an increased mesiodistal distance starting at the cemento-enamel junction, with the usual constriction at the neck being absent, and teeth with increased pulp cavity and short roots in the crown/root ratio. The parameters, defined by Ackerman et al,¹¹ used for this classification and taurodontia were considered moderate and severe (Figure 2).
4. Hypodontia—an absence of one or more teeth due to developmental failure, resulting in a reduced number of teeth in the permanent and/or deciduous dentitions (Figure 2).¹²
5. Tapered root—root with diminished volume (Figure 3).⁴
6. Blunted root—root with increased volume and closed, rounded apices (Figure 3).⁴

The radiographs were analyzed according to the developmental stage of the tooth using Nolla's table¹³ as a reference. To analyze crown abnormalities (microdontia and macrodontia), the teeth had to be at least in Nolla's stage 6, where crown formation is complete. For root abnormalities (tapered and blunt), the teeth should be at least in Nolla's stage 10, where the roots are complete and the apices are closed. For anodontia, the assessment was made according to the permanent teeth's maturation age.¹⁴ The third molars (wisdom teeth) were not taken into account, given the high number of disturbances in the development of these teeth observed in the general population. The upper and lower incisors were not assessed, since this region is distorted in panoramic radiographs.

The analysis of the dental abnormalities found was cor

related with the following characteristics: (1) age group; (2) type of malignant neoplasia; and (3) treatment type.

STATISTICAL ANALYSIS

Fisher's exact test and the chi-square test were used to compare the rate of dental abnormalities between the type of treatment, diagnostic, and age groups. The adopted level of significance was 5%.

RESULTS

Of the 137 patients, 79 were females (58%) and 58 were males (42%). Seventy patients were younger than (51%) and 67 patients were older than age 6 (49%). The mean age of the patients was 5 years, 6 months.

Eighty-three (61%) patients had been diagnosed with lymphoproliferative (leukemia or lymphoma) neoplasias, while 54 (39%) had solid tumors.

The radiographs were assessed by 3 examiners, and the results were analyzed statistically. Agreement was considered good when above 80% (Table 1).

The doses and type of chemotherapy each patient received depended on the diagnosis and was done according to the established therapeutic protocols. Given the histologic diversity of the diagnoses and the treatment duration, it was not possible to correlate the dental abnormalities found with the specific chemotherapy protocol. The many chemotherapy protocols used were:

1. leukemias (protocol GBTL 93 and 99);
2. neuroblastomas (carboplatin, Etoposide, cyclophosphamide, vincristine, Ifosfamide);

Table 5. Literature Review Dental Abnormalities of Patients Submitted to Chemotherapy or Chemoradiotherapy

Authors	n	Diagnosis	Gender		Mean age	Dental disturbances						
			F	M		Microdontia	Taurodontia	Hypoplasia	Tapered roots	Hypodontia	Blunted roots	Macrodontia
Rosenberg et al, ¹⁸ 1987*	17	Acute Lymphoid Leukemia (ALL)	—	—	7.2	—	—	—	13 76%	—	5 29%	—
Pajari et al, ²³ 1988†	34	Various tumors	19	18	5.7	—	—	32 94%	—	—	—	—
Dahlloff et al, ²⁰ 1988‡	16	BMT§	7	9	7.1	3 19%	—	4 25%	14 88%	—	5 31%	—
Sonis et al, ⁴ 1990	97	ALL	61	36	—	21 22%	—	27 28%	85 88%	5 5%	60 62%	—
Nunn et al, ²¹ 1991‡	52	ALL+lymphoma	30	22	6.7	14 27%	14 27%	14 29%	14 27%	8 15%	14 27%	—
Pajari et al, ²² 1995†	45	ALL	25	20	5.4	—	—	40 95%	—	—	—	—
Kaste et al, ⁵ 1995‡	22	Rhabdomyosarcoma	12	10	5.1	5 23%	—	—	—	11 50%	13 59%	—
Kaste et al, ⁶ 1997‡	423	ALL	204	219	4.8	80 19%	25 6%	—	—	36 9%	103 24%	—
Näsmann et al, ²³ 1997‡	16	BMT+TBI	9	7	6.3	12 75%	—	7 44%	15 94%	9 56%	11 69%	—
	52	BMT, no TBI	23	29	5.1	7 13%	—	7 13%	10 19%	11 21%	4 8%	—
Kaste et al, ⁷ 1998‡	52	Neuroblastoma	19	33	0.0	20 38%	—	9 17%	—	9 17%	9 17%	—
Alpaslan et al, ²⁴ 1999‡	30	Lymphoma	7	23	—	—	—	14 47%	9 30%	15 50%	2 7%	—
Minicucci et al, ⁸ 2003‡	76	ALL	33	43	5.1	28 44%	—	25 39%	—	—	—	—

*Only the premolar roots were assessed.

†Only hypoplasia was assessed.

‡Patients who presented more than one abnormality.

§BMT=bone marrow transplantation.

||TBI=total body irradiation.

3. rhabdomyosarcoma (vincristine, actinomycin-D, cyclophosphamide, ifosfamide, Etoposide); and
4. central nervous system tumors (ifosfamide, carboplatin, Etoposide, cisplatin, cyclophosphamide).

The distribution of the dental abnormalities found according to diagnosis, age and treatment are shown in Tables 2, 3, and 4.

DISCUSSION

The incidence and degree of severity of the dental abnormalities found in children who survive cancer depend on the: (1) stage of histogenesis of the tooth; (2) type of chemotherapeutic agent used; and (3) irradiation dose and area.^{2,3} Sonis et al⁴ reported that children treated before age 5 can present more severe dental abnormalities. Thus, antineoplastic therapies affecting the cells involved in odontogenesis may cause:

1. changes in the development of the enamel and roots of the teeth;

2. early closure of the apices; and
3. dental development delay or arrest.^{2,15,16}

Published studies on the dental abnormalities found in children with cancer are controversial and depend on the: (1) kind of tumor studied; (2) chemotherapy protocol; (3) patient's age; (4) concomitant use of radiotherapy; and (5) dental assessment methodology (Table 5).

The most frequently found abnormality in this study was taurodontia (14%; 19/137 patients). In the dental literature, this rate varies from 6% to 26%.^{6,20} In Brazil, some authors found the rates of taurodontia in a healthy population to range from 2% (8/833) to 6% (61/1115).^{24,25} Therefore, the taurodontia rate among the children assessed in this study was significantly higher than those found in the healthy population ($P<.001$).

The patients who underwent chemotherapy and concomitant head and neck radiotherapy presented a higher incidence of dental abnormalities (47%; 21/45) than those who underwent chemotherapy only (33%; 30/92). Carpenter³

and Dury et al²⁶ report that 1,000 cGy are enough to cause permanent damage to mature ameloblasts and that 3,000 cGy are enough to arrest dental development. For Goho,¹ however, 400 cGy already affect dental development. The severity of these effects is directly associated with the child's age—that is, the stage of odontogenesis. Just as with chemotherapy, children who are submitted to radiotherapy before age 5 will present more odontogenic anomalies.^{4,27}

While studying the dental abnormalities of 97 children with leukemia, Sonis et al⁴ concluded that the degree of severity of dental abnormalities related to: (1) age at cancer diagnosis; (2) treatment type; and (3) cranial radiotherapy dose. Children treated before age 5 presented more severe dental abnormalities when cancer treatment was done while the teeth were not yet mature.

Children with solid tumors present a statistically significant ($P<.001$) higher incidence of dental abnormalities 52% (28/54) than those with lymphoproliferative neoplasias 28% (23/83).

When the authors compare this study's results with those of a healthy population, it is possible to notice the many differences between the rates of dental abnormalities reported by the authors, probably due to different assessment methodologies and different studied populations. It is convenient to point out that Lee²⁴ and Girondi²⁵ included the third molars in their studies. In Table 6, the authors have not included the third molars in their assessment due to the patients' young ages and the high rate of developmental changes affecting third molars.

In this study, dental abnormalities were detected in 39/137 (28%) cases, showing how important it is for the dentist to participate in the treatment of children with cancer. Another aspect that deserves attention is the need to standardize the definitions and methods used in dental abnormality assessments. The increasing knowledge on dental abnormalities in children with cancer and its precipitating factors and causes may contribute to an early diagnosis and allow preventive measures to be taken.

CONCLUSION

Taurodontia was the most frequent dental abnormality found among children and adolescents who underwent chemotherapy, and its rate was significantly higher than those found for the healthy population. Children who received chemotherapy and radiotherapy greater than or equal to 2,200 cGy before age 5 presented the highest rates of dental abnormalities. This suggested that immature teeth were at higher risk for developmental disturbances than mature teeth.

The results obtained suggest that dental abnormalities may be closely related to the stage of dental development. These abnormalities may be directly related to the: (1) younger age at cancer treatment; (2) type, intensity, and

Table 6. Prevalence of Dental Abnormalities in Children Treated for Cancer (Lopes) and a Healthy Population (Lee,²⁴ Girondi²⁵)*

Study	n	Microdontia	Macrodontia	Hypodontia	Taurodontia
Lopes	137	7%	5%	6%	14%
Lee ²⁴	1115	7%	4%	15%	6%
Girondi ²⁵	533	3%	1%	7%	2%

* $P<.001$.

frequency of the drugs administered; and (3) concomitant use of radiotherapy.

REFERENCES

- Goho C. Chemoradiation therapy: Effect on dental development. *Pediatr Dent* 1993;15:6-11.
- Jaffe N, Toth BB, Hoar RE, et al. Dental and maxillofacial abnormalities in long-term survivors of childhood cancer effects of treatment with chemotherapy and radiation to the head and neck. *Pediatrics* 1984;73:816-823.
- Carpenter JS. Dental care for children who have received head and neck therapeutic radiation. *J Pedod* 1978;3:36-48.
- Sonis AL, Tarbell N, Valachovic RW, et al. Dentofacial development in long-term survivors of acute lymphoblastic leukemia. A comparison of three treatment modalities. *Cancer* 1990;66:2645-2652.
- Kaste SC, Hopkins KP, Bowman LC. Dental abnormalities in long-term survivors of head and neck rhabdomyosarcoma. *Med Pediatr Oncol* 1995;25:96-101.
- Kaste SC, Hopkins KP, Jones D, et al. Dental abnormalities in children treated for acute lymphoblastic leukemia. *Leukemia* 1997;11:792-796.
- Kaste SC, Hopkins KP, Bowman L, et al. Dental abnormalities in children treated for neuroblastoma. *Med Pediatr Oncol* 1998;30:22-27.
- Minicucci EM, Lopes LF, Crocci AJ. Dental abnormalities in children after chemotherapy treatment for acute lymphoid leukemia. *Leuk Res* 2003;27:45-50.
- Petrilli AS, Carneiro Jr TL, Cypriano M, et al. Diferenças clínicas, epidemiológicas e biológicas entre o câncer na criança e no adulto. *Ver. Bras. Cancerol* 1997;43:191-203.
- Nuez RA. Hiperplasia dos dentes: Gigantismo. *Rev Cubana Estomatol* 1960;27:9-28.
- Ackerman JL, Acherman LA, Ackerman BA. Taurodont, pyramidal, and fused molar roots associated with other anomalies in a kindred. *Am J Phys Anthropol* 1973;38:681-694.
- Freitas A, Freitas C. Aspectos Radiográficos das Alterações e Lesões do Órgão Dentário. In: Freitas A, Rosa EJ, Souza, IF, eds. *Radiologia Odontológica*. 5th ed. São Paulo, Brasil: Editora Artes Médicas Ltd; 2000:369-454.
- Nolla CM. The development of the permanent teeth. *J Dent Child* 1960;25:254-266.

14. Ferreira FV. Desenvolvimento da dentição. In: Vellini-Ferreira F, eds. *Ortodontia-Diagnóstico e Planejamento Clínico*. 4th ed. São Paulo, Brazil: Editora Artes Médicas Ltd; 2001:59-70.
15. Sanders BJ, Shapiro AM, Hock, RA, Weddell JA. Tratamento de Pacientes com problemas medico: Hematologia, Oncologia, Hepatite e AIDS. In: McDonald RE, Avery DR, eds. *Odontopediatria*. 7th ed. Rio de Janeiro, Brazil: Editora Guanabara Koogan SA; 2001:436-452.
16. Takeda Y, Kuroda M, Amari E, et al. Failure of root development of human permanent teeth following irradiation. *Int J Oral Maxillofac Surg* 1987;16:376-382.
17. Rosenberg SW, Kolodney H, Wong GY, et al. Altered dental root development in long-term survivors of pediatric acute lymphoblastic leukemia: A review of 17 cases. *Cancer* 1987;59:1640-1648.
18. Pajari U, Lanning M, Larmas N. Prevalence and location of enamel opacities in children after anti-neoplastic therapy. *Community Dent Oral Epidemiol* 1988;16:222-226.
19. Dahllöf G, Heimdahl A, Bolme P, et al. Oral condition in children treated with bone marrow transplantation. *Bone Marrow Transplant* 1988;3:43-51.
20. Nunn JH, Welbury RR, Gordon PH, et al. Dental caries and dental anomalies in children treated by chemotherapy for malignant disease: A study in the north of England. *Int J Pediatr Dent* 1991;1:131-135.
21. Pajari U, Ollila P, Lanning M. Incidence of dental caries in children with acute lymphoblastic leukemia is related to the therapy used. *J Dent Child* 1995;62:349-352.
22. Näsman M, Forsberg CM, Dahllöf G. Long-term dental development in children after treatment for malignant disease. *Eur J Orthod* 1997;19:151-159.
23. Alpaslan G, Alpaslan C, Gögen H, et al. Disturbances in oral dental structures in patients with pediatric lymphoma after chemotherapy: A preliminary report. *Oral Surg Oral Med Oral Pathol Oral Radiol Endod* 1999;87:317-321.
24. Dept de Radiologia da Faculdade de Odontologia da Universidade de São Paulo. In: Lee KB, ed. *Estudo da Prevalência das Anomalias Dentárias de Desenvolvimento por Meio de Radiografias Panorâmicas em uma Amostra Populacional da Cidade de São Paulo* (Tese). São Paulo, Brazil: Dept de Radiologia da Faculdade de Odontologia da Universidade de São Paulo; 1999.
25. Dept de Radiologia da Faculdade de Odontologia da Universidade de São Paulo. In: Girondi JR, ed. *Estudo da Prevalência das Anomalias Dentárias de Desenvolvimento por Meio de Radiografias Panorâmicas em uma Amostra Populacional da Cidade de São Paulo* (Tese). São Paulo, Brazil: Dept de Radiologia da Faculdade de Odontologia da Universidade de São Paulo; 2001.
26. Dury DC, Roberts MW, Miser JS, et al. Dental root agenesis secondary to irradiation therapy in a case of rhabdomyosarcoma of the middle ear. *Oral Surg* 1984;57:595-599.
27. Cousin GCS. Oral manifestations of leukemia. *Dent Update* 1997;24:67-70.

Copyright of Journal of Dentistry for Children is the property of American Academy of Pediatric Dentistry and its content may not be copied or emailed to multiple sites or posted to a listserv without the copyright holder's express written permission. However, users may print, download, or email articles for individual use.