

The Use of Resin-based Composite Restorations in Pulpotomized Primary Molars

Jorge H. Caceda, DDS, MPH, MS

ABSTRACT

The purpose of this retrospective clinical study was to report a 12- to 54-month follow-up, in which a resin-based composite filling material was used in direct contact with a fast-setting zinc oxide eugenol cement to restore the function and anatomy of 51 pulpotomized primary molars in 2- to 11-year-old children who needed a Class I or II restoration. Formocresol pulpotomy using Temrex cement was performed in all cases. The total-etch technique was used with: (1) 35% phosphoric acid; (2) OptiBond Solo Plus bonding agent; and (3) Filtek P60/shade B2 resin-based composite material. The restored teeth were sealed with Embrace pit and fissure sealant, monitored, and evaluated with periodic radiographs and clinical exams at 6-month recall visits. The results revealed that none of the 51 pulpotomized primary molars had evidence of periapical or furcation pathosis, recurrent decay, open margins, or broken restorations. In conclusion, this clinical study demonstrated that resin-based composite restorations—combined with the total-etch technique and a fifth-generation bonding agent and in direct contact with a fast-setting zinc oxide eugenol cement were long-lasting, quality clinical alternatives to restore the anatomy and function of pulpotomized primary molars. (*J Dent Child* 2007;74:147-50)

KEYWORDS: COMPOSITE RESINS, PULPOTOMY, MOLARS, PRIMARY

Due to the destruction of hard tooth tissue caused by extensive carious lesions in many pulpotomized primary molars, the use of stainless steel crowns (SSCs) has been the treatment of choice to restore the function and anatomy of these teeth.^{1,2} Currently, the improvement in the bond strengths, wear resistance, and esthetics of resin-based composite materials have allowed a change in the selection of dental materials to restore primary teeth with extensive carious lesions and poor tooth tissue support.³⁻⁵ Furthermore, these improvements in the quality of dental materials have led the dental profession to modify some clinical aspects in the treatment of dental decay. This allows for the preservation of tooth structure and more esthetic and longer-lasting restorations in both primary and permanent teeth. In teeth treated with pulp

therapy in which zinc oxide eugenol cement (ZOE) was used to obturate the root canal, the use of resin-based composite material in direct contact with ZOE has not been indicated. A resin-based composite (RBC) material should not be used over ZOE because ZOE can inhibit micro-hardness, increase microleakage and produce adequate poor bond strength to dentin.⁶⁻⁸ On the other hand, some in vitro studies performed to evaluate the effect of ZOE on RBC materials have shown no adverse effect, making the interpretation of this interaction somewhat contradictory.⁹⁻¹¹ At present, no clinical studies have shown whether a RBC material in direct contact with ZOE cement has a long-lasting effect to restore pulpotomized primary molars.

The purpose of this retrospective clinical study was to report a 12- to 54-month follow-up, in which a resin-based composite filling material was used in direct contact with a fast-setting zinc oxide eugenol cement to restore the function and anatomy of 51 pulpotomized primary molars in 2- to 11-year-old children who needed a Class I or II restoration.

Dr. Caceda is clinical associate professor, Department of Pediatric Dentistry, University of Medicine and Dentistry of New Jersey, New Jersey Dental School, Newark, New Jersey. Correspond with Dr. Caceda at jhkcdca@earthlink.net

METHODS

Selected were 51 pulpotomized primary molars of 2- to 11-year-old child patients from the author's dental office needing a Class I or II restoration and followed over a period of 12 months. The medical status of all children was unremarkable and noncontributory. Using a standard technique, periapical and bitewing radiographs from the affected tooth were taken prior to the pulpotomy therapy. Teeth with a carious lesion that had evidence of pulp involvement, but which did not have furcation, periapical pathosis, or internal or external root resorption, were selected. All cases were diagnosed and treated by the same pediatric dentist. The pulp therapy and the RBC restoration were performed in one appointment using 2% lidocaine with epinephrine 1:100,000, rubber dam isolation and a fast-setting ZOE (Temrex cement, Temrex Corp, Freeport, NY).

The pulpotomy therapy was completed using a cotton pellet moistened with full-strength formocresol and placed on the radicular pulp stumps for 5 minutes. After waiting approximately 2 minutes for the ZOE to set, the prepared tooth's axial wall was cleaned with a hand instrument and/or high-speed hand-piece to ensure that the dentin and enamel were free of the ZOE. The total-etch technique was used with:

1. 35% phosphoric acid (Gel Etch, Temrex Corp, Freeport, NY);
2. OptiBond Solo Plus bonding agent (Kerr Corp, Orange, Calif); and
3. Filtek P60/shade B2 RBC material (3M/ESPE, St. Paul, Minn).

In all cases, the cavity preparation was filled using the incremental light cure technique. Each increment of approximately 2 mm thickness was cured for 20 seconds with a conventional halogen light-curing unit (Litex 680A, Dent America, City of Industry, Calif). The anatomy, function and occlusion of all primary molars were restored using a flame-shaped White Arkansas Stone (Dedeco International, Inc, Long Eddy, NY) and/or a 12-blade finishing bur (Dentsply Caulk, Milford, Del) and articulating paper (Accu Film II, Parkell, Farmingdale, NY). They were then sealed with Embrace Wet Bond Pit and Fissure sealant (Pulpdent Corp, Watertown, Mass) to ensure that the clinical interface between the RBC material and the enamel on the occlusal surface did not have any voids. All teeth were monitored and evaluated with periodic radiographs and clinical exams at 6-month recall visits. Treatment success was established when a pulpotomized tooth showed neither clinical nor radiographic evidence of pathosis as aforementioned.

RESULTS

Twenty-eight first molars and 23 second primary molars from 39 patients were included in the study. The patients' ages ranged from 2 to 11 years (mean age=6.5 years). The

13 teeth that initially needed a Class I restoration had the lingual or buccal surface also restored. There were 6 teeth that needed a Class II restoration only, and 32 teeth with a Class II restoration that also had a lingual or buccal restoration. A total of 21 teeth and 30 teeth were treated in the upper and lower dental arches, respectively (Table 1). Table 2 shows the number of pulpotomized teeth for a period of 12- to 54-month follow-up (mean follow-up=23 months). Recall exams and radiographs revealed no evidence of periapical or furcation pathosis, recurrent decay, open margins or broken restorations in all pulpotomized primary teeth. Figure 1 shows the pre- and postoperative treatment of 3 cases in which this technique was used.

Table 1. Gender Distribution, Mean Age at the Time of the Pulp Treatment, and Number of Pulpotomized Primary Molars According to Type of Restoration and Location

Gender		Mean age (ys)		Restoration type			Tooth type and location			
				Class I	Class II		First molar		Second molar	
M	F	M	F	*	†	‡	Maxillary	Mandibular	Maxillary	Mandibular
21	18	5.8	6.3	13	6	32	12	16	9	14

Table 2. Number and Type of Pulpotomized Primary Molars According to Follow-up Period

Follow-up (mos)	Pulpotomized primary molars		Total
	First molar	Second molar	
12-23	4	4	8
24-35	5	4	9
36-47	9	8	17
48-54	10	7	17

DISCUSSION

Some of the most important factors in restoring pulpotomized primary teeth appear to be clinical factors,¹²⁻¹⁵ such as:

1. cavity preparation and configuration;
2. amount of tooth surface left after removal of the carious lesion;
3. patient cooperation; and
4. the selection of an appropriate dental material.

Regarding the selection of dental materials to treat pulpotomized primary teeth, ZEO and SSCs have been and still are the recommended dental material to treat this condition.¹⁶ In vitro studies comparing different restorative materials in pulpotomized primary teeth have shown that RBC restorations provided a better margin seal compared to the use of a SSC cemented with glass ionomer.¹⁷

The results of these in vitro studies supports this clinical

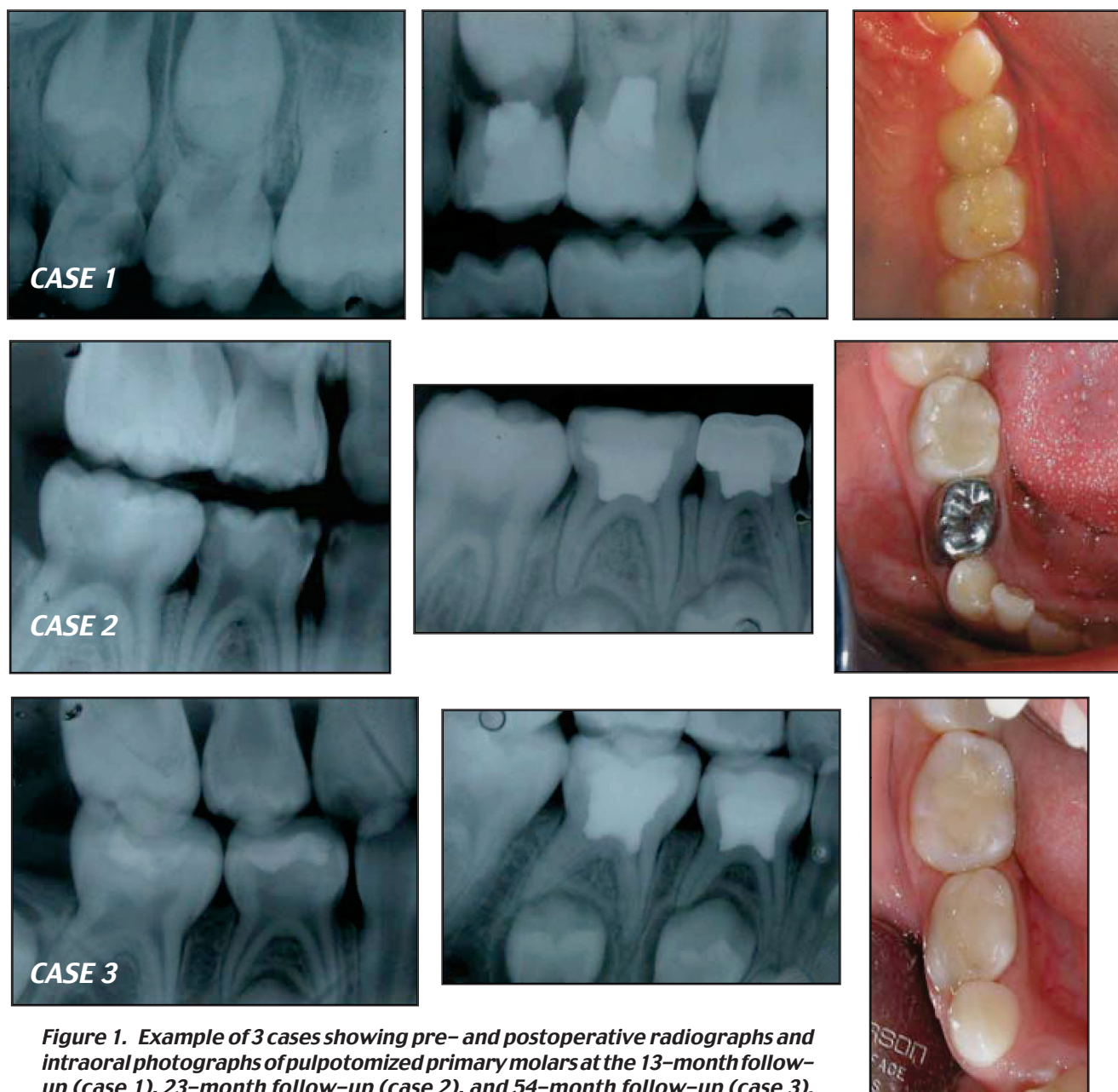


Figure 1. Example of 3 cases showing pre- and postoperative radiographs and intraoral photographs of pulpotted primary molars at the 13-month follow-up (case 1), 23-month follow-up (case 2), and 54-month follow-up (case 3).

study's findings. The time frame to complete a pulp therapy and restore the anatomy and function of a primary tooth will depend, in some cases, on the type of dental material used. In pulpotted primary teeth, ZOE or a reinforced intermediate restorative material (IRM) are the materials of choice to seal the entrance to the root canals. The setting time of ZOE is not a critical factor for the cementation and placement of the SSC. On the other hand, the long setting time of ZOE and IRM (approximately 6-10 minutes) makes use of composite material to restore the anatomy and function of primary teeth in the same dental visit sometime impractical. In this clinical study, all pulpottedies were performed using Temrex, a fast-setting ZOE, which has a setting time of approximately 2 minutes from the start of the mix. In terms of a clinical perspective, the Temrex cement's short setting time makes the use of composite material in

pulpotted primary teeth easy and practical compared to traditional ZOE or IRM cements. Recently, a retrospective study has shown a 69% to 83% success rate in pulpotted primary teeth restored with a Z-100 resin-based material.¹⁸ In the same retrospective study, the difference in the success after at least 6 months follow-up was associated with the number of surfaces restored and use of a glass ionomer cement to cover the IRM.

In this clinical study, a P-60 composite material, which is recommended to restore posterior teeth, was placed using a fifth-generation bonding agent and in direct contact with the Temrex cement. Although no glass ionomer was used to cover the Temrex cement, in all cases presented in this study the success rate was 100%. It has been reported that eugenol inhibits the curing of the composite material, which suggests that this inhibition occurs when the eugenol is in

its active stage and the ZOE is not fully set.¹⁹⁻²¹ Considering the 100% success and long-lasting effect of composite restorations in pulpotomized primary teeth shown in this study, it may be speculated that the fast-setting ZOE use in all pulpotomized primary molars does not interfere with the curing and bonding of the P-60 composite material to the dentin and the primary tooth's enamel surface. This might be due to the fast-setting of the Temrex cement, possible inactivation of the eugenol and care taken to remove any residue of ZOE from the cavity preparation's axial wall.

It is also important to point out that, in all cases, the composite material was placed using the incremental technique. Furthermore, if an inhibitory effect occurred between the eugenol and composite restoration, it took place with the first increment. In this study, the Temrex cement was set at the time that the composite material was placed and cured, suggesting that inhibition did not take place even with the first increment.

CONCLUSIONS

This clinical study demonstrated that resin-based composite restorations—combined with the total-etch technique and a fifth-generation bonding agent and in direct contact with a fast-setting zinc oxide eugenol cement—were long-lasting, quality clinical alternatives to restore the anatomy and function of pulpotomized primary molars.

ACKNOWLEDGEMENTS

The author would like to thank Dr. Melvyn Oppenheim, Clinical Professor, Department of Pediatric Dentistry, University of Medicine and Dentistry of New Jersey, New Jersey, New Jersey Dental School, for his suggestions in the preparation of this manuscript.

REFERENCES

- Holan G, Fuks AB, Nirit K. Success rate formocresol pulpotomy in primary molars restored with stainless steel crown vs amalgam. *Pediatr Dent* 2002;24:212-6.
- Messer LB, Levering NJ. The durability of primary molar restorations: Observations and predictions of success of stainless steel crowns. *Pediatr Dent* 1988;10:81-5.
- Nakornchai S, Harnirattisai C, Surarit R, Thiradilok S. Microtensile bond strength of a total-etching adhesive to caries-affected and intact dentin in primary teeth. *J Am Dent Assoc* 2005;135:477-83.
- Alex G. Adhesive dentistry: Where are we today? *Compend Contin Educ Dent* 2005;26:150-5.
- Baghdadi ZD. Bond strengths of Dyract AP compomer material to dentin of permanent and primary molars: Phosphoric acid versus nonrinse conditioner. *J Dent Child* 2003;70:145-52.
- Reisbick MH, Brodsky JF. Strength parameters of composite resins. *J Prosthet Dent* 1971;26:178-85.
- Yap AU, Shah KC, Loh ET, Sim SS, Tan CC. Influence of eugenol-containing temporary restorations on bond strength of composite dentin. *Oper Dent* 2001;26:556-61.
- Yap AU, Shah KC, Loh ET, Sim SS, Tan CC. Influence of ZOE temporary restorations on microleakage in composite restorations. *Oper Dent* 2002;27:142-6.
- Ganss C, Jung M. Effect of eugenol-containing temporary cements on bond strength of composite to dentin. *Oper Dent* 1998;23:55-62.
- Jung M, Ganss C, Senger S. Effect of eugenol-containing temporary cements on bond strength of composite to enamel. *Oper Dent* 1998;23:63-8.
- Leirskar J, Nordbo H. The effect of zinc oxide-eugenol on the shear bond strength of a commonly used bonding system. *Endod Dent Traumotol* 2000;16:265-8.
- Feilzer AJ, DeGee AJ, Davidson CL. Setting stress in composite resin in relation to configuration of the restoration. *J Dent Res* 1987;66:1636-9.
- Donly KJ, Garcia-Godoy F. The use of resin-based composite in children. *Pediatr Dent* 2002;24:480-8.
- Pamir T, Türkün M. Factors affecting microleakage of a packable resin composite: An in vitro study. *Oper Dent* 2005;30:338-45.
- Suwatviroj P, Messer LB, Palamara JE. The effects of cavity preparation and lamination on bond strength and fractures of tooth-colored restorations in primary molars. *Pediatr Dent* 2002;25:534-40.
- McDonald RE, Avery DR, Dean JA. Treatment of deep caries, vital pulp exposure, and pulpless teeth. In: MacDonald RE, Avery DR, eds. *Dentistry for the Child and Adolescent*. 8th ed. Philadelphia, Pa: CV Mosby Co; 2004:388-412.
- Guelmann M, Bookmyer KL, Villalta P, Garcia-Godoy F. Microleakage of restorative techniques for pulpotomized primary molars. *J Dent Child* 2004;71:209-11.
- Guelmann M, McIlwain MF, Primosch RE. Radiographic assessment of primary molar pulpotomies restored with resin-based materials. *Pediatr Dent* 2005;27:24-7.
- Cohen BI, Volovich Y, Musikant BL, Deutsch AS. The effects of eugenol and epoxy-resin on the strength of a hybrid composite resin. *J Endod* 2002;28:79-82.
- Millstein PL, Nathanson D. Effect of eugenol and eugenol cements on cured composite resin. *J Prosthet Dent* 1983;50:211-5.
- Salama FS. Influence of zinc-oxide eugenol, formocresol, and ferric sulfate on bond strength of dentin adhesives to primary teeth. *J Contemp Dent Pract* 2005;6:14-21.

Copyright of Journal of Dentistry for Children is the property of American Academy of Pediatric Dentistry and its content may not be copied or emailed to multiple sites or posted to a listserv without the copyright holder's express written permission. However, users may print, download, or email articles for individual use.