

Kenny–Caffey Syndrome: Oral Findings and 4-year Follow-up of Overlay Denture Therapy

Tahsin Demir, DDS Defne Kecik, DDS, PhD Zafer C. Cehreli, DDS, PhD

ABSTRACT

Kenny–Caffey Syndrome (KCS) is an extremely rare osteosclerotic bone dysplasia associated with hypocalcemia and ocular abnormalities. Although the condition is well reported in the medical literature, dental manifestations have not been discussed in great detail. The purpose of this report is to present specific oral features and prosthetic management in a KCS patient. Overlay dentures were utilized in the management of low vertical dimension of occlusion, congenital absence of several permanent teeth, and problems associated with function and esthetics. Results of the 4-year follow-up overlay denture therapy are presented. (*J Dent Child* 2007;74:236-40)

KEYWORDS: KENNY–CAFFEY SYNDROME, OVERLAY DENTURE, OVERDENTURE, OLIGODONTIA

Kenny–Caffey syndrome (KCS) is an extremely rare bone dysplasia characterized by: (1) medullary stenosis of the long bones; (2) growth retardation with short stature; (3) intermittent to long-standing (episodic) hypocalcemia; and (4) ocular abnormalities.¹⁻⁸ Features occasionally associated with the phenotype include anemia, minor genitourinary anomalies, micro-orchidism or infertility (in affected males), calcification of the basal ganglia, central nervous system malformations, and T-cell dysfunction.^{1,2,9-13} Small hands and feet have also been consistently reported.^{8,10}

In addition to skeletal and calcium abnormalities, oral and dental findings reported separately or in combinations in the medical literature^{2,5,6,9,11,14} include: (1) micrognathia; (2) generalized hypodontia; (3) delayed eruption; (4) dental caries; and (5) gingivitis. It is unclear, however, whether clinical features such as caries, gingivitis, delayed eruption, etc. are specific to KCS. To date, dentate, caries-free patients with healthy gingiva and normal eruption time have also been reported.^{11,15}

Despite a variety of oral and dental problems associated with KCS-affected patients, there appears to be no documentation on available treatment options other than tooth extractions. The purpose of the present paper is to report the oral and dental findings in a KCS patient and present results of the 4-year clinical follow-up of oral rehabilitation accomplished by use of overlay dentures.

CASE REPORT

A 13-year-old boy was referred to the pediatric dentistry clinic at the Hacettepe University Faculty of Dentistry, Ankara, Turkey, with the chief complaints of: difficulty in chewing, difficulty with speech, and compromised esthetics. He was being regularly followed by several medical departments due to systemic problems associated with Kenny–Caffey syndrome (KCS). Reportedly, the patient was born after an uneventful first pregnancy to nonconsanguineous, healthy parents. Later, the mother delivered two healthy female siblings. On the third postnatal day, the patient presented with episodes of generalized convulsions due to hypocalcemia and received treatment, after which the patient's serum calcium levels were normalized. The patient had his second hospital admission at age 4, reportedly because his growth and weight were perceptibly lagging behind his peers. The patient was diagnosed for Di George syndrome and treated accordingly until age 9, during which a moderate increase in body weight

Dr. Demir is research assistant and Dr. Cehreli is associate professor, Department of Pediatric Dentistry, Faculty of Dentistry, Hacettepe University, Ankara, Turkey; Dr. Kecik is research associate, Department of Orthodontics, Faculty of Dentistry, Baskent University Ankara, Turkey. Correspond with Dr. Cehreli at zcehrel@yahoo.com

and height was recorded. The patient was further diagnosed for KCS by his:

1. genetic profile;
2. blood chemistry; and
3. other clinical characteristics, which included:
 - a. proportionally short stature;
 - b. narrow prominent forehead;
 - c. small deep-set eyes;
 - d. low set ears;
 - e. slender extremities;
 - f. normal intelligence; and
 - g. radiographic evidence of open anterior fontanelle and medullary stenosis of the long bones.

Following definitive diagnosis, the patient received synthetic growth hormone as well as routine medications until age 13. The hormone therapy had been recently discontinued due to changes in his hepatic enzyme profiles.

Clinical examination findings were consistent with the prediagnosed features of KCS. Additionally, the patient presented with a protruded chin and nose tip at full jaw closure. Due to his low facial height, there was a deep labiomental sulcus with the lower lip folded downwards (Figure 1). Oral examination of the patient revealed absence of several teeth, and the remaining teeth had hypoplastic enamel of varying degrees (Figure 2). When the patient was asked to bring jaws to full closure, the upper incisors prematurely contacted the edentulous intercanine alveolar crest, avoiding contact of the posterior teeth (Figure 2). Due to this problem, the patient was not able to use his molar teeth for grinding. Bilateral tongue thrust accompanied the deep bite. A marked midline diastema and a fibrous labial frenulum extending to the alveolar crest were also observed.

Radiographic examination revealed severe oligodontia that affected the permanent dentition (Figure 3). The only

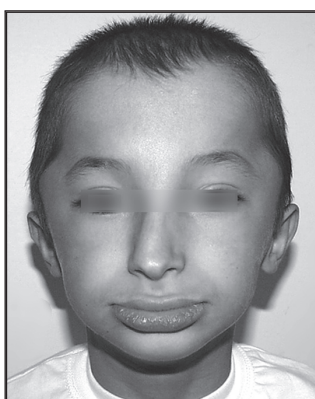

Figure 1. View of the patient at first visit.

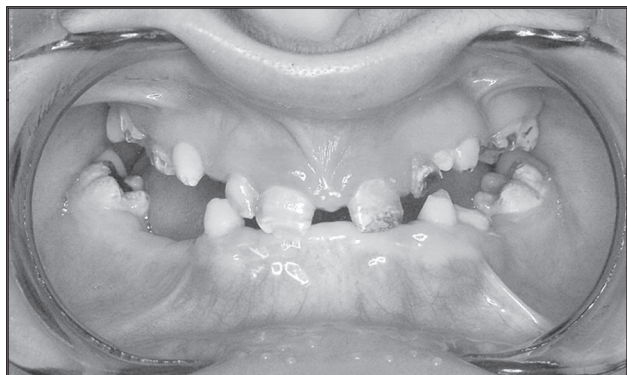

Figure 2. Intraoral view of the patient at full closure. Bilateral posterior open bite due to the premature contact caused by his maxillary incisors is evident.

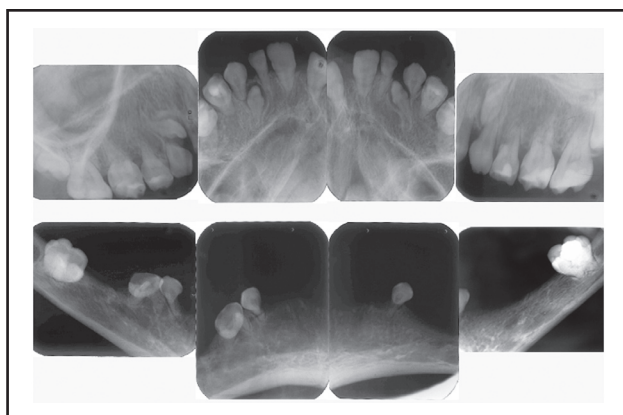


Figure 3. Periapical radiographs taken at first visit.

permanent teeth present were the: maxillary and mandibular first molars; maxillary central incisors; and unerupted maxillary canines. Radiographically, the unerupted maxillary canines demonstrated: extremely short roots; slender pulpal space; and short, conical crowns. Discontinuity in the lamina dura was consistent in both primary and permanent teeth. All permanent molars demonstrated pulpal calcifications; and extremely short and conical roots with thin root canals. Intrapulpal calcifications were also observed in primary molars and canine teeth (Figures 2 and 3). The patient had a few occlusal restorations and showed moderate oral hygiene and good periodontal status. Results of the Ricketts analysis showed that the maxilla and mandible were positioned retrusively relative to the cranial base and that the patient had a severe brachyfacial cranial type (Figure 4). The lower facial height angle was 39° (the normal value, being 45° – 47°).

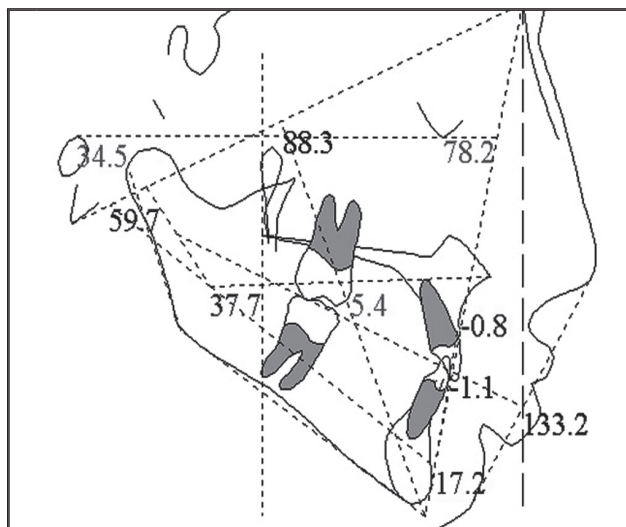


Figure 4. Results of the Ricketts analysis.

Despite short roots, the permanent molar teeth were not mobile. The abscessed maxillary left primary first molar was extracted. In light of clinical findings, overlay denture therapy was the treatment of choice for: (1) rehabilitation of the lost vertical dimension; (2) partial edentulism; and (3) compromised esthetics. Preliminary impressions were

made with stock trays and irreversible hydrocolloid impression material (Kromopan, Lascod, Italy). Custom, self-cured acrylic resin trays were fabricated to obtain final impressions. Final impressions were made using a vinyl polysiloxane impression material (Panasil, Kettenbach, Germany).

The vertical dimension of occlusion was determined using a Boley gauge, and intermaxillary relationships were recorded on occlusion rims. Final adjustments of the dentures were made in the mouth. The dentures were delivered to the patient following storage and hygiene instructions. First recall was scheduled 1 week later. The use of overlay dentures apparently caused no discomfort, and the patient was highly motivated by the esthetic results and the improved ease of eating.

The patient has been attending regular control visits for 4 years (Figure 5). Over this time, the overlay dentures have been replaced twice. At every semiannual visit, the overlay dentures were used as custom fluoridation trays. The patient did not report any discomfort regarding the use of his prostheses. The retention of the dentures relies solely on physiologic undercuts of all overlaid teeth, which have provided perfect stability and retention to date. The supporting teeth, periodontal tissues, and the temporomandibular joint (TMJ) were free of symptoms. Annual cephalometric follow-ups performed with Ricketts analysis showed that the maxilla and mandible were still positioned retruded relative to the cranial base, while the lower facial height angle of 38° at the beginning of treatment was improved to 39° after 4 years (Figures 6 and 7). This value, however, is still lower than the normal value ($45^\circ - 47^\circ$).

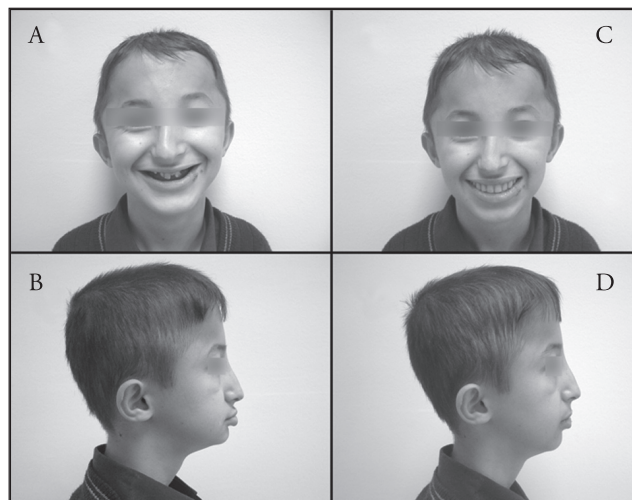

Figure 5. Clinical view of the patient without (A and B) and with (C and D) overlay dentures at year 4.

DISCUSSION

In the present report, detailed oral and dental findings for a boy with KCS are presented. Kjellberg et al¹⁶ have reported that boys who are short statured—either due to idiopathic origin or growth hormone deficiency—demonstrate similar orofacial findings and a proportionately smaller facial height. Their findings also

include: a marked delay in dental maturation and tooth eruption; dental crowding; reduced overbite; and larger palatal height (with smaller palatal width).

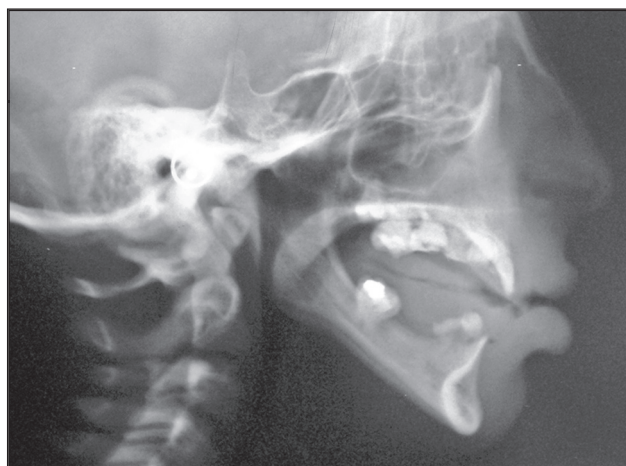

Figure 6. Lateral cephalogram of the patient recorded with overlay dentures.

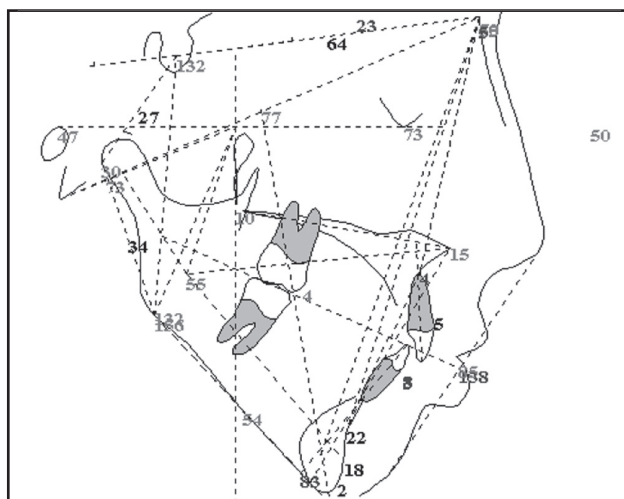


Figure 7. Results of the Ricketts analysis after 4 years.

KCS is an unusual cause of short stature that manifests with orofacial features similar to those of idiopathic origin or due to growth hormone deficiency. A study by Cantu et al¹⁷ has shown that exogenous growth hormone therapy clearly has less of a positive effect on craniofacial bony development than on somatic (height) growth or overall skeletal maturation. Their findings are confirmed in the present case, with the minimal increase in lower facial height. This contrasts to an approximately 2-fold increase in body height and weight, as observed during the 4-year follow-up.

While delayed eruption and the absence of permanent teeth in this patient corroborate with previous KCS reports, the periodontal condition was insignificant. Due to the lack of previous data, it is not known if the reported dental features herein—which include short-conical roots with thin root canals, discontinuity in lamina dura, slender coronal pulpal space, intrapulpal calcifications, enamel hypoplasia, and short-conical crowns—are specific to KCS.

Another aim of this report was to present the long-term follow-up of overlay denture therapy. The dental literature has reported the advantages of overlay denture prostheses, which include: (1) improved support and stability; (2) improved proprioception and neuromuscular feedback mechanism; and (3) preservation of tooth structure and alveolar bone.¹⁷⁻²⁰ Additional benefits of this treatment modality are: restoration of the vital oral function of speech; swallowing and chewing with improved comfort; and an increased sense of security.²¹⁻²³ Although partial removable dentures were suggested as another treatment option, the patient refused using a denture with clasps. Despite his retarded growth, dental implants were not considered due to his age. Patients using removable dentures during years of growth must be examined at least once a year to assess the necessity to reline/rebase or remake the prostheses, depending on the dentures' growth profile and fit.²² In the present case, the overlay dentures were rebased in the first year and refabricated twice (years 2 and 4) during the 4-year follow-up. The reason for the first change was fracture of the dentures during cleaning outside the mouth.

Caries has been a major concern with use of overdentures, particularly with maxillary ones, since the maxillary teeth are isolated from saliva by the denture, thus avoiding the protective and remineralizing capacity of saliva.²² In the present case, this did not appear to be a problem, since the patient maintained excellent home care. Topical fluoridation with APF gel using the prostheses as fluoridation trays could also have contributed to the overall success. Another major concern is the status of periodontal tissues. Over the clinical follow-up period of 4-years, the patient demonstrated excellent gingival health with apparent lack of tooth mobility. These findings corroborate with previous case reports and clinical studies showing no significant change in the periodontium when proper hygiene measures as well as resting of supporting structures during sleeping hours are maintained.^{19,22}

When proper assessments are made at the preprosthetic stage, restoration of the vertical height with overdentures has been shown to avoid TMJ-related complications for up to 25 years.²² During the 4-year clinical assessment, the TMJ appeared to be stable with no signs of pain or hypertonicity.

Applying overlay dentures in the present case with KCS provided a simple, conservative, and effective oral rehabilitation, as observed over the long-term clinical follow-up.

REFERENCES

1. Kenney FM, Linarelli L. Dwarfism and cortical thickening of tubular bones. *Am J Dis Child* 1966;111:201-7.
2. Caffey J. Congenital stenosis of medullary spaces in tubular ones and calvaria in two proportional mother and son dwarfs, coupled with transitory hypocalcemic tetany. *Am J Roentgenol* 1967;100:1-11.
3. Larsen JL, Kivlin J, Odell WD. Unusual case of short stature. *Am J Med* 1985;78:1025-32.
4. Diaz GA, Khan KTS, Geib BD. The autosomal recessive Kenny-Caffey syndrome locus maps to chromosome 1q42-q43. *Genomics* 1998;54:13-18.
5. Khan KTS, Uma R, Usha R, Al Ghanem MM, Al Awadi SA, Farag TI. Kenny-Caffey syndrome in six bedouin sibships: Autosomal recessive inheritance is confirmed. *Am J Med Genet* 1997;69:126-32.
6. Abdel-Al YK, Auger LT, El-Gharbawy F. Kenny-Caffey syndrome: Case report and literature review. *Clin Pediatr* 1989;28:175-79.
7. Fernandez GR, Negrete FJ, Martin BG, Lozano C. Bilateral optic atrophy in Kenny's syndrome. *Acta Ophthalmol* 1992;70:135-38.
8. Sabry MA, Farag TI, Shaltout AA, Zaki M, Al-Mazidi Z, Abulhassan SJ, Al-Torki N, Quishavi A, Al Awadi SA. Kenny-Caffey syndrome: An Arab variant? *Clin Genet* 1999;55:44-49.
9. Majewski F, Rosendahl W, Ranke M, Nolte K. The Kenny syndrome: A rare type of growth deficiency with tubular stenosis, transient hypoparathyroidism, and anomalies of refraction. *Eur J Pediatr* 1981;136:21-30.
10. Francheschini P, Testa A, Bogetti G, Girardo E, Gulala A, Lopez-Bell G, Buzio G, Ferrario E, Picatto E. Kenny-Caffey syndrome in two sibs born to consanguineous parents: Evidence for an autosomal recessive variant. *Am J Med Genet* 1992;42:112-16.
11. Fanconi S, Fischer JS, Wieland P, Atares M, Fanconi A, Giedion A, Prader A. Kenny syndrome: Evidence for idiopathic hypoparathyroidism in two parents and for abnormal parathyroid hormone in bone. *J Pediatr* 1986;109:469-75.
12. Boynton JR, Pheasant TR, Jounhson BL, Levin DB, Streeten BW. Ocular findings in Kenny's syndrome. *Arch Ophthalmol* 1979;97:896-900.
13. Bergada I, Schiffrin A, Abu Srair H, Kaplan P, Dornan J, Goltzman D, Hendy GN. Kenny syndrome: Description of additional abnormalities and molecular studies. *Hum Genet* 1988;80:39-42.
14. Lee WK, Vargas A, Barnes J, Root AW. Kenny-Caffey syndrome: Growth retardation and hypocalcemia in a young boy. *Am J Med Genet* 1983;14:773-82.
15. Hoffman WH, Kovacs K, Li S, Kulharya AS, Johnson BL, Eidson Ms, Cleveland WH. Kenney-Caffey syndrome and micro-orchidism. *Am J Med Genet* 1998;80:107-11.
16. Kjellberg H, Beiring M, Wikland KA. Craniofacial morphology, dental occlusion, tooth eruption, and dental maturity in boys of short stature with or without growth hormone deficiency. *Eur J Oral Sci* 2000;108:359-67.
17. Esposito S, Vergo TJ Jr. Removable overdentures in the oral rehabilitation of patient with dentinogenesis imperfecta. *J Pediatr* 1978;2:304-15.

18. Loisel RJ, Crum RJ, Rooney GE Jr, Struever CH Jr. The physiologic basis of the overlay denture. *J Prosthet Dent* 1972;28:4-12.
19. Cehreli ZC, Altay N. Dentinogenesis imperfecta: Influence of an overdenture on gingival tissues and tooth mobility. *J Clin Pediatr Dent* 1996;20:227-80.
20. Crum RJ, Rooney GE Jr. Alveolar bone loss in overdentures: A five-year study. *J Prosthet Dent* 1978;40:610-13.
21. Rissin L, House JE, Manly RS, Kapur KK. Clinical comparison of masticatory performance and electromyographic activity of patients with complete dentures, overdentures, and natural teeth. *J Prosthet Dent* 1978;39:508-11.
22. Vergo TJ Jr. Prosthodontics for pediatric patients with congenital/developmental orofacial anomalies: A long-term follow-up. *J Prosthet Dent* 2001;86:342-47.
23. Schneidman E, Wilson S, Spuller RL. Complete overlay dentures for the pediatric patient: Case reports. *Pediatr Dent* 1988;10:222-25.
24. Cengiz SB, Stephen A. The use of overdentures in the management of severe hypodontia associated with microdontia: A case report. *J Clin Pediatr Dent* 2003;27:219-22.

Copyright of Journal of Dentistry for Children is the property of American Academy of Pediatric Dentistry and its content may not be copied or emailed to multiple sites or posted to a listserv without the copyright holder's express written permission. However, users may print, download, or email articles for individual use.