

# Head and Neck Extramedullary Disease as the Initial Presentation of Acute Myelogenous Leukemia in a Child

Marcio A. da Fonseca, DDS, MS

## ABSTRACT

The purpose of this paper was to describe a child with a noncontributory medical history who sought an emergency dental appointment due to a significant facial and neck swelling. The clinical and radiographic exams revealed no odontogenic infection, and the patient was subsequently diagnosed with acute myelogenous leukemia by the hematology/oncology service. This report underscores the important role pediatric dentists can play in an early referral for further workup of a suspected malignancy, which may initially present as extramedullary disease in the head and neck. (*J Dent Child* 2007;74:241-4)

**KEYWORDS:** SUBMANDIBULAR ENLARGEMENT, LEUKEMIA, ACUTE MYELOGENOUS SARCOMA GRANULOCYTIC, CHLOROMA, EXTRAMEDULLARY DISEASE,

Acute myelogenous leukemia (AML) is a heterogeneous group of hematologic malignancies arising within bone marrow precursors of the myeloid, monocyte, erythroid, and megakaryocytic cell lineages.<sup>1</sup> Its incidence increases with age, with less than 50% of cases occurring in patients younger than 50 years.<sup>2</sup> Pediatric AML occurs in approximately 1 in 130,000 individuals younger than 20 years of age each year. Although it comprises only 15% to 20% of childhood leukemia, it accounts for greater than 30% of deaths from the disease.<sup>1,3</sup> Predisposing factors include: environmental risks (exposure to ionizing radiation and chemicals); genetic inheritance (twinning, Down's Syndrome, Fanconi's anemia, etc), and noninherited predisposition (aplastic anemia, myelodysplastic syndrome).<sup>1,2</sup>

The French-American-British classification system divides AML into 8 subtypes according to cytochemistry and immunology, describing the differentiation status of the predominant leukemic cell.<sup>1,2</sup> There is a large range of presenting signs and symptoms, including: (1) persistent fevers; (2) anemia; (3) fatigue; (4) anorexia; (5) bruising; (6) epistaxis; (7) lymphadenopathy; (8) hepatosplenomegaly; and (9) headaches.<sup>1,2</sup> Affected patients may complain of pain in the ribs, long bones, or back, and present with a limp.<sup>1</sup>

Gingival hypertrophy is present in 10% to 15% of the cases and bleeding may involve the oral mucosa.<sup>1,2</sup> Extramedullary disease (EMD) is rare but may be evident in the head and neck region. Laboratory findings include low hemoglobin, thrombocytopenia, and elevated white blood cell (WBC) count with a decreased number of mature, functional neutrophils.<sup>1</sup>

AML diagnosis is established through a combination of morphologic, immunophenotypic, and cytogenetic studies.<sup>3</sup> Because of considerable differences in clinical and biological features among the subtypes of AML as well as in response to and tolerance of therapy by age group, it is currently impossible to apply individualized treatment to the vast majority of cases.<sup>3</sup> Therefore, the overall survival rate has peaked around 60%. Remission induction is usually done with cytarabine, daunorubicin, and etoposide or 6-thioguanine, while postremission therapy is accomplished by combining noncross-resistant agents every 4 to 6 weeks.<sup>2,3</sup> The majority of relapses occurs between 9 months and 2 years.<sup>2</sup> Hematopoietic stem cell transplantation, which has shown a lower relapse rate than intensive postremission chemotherapy, is usually done in first complete remission—especially when there is an available matched-sibling donor.<sup>2,3</sup> Targeted immunotherapy with monoclonal antibodies is also being used to treat the disease.

The purpose of this paper was to describe a child with a non-contributory medical history who sought an emergency dental appointment due to a significant facial and neck swelling. The clinical and radiographic exams revealed no odonto-

*Dr. da Fonseca is clinical associate professor, Section of Pediatric Dentistry, The Ohio State University, Nationwide Children's Hospital, Columbus, Ohio. Correspond with Dr. da Fonseca at Marcio.DaFonseca@NationwideChildrens.org*

genic infection, and the patient was subsequently diagnosed with acute myelogenous leukemia by the hematology/oncology service. This report underscores the important role pediatric dentists can play in an early referral for further workup of a suspected malignancy, which may initially present as extramedullary disease in the head and neck.

## CASE REPORT

A 10-year, 7-month-old Caucasian girl with no known health problems presented for an emergency dental exam at the Nationwide Children's Hospital dental clinic complaining of pain and swelling on the left side of the face and neck, which had started approximately 48 hours before. She had a negative history of weight loss, recent illness, bone pain, fever, oral infections, trauma, toothaches and recent dental procedures. The patient was taking no medications and had no known drug allergy. Her weight was 49 kg. She had mild dysphagia, but no breathing difficulties. The extraoral exam showed a large swelling on the left face and neck crossing the midline (Figure 1). The mass was firm and painful upon touch, and the mandible's inferior border was not palpable.

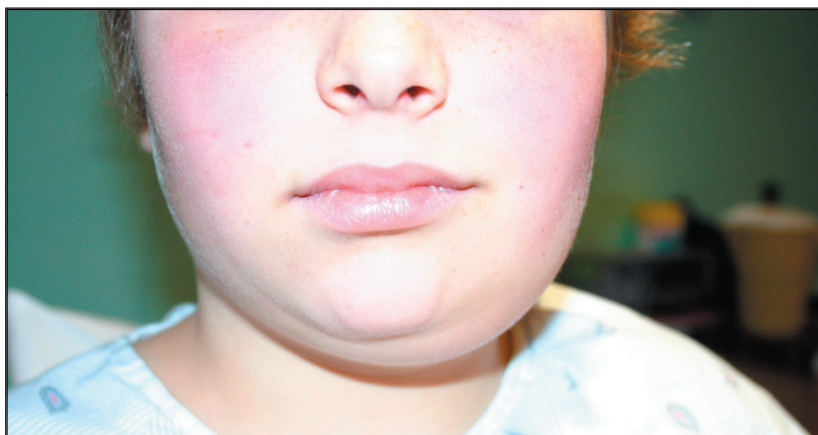

Figure 1. Significant left face and neck swelling.

There was a normal range of motion of the mandible with no trismus. The intraoral exam revealed:

1. mucosal pallor;
2. tonsils of normal appearance and size;
3. good oral hygiene with minimal plaque accumulation;
4. few areas of localized mild gingival overgrowth;
5. petechiae on the palatal gingival margin of teeth nos. 2 and 3 and on the labial gingiva of tooth no. 11.

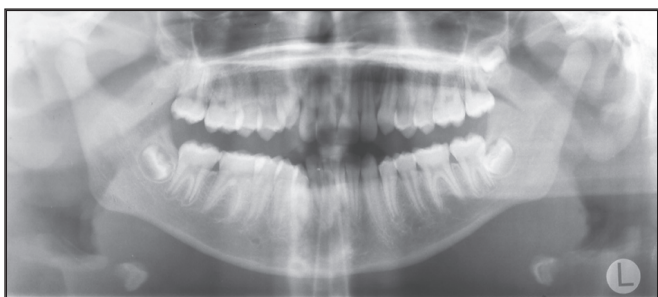


Figure 2. Panoramic radiograph showing no pathoses.

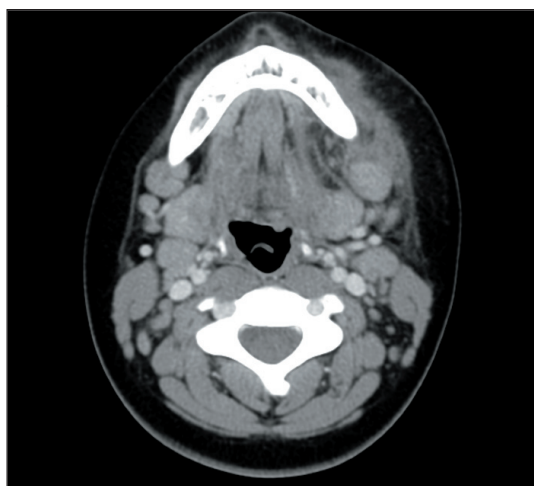


Figure 3. CT Scan showing soft tissue swelling and abnormal density on the left side.

There was no intraoral swelling, although the lower left buccal area was tender to pressure. She had a caries-free dentition with no restorations and no loose teeth although the lower left posterior teeth presented sensitivity to percussion. A lower left periapical radiograph and a panoramic film (Figure 2) showed all permanent teeth present and sound bone structure with no pathoses, although the left mandibular canal was not visible. The patient admitted that she had been feeling tired for the past 2 weeks and that her gingiva bled occasionally during toothbrushing. Due to her negative dental examination and recent history of fatigue, pallor, oral mucosal bleeding, oral petechiae, localized gingival hypertrophy and a rapidly developing swelling, an immediate medical evaluation was warranted to rule out a possible malignant condition such as AML, Ewing's sarcoma, or Hodgkin's lymphoma.

A complete blood count was evaluated in the emergency department (ED) on the same day. These results showed:

1. a slightly elevated WBC ( $14.3/\text{mm}^3$ ; normal= $4.5\text{--}13.5/\text{mm}^3$ );
2. decreased hemoglobin ( $9.1\text{ g/dl}$ ; normal= $11.5\text{--}15.5\text{ g/dl}$ );
3. low hematocrit ( $24.4\%$ ; normal= $35\%\text{--}45\%$ );
4. low platelet count ( $45,000/\text{mm}^3$ ; normal= $140,000\text{--}440,000/\text{mm}^3$ ); and
5. 51% blasts.

A computerized tomography (CT) revealed:

1. abnormal induration and swelling in the soft tissues surrounding the left mandible's angle;
2. abnormally enlarged soft tissue density;
3. regional adenopathy with enlarged left submental and sublingual lymph nodes;
4. bilateral cervical adenopathy; and
5. extensive inflammatory changes without any suppuration or abscess (Figure 3).

The findings were nonspecific but consistent with a tentative diagnosis of lymphoproliferative disorder. A bone marrow aspirate and biopsy showed a predominance of myeloblasts in the specimens (55%). Further testing yielded a diagnosis of AML subtype M2. Remission induction was promptly initiated using cytarabine, etoposide, and daunorubicin. The mass had resolved by the time the induction cycle ended 2 weeks later. Although a neck biopsy was not performed, the pediatric oncologists thought that it was very likely a granulocytic sarcoma (GS) based on the patient's history, CT scan findings and subtype of AML, which has been shown to be highly associated with GS.

## DISCUSSION

A number of childhood diseases may manifest initially in the head and neck. Thus, the pediatric dentist must be astute to suspect a systemic problem when no oral/dental explanations can be found for those manifestations. In acute leukemias, as seen in this case, it is not uncommon for the patient to seek care first from a dentist because of oral or head and neck complaints. The patient herein described presented many issues that heralded the suspicion of a malignancy, such as: fast development of a swelling without a clear etiology, recent fatigue, intraoral bleeding despite good oral hygiene, soft tissue petechiae, and unexplained gingival overgrowth. The negative findings in the radiographic exam, coupled with the aforementioned findings, warranted a thorough systemic investigation which was immediately done.

The differential diagnosis for facial and neck asymmetry included, among others:

1. facial cellulitis due to odontogenic infection;
2. facial lymphangioma;
3. Burkitt's lymphoma;
4. Langerhans cell histiocytosis;
5. fibrous dysplasia; and
6. salivary gland swelling caused by:
  - a. duct obstruction;
  - b. mumps;
  - c. parotitis;
  - d. neoplasms; and
  - e. HIV infection.

The most common head, neck, and intraoral manifestations seen as initial signs of hematologic malignancies include lymphadenopathy, laryngeal pain, gingival bleeding, oral ulceration, gingival hyperplasia, petechiae, hematomas, and ecchymoses.<sup>2,4-7</sup> The involvement of the oral mucosa is 3 times more common in acute leukemia than in chronic leukemia.<sup>7</sup> The mucosal pallor results from anemia caused by the defective erythropoiesis, whereas gingival hyperplasia, which AML shows a predilection for, represents an infiltration of leukemic cells.<sup>2,7</sup> The petechiae and the oral bleeding are associated with the quality and quantity of platelets, abnormal coagulation factors, and capillary fragility.<sup>7</sup> Dental pulp infiltration of leukemic cells may also lead patients to complain of a toothache.<sup>7</sup> Hiraki et al<sup>8</sup> described a mental nerve neuropathy of unknown etiology in 3 young subjects

diagnosed with acute lymphoblastic leukemia (ALL). Besides numbness of the chin and lower lip, these patients also presented tooth pain, tenderness in the mental foramen, loose teeth, and disappearance of the mandibular canal on radiographic examination. Interestingly, the left mandibular canal was not evident in the panoramic radiograph of this study's patient. Trismus has also been described as a possible first manifestation of ALL in a 6 year-old patient who had no oral pathology.<sup>9</sup>

EMD, which is commonly known as granulocytic sarcoma, myeloblastoma, myelosarcoma and chloroma, is used to describe any extramedullary tumorous collections of immature myeloid leukemic cells from the granulocytic lineage which are capable of local tissue destruction and invasion.<sup>1,10-14</sup> EMD is usually associated with chronic leukemias and other myeloproliferative disorders and may either precede their development or present at any time in the course of the disease or during a remission or relapse.<sup>12-15</sup> It can also occur without overt hematologic disease and be completely asymptomatic.<sup>16</sup> "Extramedullary leukemia" (EML), a term that should be used to describe patients with extramedullary, nonmedullary leukemia, is an unusual presentation of AML.<sup>14</sup> The Children's Cancer Group reported an 11% incidence of EML, with the most common sites being, in order, the skin, orbit, head and neck, and central nervous system.<sup>14</sup> A smaller study on pediatric patients with myelodysplastic syndromes found an incidence of 36%.<sup>15</sup> EMD is thought to arise in the bone marrow and travel through the Haversian canals to reach the bone's subperiosteal region. Once in the periosteum, the tumor cells can spread to other parts of the body.<sup>11,12</sup> Clinically, EMD presents as rapidly growing, firm, nodular masses.<sup>1,10,11,16</sup> It has a predilection for the cranium and facial bones and is most commonly found in the skin, soft tissue, lymph node, orbit, or periorbital areas. In the latter, EMD can lead to ptosis and exophthalmos.<sup>1,10-12,17,18</sup> EMD can also be found in the gingiva, parotid gland, nasal cavity, oral cavity, and masticatory muscles.<sup>10-13,15,19,20</sup> When the temporal bone is involved, pre- and postauricular swellings, hearing loss, otalgia, and facial paralysis can be observed.<sup>18,19,21</sup> Carmona et al<sup>22</sup> presented a case of GS that developed in the socket following a tooth extraction in an adult patient with chronic myelogenous leukemia.

EMD is more prevalent in patients younger than 15 years old and 4 times more frequent in AML subtype M2.<sup>2,11,16,21</sup> There is no gender preference,<sup>11,16,21</sup> but in intraoral cases women seem to be affected twice as often as men.<sup>13,22</sup> The tumor's histologic diagnosis can be made using routine tissue examination, immunochemical staining, or electron microscopy. It can also be suspected on CT and MRI scans.<sup>11</sup> The term chloroma comes from the tumor's bluish-green appearance on the cut surface secondary to myeloperoxidase granules in the blasts' cytoplasm, but it is not very specific because not all masses contain myeloperoxidase.<sup>1,10,14</sup> The initial solitary lesion may be misdiagnosed as lymphoma, rhabdomyosarcoma, neuroblastoma, Ewing's sarcoma, or eosinophilic granuloma.<sup>16,19,21</sup> EMD should also be included



in the differential diagnosis of rapid and severe gingival hyperplasia because the tumor can occur before the diagnosis of leukemia or without any bone marrow involvement.<sup>13</sup>

There is no uniform treatment for EMD. Most patients achieve a complete remission with aggressive combination chemotherapy, thus routine irradiation at the induction therapy is probably not necessary.<sup>14</sup> Localized radiation should be reserved for patients with life-threatening or organ-threatening EMD and for those with residual disease at the end of induction.<sup>14</sup> Hematopoietic stem cell transplant has been successful in some cases.<sup>10,11,16,17,19</sup> EML patients must be followed closely for evidence of extramedullary relapse. The series presented by the Children's Cancer Group showed that the first site of relapse in almost 40% of EML patients was extramedullary, particularly the central nervous system.<sup>14</sup> Most studies<sup>11,17,21</sup> have shown a poor prognosis for EMD patients, although Bisschop et al<sup>20</sup> did not find a prognostic significance of EML in AML children.

In summary, pediatric dentists should have a heightened awareness of oral manifestations of systemic diseases because patients may present with head and neck problems for which there are no obvious oral/dental explanations. The frequency with which head and neck manifestations are observed in malignancies, particularly in acute leukemias, shows the important role dental professionals play in an early referral which may save patients' lives.

## REFERENCES

- Golub TR, Arceci RJ. Acute Myelogenous Leukemia. In: Pizzo PA, Poplack DG, eds. Principles and Practice of Pediatric Oncology. 4th ed. Philadelphia, Pa: Lippincott Williams & Wilkins; 2002:545-89.
- Parisi E, Draznin J, Stoopler E, et al. Acute myelogenous leukemia: Advances and limitations of treatment. *Oral Surg Oral Med Oral Pathol Oral Radiol Endod* 2002;93:257-63.
- Pui CH, Schrappe M, Ribeiro RC, Niemeyer CM. Childhood and adolescent lymphoid and myeloid leukemia. *Hematology* 2004;1:118-45.
- Hou GL, Huang JS, Tsai CC. Analysis of oral manifestations of leukemia: A retrospective study. *Oral Dis* 1997;3:31-38.
- Stafford R, Sonis S, Lockhart P, Sonis A. Oral pathoses as diagnostic indicators in leukemia. *Oral Surg Oral Med Oral Pathol* 1980;50:134-9.
- Dean AK, Ferguson JW, Marvan ES. Acute leukemia presenting as oral ulceration to a dental emergency service. *Aust Dent J* 2003;48:195-7.
- Weckx LLM, Hidal LBT, Marcucci G. Oral manifestations of leukemia. *Ear Nose Throat J* 1990;69:341-6.
- Hiraki A, Nakamura S, Abe K, et al. Numb chin syndrome as an initial symptom of acute lymphocytic leukemia. *Oral Surg Oral Med Oral Pathol Oral Radiol Endod* 1997; 83:555-61.
- Katz J, Peretz B. Trismus in a 6-year-old child: A manifestation of leukemia? *J Clin Pediatr Dent* 2002;26:337-9.
- Lampkin BC, Bernstein I, Odom L, et al. Biologic characteristics and treatment of acute nonlymphocytic leukemia in children. *Pediatr Clin North Am* 1988;35:743-64.
- Bassichis B, McClay J, Wiatrak B. Chloroma of the masseteric muscle. *Int J Pediatr Otorhinolaryngol* 2000;53:57-61.
- Uyesugi WY, Watabe J, Petermann G. Orbital and facial granulocytic sarcoma (chloroma): A case report. *Pediatr Radiol* 2000;30:276-8.
- Antmen B, Haytac MC, Sasmaz I, et al. Granulocytic sarcoma of gingiva: An unusual case with aleukemic presentation. *J Periodontol* 2003;74:1514-9.
- Dusenbery KE, Howells WB, Arthur DC, et al. Extramedullary leukemia in children with newly diagnosed acute myeloid leukemia. A report from the Children's Cancer Group. *J Pediatr Hematol Oncol* 2003;25:760-8.
- Hiçsonmez G, Çetin M, Yenicesu I, et al. Evaluation of children with myelodysplastic syndrome: Importance of extramedullary disease as a presenting symptom. *Leuk Lymphoma* 2001;42:665-74.
- Şisack MJ, Dunsmore K, Sidhu-Malik N. Granulocytic sarcoma in the absence of myeloid leukemia. *J Am Acad Dermatol* 1997;37:308-11.
- Reinhardt D, Creutzig U. Isolated myelosarcoma in children: Update and review. *Leuk Lymphoma* 2002;43:565-74.
- Todd Jr NW, Bowman CA. Acute myelogenous leukemia presenting as atypical mastoiditis with facial paralysis. *Int J Pediatr Otorhinolaryngol* 1984;7:173-7.
- Çankaya H, Ugras S, Dilek I. Head and neck granulocytic sarcoma with acute myeloid leukemia: three rare cases. *Ear Nose Throat J* 2001;80:224-9.
- Bisschop MM, Revesz T, Bierings M, et al. Extramedullary infiltrates at diagnosis have no prognostic significance in children with acute myeloid leukemia. *Leuk Lymphoma* 2001;15:46-9.
- Almadori G, Del Ninno M, Cadoni G, et al. Facial nerve paralysis in acute otomastoiditis as presenting symptom of FAB M2, T8;21 leukemic relapse. Case report and review of the literature. *Int J Pediatr Otorhinolaryngol* 1996;36:45-52.
- Carmona IT, Teijeiro JC, Dios PD, et al. Intra-alveolar granulocytic sarcoma developing after tooth extraction. *Oral Oncol* 2000;36:491-4.

Copyright of Journal of Dentistry for Children is the property of American Academy of Pediatric Dentistry and its content may not be copied or emailed to multiple sites or posted to a listserv without the copyright holder's express written permission. However, users may print, download, or email articles for individual use.