

Endodontic Treatment of a Multirooted Permanent Maxillary Canine

**Virat Galhotra, BDS (MDS student) I.K. Pandit, BDS, MDS, FPFA
Nikhil Srivastava, BDS, MDS Neeraj Gugnani, BDS, MDS**

ABSTRACT

The purpose of this paper was to report an unusual case of multirooted permanent maxillary canine. A 16-year-old female patient presented with pain and swelling related to the upper right permanent canine. Radiographic examination revealed a multirooted permanent maxillary canine—an unusual finding. Endodontic treatment was performed after amputation of 2 extra roots, and then the tooth was intentionally reimplanted. The prevalence of birooted permanent mandibular canines in the Japanese population has been reported, but the prevalence of this 3-rooted maxillary canine is still unknown. This report also states the potential etiological factors, effects on the developing dentition, and various treatment options for the multirooted maxillary permanent canine. (*J Dent Child* 2007;74:73-5)

KEYWORDS: INTENTIONAL REIMPLANTATION, ENDODONTICS, ROOT AMPUTATION, DENTAL ANOMALY

Dentists come across a number of discrepancies in normal morphology of the teeth in their day-to-day practice. These variations can include teeth with different shapes and sizes of roots or crowns, altered root numbers, and fused or malpositioned teeth.

The specific variation influences the treatment plan and the prognosis of the tooth.

Accessory roots are most frequently seen on maxillary molar teeth and mandibular molars. Multiple roots in the mandibular canine have been reported, but the literature about the presence of multiple roots in any other anterior tooth is scanty. Schulze¹ reported that the frequency of two roots is 2% to 8% in permanent canines. The prevalence of birooted permanent canines in the Japanese population has been reported to be 0.5%,² 0.32%,³ and 0.29%⁴—much lower than the frequency reported by Schulze. Other authors have also reported double-rooted bilateral mandibular canines,^{5,6} but an effort to locate literature reporting more than 2 roots in any of the anterior teeth proved futile.

The purpose of this case report was to present the treat-

ment—including intentional reimplantation and endodontics—of a nonvital, multirooted permanent maxillary canine.

CASE REPORT

A 16-year-old female patient reported to the Postgraduate Department of Pedodontics and Preventive Dentistry, Dayanand Anglo Vedic Centenary Dental College and Hospital, Yamuna-Nagar, Haryana, India. Her chief complaint was pain and palatal swelling related to the upper right anterior region for the last 5 days. The patient had a history of trauma in this region when she was very young. Intraoral examination revealed the presence of a full complement of permanent teeth except for third molars (without caries or periodontal involvement). The tooth in question, which appeared to be the right maxillary canine, was malformed and hypoplastic (Figure 1) with a palatal swelling and was tender to percussion. Malformation and unusual shape and position had led to the creation of a food-retentive, noncleansable area, resulting in food lodgment and local periodontal pocket formation. The maxillary canine tested nonvital, while the adjoining teeth were vital.

Radiographic examination revealed the following:

1. the presence of a multirooted canine giving a faulty picture of a retained root stump of the primary canine; and
2. periapical radiolucency related to the curved distal root extending to the first premolar's root (Figure 2).

The confirmed diagnosis was a case of a nonvital, mal-

Dr. Galhotra is student, Dr. Pandit is professor and head, Dr. Srivastava is associate professor, and Dr. Gugnani is reader, all in the Postgraduate Department of Pedodontics and Preventive Dentistry, Dayanand Anglo Vedic Centenary Dental College and Hospital, Yamuna-Nagar, Haryana, India. Correspond with Dr. Pandit at drpanditynr@rediffmail.com

formed, permanent, multirooted canine—a variant from the normal. Hence, root canal treatment—normally the

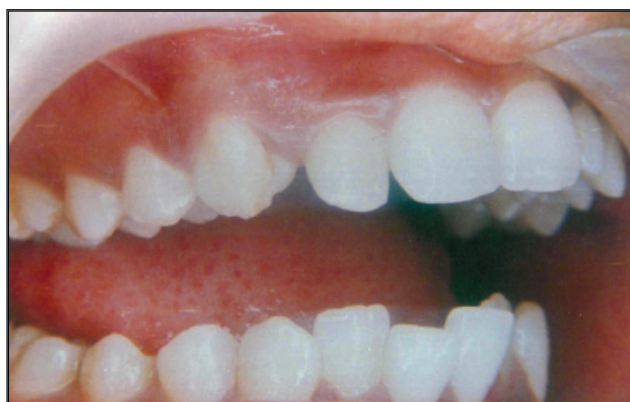

Figure 1. Right maxillary permanent canine to be malformed and hypoplastic.

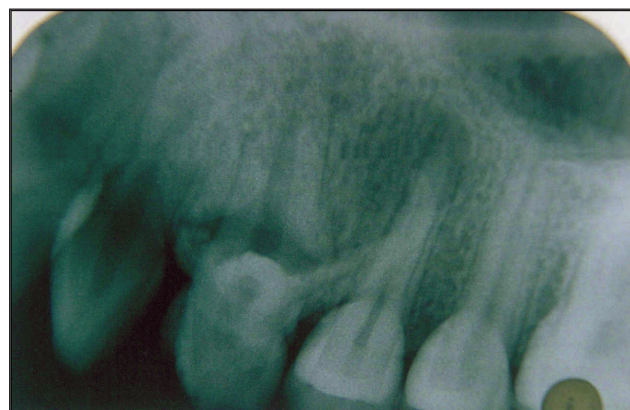


Figure 2. Radiograph of a multirooted canine with periapical radiolucency in relation to the curved distal root extending to the first premolar's root.

treatment of choice—could not be predictably guaranteed due to great variation in the morphology of its roots and their canals. Therefore, to avoid multiple appointments and any further related complications, intentional replan-

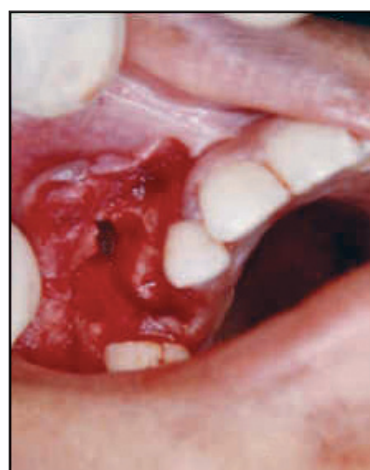

Figure 3. The surgical exposure of the site after tooth extraction.

tation was planned. It was also planned to amputate the additional infected roots.

The required informed consent for the surgical procedures was obtained. The area was anesthetized, surgical exposure of the site was achieved after flap reflection, and, subsequently, the tooth was carefully extracted (Figure 3). Because of the unfavorable curvature of

roots, the distal root was fractured during extraction. The fractured root was removed, and, subsequently, the periapical pathology was curetted using a surgical curette.

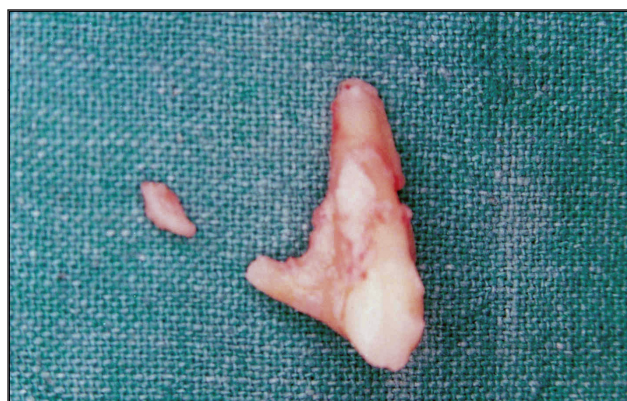

Figure 4. The extracted tooth exhibiting 3 roots.

The extracted tooth exhibited 3 roots (Figure 4). The 2 extra roots were amputated. The tooth was shaped, canals were obturated, and retrograde filling was placed (Figure 5).

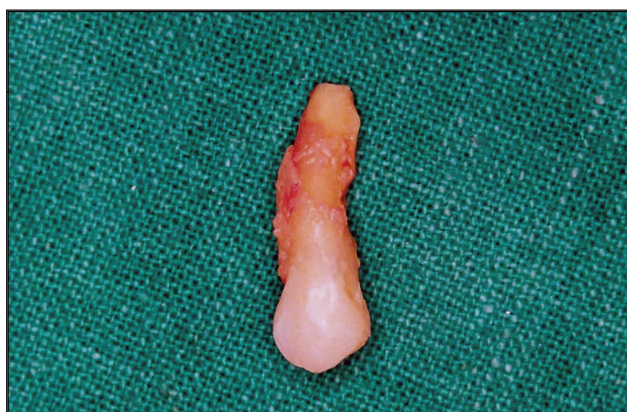


Figure 5. The prepared tooth after extra root amputations.

Utmost care was taken to avoid any damage to the socket and to the periodontal ligament fibers of the extracted tooth during the whole procedure.

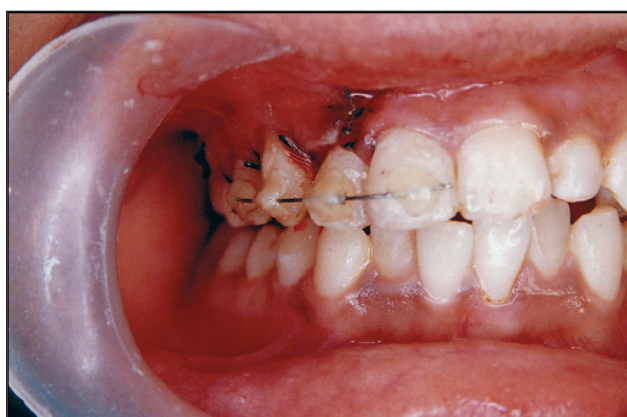


Figure 6. The sutures and placed splint.

The tooth was then replanted and splinted using wire and composite resin splints (Figure 6). Analgesics and antibiotics were prescribed for 5 days, postoperative instructions were given, and the patient was asked to report after 10 days for the splint removal.

After 10 days, the tooth was found clinically and radiographically to be asymptomatic and healthy with an intact periodontal ligament and minimal mobility (Figures 7 and 8). A 6-month follow-up was maintained, and the tooth showed no clinically significant alteration from the baseline picture.

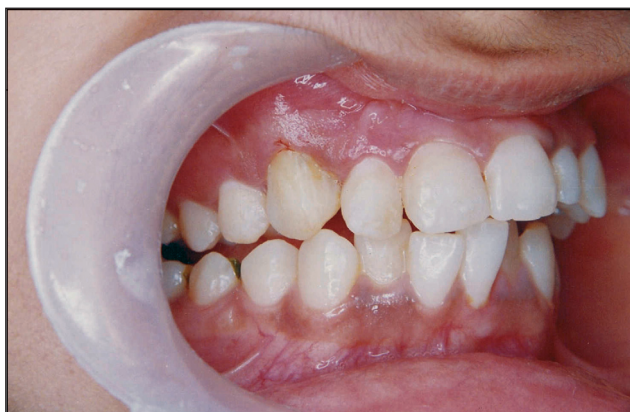

Figure 7. Clinically asymptomatic tooth after 10 days.

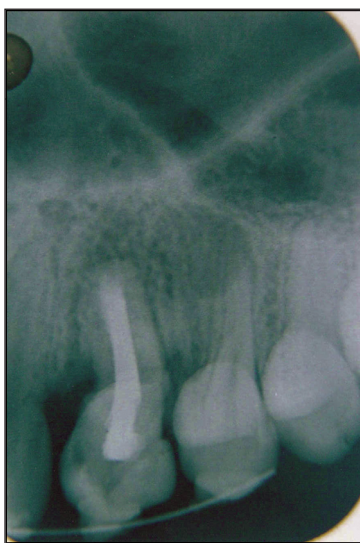


Figure 8. Radiograph of an asymptomatic tooth after 10 days.

DISCUSSION

The development of roots begins after enamel and dentin formation reaches the future cemento-enamel junction (CEJ). Both the inner and outer epithelial layers of the enamel organ join at the area of the future CEJ and give rise to the epithelial root sheath. This epithelial sheath eventually grows into the surrounding mesenchyme and induces root formation.

This process is significantly different in teeth with multiple roots. Before root formation begins, the epithelial root sheath forms horizontal epithelial ledges called epithelial diaphragms. In multirooted teeth, these epithelial diaphragms undergo differential growth, resulting in the root trunk dividing into multiple roots.⁷

The etiology of teeth with supernumerary roots has, so far, not been intensively studied and researched. A defect in the dental lamina at the early stage of root formation could be an etiological factor in multirooted canines.⁸ It is also

possible that an abnormality in the morphodifferentiation of canines might have occurred.⁸

Very few reported cases regarding multiple roots associated with cuspids have been placed on record. Paulson et al reported morphological descriptions of double-rooted maxillary primary canines, which led to the recognition of 3 major primary root types:

1. a single root without trace of a groove;
2. a root with a faint to distinct labial groove; and
3. a root with a broad and deep labial groove in the root's apical portion.⁹

The various treatment options considered were the extraction and prosthetic replacement of the tooth with a bridge, a partial denture, or an implant.

An understanding of anatomic morphology improves the chances of endodontic success, but a detailed study of the anatomy of multirooted permanent canine has not been conducted.¹⁰ Hence, intentional reimplantation with endodontic procedures and shaping of the crown was considered a viable treatment option for the atypical tooth morphology. The long-term prognosis of reimplantation is guarded, and the risks associated include ankylosis, replacement resorption, inflammatory root resorption, and mobility. The 6-month follow-up, however, did not reveal any clinical abnormality.

REFERENCES

1. Schulze C. Developmental abnormalities of teeth and jaws. In: Gorlin RJ, Goldman HM, eds. *Thoma's Oral Pathology*. Vol. 1, 6th ed. St. Louis, Mo: Mosby; 1970:96-183.
2. Fujita K, Kirino T. *Tooth Anatomy*. 21st ed. Tokyo, Japan: Kinbara; 1986:137-66.
3. Okamoto O, Osada J. Double-rooted mandibular permanent canine. *Rinsho Shika* 1951;193:26-8.
4. Imoto H, Fukuya T, Ikeda H, Ikeda H. Thirteen cases of the two-rooted mandibular canines. *Kyushu J Dent Sci* 1975;29:54-61.
5. Harborow G. The two-rooted mandibular canine. *Br Dent J* 1934;56:244-6.
6. Sunaga T. Double-rooted bilateral mandibular permanent canines. *Shika Gaku Zashi* 1944;1:169-72.
7. Milano M, Chavarria C, Hoppe J. Multirooted mandibular premolars: Report of a case. *J Dent Child* 2002;69:63-5.
8. Mochizuki K, Ohtawa Y, Kubo S, Machida Y, Yakushiji M. Bifurcation, birooted primary canines: A case report. *Int J Paediatr Dent* 2001;11:380-5.
9. Paulson RB, Gottlieb LJ, Sciulli PW, Schneider KN. Double-rooted maxillary primary canines. *J Dent Child* 1985;52:195-8.
10. Sharma R, Pecora JD, Lumley PJ, Walmsley AD. The external and internal anatomy of human mandibular canine teeth with two roots. *Endod Dent Traumatol* 1998;14:88-92.

Copyright of Journal of Dentistry for Children is the property of American Academy of Pediatric Dentistry and its content may not be copied or emailed to multiple sites or posted to a listserv without the copyright holder's express written permission. However, users may print, download, or email articles for individual use.