

Pulpal and Periapical Response of Dogs' Teeth after Pulpotomy and use of Recombinant Human Bone Morphogenetic Protein-7 as a Capping Agent

Léa Assed Bezerra da Silva, DDS, MSc, PhD

Francisco Wanderley Garcia de Paula e Silva, DDS, MSc

Mário Roberto Leonardo, DDS, MSc, PhD Sada Assed, DDS, MSc, PhD

ABSTRACT

Objective: The purpose of this study was to evaluate the pulpal and periapical response of dogs' teeth after pulpotomy and the use of recombinant human bone morphogenetic protein-7 as a capping agent.

Methods: Pulpotomy was performed in 60 teeth from 6 dogs, and the remaining pulp tissue was capped with the following materials: (a) groups 1 and 5: recombinant human bone morphogenetic protein-7 associated with recombinant human-like collagen; (b) groups 2 and 6: recombinant human-like collagen; (c) groups 3 and 7: calcium hydroxide; and (d) groups 4 and 8: zinc oxide and eugenol cement. After 7 days (groups 1-4) and 70 days (groups 5-8), the animals were sacrificed and the pieces containing the teeth were removed and processed for histological analysis.

Results: *Seven-day period:* according to the type of inflammatory infiltrate observed in the root pulp tissue: (a) groups 1 and 2 were classified as severe with intense vascular proliferation; (b) group 4 was classified as moderate; and (c) group 3 was classified as mild. No dentin bridge formation was observed in any specimen, and the periapical region had normal appearance. *70-day period:* groups 5, 6, and 8 showed no dentin bridge formation, and the remaining pulp tissue presented necrotic areas with inflammatory cells in the periapical region as well as bone and cemental resorption. In group 7, there was dentin bridge formation, absence of inflammation, and absence of mineralized tissue resorption.

Conclusion: The use of rHuBMP-7/rHuCollagen as a capping material after pulpotomy did not show either satisfactory apical and periapical response or capacity of inducing deposition of mineralized tissue. (J Dent Child 2007;74:79-84)

KEYWORDS: PULPOTOMY, RECOMBINANT HUMAN BONE MORPHOGENETIC PROTEIN-7, RECOMBINANT HUMAN-LIKE COLLAGEN, CALCIUM HYDROXIDE, ZINC OXIDE AND EUGENOL CEMENT

Pulpotomy is a conservative endodontic procedure that consists of amputation of the coronal pulp and protection of the vital root pulp tissue with a capping material to preserve its vitality and integrity and stimulate the deposition of reparative mineralized tissue.¹

Compared to other endodontic procedures, pulpotomy is considered a low-cost, definitive technique and has nearly a 96% success rate for both primary and permanent teeth.²⁻⁴

For several years, Ca(OH)₂ (calcium hydroxide) has been the most widely accepted capping material for pulpotomy.

Dr. da Silva and Dr. Assed are chair professors, Dr. Silva is post doctoral student, and Dr. Leonardo is visiting professor, all in the Department of Pediatric Clinics, Preventive and Social Dentistry, School of Dentistry of Ribeirão Preto, University of São Paulo, Ribeirão Preto, São Paulo, Brazil. Correspond with Dr. Silva at fwsilv58@estadao.com.br

This is due to its excellent biological properties, such as the capacity of inducing the formation of a mineralized tissue barrier when placed in contact with the exposed pulp tissue and its antimicrobial activity.^{5,6} Over the last decades, however, in vitro and in vivo studies have investigated other materials that would be capable of providing pulp tissue healing in cases of pathological and accidental exposure, including:

1. mineral trioxide aggregate (MTA)^{4,7};
2. bioactive glasses⁷;
3. freeze-dried cortical bone⁸;
4. hydroxyapatite⁹;
5. transforming growth factor-beta (TGF-beta)^{9,10};
6. collagen⁶;
7. enamel matrix derivatives¹¹; and
8. bone morphogenetic proteins.¹²⁻²²

Bone morphogenetic proteins (BMPs) comprise the largest subfamily of TGF-beta and belong to a group of noncollagen proteins. The BMPs are widely distributed in mineralized and nonmineralized tissues and play an important role during embryogenesis.²²⁻²⁴ They are responsible for several biological activities involving tissue morphogenesis, regeneration, healing and cell differentiation processes.^{24,25} When applied directly to the pulp tissue, the BMPs dissolve in the tissue fluids within 2 weeks, thus stimulating the mitosis of mesenchymal cells and cell differentiation.¹¹ BMP target-cells in the pulp tissue are undifferentiated mesenchymal cells,^{22,25,26} which present BMP-specific surface receptors to which BMP bind and initiate a cascade of cellular and biological events that culminate in cell differentiation and production of reparative dentin.²³⁻²⁶

Nevertheless, to exert its biological function, BMP should be associated with a proper carrier because it is highly soluble if used alone and disperses immediately after grafting.^{14,22,23} Due to its important characteristics, such as ease of handling and hemostatic property, collagen has been used as the carrier agent of choice and promotes a controlled release of BMPs.^{15,16,18,24,27}

Therefore, the purpose of this study was to evaluate histologically the pulpal and periapical response of dogs' teeth after pulpotomy and use of recombinant human bone morphogenetic protein-7 associated with recombinant human-like collagen as a capping agent.

METHODS

PREPARATION OF RECOMBINANT HUMAN BONE MORPHOGENETIC PROTEIN ASSOCIATED WITH RECOMBINANT HUMAN-LIKE COLLAGEN

Under aseptic conditions, recombinant human bone morphogenetic protein-7 (rHuBMP-7; recombinant human bone morphogenetic protein 7; ProSpec Tany TechnoGene Ltd, Rehovot, Israel, batch no. 605BMP01) and recombinant human-like collagen (rHuCollagen; recombinant human like collagen; ProSpec Tany TechnoGene Ltd, no. 605COL01) were solubilized in pyrogen-free water (Milli-Q Ultrapure Water Purification; Millipore Corporate Headquarters, Billerica, Mass) and mixed to obtain a solution at a concentration of 2.5 µg rHuBMP-7/mg rHuCollagen. The material was:

1. lyophilized (Speed Vac SC 100; Savant Instruments, Inc, Ramsey, Minn) at 25°C for 2 hours; 2. sterilized with ethylene oxide; and 3. stored at -20°C until use.

OPERATIVE PROCEDURES

The experimental protocol was conducted in compliance with the specifications of the Animal Experimentation Ethics Committee of the University of São Paulo, São Paulo, Brazil.

The second, third, and fourth mandibular premolars and the second and third maxillary premolars of 6 12-month-old male and female dogs of undefined breed, coming from the same litter and weighing 8-10 kg, were selected for this study. A total of 60 teeth (120 roots) were assigned to 8 groups, as described in Table 1.

The animals were anesthetized intravenously with 3% sodium thiopental (Thionembutal, Abbot Laboratories, Rio de Janeiro, Brazil; 30 mg/kg body weight). Supplementary anesthesia was provided when required. Throughout the duration of the procedures, the animals were maintained with isotonic saline with the addition of 2.5% glucose (Glicolabor Indústria Farmacêutica Ltda, Ribeirão Preto, São Paulo, Brazil).

After placement of a rubber dam and disinfection with 3% hydrogen peroxide and 2% chlorhexidine digluconate, coronal access

Table 1. Groups, Tested Materials, Number of Teeth Per Group and Experimental Periods

Group	Material	No. of teeth/roots	Experimental period (days)
1	Recombinant human bone morphogenetic protein-7 plus recombinant human-like collagen	10/20	7
2	Recombinant human-like collagen	10/20	7
3	Ca(OH) ₂ (negative control)	5/10	7
4	Zinc oxide and eugenol cement (positive control)	5/10	7
5	Recombinant human bone morphogenetic protein-7 plus recombinant human-like collagen	10/20	70
6	Recombinant human-like collagen	10/20	70
7	Ca(OH) ₂ (negative control)	5/10	70
8	Zinc oxide and eugenol cement (positive control)	5/10	70

was performed using air-/water-cooled, high-speed no. 1015 diamond burs (KG Sorensen Indústria e Comércio, São Paulo, Brazil). The burs were replaced every 4 cavity preparations to ensure cutting efficiency and avoid overheating. The pulp chamber was irrigated with sterile saline, and the coronal pulp was amputated at the level of the root canal entrances using sharp curettes. Hemostasis was obtained by copious irrigation of the pulp chamber with saline.

All experimental groups were tested in the same animal and were performed in alternate quadrants in a change-over system distributed at random. The materials were prepared according to the manufacturer's instructions.

The following materials were used as capping agents:

- a. groups 1 and 5: 3 mg rHuBMP-7 /rHuCollagen (2.5 µg rHuBMP-7/mg rHuCollagen) mixed with 0.5 mL saline;
- b. groups 2 and 6: 3 mg rHuCollagen mixed with 0.5 mL saline;
- c. groups 3 and 7: 0.5 g Ca(OH)₂ pro analysis (chemically pure). (Calcium Hidroxide zur Analyse, Merck, Darmstadt, Germany) mixed with 0.5 mL saline;
- d. groups 4 and 8: zinc oxide (ZnO) and eugenol cement (IRM, Dentsply Indústria e Comércio Ltda, Petrópolis, Rio de Janeiro, Brazil; 1 g ZnO mixed with 1 drop eugenol).

In all groups, the pulp-capping material was covered with a commercial Ca(OH)₂ cement layer (Dycal, Dentsply Indústria e Comércio Ltda) and the access cavity was restored with resin-modified glass ionomer cement (Vitremer, 3M/ESPE, St. Paul, Minn).

The dogs were sacrificed by anesthetic overdose 7 days (groups 1-4) and 70 days (groups 5-8) after pulpotomy. The maxillas and mandibles were removed, and the anatomic pieces containing the teeth were sectioned using water-cooled diamond disks.

HISTOLOGICAL PROCESSING

The pieces were fixed in buffered 10% formalin for 72 hours at room temperature and demineralized in an EDTA-based solution activated in a microwave oven (Sharp Carousel, São Paulo, Brazil).

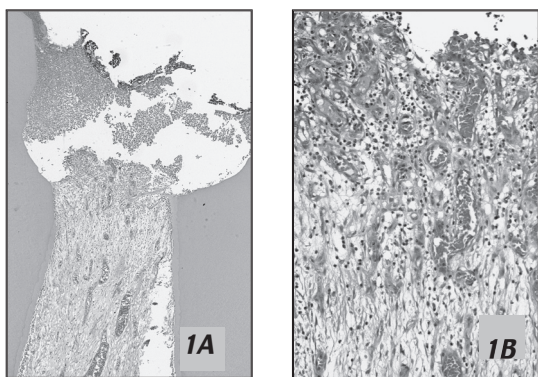
After demineralization, the pieces were:

1. neutralized in 5% sodium sulfate (JT Baker, Xalostoc, Mexico);
2. washed in running water for 24 hours;
3. dehydrated in ascending ethanol grades;
4. cleared in xylol; and
5. embedded in paraffin, according to the standard processing.

The blocks were serially sectioned, and 5- μ m-thick longitudinal cuts were obtained and stained with hematoxylin and eosin (HE), Mallory's Trichrome and Brown and Brenn staining technique for histological analysis under optical microscopy by only one blind examiner.

RESULTS

GROUP 1 (7 DAYS) – rHuBMP-7/rHuCollagen (FIGURES 1A AND 1B)



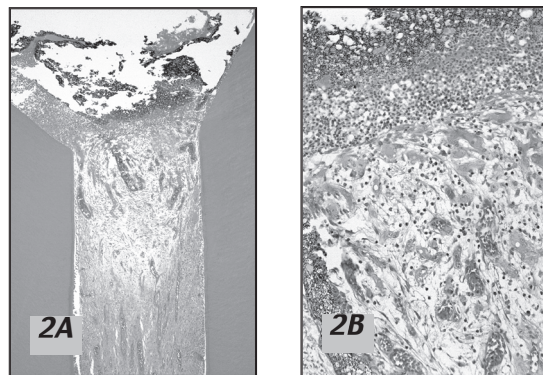
The histological analysis of the remaining root pulp tissue 7 days after pulpotomy showed that the capping material was partially resorbed. A severe mixed inflammatory infiltrate—composed of neutrophils, macrophages, and lymphocytes associated with interstitial edema—was observed close to the remnants of pulp-capping material. Adjacent to this inflammatory process at a farther site, there was vascular proliferation and congestion in the pulp tissue, fibril dissociation, and moderate presence of inflammatory cells with loss of considerable amount of matrix.

No dentin bridge formation was observed in any of the specimens. There was intense angioblastic proliferation with a more consistent matrix, in spite of reduced cell population close to the middle third and extending towards the apical third. At the root apex, most canals of the apical delta were widened and presented a reduced cell population. Close to the apex, the cemental surface was regular presenting cementoblasts throughout its extension in addition to fibers and absence of resorption areas. The periodontal ligament was intact. There were no areas of alveolar bone resorption, and a large number of osteoblasts was observed. Presence of bacteria was not detected in any specimen.

GROUP 2 (7 DAYS)—rHuCollagen (FIGURES 2A AND 2B)

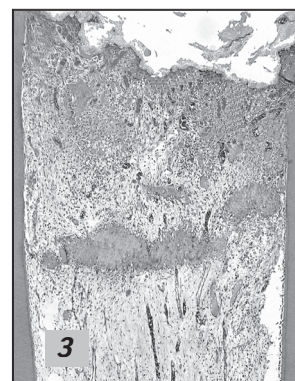
In this group, the pulp-capping material was partially resorbed and the pulp tissue indicated: (1) signs of severe inflammation; (2) presence of a mixed, predominantly mononuclear inflammatory infiltrate; (3) intense fibril dissociation; (4) small cell population;

and (5) absence of dentin bridge formation. At the middle third, farther from the capping material, there was: (1) vascular proliferation and congestion; (2) intense hemorrhage with leakage of red blood cells; and (3) areas of necrosis. The canals of the apical delta were widened and, in many cases, filled with hemorrhagic cells. There were no resorption areas on the apical cementum surface, which was regular, in spite of the small cementoblastic population. Periodontal ligament thickness was slightly increased with small hemorrhagic spots. The alveolar bone was intact. Presence of bacteria was not detected in any specimen.



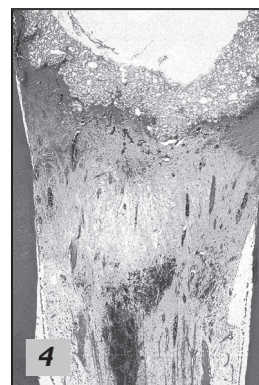GROUP 3 (7 DAYS)—Ca(OH)₂ (FIGURE 3)

Seven days after pulpotomy, no dentin bridge formation was observed close to the Ca(OH)₂ capping in any specimen. Pulp tissue adjacent to the material presented a slight mononuclear inflammatory infiltrate and slightly increased number of vessels. The radicular pulp tissue and the odontoblastic layer were intact as well as the apical and periapical regions. There were no inflammatory cells in the periodontal ligament, but intense presence of cells and fibers were observed originating from the cementum and attaching to the alveolar bone within a dense and vascularized connective tissue. No bacteria were observed in any of this group's specimens.

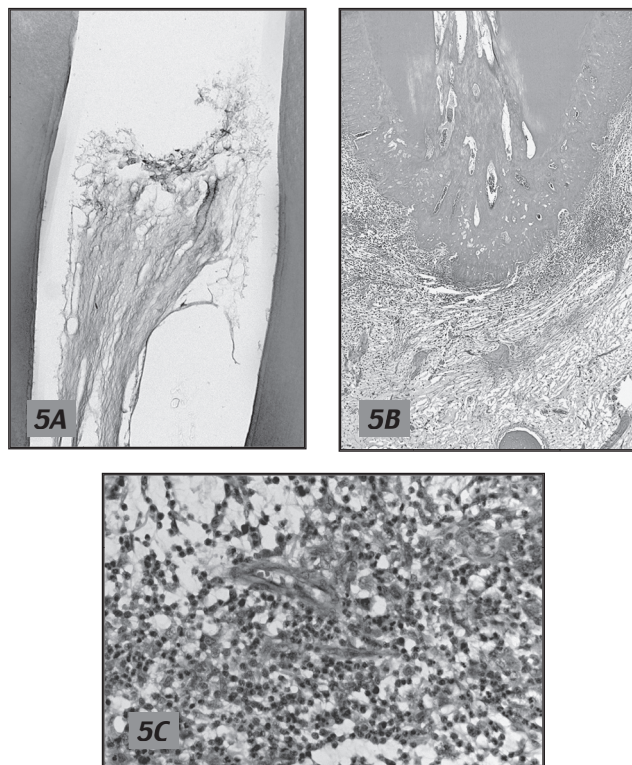


GROUP 4 (7 DAYS)—ZnO AND EUGENOL CEMENT (FIGURE 4)

Pulp tissue close to the material presented a concentrated mixed inflammatory cell infiltrate with few areas of edema. Radicular pulp tissue presented congested vessels and accentuated vessel proliferation. At the root apex, the canals of the delta were widened and filled with intact connective tissue. There were no resorption areas on the cementum surface. The periodontal ligament showed a large number of collagen fibers and intense angioblastic proliferation. Alveolar bone was intact and no bacteria were detected.



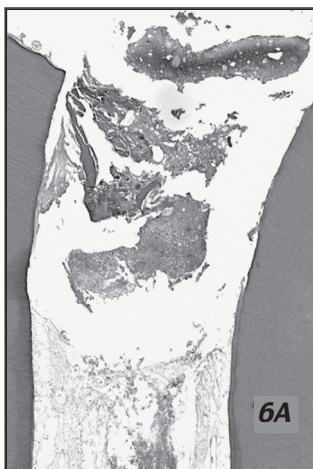
GROUP 5 (70 DAYS)-rHuBMP-7/rHuCollagen (FIGURES 5A, 5B, AND 5C)



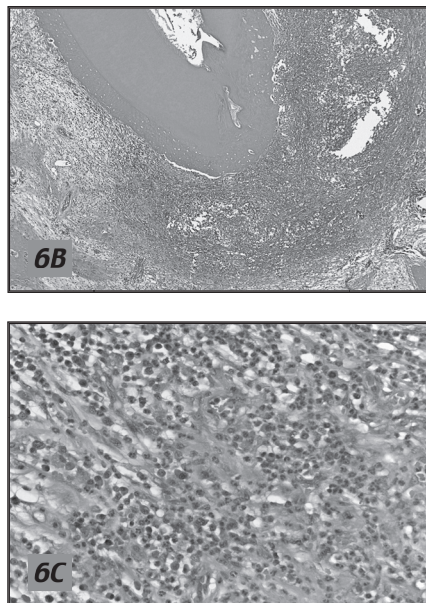
No dentin bridge formation was observed in any of this group's specimens. The odontoblastic layer was not present along the dentin walls. In all specimens, pulp remnant at the cervical and middle thirds was necrotic and surrounded by inflammatory cells. The cementum surface was irregular due to the resorption areas that formed lacunae, some of which containing clast cells. In the periodontal ligament, mononuclear and polymorphonuclear inflammatory cells were present. They were more concentrated close to the root apex, forming one or more foci. There was generalized edema, and scarcity of cells were noted. The alveolar bone showed nonrepaired areas, which created an accentuated enlargement of the periodontal space. No bacteria were found in any specimen.

GROUP 6 (70 DAYS)-rHuCollagen (FIGURES 6A, 6B, AND 6C)

Seventy days after pulpotomy and capping with rHuCollagen, there were no dentin bridge formation in any of this group's specimens. Close to the capping material, pulp remnants were disintegrated or absent. If present at the middle and apical thirds, the pulp tissue presented: (1) extensive necrotic areas; (2) fibril dissociation; and (3) almost total absence of cells. At the root apex, there were nonrepaired resorption areas on the cemental surface, which was irregular with no cementoblasts. In the periodontal ligament, inflammatory cells were frequently



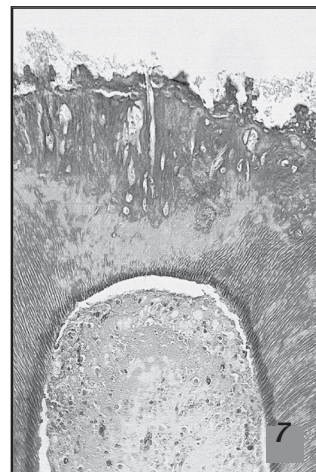
observed, forming one or more dense mixed foci accompanied by abscess formation in most cases. Fibril dissociation and edema were observed throughout the periapical region. Periodontal space was enlarged due to the extensively resorbed and nonrepaired alveolar bone tissue. Presence of bacteria was not detected in any specimen.



GROUP 7 (70 DAYS)-Ca(OH)₂ (FIGURE 7)

In this group, the response pattern observed was the presence of dentin bridges of different thicknesses, sometimes thinner and sometimes thicker, which completely obliterated the pulp exposure area. Along all dentin extension, the odontoblastic layer was within the normal standards. The apical and periapical regions were intact. The connective tissue was also intact and presented a considerable fibroblastic and collagen fiber population. The apical cementum surface was regular and contained a large number of cementoblasts. The periodontal ligament presented dense connective tissue absence of inflammatory cells and a large number of collagen fibers disposed perpendicular to the cemental surface.

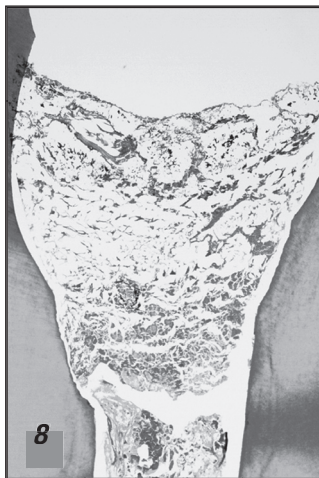The alveolar bone did not present areas of resorption, and a large number of osteoblasts was observed on its surface. No bacteria were observed in this group.



GROUP 8 (70 DAYS)-ZnO AND EUGENOL CEMENT (FIGURE 8)

In this group, the formation of a mineralized tissue bridge was not observed in any specimen. The pulp tissue was inflamed with a moderate number of mononuclear inflammatory cells in all roots. The presence of polymorphonuclear inflammatory cells, however, was discrete. Areas of fibril dissociation were frequently observed all over the extension of the radicular pulp tissue, together with

edema and areas of necrosis. Apical cementum surface presented nonrepaired resorption areas. The apical foramina were widened and contained inflamed tissue remnants. The periodontal ligament thickness was increased with the presence of moderate inflammatory infiltrate and generalized edema. The alveolar bone was resorbed and not repaired. No bacteria were detected in this group.



DISCUSSION

A dog model was chosen for this study because this is the most widely used experimental model in biological research. It has been shown that the pulpal, apical and periapical healing process in dogs is similar to that in humans.^{6,12,14}

The first studies with bone morphogenetic proteins used materials extracted from animal bone tissues.^{12,17,23} Despite the good results, there has been great concern regarding the risks of disease transmission and immunological rejection when products of animal origin are employed.²⁸ Recent advances in molecular and cellular biology have allowed obtaining pure proteins by use recombinant DNA techniques. In spite of the current technology, collagen of animal origin has still been used as a carrier agent. Therefore, the purpose of this study was to evaluate the pulpal and periapical response of dogs' teeth after pulpotomy and capping of pulp remnant with rHuBMP-7 associated with rHuCollagen. Both materials were obtained by recombinant DNA techniques (ie, a pure protein-carrier combination).

It has been shown that bone morphogenetic proteins are capable of inducing the formation of a dentin bridge after direct pulp capping^{15,16,18} or pulpotomy.^{12,14,19,23} In the 7-day experimental period of this study, however, the pulp tissue presented signs of severe inflammation. In the 70-day period, in the absence of bacteria (confirmed by Brown and Brenn staining method), pulp necrosis and lack of dentin bridge formation occurred in all specimens treated with this material. These findings do not agree with those reported by Nakashima (1990),¹² who observed presence of dentin bridges 8 weeks after pulpotomy and the use of bone morphogenetic proteins. Similar results were obtained by other authors.^{14,15,17-19,21,23}

The differences of the present study's findings compared to other investigations might be related to the type of carrier used (ie, rHuCollagen) which may have influenced rHuBMP-7 biocompatibility. When collagen was used alone as a pulp-capping material (groups 2 and 6), the remaining root pulp tissue showed a severe inflammatory response in the 7-day experimental period

and extensive necrotic areas, fibril dissociation, and almost total absence of cells in the 70-day experimental period.

On the other hand, in all specimens of the Ca(OH)₂ groups (3 and 7), there was mild inflammatory infiltrate in the pulp tissue in the 7-day experimental period and formation of dentin bridge obliterating the pulp exposure in the 70-day period.

These findings are consistent with those of previous studies that used Ca(OH)₂ as a capping material after pulpotomy and also had results within the standard of normality.^{5,6,18,21} Ca(OH)₂ was the first agent used in pulpotomies that demonstrated capacity to induce dentin regeneration.²⁹ Besides the fact that some authors believe that Ca(OH)₂ leads to internal resorption, this was not observed histologically in this study. The authors agree with the studies that attribute the bad results of pulpotomy in primary teeth to the technique used and the quality of the final restoration.³⁰⁻³²

Regarding the ZnO and eugenol cement, there was absence of: (1) dentin bridge formation; (2) inflammatory infiltrate in the pulp tissue; (3) increased thickness of the periodontal ligament; (4) bone resorption; and (5) cemental resorption. These findings agree with those of previous investigations.^{6,8}

According to the methodology employed in this study and based on the results of the histological analysis, it may be concluded that the use of recombinant human bone morphogenetic protein-7 associated with recombinant human-like collagen for covering the radicular pulp remnant after pulpotomy did not show either satisfactory apical and periapical response or capacity of inducing mineralized tissue deposition.

ACKNOWLEDGMENTS

The authors wish to thank Fundação de Amparo à Pesquisa do Estado de São Paulo (Foundation of Support for Research in the State of São Paulo) for financial support.

REFERENCES

1. American Academy of Pediatric Dentistry. Reference Manual 2000-01. Guidelines for pulp therapy for primary and young permanent teeth. *Pediatr Dent* 2000;22:67-70.
2. Assed S, Leonardo MR, Silva LAB, Nelson-Filho P, Pinto DMG. Calcium hydroxide pulpotomy in young permanent teeth with periapical involvement. *Braz Endod J* 1997;2:38-42.
3. Rangel SR, Leonardo MR, Silva LAB, Assed S, Nelson-Filho P. Evaluación clínica y radiográfica de dientes deciduos sometidos a la técnica de pulpotomía con hidróxido de calcio. *Vida y Salud* 1998;5:18-21.
4. Holan G, Eidelman E, Fuks AB. Long-term evaluation of pulpotomy in primary molars using mineral trioxide aggregate or formocresol. *Pediatr Dent* 2005;27:129-36.
5. Nosrat IV, Nosrat CA. Reparative hard tissue formation following calcium hydroxide application after partial pulpotomy in cariously exposed pulps of permanent teeth. *Int Endod J* 1998;31:221-6.
6. Silva LAB, Leonardo MR, Nelson-Filho P, Medeiros AS, Rossi MA. Pulp response of anionic lyophilized collagen matrix with or without hydroxyapatite after pulpotomy in dog's teeth. *Mater Res* 2006;9:175-80.
7. Salako N, Joseph B, Ritwik P, Salonen J, John P, Junaid TA. Comparison of bioactive glass, mineral trioxide aggregate, ferric sulfate, and formocresol as pulpotomy agents in rat molar. *Dent Traumatol* 2003;19:314-20.

8. Fadavi S, Anderson AW. A comparison of the pulpal response to freeze-dried bone, calcium hydroxide, and zinc oxide-eugenol in primary teeth in two cynomolgus monkeys. *Pediatr Dent* 1996;18:52-6.
9. Tziafas D, Belibasakis G, Veis A, Papadimitriou S. Dentin regeneration in vital pulp therapy: Design principles. *Adv Dent Res* 2001;15:96-100.
10. Hu CC, Zhavg C, Qian G, Tatum N. Reparative dentin formation in rat molars after direct pulp capping with growth factors. *J Endod* 1998;24:744-51.
11. Olsson H, Davies JR, Holst KE, Schröder U, Petersson K. Dental pulp capping: Effect of Emdogain Gel on experimentally exposed human pulps. *Int Endod J* 2005;38:186-94.
12. Nakashima M. The induction of reparative dentine in the amputated dental pulp of the dog by bone morphogenetic protein. *Arch Oral Biol* 1990;35:493-7.
13. Nakashima M. Mitogenic and dentin-induction effects of crude bone morphogenetic protein from bone and dentin in primary adult pulp cell culture. *Oral Surg Oral Med Oral Pathol* 1992;73:484-9.
14. Nakashima M. Induction of dentin formation on canine amputated pulp by recombinant human bone morphogenetic protein (BMP)-2 and -4. *J Dent Res* 1994;73:1515-22.
15. Rutherford RB, Wahle J, Tucker M, Rueger D, Charette M. Induction of reparative dentine formation in monkeys by recombinant human osteogenic protein-1. *Arch Oral Biol* 1993;38:571-6.
16. Rutherford RB, Spangberg L, Tucker M, Rueger D, Charette M. The time-course of the induction of reparative dentine formation in monkeys by recombinant human osteogenic protein-1. *Arch Oral Biol* 1994;39:833-8.
17. Gao Y, Fang R, Suwa F, Yoshida S, Yang L, Tanaka A. Induction of reparative dentin formation in dogs by bovine bone morphogenetic protein bound to ceramic dentin. *J Osaka Dent Univ* 1995;29:29-38.
18. Jepsen S, Albers HK, Fleiner B, Tucker M, Rueger D. Recombinant human osteogenic protein-1 induces dentin formation: An experimental study in miniature swine. *J Endod* 1997;23:378-82.
19. Rutherford RB, Gu K. Treatment of inflamed ferret dental pulps with recombinant bone morphogenetic protein-7. *Eur J Oral Sci* 2000;108:202-6.
20. Rutherford RB. BMP-7 gene transfer to inflamed ferret dental pulps. *Eur J Oral Sci* 2001;109:422-4.
21. Six N, Lasfargues JJ, Goldberg M. Differential repair responses in the coronal and radicular areas of the exposed rat molar pulp induced by recombinant human bone morphogenetic protein 7 (osteogenic protein 1). *Arch Oral Biol* 2002;47:177-87.
22. Nakashima M. Bone morphogenetic proteins in dentin regeneration for potential use in endodontic therapy. *Cytokine Growth Factor Rev* 2005;16:369-76.
23. Lianja Y, Yuhao G, White FH. Bovine bone morphogenetic protein-induced dentinogenesis. *Clin Orthop Relat Res* 1993;295:305-12.
24. Nakashima M, Reddi AH. The application of bone morphogenetic proteins to dental tissue engineering. *Nat Biotechnol* 2003;21:1025-32.
25. Iohara K, Nakashima M, Ito M, Ishikawa M, Nakashima A, Akamine A. Dentin regeneration by dental pulp stem cell therapy with recombinant human bone morphogenetic protein 2. *J Dent Res* 2004;83:590-5.
26. Saito T, Ogawa M, Hata Y, Bessho K. Acceleration effect of human recombinant bone morphogenetic protein-2 on differentiation of human pulp cells into odontoblasts. *J Endod* 2004;30:205-8.
27. Geiger M, Li RH, Friess W. Collagen sponges for bone regeneration with rhBMP-2. *Adv Drug Deliv Rev* 2003;55:1613-29.
28. Hu K, Lv Q, Cui FZ, Feng QL, Kong XD. Biocompatible fibrin blended films with recombinant human-like collagen for hepatic tissue engineering. *J Bioact Compat Polym* 2006;21:23-37.
29. Zander HA. Reaction of the pulp to calcium hydroxide. *J Dent Res* 1939;18:373-9.
30. Granath LE, Hagman G. Experimental pulpotomy in human bicuspid with reference to cutting technique. *Acta Odontol Scand* 1971;29:155-63.
31. Gruythuysen RJ, Smits MF. Polycarboxylate cement as a cavity-sealing material for the calcium hydroxide pulpotomy: A retrospective study. *J Dent Child* 1995;62:22-4.
32. Gruythuysen RJ, Weerheijm KL. Calcium hydroxide pulpotomy with a light-cured cavity-sealing material after two years. *J Dent Child* 1997;64:251-3.

Copyright of Journal of Dentistry for Children is the property of American Academy of Pediatric Dentistry and its content may not be copied or emailed to multiple sites or posted to a listserv without the copyright holder's express written permission. However, users may print, download, or email articles for individual use.