

Kabuki Syndrome With Additional Dental Findings: A Case Report

Dilsah Cogulu, DDS, PhD

Elif Celen, DDS

Ozant Oncag, DDS, PhD

Ferda Ozkinay, MD

ABSTRACT

Kabuki Syndrome (KS) is a multiple congenital anomalies/mental retardation syndrome of unknown etiology. It is characterized by a dysmorphic face, postnatal growth retardation, skeletal abnormalities, mental retardation, and unusual dermatoglyphic patterns. The characteristic dental findings include hypodontia, microdontia, absence of upper lateral and lower central incisors and upper molars, abnormal tooth shape, widely spaced teeth, ectopic upper molars and malocclusion.

The purpose of this report is to describe common and additional dental findings and dental treatment of an 11-year old female patient with KS. This case report emphasises the importance of oral and dental manifestations for diagnosis. (*J Dent Child* 2008;75:185-7)

Received December 21, 2006; Last Revision February 6, 2007; Revision Accepted February 7, 2007.

KEYWORDS: KABUKI SYNDROME, ORAL MANIFESTATION, TAURODONTISM

Kabuki syndrome (KS), also known as Niikawa-Kuroki syndrome, is a congenital condition characterized by multiple anomalies and usually associated with mild to moderate mental retardation. This syndrome was first described independently by 2 groups from Japan.^{1,2}

The etiology of KS remains unknown. Most cases have been sporadic. In a few families, possible parent-child transmission of the syndrome has been reported. Thus, autosomal dominant inheritance with variable expressivity is suggested.³ More than 350 cases are known in the literature.⁴

KS is characterized by a peculiar facial appearance, mild to moderate mental retardation, postnatal growth retardation, short stature, skeletal anomalies and dermatoglyphic abnormalities, including prominent fingertip pads.⁴ A peculiar face in all cases, characterized by eversion of the lower lateral eyelid, arched eyebrows with a sparse or dispersed lateral one third, depressed nasal tip and prominent ears.⁵⁻⁷

A 92% incidence of skeletal anomalies, including brachydactyly V and spinal deformity with or without sagittal cleft vertebrae has been reported. Dermatoglyphic abnormalities in 93%, including increased digital ulnar loop and hypothenar loop patterns, absence of the digital triradius c and/or d, and presence of fingertip pads, mild to moderate mental retardation in 92%, and postnatal growth deficiency in 83%.⁸

In some cases, KS has been accompanied by critical visceral anomalies of the heart, liver, kidneys, central bronchial airways and diaphragm.⁹

The characteristic dental abnormalities include:

1. hypodontia;
2. microdontia;
3. absence of upper lateral and lower central incisors and upper molars;
4. abnormal tooth shape;
5. widely spaced teeth;
6. ectopic upper molars; and
7. malocclusion.^{5,10}

The increased occurrence of cleft lip and palate or the development of a high palate has been described by a number of authors.^{1,11} Recently, a case with fusion and gemination was also reported.¹² Speech difficulties in KS patients are thought to be associated with poor oral motor coordination and hypodontia.¹³

Dr. Cogulu is a senior assistant, Dr. Oncag is a professor, and Dr. Celen is a research assistant, Department of Pedodontics, School of Dentistry. Dr. Ozkinay is a professor, Department of Medical Genetics, School of Medicine, all at Ege University, Bornova-Izmir, Turkey.

Correspond with Dr. Cogulu at dilsah.cogulu@ege.edu.tr

This case report's purpose was to present common and additional manifestations of a case with Kabuki syndrome and the dental rehabilitation.

CASE DESCRIPTION

An 11-year-old Caucasian female patient was referred to the pediatric dentistry clinic of the School of Dentistry, Ege University, Bornova-Izmir, Turkey, for dental examination with her mother. Extraorally, the patient had long palpebral fissures, eversion of the lower eyelids, large ears, highly arched eyebrows and a flat nasal tip (Figure 1). The other detected abnormalities were mental retardation and skeletal anomalies including spinal deformity with sagittal cleft vertebrae. The patient was born at term with a birthweight of 2,750 g and a birth length of 45 cm to healthy nonconsanguineous parents after uneventful pregnancy with no history of exposure to known teratogens. She was an only child, and her parents were systemically healthy. A heart defect was diagnosed postnatally and required surgery 3 times in the first year of the life. The patient had cleft palate surgery at age 14 months and cardiac surgery for atrial septal defect at age 5. Speech started at 22 months. Chromosomal analysis showed a normal female karyotype 46,XX. She was diagnosed with Kabuki syndrome.

Detected intraoral anomalies were oligodontia, abnormal tooth shape, widely spaced teeth, operated cleft palate and malocclusion. She was in the mixed dentition phase, and some of her teeth were noted to have carious lesions (Figures 2, 3, and 4). Radiographic examination revealed that 10 of her permanent teeth (maxillary second premolars, lateral incisors, mandibular second premolars, lateral and central incisors) were congenitally missing. The panoramic radiograph also showed the root abnormalities of her all permanent premolar teeth; the large pulp chambers gave the appearance of a taurodont molar (Figure 5).

Considering the continuing development of the jaws, carious teeth were restored with composites (3M Filtek Z250, 3M ESPE Dental Products, St. Paul, Minn), whereas the tooth with a poor prognosis (mandibular left first molar) was extracted. Orthodontic and prosthodontic treatments could not be planned because of the mental retardation.



Figure 1. The patient's facial appearance.

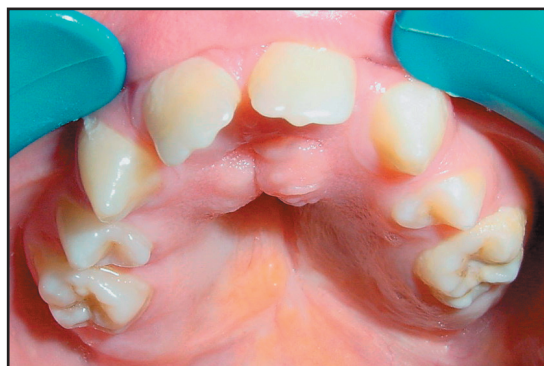

Figure 2. The patient's intraoral appearance revealed the oral and dental abnormalities. Maxilla: Operated cleft palate, absence of lateral incisors, and premolar teeth.

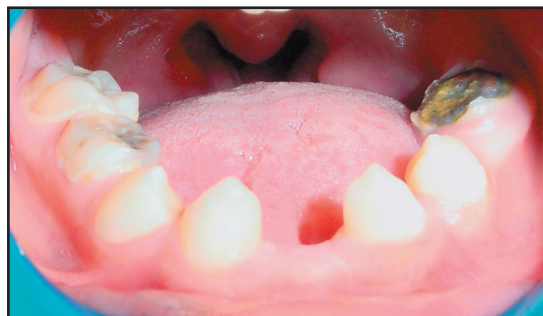

Figure 3. Mandibula: Absence of central and lateral incisors and premolar teeth.

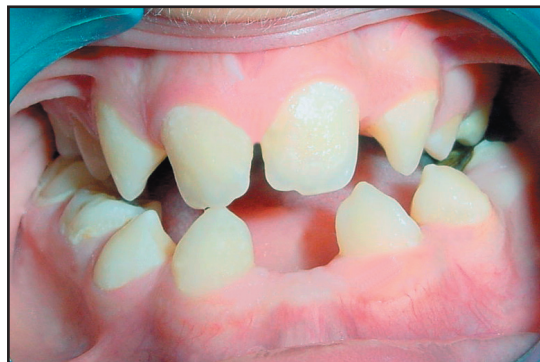

Figure 4. Occlusion: Malocclusion and growth deficiency of the jaws.

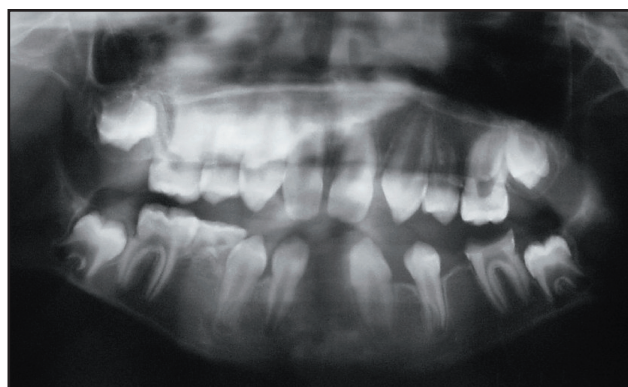


Figure 5. Panoramic radiograph revealed the patient's oligodontia, root abnormalities, and taurodontism in all her premolar teeth.

The patient was given home oral hygiene instructions, and sucrose intake was limited for prevention of caries according to her physician's recommendation. Topical fluoride was applied, and the patient was scheduled for regular fluoride applications every 6 months. Six-month follow-up of the patient revealed good maintenance.

DISCUSSION

Kabuki syndrome is a rare congenital syndrome with distinctive facial features, skeletal anomalies, dermatoglyphic abnormalities, mild to moderate mental retardation, and postnatal growth deficiency.⁵⁻⁸ The clinical diagnosis in the present case is based on the presence of these cardinal manifestations, including long palpebral fissures, eversion of the lower eyelids, large ears, highly arched eyebrows, a flat nasal tip, skeletal anomalies, mental retardation, and cardiac problems.

Oral and dental characteristic manifestations of KS were also reported, such as oligodontia, abnormal tooth shape, widely spaced teeth, high palate and malocclusion.^{5,10} Two additional dental findings, root abnormalities and taurodontism, were also detected on all her premolar teeth. Petzold et al³ also reported a case of KS with 2 immature premolar teeth having an appearance of taurodontism. In the present case, all the patient's permanent premolar teeth have double roots and the large pulp chambers gave the appearance of a taurodont molar. The radiographic findings may extend the spectrum and symptoms associated with KS.

The dental treatment of children with mental retardation and/or with different kinds of syndromes is very difficult. Therefore, this syndrome's additional findings (especially the taurodontism) also emphasize the importance of early diagnosis and conservative dental treatment of KS patients. It should be also emphasized that the existence of congenital cardiac abnormalities in KS patients put them at high risk for bacterial endocarditis. Therefore, administration of an antibiotic regimen for prophylaxis of infections before invasive dental procedures is a highly advisable approach.

It can be assumed that the oral/dental features described will lead to prompt dental referral. When dental professionals are aware of the clinical features, it will contribute to diagnosis, allow referral to a clinical geneticist, encourage investigation of oral/dental findings, and support comprehensive care of the patient. Oral/dental findings seen in KS patients could provide an important clue to understand this syndrome's pathogenesis.

REFERENCES

1. Niikawa N, Matsuura N, Fukushima Y, Ohsawa T, Kajii T. Kabuki make-up syndrome: A syndrome of mental retardation, unusual facies, large and protruding ears, and postnatal growth deficiency. *J Pediatr* 1981;99:565-9.
2. Kuroki Y, Suzuki Y, Chyo H, Hata A, Matsui I. A new malformation syndrome of long palpebral fissures, large ears, depressed nasal tip, and skeletal anomalies associated with postnatal dwarfism and mental retardation. *J Pediatr* 1981;99:570-3.
3. Petzold D, Kratzsch E, Opitz C, Tinschert S. The Kabuki syndrome: Four patients with oral abnormalities. *Eur J Orthod* 2003;25:13-9.
4. Matsumoto N, Niikawa N. Kabuki Make-up Syndrome: A review. *Am J Genet C Semin Med Genet* 2003;117:57-65.
5. Mhanni AA, Cros HG, Chudley AE. Kabuki syndrome: Description of dental findings in 8 patients. *Clin Genet* 1999;56:154-7.
6. Philip N, Meinecke P, David A, et al. Kabuki make-up (Niikawa-Kuroki) syndrome: A study of 16 non-Japanese cases. *Clin Dysmorphol* 1992;1:63-77.
7. Online Mendelian Inheritance in Man, OMIM. Baltimore, Md: Johns Hopkins University. MIM no. 147920. Available at: "<http://www.ncbi.nlm.nih.gov/omim/>".
8. Wessels MW, Brooks AS, Hoogeboom J, Niermeijer MF, Willems PJ. Kabuki syndrome: A review study of 300 patients. *Clin Dysmorphol* 2002;11:95-102.
9. Atar M, Lee W, O'Donnell D. Kabuki syndrome: Oral and general features seen in a 2-year-old Chinese boy. *Int J Paediatr Dent* 2006;16:222-6.
10. Matsune K, Shimizu T, Tohma T, Asada Y, Ohashi H, Maeda T. Craniofacial and dental characteristics of Kabuki syndrome. *Am J Med Genet* 2001;98:185-90.
11. Kawame H, Hannibal MC, Hudgins L, Pagon RA. Phenotypic spectrum and management issues in Kabuki syndrome. *J Pediatr* 1999;134:480-5.
12. Adam MP, Hudgin SL. Kabuki syndrome: a review. *Clin Genet* 2005;67:209-19.
13. Upton S, Stadter CS, Landis P, Wulfsberg EA. Speech characteristics in the Kabuki syndrome. *Am J Med Genet A* 2003;116:338-41.

Copyright of Journal of Dentistry for Children is the property of American Academy of Pediatric Dentistry and its content may not be copied or emailed to multiple sites or posted to a listserv without the copyright holder's express written permission. However, users may print, download, or email articles for individual use.