

Repair of Furcal Perforation Treated With Mineral Trioxide Aggregate in a Primary Molar Tooth: 20-month Follow-up

Thais M. Oliveira, DDS, PhD Vivien T. Sakai, DDS, MSc Thiago C. Silva, DDS
Carlos F. Santos, DDS, PhD Maria Aparecida A. M. Machado, DDS, PhD
Ruy C. C. Abdo, DDS, PhD

ABSTRACT

Furcal perforations may occur during access opening of the pulp chamber or cavity preparation. The perforation can cause an inflammatory reaction in the periodontal ligament. Management of these iatrogenic accidents can pose a significant clinical challenge, mainly when they occur in primary teeth. Current developments in the techniques and materials utilized for root perforation repair have enhanced this procedure's prognosis. Recently, mineral trioxide aggregate (MTA) has been used for several dental purposes. This biocompatible material promotes bone healing and elimination of clinical symptoms. The purpose of this case report was to describe the treatment of a furcal perforation using mineral trioxide aggregate (MTA) in a primary molar tooth. After 20 months, the tooth was asymptomatic. The radiolucent image had disappeared and bone formation at the furcation area had been observed, suggesting healing of the underlying periodontal tissues. Therefore, MTA may be considered an alternative option for the repair of furcal perforation in primary teeth, prolonging the longevity of these dental elements. (*J Dent Child* 2008;75:188-91)

Received July 15, 2006; Last Revision September 21, 2006; Revision Accepted October 27, 2006

KEYWORDS: FURCAL PERFORATION, FURCATION, MINERAL TRIOXIDE AGGREGATE, TOOTH, PRIMARY

Furcal perforations may occur during access opening of the pulp chamber or cavity preparation. The perforation can cause an inflammatory reaction and severely compromise the tooth's prognosis. Such a perforation results in loss of the root's integrity and further destruction of the adjacent periodontal tissues.¹

Recently, mineral trioxide aggregate (MTA) has been used for several dental purposes.²⁻¹¹ MTA is a mineral pow-

der that consists of hydrophilic particles, whose principal components are tricalcium silicate, tricalcium aluminate, tricalcium oxide, and other mineral oxides. It has a pH of 12.5, and sets in the presence of moisture in approximately 4 hours.^{2,3,9} Studies have shown that MTA apparently is equal or superior to other materials concerning dye and bacterial contamination.²⁻⁶ Its benefits include good sealing ability,^{2,3} biocompatibility,²⁻⁶ low cytotoxicity,^{2,3,7} and promotion of odontoblasts to form a hard barrier.^{2,3}

MTA is suggested for root-end filling,^{2,3} pulp capping,⁷ repair of furcal perforations,¹⁰⁻¹⁵ apical filling of teeth with open apices, and apexification therapy.^{3,8} MTA has been proposed as a potential medicament for pulpotomy, and tests in dogs' teeth produced favorable pulp responses.^{8,13} When compared with other materials used for these purposes, similar or better biocompatibility has been reported.^{7,8,16,17}

Dr. Oliveira is postdoctoral fellow and Dr. Santos is associate professor, both at Department of Biological Sciences, University of São Paulo, Bauru, São Paulo, Brazil. Drs. Sakai and Silva are graduate students, Dr. Machado is associate professor, and Dr. Abdo is professor, all Department of Pediatric Dentistry, Orthodontics and Public Health of the Bauru School of Dentistry, University of São Paulo, Bauru, São Paulo, Brazil.

Correspond with Dr. Abdo at r.abdo@fob.usp.br

Perforated roots treated with MTA showed no inflammatory tissue layer and root cementum attached to the MTA.^{10,11,16}

The purpose of this case report was to describe the repair of a furcal perforation, treated with mineral trioxide aggregate in a primary molar tooth, in which underlying periodontal tissue healing could be observed radiographically at the 20-month follow-up.

CASE DESCRIPTION

A 6-year-old boy was referred to our clinic for the management of pain associated with his primary mandibular left second molar. The mother reported that he had experienced pain during feeding and that there was no history of dental trauma. She also reported that another dentist had treated the tooth due to a carious lesion 2 months before this visit.

Clinical examination showed that the primary mandibular left second molar was restored with glass ionomer cement (GIC). A periapical radiographic examination revealed the presence of a pulpotomy and evidence of a circumscribed radiolucent lesion associated with the furcation area. These findings suggested that a perforation with a bur had occurred on the pulp chamber floor during coronal opening for the execution of this pulpotomy (Figure 1).

After a thorough examination, the treatment plan was presented to the patient's parents. Initially, a local anesthetic was administered and the GIC restoration of that tooth was removed. The pulpotomy's material also was removed,

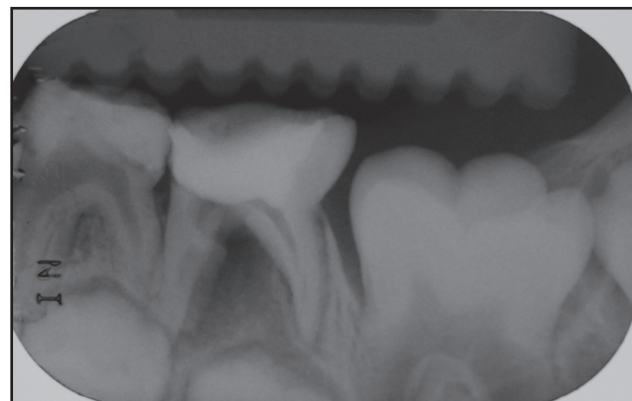


Figure 1. Preoperative radiograph showing the presence of pulpotomy and evidence of a circumscribed radiolucent lesion associated with the furcation area.

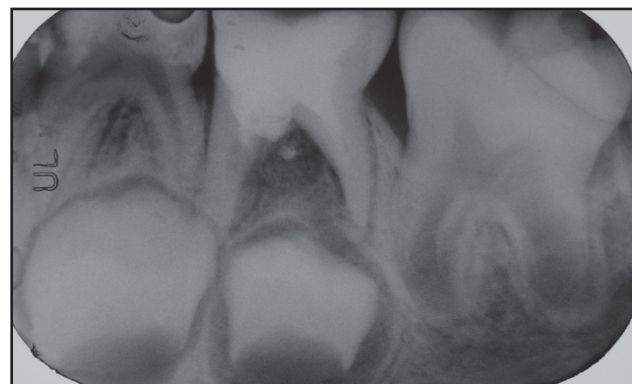


Figure 2. Immediate postoperative radiograph of a tooth with a furcal perforation treated with mineral trioxide aggregate.

and the pulp chamber was cleaned with a saline solution. Controlled bleeding of remaining pulp tissue of the roots was obtained. At this point, bleeding from a perforation was noted, which was also carefully controlled. Then, MTA (Ángelus LTDA, Londrina, Paraná, Brazil) was chosen as the filling material. MTA was mixed with sterile water into a paste consistency and applied into the perforation and pulp chamber with an amalgam carrier. The tooth then was restored with GIC (Figure 2).

At the second appointment, after 7 days, no pain or discomfort was reported. The patient was recalled every 10 months (Figure 3). At the 20-month follow-up, the tooth was asymptomatic. Radiographically, the radiolucent image had disappeared and bone formation at the furcation area had been observed, suggesting the healing of the underlying periodontal tissues (Figure 4).

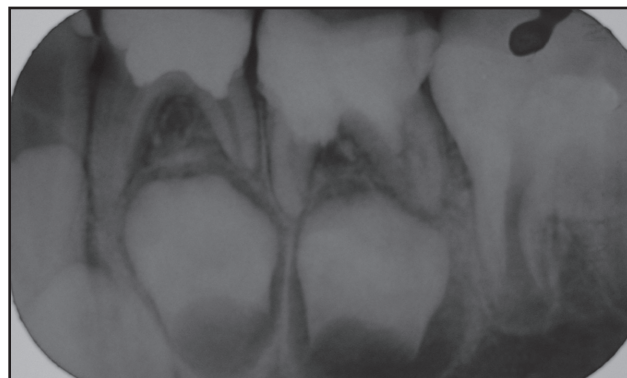


Figure 3. The 10-month follow-up periapical radiograph. Even though the radiographic examination suggested recurrent caries on the primary mandibular left canine and second molar, this was not confirmed clinically.

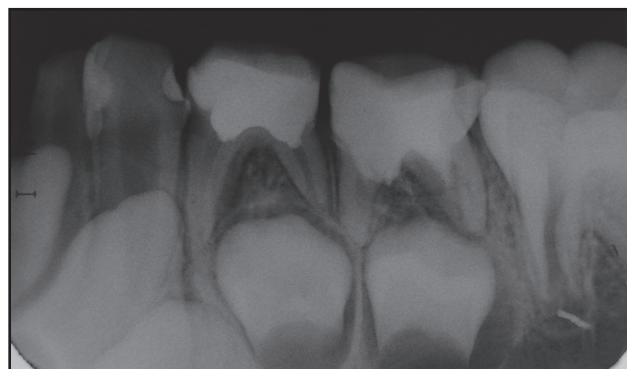

Figure 4. The 20-month follow-up radiograph showing bone formation at the furcation area and suggesting the healing of the underlying periodontal tissues.

DISCUSSION

Furcal perforations adversely affect the prognosis of teeth. Management of these iatrogenic accidents can pose a significant clinical challenge, mainly when they occur in primary teeth. In these cases, the treatment most often performed is the extraction of the perforated teeth. When the normal physiological process of a primary tooth exfoliation and eruption of its successor is disrupted and a space maintainer

appliance is not used, however, several changes in the dental arches may be observed. These can include reduction in arch length, inclination of adjacent teeth, extrusion of an antagonist tooth, and accelerated or delayed emergence of a succeeding permanent tooth.^{18,19} Therefore, every effort must be made to preserve the tooth until exfoliation rather than extract perforated primary teeth. For successful treatment of such defects, the root surface should be reconstructed to allow reattachment of periodontal ligament.¹

Ideally, the repair material should be nontoxic and bacteriostatic, promote healing, and provide an optimal hermetic seal.^{5,11,15} Studies have shown that the materials used to repair furcal perforations—such as amalgam, zinc oxide-eugenol, intermediate restorative material, gutta percha, calcium hydroxide, Cavit, GIC, hydroxylapatite, tricalcium phosphate, and bonding agents—have not been able to produce consistent results. This is probably due to bacterial leakage or lack of biocompatibility.^{5,11,15,20}

Based on the recent physical and biological property studies of the newly introduced MTA, this material may be suitable for closing the communication between the pulp chamber and the underlying periodontal tissues.^{3,10,13,21} MTA prevents microleakage and promotes the original tissues' regeneration when placed in contact with the dental pulp or periradicular tissues.^{3,8,10-17} There are reports of complete dentine bridge formation when MTA was used as a pulp capping agent.^{4,7} Moreover, MTA shows good sealing ability, marginal adaptation, a high degree of biocompatibility, and reasonable setting time.^{4,9} MTA is commercially available and, despite its high cost, may be considered an alternative option for the repair of furcal perforation in primary teeth in an attempt to prolong the longevity of these dental elements.

In the present case report, the use of a stainless steel crown to restore the tooth was considered. A provisional and faster restoration with GIC, however, was chosen. GIC has good sealing properties and is easy to handle.²² GIC's adhesion properties impart adequate retention, even if mechanical undercuts are absent. GIC's coverage of exposed dentin and sharp margins also provide good patient comfort with minimal chair time.²² In future follow-ups, a stainless steel crown may still be considered since the lesion in the furcation area is healed.

In the present case, periodontal attachment regeneration in the perforation area could be radiographically observed after 20 months. Although the sealing of furcal perforation and the execution of pulpotomy with MTA appeared to be successful after a short-term evaluation period, further long-term clinical and radiographic assessments of these approaches need to be performed.

In summary, mineral trioxide aggregate may be considered an alternative option for the repair of furcal perforation in primary teeth, allowing adjacent periodontal tissue healing and prolonging the longevity of these dental elements. It is a rather expensive way to solve a problem, but it is a method that can be used effectively and should be considered in certain cases.

REFERENCES

1. Bargholz C. Perforation repair with mineral trioxide aggregate: A modified matrix concept. *Int Endod J* 2005;38:59-69.
2. Torabinejad M, Pitt Ford TR. Root-end filing materials: A review. *Endod Dent Traumatol* 1996;12:161-78.
3. Torabinejad M, Chivian N. Clinical applications of mineral trioxide aggregate. *J Endod* 1999;25:197-205.
4. Schwartz RS, Mauger M, Clement DJ, Walker WA III. Mineral trioxide aggregate: A new material for endodontics. *J Am Dent Assoc* 1999;130:967-75.
5. Joffe E. Use of mineral trioxide aggregate (MTA) in root repairs. *Clinical cases. NY State Dent J* 2002;68:34-6.
6. McCabe PS. The clinical applications of mineral trioxide aggregate. *J Ir Dent Assoc* 2003;49:123-31.
7. Queiroz AM, Assed S, Leonardo MR, Nelson Filho P, Silva LAB. MTA and calcium hydroxide for pulp capping. *J App Oral Sci* 2005;13:126-30.
8. Shabahang S, Torabinejad M, Boyne PP, Abedi H, McMillan P. A comparative study of root-end induction using osteogenic protein-1, calcium hydroxide, and mineral trioxide aggregate in dogs. *J Endod* 1999;25:1-5.
9. Torabinejad M, Watson TF, Pitt Ford TR. Sealing ability of a mineral trioxide aggregate when used as a root end filling material. *J Endod* 1993;19:591-5.
10. Tsatsas DV, Meliou HA, Kerezoudis NP. Sealing effectiveness of materials used in furcation perforation in vitro. *Int Dent J* 2005;55:133-41.
11. De-Deus G, Petrucci V, Gurgel-Filho E, Coutinho-Filho T. MTA versus Portland cement as repair material for furcal perforations: A laboratory study using a polymicrobial leakage model. *Int Endod J* 2006;39:293-8.
12. Behnia A, Strassler HE, Campbell R. Repairing iatrogenic root perforations. *J Am Dent Assoc* 2000;131:196-201.
13. Main C, Mirzaryan N, Shabahang S, Torabinejad M. Repair of root perforations using mineral trioxide aggregate: A long-term study. *J Endod* 2004;30:80-3.
14. Ferris DM, Baumgartner JC. Perforation repair comparing two types of mineral trioxide aggregate. *J Endod* 2004;30:422-4.
15. Hsien HC, Cheng YA, Lee YL, Lan WH, Lin CP. Repair of perforating internal resorption with mineral trioxide aggregate: A case report. *J Endod* 2003;29:538-9.
16. Holland R, de Souza V, Nery MJ, Faraco Junior IM, Bernabe PF, Otoboni Filho JA, et al. Reaction of rat connective tissue to implanted dentin tube filled with mineral trioxide aggregate, Portland cement, or calcium hydroxide. *Braz Dent J* 2001;12:3-8.
17. Yildirim T, Gencoglu N, Firat I, Perk C, Guzel O. Histologic study of furcation perforations treated with MTA or Super EBA in dogs' teeth. *Oral Surg Oral Med Oral Pathol Oral Radiol Endod* 2005;100:120-4.

18. Rao AK, Sarkar S. Changes in the arch length following premature loss of deciduous molars. *J Indian Soc Pedod Prev Dent* 1999;17:29-32.
19. Cuoghi OA, Bertoz FA, de Mendonca MR, Santos EC. Loss of space and dental arch length after the loss of the lower first primary molar: A longitudinal study. *J Clin Pediatr Dent* 1998;22:117-20.
20. Bryan EB, Woollard G, Mitchell WC. Nonsurgical repair of furcal perforations: A literature review. *Gen Dent* 1999;47:274-80.
21. Sluyk SR, Moon PC, Hartwell GR. Evaluation of setting properties and retention characteristics of mineral trioxide aggregate when used as a furcation perforation repair materials. *J Endod* 1998;24:768-71.
22. Hewlett ER, Mount GJ. Glass ionomers in contemporary restorative dentistry—a clinical update. *J Calif Dent Assoc* 2003;31:483-92.

Copyright of Journal of Dentistry for Children is the property of American Academy of Pediatric Dentistry and its content may not be copied or emailed to multiple sites or posted to a listserv without the copyright holder's express written permission. However, users may print, download, or email articles for individual use.