

Management of Supplemental Permanent Maxillary Lateral Incisors in Association With Talon Cusp on the Primary Predecessors: A Report of 3 Cases

Chun-kei Lee, BDS, MDS, MBA, FRACDS, M Paed Dent RCS (Edin), MFGDP (UK), FCDSHK (Paediatr Dent), FHKAM (Dental Surgery)

Nigel M. King, BDS, MSc, PhD, FCDSHK (Paediatr Dent), FHKAM (Dental Surgery), FDS RCS (Edin), LDS RCS (Eng)

Edward Chin-man Lo, BDS, MDS, PhD, FCDSHK, FHKAM (Dental Surgery)

Shiu-yin Cho, BDS, MDS, FRACDS, FCDSHK (Paediatr Dent), FHKAM (Dental Surgery)

ABSTRACT

Most of the cases of talon cusp in the primary dentition affected the maxillary central incisors, but have no effect on the permanent successors. Among the 5 cases of a talon cusp in primary maxillary lateral incisors reported in the dental literature, however, one was associated with a supernumerary tooth and 3 with supplemental permanent successors. The purpose of this report was to describe 3 cases of a talon cusp on the primary maxillary lateral incisors of Chinese children, all of which were associated with talon teeth or the permanent successors. A conservative approach was used to manage these supplemental permanent lateral incisors, and the advantages of such an approach are discussed. (J Dent Child 2008;75:59-63) Received June 12, 2006 | Accepted November 2, 2006.

KEYWORDS: TALON CUSP, INCISORS, SUPERNUMERARY

In 1970, Mellor and Ripa defined talon cusp as a cusp-like structure projecting from the cingulum area of a maxillary or mandibular incisor of varying length which may extend past the incisal edge of the tooth.¹ At that time, they stated that the talon cusp, which was unusual and relatively rare, had only been reported on permanent teeth. The first report of a talon cusp in the primary dentition did not appear in the dental literature until 1976. The anomaly was present on a primary left maxillary central incisor of a mummy which was approximately 2,200 years old,

discovered in southern Peru.² A review of the literature showed that, to date, there have been 37 documented cases of talon cusp in the primary dentition of nonsyndromic and noncleft patients: 31 cases involved maxillary central incisors, 1 case involved mandibular lateral incisors, and 5 cases involved primary maxillary lateral incisors. Four out of 5 cases involving primary maxillary lateral incisors were associated with supernumerary permanent lateral incisors,³⁻⁶ but no such correlation was found when the talon cusp was on a primary maxillary central incisor

The term supplemental tooth, first used by Tomes more than a century ago,⁷ refers to an extra tooth resembling a tooth of the normal series of the dentition. Although supernumerary teeth are not uncommon in the permanent dentition and mostly occur in the maxilla's anterior, supplemental maxillary incisors are much less common than conical or tuberculate supernumerary teeth in this region. In a study of 112 supernumerary teeth observed in the anterior maxilla, only 6 supplemental teeth were found. No mention was

Dr. Lee is dental officer, Ha Kwai Chung School Dental Clinic, Department of Health, HKSAR Government; Dr. King is professor and Director, Postgraduate Program in Pediatric Dentistry, and Dr. Lo is professor in Dental Public Health, both in the Faculty of Dentistry, The University of Hong Kong, Hong Kong SAR; Dr. Cho is senior dental officer, Fanling School Dental Clinic, Department of Health, Hong Kong SAR Government, all in Hong Kong, China.

Correspond with Dr. Lee at chunkeilee@hkusua.hku.hk.

made, however, as to whether they were central or lateral incisors.⁸ Although no supplemental central incisor was found in a study of 180 adult patients with supernumerary teeth in the maxillary central incisor region,⁹ isolated cases of supplemental permanent maxillary central incisor have been reported.¹⁰⁻¹² Supplemental maxillary lateral incisors seem to be more commonly found than central incisors—based on a study of 8,500 schoolchildren in which 8 supplemental maxillary lateral incisors and only 1 central incisor was found.¹³ A study of 739 7-year-old Caucasian children found 2 cases (<1%) with supplemental maxillary lateral incisors,¹⁴ while a study of 2,550 males in the US Navy revealed 4 such cases.¹⁵ In a study of 62 cases of supernumerary permanent maxillary lateral incisors, 30% had supernumerary primary predecessors.¹⁶ The study, however, did not mention any association between supplemental permanent lateral incisors and a talon cusp on the primary predecessors.

The purpose of this report was to describe the clinical management of 3 cases of supplemental permanent maxillary lateral incisors in association with talon cusps on the primary predecessors.

CASE REPORT

CASE 1

A Chinese boy 8 years and 7 months old presented for a routine dental checkup with a noncontributory medical history. Clinical examination revealed that all his permanent incisors, except the maxillary and mandibular right lateral incisors, had erupted. On the retained primary maxillary right lateral incisor's palatal surface, the talon cusp, the majority of which remained, exhibited attrition. Nevertheless, its extension to the incisal edge could still be traced. A panoramic radiograph revealed that the permanent mandibular right lateral incisor was congenitally missing and that a supernumerary tooth was present in the maxillary right lateral incisor region (Figure 1).

A periapical radiograph taken 3 months later indicated the presence of a supplemental maxillary permanent right lateral incisor (Figure 2). The 2 right lateral incisors were almost identical in shape, and it was impossible to identify which one was the supplemental tooth. The treatment options were

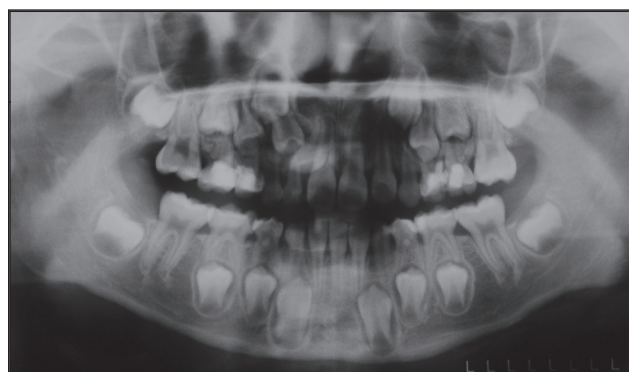


Figure 1. Case 1: A panoramic radiograph, taken at the age of 8 years, 7 months, shows a supplemental permanent maxillary right lateral incisor and congenital absence of the permanent mandibular right lateral incisor.

discussed with the parents, but they declined consultation with an orthodontist. At the same visit, the retained primary lateral incisor was extracted. At a review appointment 4 months later, the mesially located lateral incisor had erupted; the distal one erupted approximately 6 months later.

The clinical examination showed that these 2 right lateral incisors were almost identical in morphology; the more mesial of the 2 lateral incisors lay in the arch, but with the root inclined palatally while the distal one was buccally positioned in the canine region (Figure 3). A panoramic radiograph confirmed that both maxillary canines were at the same eruption stage. The more distally located of the 2 right lateral incisors was extracted. A review appointment at the age of 11 years, 5 months showed that both maxillary canines were erupting normally.

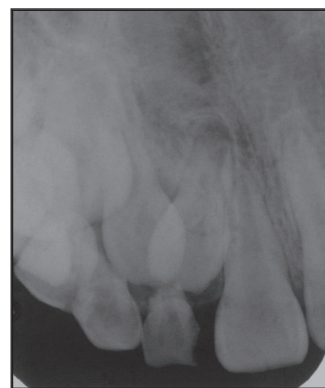

Figure 2. Case 1: A periapical radiograph, taken at the age of 8 years, 10 months, shows that a supplemental permanent lateral incisor is present.

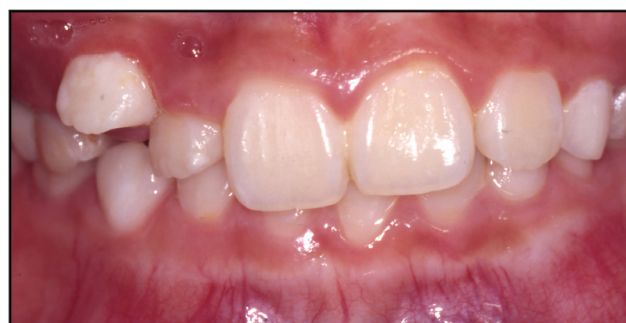

Figure 3. Case 1: At the age of 9 years, 8 months, the more distal of the 2 maxillary lateral incisors has erupted buccal to the arch.

CASE 2

A 7-year-old Chinese girl presented for a routine dental checkup. Her medical history was noncontributory. The clinical examination revealed that her permanent maxillary central incisors had erupted and a talon cusp was present on the primary maxillary right lateral incisor's palatal surface. An upper anterior occlusal radiograph showed that there was a supplemental permanent right lateral incisor. At a following appointment at the age of 7 years, 10 months, the permanent left (but not the 2 right) lateral incisors had erupted. A periapical radiograph showed that the 2 right lateral incisors were similar in shape (Figure 4). When the child was 8 years, 8 months old, the more mesial of the 2 right lateral incisors began to erupt. Four months later, the distal one erupted (Figure 5). The distal of the two right lateral incisors had a crown width matching its antimere, while the crown of the other lateral incisor was smaller than the antimere. An orthodontist recommended ex-

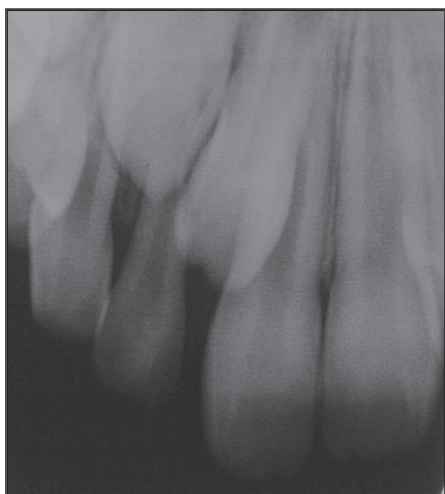

Figure 4. Case 2: A periapical radiograph taken at the age of 7 years, 10 months shows the 2 right lateral incisors which are similar in shape.

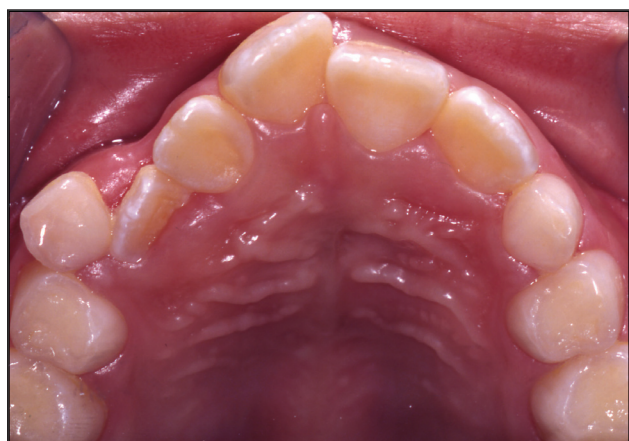

Figure 5. Case 2: At the age of 9 years, when the lateral incisors on the right side had erupted, it is apparent that the mesial of the 2 right lateral incisors is smaller in size.

traction of the mesial of the 2 right lateral incisors and a simple fixed appliance was subsequently used to close the space and to align the maxillary incisors.

CASE 3

A 6-year-old Chinese girl presented for a routine dental checkup. Her medical history was noncontributory. She had avulsed her primary maxillary left central incisor after a fall at the age of 1 year. The primary maxillary right central incisor was mobile, and the primary maxillary right lateral incisor had a talon cusp on the palatal surface extending more than half the height of the clinical crown (Figure 6). Upper anterior occlusal and panoramic radiographs showed that there was a supplemental permanent right lateral incisor. At the 1-year follow up visit, both of the permanent maxillary central incisors had erupted. At the 2-year review, the left lateral incisor had erupted while both right lateral incisors were erupting (Figure 7). The more mesial of the 2 right lateral incisors was slightly palatal to the arch and in mild crossbite with the mandibular right lateral incisor. The distal one, meanwhile,

was slightly smaller and inclined distally. A panoramic radiograph showed that both maxillary canines were at a similar stage of development. The smaller of the two maxillary right lateral incisors was subsequently extracted.

DISCUSSION

The prevalence of the anomaly talon cusp, which is rare in the primary dentition, is less than 1% to approximately 8% in the permanent dentition.¹⁷⁻²⁰ The contributing factors for the disparity in prevalences include variations in: ethnic group, age, sampling populations, and criteria used to define talon cusp.²¹ Although a review of the literature by Al-Omari et al revealed that permanent teeth are affected by talon cusp 3 times more frequently than primary teeth,²² it has been suggested that the incidence of a talon cusp in the primary dentition may not be lower than that in permanent dentition.^{23,24} Of the 37 documented cases in the dental literature of talon cusp in the primary dentition: 20 cases were Chinese, 7 were Asians, 7 were non-Asians, and the ethnicity of 3 cases was not mentioned. This report described 3 cases of talon cusps on the primary maxillary lateral incisors of Chinese children.

Among the 4 reported cases of a talon cusp on the primary maxillary lateral incisor associated with supernumerary or supplemental successors,³⁻⁶ only 1 report described the management of the supplemental incisor which had erupted.⁶

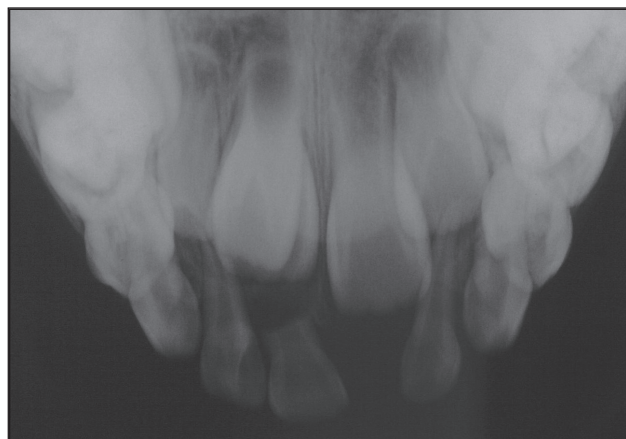


Figure 6. Case 3: An upper anterior occlusal radiograph shows a supernumerary tooth in the right incisor region.

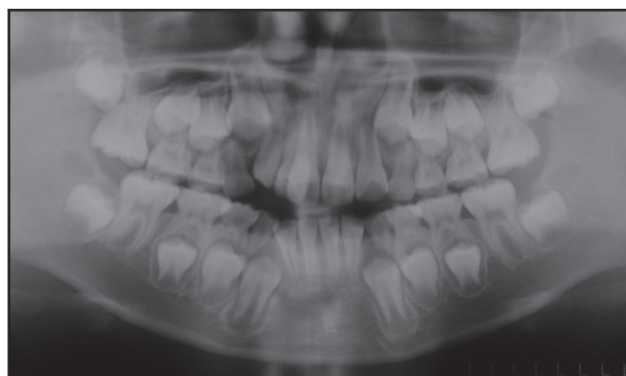


Figure 7. Case 3: A panoramic radiograph, taken at the age of 8 years, 1 month, shows that the 2 maxillary lateral incisors on the right side are erupting.

Unlike supplemental premolars—which usually develop much later than their normal counterparts,^{25,26}—supplemental lateral incisors develop at the same stage as the normal lateral incisors. Most cases are diagnosed and reported after eruption of one or both of the supplemental and normal lateral incisors. The treatment planning is comparatively straightforward. In most cases, simple extraction, with or without orthodontic treatment, is the treatment of choice. In some suitable cases, the supplemental tooth may be used as a donor tooth in autotransplantation.^{27,28} If the supplemental tooth is detected prior to its eruption, however, a decision has to be made as to whether or not to remove the tooth at this earlier stage.

Obviously, the supplemental tooth should be indicated for early removal if it causes impaction of any adjacent tooth or if there is an associated pathology, such as a cyst or root resorption of the adjacent tooth. Some authorities, however, express concern about the merits of prophylactic removal of an unerupted supplemental tooth when there are no apparent pathological complications. Weber suggested that the unerupted supplemental permanent maxillary lateral incisor should be extracted immediately after diagnosis.²⁹ This approach, however, fails to consider the developmental status of the dentition. We adopted a more conservative approach to the management of all three reported cases.

The supplemental lateral incisor may cause impaction of the adjacent central incisor or canine, although, in the authors' experience, this is uncommon. Nevertheless, regular reviews every 4 to 6 months are advisable to ensure the early detection of any impaction. The degree of root formation of the two lateral incisors on the involved side should be carefully assessed. In most cases, eruption will be expected to be delayed when comparison is made with the antimere. From the panoramic radiograph of Case 1, the permanent maxillary right lateral incisor (the distal one) seemed to be impacted by a supernumerary tooth (the mesial one).

The root formation of both teeth, however, was incomplete. Therefore, it was 7 months before the mesial of the two lateral incisors erupted and the distal one erupted 6 months later. If a premature decision had been made to remove the supernumerary tooth, it is highly likely that the mesial of the two lateral incisors would have been extracted, and not the distal one. In Case 2, the mesial of the 2 right lateral incisors erupted 10 months after eruption of the antimere on the left side and the distal one did not erupt until 14 months later. In Case 3, the two right lateral incisors commenced to erupt at the age of 8 years and 1 month, while the left lateral incisor had been fully erupted for some time.

When the supplemental tooth and normal lateral incisor erupt, their morphology, size, and alignment can be assessed directly. A decision can then be made regarding which tooth should be extracted. In Case 1, the two right lateral incisors were identical in shape and the distal one was extracted due to its malalignment. The mesial of the two lateral incisors in Case 2 and the distal one in Case 3 were extracted due to them being the slightly smaller teeth. This characteristic

would have been difficult to determine accurately prior to eruption of these teeth. The conservative approach adopted in this study avoids the difficulties of assessing which tooth should be extracted prior to its eruption when based only on the use of two dimensional radiographic images. More importantly, this saves the child from an unnecessary surgical procedure, which may have to be performed under general anesthesia. Furthermore, it avoids the possibility of damaging the normally forming adjacent lateral incisor.

REFERENCES

1. Mellor JK, Ripa LW. Talon cusp: A clinically significant anomaly. *Oral Surg Oral Med Oral Pathol* 1970;29: 225-8.
2. Sawyer DR, Allison MJ, Pezzia A. Talon cusp: A clinically significant anomaly in a primary incisor from pre-Columbian America. *Med Coll Va Q* 1976;12:64-6.
3. Reddy VVS, Mehta DS. Talon cusp in primary lateral incisor: Report of a case. *J Indian Soc Pedod Prev Dent* 1989;7:20-2.
4. Acs G, Pokala P, Cozzi E. Shovel incisors, three-rooted molars, talon cusp, and supernumerary tooth in one patient. *Pediatr Dent* 1992;14:263-4.
5. Mays S. Talon cusp in a primary lateral incisor from a medieval child. *Int J Paediatr Dent* 2005;15:67-72.
6. Tiku A, Nadkarni UM, Damle SG. Management of two unusual cases of dens invaginatus and talon cusp associated with other dental anomalies. *J Indian Soc Pedod Prev Dent* 2004;22:128-33.
7. Tomes J. *A System of Dental Surgery*. 3rd ed. London. J & A Churchill; 1887:106.
8. Liu JF. Characteristics of premaxillary supernumerary teeth: A survey of 112 cases. *J Dent Child* 1995;62: 262-5.
9. Stafne EC. Supernumerary upper central incisors. *Dental Cosmos* 1931;73:976-80.
10. Camilleri S. A case of bilateral supplemental maxillary central incisors. *Int J Paediatr Dent* 2003;13:57-61.
11. Rock WP. A case of bilateral supplemental maxillary central incisors. *Int J Paediatr Dent* 1991;1:155-8.
12. Orsech GE. Case report. *J Dent Child* 1957;12:106-7.
13. Tinn CA. Excess, deficiency, and gemination in the deciduous and permanent dentitions of school children. *Br Dent J* 1940;68:236-8.
14. Bäckman B, Wahlin YB. Variations in number and morphology of permanent teeth in 7-year-old Swedish children. *Int J Paediatr Dent* 2001;11:11-7.
15. Boyne PJ. Supernumerary maxillary incisors. *Oral Surg Oral Med Oral Pathol* 1954;7:901-5.
16. Johnson DB. Supernumerary lateral incisor teeth. *Br J Orthod* 1974;1:149-57.
17. Dankner E, Harari D, Rotstein I. Dens evaginatus of anterior teeth. Literature review and radiographic survey of 15,000 teeth. *Oral Surg Oral Med Oral Pathol Oral Radiol Endod* 1996;81:472-5.

18. Sedano HO, Carreon Freyre I, Garza de la Garza ML, et al. Clinical orodental abnormalities in Mexican children. *Oral Surg Oral Med Oral Pathol* 1989;68:300-11.
19. Chawla HS, Tewari A, Gopalakrishnan NS. Talon cusp: A prevalence study. *J Indian Soc Pedod Prev Dent* 1983;1:28-34.
20. Sobhi MB, Rana MJ, Ibrahim M, Chaudary A, Manzoor MA, Tasleem ul H. Frequency of dens evaginatus of permanent anterior teeth. *J Coll Physicians Surg Pak* 2004;14:88-90.
21. Hsu CY, Girija V, Fei YJ. Bilateral talon cusps in primary teeth: Clinical significance and treatment. *J Dent Child* 2001;68:239-43.
22. al-Omari MA, Hattab FN, Darwazeh AM, Dummer PM. Clinical problems associated with unusual cases of talon cusp. *Int Endod J* 1999;32:183-90.
23. Chen RJ, Chen HS. Talon cusp in primary dentition. *Oral Surg Oral Med Oral Pathol* 1986;62:67-72.
24. Liu JF, Chen LR. Talon cusp affecting the primary maxillary central incisors in two sets of female twins: Report of two cases. *Pediatr Dent* 1995;17:362-4.
25. Solares R, Romero MI. Supernumerary premolars: A literature review. *Pediatr Dent* 2004;26:450-8.
26. King NM, Lee AM, Wan PK. Multiple supernumerary premolars: Their occurrence in three patients. *Aust Dent J* 1993;38:11-6.
27. Slagvold O, Bjercke B. Applicability of autotransplantation in cases of missing upper anterior teeth. *Am J Orthod* 1978;74:410-21.
28. Taylor GS. Auto transplant replacement of a geminated incisor by a supplemental incisor. *Br J Orthod* 1979;6:195-8.
29. Weber FN. Supernumerary teeth. *Dent Clin North Am* 1964;8:509-17.

Copyright of Journal of Dentistry for Children is the property of American Academy of Pediatric Dentistry and its content may not be copied or emailed to multiple sites or posted to a listserv without the copyright holder's express written permission. However, users may print, download, or email articles for individual use.