

# Radicular Cyst in a Deciduous Tooth: A Case Report and Literature Review

**Takayuki Nagata, DDS    Jouji Nomura, DDS, PhD**  
**Yoshihiko Matsumura, DDS    Shigeaki Yanase, DDS    Tasuku Fujii, DDS**  
**Tomomichi Oka, DDS    Shiori Uno, DDS    Toshiro Tagawa, DDS, PhD**

## ABSTRACT

Radicular cyst is comparatively rare in primary teeth. The purposes of this paper were to report the case of a 6-year-old male child with a radicular cyst in a primary mandibular molar tooth, and discuss the causal factors and treatment of this lesion based on a review of the literature. (J Dent Child 2008;75:80-4) Received October 17, 2006 | Last Revision March 22, 2007 | Revision Accepted March 23, 2007.

KEYWORDS: RADICULAR CYST, TOOTH PRIMARY

The incidence rate of a radicular cyst is high among cystic lesions that develop in the oral region.<sup>1</sup> The disease occurs most commonly associated with permanent teeth and is rare in primary teeth.<sup>2</sup> Shear<sup>3</sup> reported that development of a radicular cyst in primary teeth accounted for less than 1% of all cases, while Lustmann et al<sup>2</sup> showed that the number of cases of a radicular cyst in primary teeth from 1898 to 1983 was 51, including their 23 cases.<sup>2</sup> Mass et al,<sup>4</sup> however, reported 36 cases, suggesting that development of a radicular cyst in primary teeth may not be uncommon. As far as the authors are aware, the number of such cases reported from 1927 to 2004 is 112, including this case.

The purposes of this paper were to report a case of a radicular cyst in a primary molar tooth in the mandible, and discuss the causal factors and treatment of this lesion based on a review of the literature.

## CASE REPORT

A 6-year, 6-month-old Japanese male child visited the Department of Oral and Maxillofacial Surgery at Mie University Hospital, Mie, Japan, for buccal swelling of the gingiva in a region of primary mandibular molar teeth on the right side.

*Drs. Nagata, Fujii, Oka and Uno are residents; Dr. Nomura is a lecturer; Dr. Matsumura is instructor; Dr. Yanase is a research fellow; and Dr. Tagawa is professor, all in the Department of Oral and Maxillofacial Surgery, Faculty of Medicine, Mie University, Mie, Japan. Correspond with Dr. Nagata at [jn@clin.medic.mie-u.ac.jp](mailto:jn@clin.medic.mie-u.ac.jp).*

There were no specific issues in his family history and past history. Approximately 1 month before the first visit, the patient had noticed painless swelling in the region. The swelling had subsequently expanded, and he had visited a nearby dentist, where an X-ray examination showed a thumb-sized radiolucent region in the apical area of the second primary molar tooth in the right mandible. Based on the dentist's advice, the patient then visited Mie University Hospital.

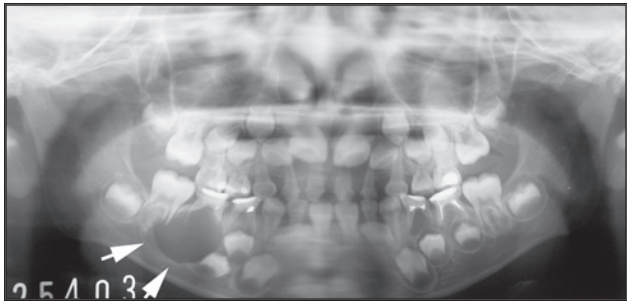
The patient had a medium body build and a good nutritional state, with a height and weight of 114.8 cm and 19.8 kg, respectively. No systemic abnormalities were apparent, but diffuse swelling with tenderness was observed in the right buccal region. In addition, resin restoration was seen in the second primary molar tooth in the right mandible, with bone-like bulging towards the buccal region (Figure 1).

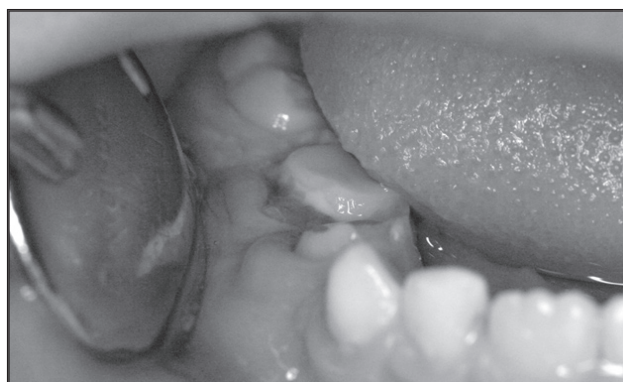

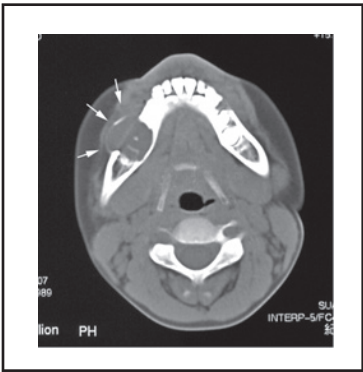Figure 1. Intraoral image at the first visit. Bone-like bulging was confirmed on the buccal side of a second deciduous molar tooth in the right mandible.

There was no percussion pain at the tooth, however, and no abnormality in the regional lymph node. In a detailed inter-view, it was determined that formocresol (FC) had been applied to the tooth three times and iodoform paste had been applied to the root canal filling. A panoramic radiograph showed a radiolucent image of 20 mm in size with a clear border, including the root of the second primary molar tooth immediately under the tooth.

An osteosclerotic area located around the radiolucent region was apparent in the surrounding alveolar bone. In addition, the tooth germ of the second premolar in the right mandible was displaced towards the mesial side due to the lesion (Figure 2). CT scanning was performed to differentiate the lesion from a malignant tumor and other tumorous lesions. The CT image also showed a monolocular cyst-like radiolucent region with a clear border, and thinning was observed in the cortical bone on the buccal side (Figure 3).

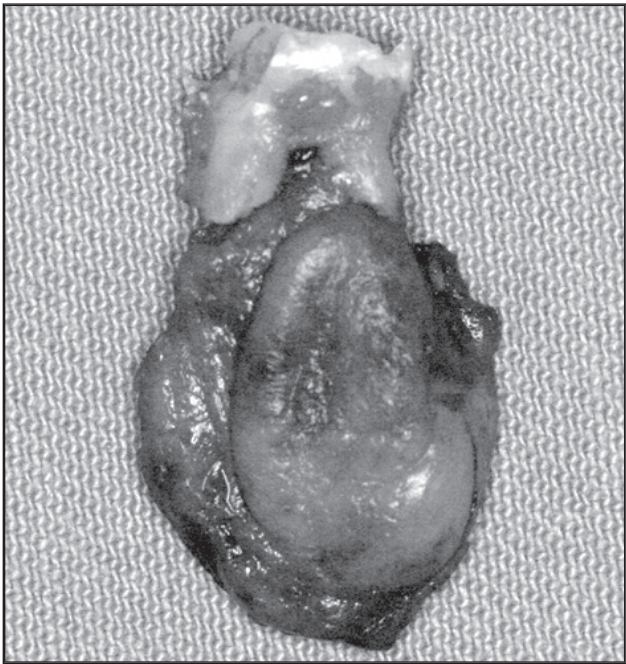


**Figure 2.** Panoramic X ray image. A radiolucent area with a clear border was observed immediately beneath the second primary molar tooth in the right mandible (indicated by the arrow), and the tooth germ of the second premolar was displaced toward the mesial side.

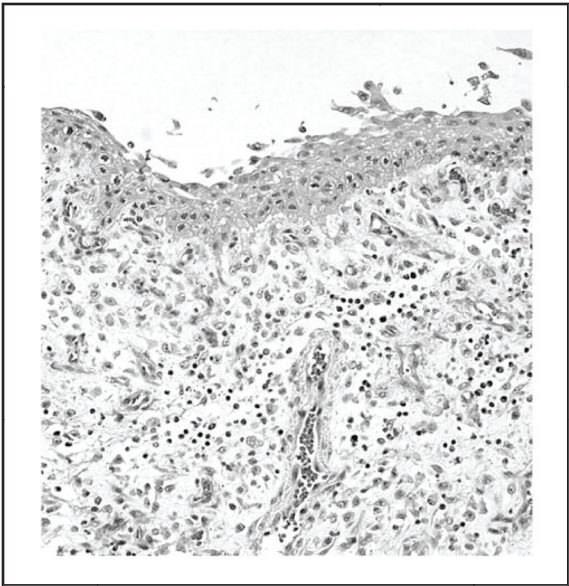


**Figure 3.** CT image. A cyst-like finding was observed, with thinning of the cortical bone on the buccal side (indicated by the arrow).

Based on a clinical diagnosis of a radicular cyst or radicular granuloma in the second primary molar, surgical removal of the lesion and extraction of the second primary molar were performed under general anesthesia. The lesion—which contained a yellow-brown, slightly viscous fluid—was not clearly continuous between the tooth germs of the first and second premolar. The lesion was removed together with the tooth as a mass, and the resultant wound was opened inserting the gauze. The size of the lesion was 22×15 mm, and it included the root of the second primary molar tooth (Figure 4).



**Figure 4.** Specimen after removal. The specimen included the root of the second deciduous molar tooth.



**Figure 5.** Histopathological image. The cyst wall was covered with stratified squamous epithelium, and granular tissues accompanied by infiltration of inflammatory cells were found under the epithelium (H-E staining, X120).

Histopathologically, the wall of the removed cyst was covered with a stratified squamous epithelium and granular tissues with inflammatory cellular infiltration were present under the epithelium. Based on these findings, the authors reached a final diagnosis of a radicular cyst of the second primary molar in the right mandible (Figure 5). One month after the surgery, the authors recommended insertion of an appliance to maintain space, but they did not obtain agreement from the patient's parents. The patient did not appear for the follow up visit.

## DISCUSSION

Radicular cyst is generally defined as arising from epithelial residues (rests of Malassez) in the periodontal ligament as a consequence of inflammation, usually following the death of dental pulp.<sup>1</sup> The incidence rate of this disease is highest among cystic diseases that develop in the maxilla, and such cysts have been observed mostly in 20- to 30-year-old patients. In addition, the disease has been observed mainly in permanent teeth.<sup>1</sup>

According to the authors' search, only 112 cases in primary teeth have been reported in the dental literature, including this case, from 1927 to 2004.<sup>2,4-13</sup> Lustmann et al<sup>2</sup> reported 51 confirmed cases, including 23 cases of their own, between 1898 and 1983, and Shear<sup>3</sup> showed that only less than 1% of cases of a radicular cyst develop in primary teeth.

The reason for the low incidence of a radicular cyst in primary teeth compared with permanent teeth is thought to be the shorter period in which primary teeth are present in the jaw, compared to that for permanent teeth.<sup>5</sup> Lustmann et al,<sup>2</sup> however, suggested that this period should be sufficient for development of a cyst because primary teeth remain in an inflamed maxilla for 5 to 6 years after death of the dental pulp. Drainage that decreases the possibility of cyst development, however, might also occur in primary teeth with inflammation. Mass et al<sup>4</sup> also suggested that inflammation in the dental pulp or apical area of primary teeth would cause drainage to the maxillary sinus or marginal gingival region, thereby resulting in improvement of symptoms and decreasing the likelihood of the provision of appropriate treatment.

There is also a possibility that the biological activity of dental pulp in primary and permanent teeth may be related to the development of a radicular cyst. Rodd et al,<sup>14</sup> reported that the number of immunocompetent cells in the dental pulp of primary teeth is significantly higher than in permanent teeth. There is, however, no difference in the inflammatory reaction in tooth caries between primary and permanent teeth. Thus, it seems that there is no specific relationship of cyst development and the activity of dental pulp. On the other hand, it has been shown that radiolucent findings in the apical area of primary teeth tend to be ignored and most of the area is absorbed after tooth extraction.<sup>4</sup>

Thus, pathological examinations may not always be performed for primary teeth, and this may account for the relatively small number of reported cases of cysts in primary teeth relative to cysts in permanent teeth, therefore, there may be more cases of cysts in deciduous teeth than actually reported. Based on data obtained in a 30-year histopathological investigation of children 16 years old or younger, Jones et al<sup>15</sup> showed that the incidence rate of a radicular cyst was 5% in the 4,406 cases, which was higher than the rate for dentigerous cyst and the third highest overall, after mucous cyst and apical granuloma.

In the present study, the youngest patient was 4 years old and the oldest was 19 years old. The subjects included 12 7-year-olds (20%), 12 8-year-olds (20%), 8 5-year-olds (14%), 8 6-year-olds (14%), 5 10-year-olds (8%), 5 11-

year-olds (8%), 4 9-year-olds (7%), 2 12-year-olds (3%), 1 4-year-old (2%), and 1 19-year-old (2%). Thus, the highest numbers of patients were 7 and 8 years old, with an average age of 7.86 years old (Table 1). These data are similar to those in previous studies. These have included:

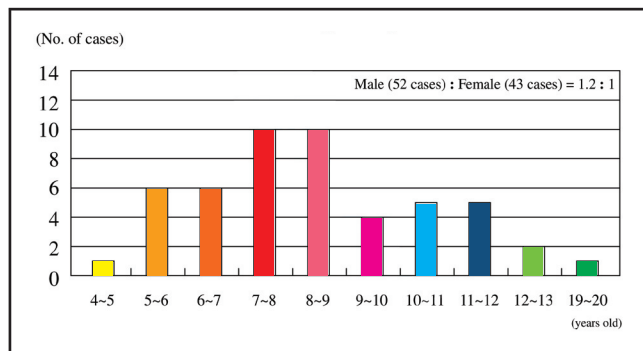
- 4- to 12-year-old patients, in addition to 1 19-year-old patient, for an average patient age of 8 years old<sup>2</sup>;
- subjects with an average age of 7 years old<sup>4</sup>; and
- subjects with an average age of 8.3 years old.<sup>6</sup>

The subjects in this study included 52 boys and 43 girls, a male to female ratio of 1.2:1 (Table 1); the sex ratios in previous studies have been 1.6:12 and 1.15:115 (both including a higher number of boys), and 1:1.38 (including a higher number of girls). Thus, the authors consider that this study has a similar sex distribution to previous studies.<sup>7</sup>

Regarding development sites, there were:

- 40 cases of the disease in primary molars in the mandible (67% of all cases);
- followed by 10 cases in primary molars in the maxilla (17%);
- 8 cases in primary anterior teeth in the maxilla (13%); and
- 2 cases in primary anterior teeth in the mandible (3%).

The number of cases in the second primary molar in the mandible was 27, which was the highest percentage among the cases in primary molar teeth (Table 2). In 17 cases reported by Grundy et al,<sup>8</sup> all had the disease in primary molar teeth in the mandible, and another report showed that cases in primary molar teeth in the mandible accounted for 83% of total cases.<sup>9</sup>



**Table 1. Age and Gender. The highest numbers of patients were 7 and 8 years old, with an average age 7.86 years.**

**Table 2. Sites and Treatment of Dental Pulp\***

Sites	Cases: N (%)
Deciduous molar teeth in mandible	40 (67)
Deciduous molar teeth in maxilla	10 (17)
Deciduous anterior teeth in maxilla	8 (13)
Deciduous anterior teeth in mandible	2 (3)
Treatment of dental pulp: Yes	46 (56)
Treatment of dental pulp: No	36 (44)

\* Regarding development sites, there were 40 cases of the disease in primary molar teeth in the mandible, accounting for 67% of the total cases.



Based on these data, it appears that primary molars in the mandible may be the favored site for development of a radicular cyst. A reason for this may be that these teeth are the frequent sites of dental caries.<sup>6</sup> By contrast, it has been reported that permanent anterior teeth in the maxilla are the most frequent site of a radicular cyst in adults,<sup>16</sup> which can be explained by silicate restorations in the maxillary incisors, the high frequency of palatal invaginations in the maxillary lateral incisors, and a high frequency of traumatic injuries to the maxillary anterior teeth.<sup>2</sup>

Explanations based on repair, however, are not applicable to cases in primary molars. Also, although some reports have shown trauma in primary anterior teeth,<sup>17,18</sup> no such reports are available for primary molars. Thus, it appears that the hypothesis of pulp necrosis due to dental caries as the basis for development of cysts in primary molars is the most likely explanation.

Treatment of dental pulp has also been discussed widely as a causal factor of a radicular cyst in primary teeth.<sup>8-10,19,20</sup> Savage et al<sup>20</sup> performed a histological examination of the amorphous eosinophilic material observed in the radicular cyst wall in primary teeth. Since this substance included phenols, it was suggested that antigen stimulation by various products used for endodontic treatment of primary teeth may be related to the development and rapid growth of a radicular cyst in primary teeth. In addition, other reports have shown that treatment of dental pulp using FC and iodoform was for a characteristic of all cases.<sup>6,8</sup> Although similar treatment was performed in this case, these medications, only accounted for 56% of the total (Table 2). Also a study of many cases of cysts are not related to treatment of dental pulp.<sup>4</sup>

Therefore, the authors conclude that there is no direct relationship between medications used for treatment of dental pulp and the development of a cyst. There is a possibility, however, that these medications may stimulate the apical area, affect consecutive permanent teeth<sup>21</sup>, or develop/expand the cyst. This is because the apical foramen of primary teeth is larger than that of permanent teeth. Based on these data, follow-up observations after treatment of dental pulp of primary molar teeth are needed to examine potential cyst development.

Regarding differential diagnosis, diseases such as periapical granuloma and dentigerous cyst should be considered.<sup>2,4,10</sup> Since periapical granuloma is the preliminary stage of a radicular cyst,<sup>1</sup> differentiation of the diseases is difficult. The larger the granuloma, the higher the possibility of a radicular cyst.<sup>4</sup> In differentiation from a dentigerous cyst, it is important to confirm whether the position of the permanent tooth germ is retained or displaced.<sup>3</sup> Since it has been reported that a radicular cyst can include the crown of consecutive permanent teeth,<sup>5</sup> a definitive diagnosis of the disease requires a comprehensive assessment based on clinical findings, X ray examination, histopathologic examination, and surgical findings.

## REFERENCES

1. Kramer IRH, Pindborg JJ, Shear M. *Histological Typing of Odontogenic Tumours*. 2<sup>nd</sup> ed. Berlin, Germany: Springer-Verlag; 1992.
2. Lustmann J, Shear M. Radicular cysts arising from deciduous teeth. *Int J Oral Surg* 1985;14:153-61.
3. Shear M. *Cyst of the Oral Region*. 2<sup>nd</sup> ed. Butterworth-Heinemann Ltd; John Wright and Sons; 1983.
4. Mass E, Kaplan I, Hirshberg A. A clinical and histopathological study of radicular cysts associated with primary molars. *J Oral Pathol Med* 1995;24:458-61.
5. Sprawson E. Further investigation of the pathology of dentigerous cysts with a new treatment based thereon. *Proc R Soc Med* 1927;20:1781-92.
6. Hill FJ. Cystic lesions associated with deciduous teeth. *Proc Br Paedod Soc* 1978;8:9-12.
7. Sofat JR. A large radicular cyst of a mandible in a child. *J Indian Dent Assoc* 1986;58:543-4.
8. Grundy GE, Adkins KE, Savage NW. Cysts associated with deciduous molars following pulp therapy. *Aust Dent J* 1984;4:249-56.
9. Joseph PL, Schwartz-Arad D, Amnon S. Odontogenic cysts related to pulpotomized deciduous molars *Oral Surg Oral Med Oral Pathol Oral Radiol Endod* 1999; 87:499-503.
10. Takiguchi M, Fujiwara T, Sobue S, Ooshima T. Radicular cyst associated with a primary molar following pulp therapy: A case report. *Int J Paediatr Dent* 2001; 11:452-5.
11. Richard E, Marshall M, George KB. Two radicular cysts associated with endodontically treated primary teeth: Rationale for long-term follow-up. *Int J Paediatr Dent* 1999;76(8):29-33.
12. Robert EW, Christoffel JN, Arun P, Grottepass F. Radicular cysts of primary teeth mimicking premolar dentigerous cysts: Report of three cases. *J Dent Child* 1988;55:288-90.
13. Delbem ACB, Cunha RF, Vieira AEM, Pugliesi DMC. Conservative treatment of a radicular cyst in a 5-year-old child: A case report. *Int J Paediatr Dent* 2003;13: 447-50.
14. Rodd HD, Boissonade FM. Immunocytochemical investigation of immune cells within human primary and permanent tooth pulp. *Int J Paediatr Dent* 2006;16:2-9.
15. Jones AV, Franklin CD. An analysis of oral and maxillofacial pathology found in children over a 30-year period. *Int J Paediatr Dent* 2006;16:19-30.
16. Regezi JA, Sciubba JJ. *Oral Pathology: Clinical-Pathologic Correlations*. Philadelphia, Pa: Saunders; 1989.
17. Alastair TFS, Jonathan GC. Radicular cyst arising from a traumatized primary incisor: A case report of a rare complication that emphasizes the need for regular follow-up. *Dent Update* 2005;32:109-13.
18. Al-Khayatt AS, Davidson LE. Complications following replantation of a primary incisor: A cautionary tale. *Br Dent J* 2005;11:687-8.

19. Brook AH, Winter GB. Developmental arrest of permanent tooth germs following pulpal infection of deciduous teeth. *Br Dent J* 1975;139:9-11.
20. Savage NW, Adkins KF, Weir AV, Grundy GE. A histological study of cystic lesions following pulp therapy in deciduous molars. *J Oral Pathol* 1986;15:209-12.
21. Ronald JP, Gary AO, Prem SS. Relationship between formocresol pulpotomies on primary teeth and enamel defect on their permanent successors. *J Am Dent Assoc* 1977;94:698-700.

Copyright of Journal of Dentistry for Children is the property of American Academy of Pediatric Dentistry and its content may not be copied or emailed to multiple sites or posted to a listserv without the copyright holder's express written permission. However, users may print, download, or email articles for individual use.