

Orofacial Aspects in Noonan Syndrome: 2 Case Report

Adriana de Oliveira Lira Ortega, DDS, MS
Renata de Oliveira Guaré, DDS, MS, PhD
Nilce Samecima Kawaji, DDS
Ana Lúcia Ciamponi, DDS, MS, PhD

ABSTRACT

Noonan syndrome (NS) is an autosomal dominant disorder characterized by dysmorphic facial features in association with short stature and heart disease. A webbed neck, chest deformities, mental retardation, and bleeding disorders are also frequently associated with this pathology. NS is relatively common, with an estimated incidence of 1 per 1,000 to 1 per 2,500 live births. Many cases have been reported in the dental literature, yet only a few of them describe some details of the oral features. The aim of this paper is to describe 2 cases of Noonan syndrome, emphasizing oral and facial aspects and particularities of the dental treatment in subjects affected by this genetic disease. (J Dent Child 2008;75: 85-90) Received December 7, 2006 | Last Revision April 4, 2007 | Revision Accepted April 4, 2007.

KEYWORDS: NOONAN SYNDROME, GENETIC DISEASE, ORAL ASPECTS, MALOCCLUSION, CONGENITAL HEART DISEASE, BLEEDING DIATHESIS

Noonan syndrome (NS; OMIM 163950),¹ is an autosomal dominant syndrome that maps to 12q24.2-q24.31- and is caused by mutations in PTPN11, a gene encoding the nonreceptor protein tyrosine phosphatase SHP2, which contains 2 Src homology-2 (SH2) domains. The pathogenesis of Noonan syndrome arises from excessive SHP-2 activity.² The NS phenotype bears similarities to that of Turner syndrome that occurs only in females and has a 45,X karyotype abnormality. NS occurs, however, in both males and females with a normal sex chromosome 46,XX and 46,XY constitution.

Dr. Ortega is a Doctorate in Dental Sciences student, Federal University of São Paulo, and professor, Group for the Study and Treatment of Special Needs Patients of the Pediatric Dentistry Discipline of the University of São Paulo; Dr. Guaré is professor, Pediatric Dentistry, and professor, Group for the Study and Treatment of Special Needs Patients of the Pediatric Dentistry Discipline, both at the University of São Paulo, and is professor, Special Needs Patients Discipline, Cruzeiro do Sul University; Dr. Kawaji is specialist, special needs patients, University of São Paulo; and Dr. Ciamponi is coordinator, Group for the Study and Treatment of Special Needs Patients of the Pediatric Dentistry Discipline, and professor, Pediatric Dentistry, University of São Paulo; all in São Paulo, Brazil. Correspond with Dr. Ortega at aliraort@uol.com.br.

NS is a dysmorphic syndrome characterized by ocular hypertelorism, ptosis, a downward eye slant, divergent squint, a tendency for exophthalmia, low-set posteriorly rotated ears, short stature, a short neck with webbing or redundancy of skin, pectus excavatum, and epicanthic folds. A number of skin manifestations are well known in NS, including “café-au-lait” spots, pigmented nevi, lentigo, and keratosis pilaris atrophicans faciei.⁴⁻⁶ Marino et al⁷ evaluated 136 NS patients and concluded that left-sided lesions, such as aortic coarctation and mitral valve anomalies, are not rare in NS patients and congenital heart disease patients. Atrioventricular canal is quite common, being that the partial form is prevalent and subaortic stenosis caused by additional anomalies of the mitral valve may be present.

Uçar et al⁸ reported a case of a 12-year-old girl with NS who had multiple cardiovascular abnormalities, including extensive bilateral coronary artery dilatation, valvular and supravalvular pulmonary stenosis, atrial septal defect, and mitral valve prolapse.

Bleeding disorders are of variable clinical severity, and stem from different defects in the coagulation and platelet systems in NS patients. It has been estimated that roughly one third of the patients have some sort of bleeding disorder.⁹ Staudt et al¹⁰ stated that factor XIII-deficiency had never been reported as an isolated deficiency and described

a case of NS in which the patient had a reduced concentration of factor XIII in association with a prolonged bleeding time, which is rare.

Due to the deafness and motor delay presented by NS individuals, there is a need for different approaches during the dental treatment. The clinician has to use special techniques to improve the relationship with the patient and the quality of the procedures.

Not many papers focusing on the oral aspects of NS were found in the literature. Torres-Carmona *et al*¹¹ reported two NS cases, and the most important oral finding was clinical and radiological evidence of advanced periodontal disease. The authors drew attention to the alveolar destruction and root resorption that could not be justified by the patients' ages and did not resemble juvenile periodontitis. Sugar *et al*⁶ reported a case of an individual presenting with moderate anteroposterior maxillary deficiency, marked mandibular prognathism with anterior open bite, excessive chin height but anteroposterior chin deficiency, and Class III occlusion with a reverse overjet of 6 mm.

The treatment plan included orthognathic approach in spite of the knowledge about the bleeding disorders associated with the disease, and there was a complicated postoperative condition. The patient had to stay in the intensive care unit due to bleeding episodes. Although the patient had been fully

aware of the risks involved, he and his parents stated that they wanted to proceed with the surgery and they were pleased that they had opted for it. A high arched palate also was reported by Nirmal *et al*.¹² Okada *et al*⁵ described a patient whose oral examination revealed a narrow, high arched palate and a hypoplastic mandible with posterior crossbite. In addition, these authors found an anterior open bite. Cephalometric measurements showed a wide gonial angle, large mandibular plane angle, large Y-axis, and long facial height.

CASE REPORTS

Parents of two unrelated individuals with a previous clinical diagnosis of NS sought treatment at the School of Dentistry, University of São Paulo, São Paulo, Brazil. The authorization for disclosure of the images for scientific publication, without need a black strip covering the eyes, was properly given by written consent of the legal guardians of the children who agreed to and signed a written consent form.

CASE REPORT NO. 1

The patient, a 14-year-old male of African descent, was born by natural childbirth and measured 3.640 kg and 45 cm. He was diagnosed at birth with cyanosis and did not suck in the first 24 hours. No case of NS was related in the family. The presented phenotype included ocular hypertelorism, palpebral ptosis, low-set ears and hair, upper chest pectus carinatum and lower pectum excavatum, short-stature, and a webbed neck (Figures 1a and 1b). Medical reports revealed mild mental deficiency and congenital heart disease. After medical diagnosis, the patient was followed and underwent a procedure for pulmonary stenosis.

The oral aspects included atypical swallowing, labial hypotonia, mixed dentition, Class II malocclusion, bilateral posterior crossbite, and lack of space for the correct dental alignment. The patient also presented with a high level of biofilm along with generalized gingival inflammation and a carious lesion in the lower first molar with endodontic involvement (Figure 2). No numerical or morphological dental anomalies were found radiographically (Figure 3).

Cephalometric analysis showed maxillary and mandibular retrognathism (SNA/SNB), positive discrepancy between upper and lower jaws (ANB), vertical growth pattern (NS.GoGn), divergence of occlusal plane in relation to cranial base (NS.PIO), and buccal inclination and protrusion of

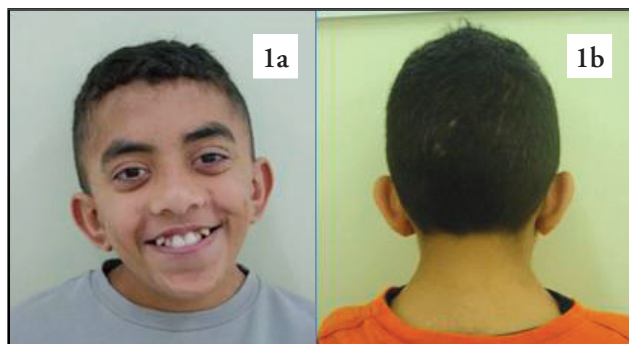

Figure 1a – 1b. Phenotypic aspects: observe ocular hypertelorism, palpebral ptosis, low-set ears and hair and a webbed neck.

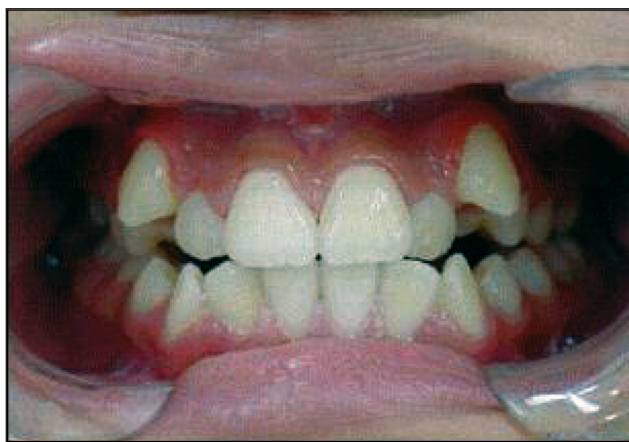

Figure 2. Intraoral aspect: mixed dentition, class II malocclusion, cross bite, and lack of space for the correct dental alignment. The patient also presented with a high level of biofilm along with generalized gingival inflammation.

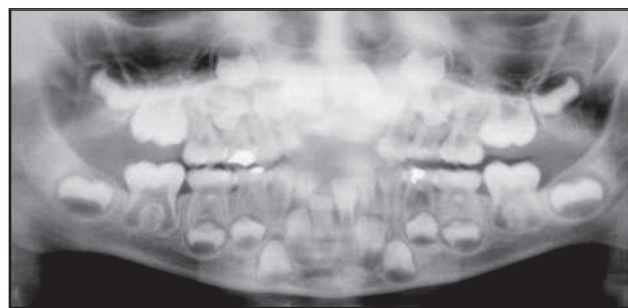


Figure 3. Orthopantomograph: no numerical or morphological dental anomalies were found in the radiographic examination

upper (1/.NA- 1/-NA) and lower incisors (/1.NB- /1-NB). (Table 1 and Figure 4).

The estimated bone age (13 years old), determined by analyzing a carpal X ray using the Greulich and Pyle method (Figure 5), was delayed in comparison to his chronological age (14 years, 9 months).

CASE REPORT NO. 2

The patient, a 13-year-old male of African descent, was born via Cesarean section and measured 2.950 kg and 47 cm. No complication was related during the neonatal period, nor was there any case of NS in the family. The phenotype included low-set hair, prominent and posteriorly rotated ears, hypertelorism, genu valgum, telecanthus, and a webbed neck (Figures 6a, 6b). Medical reports showed mild mental deficiency, pulmonary stenosis, interatrial communication, bilateral dysacusis, and epilepsy.

Oral examination revealed a mixed dentition, Class II malocclusion, mild mandibular retrognathism, dental misalignment, and carious lesion in the lower first molars. The patient also presented with a high level of biofilm along

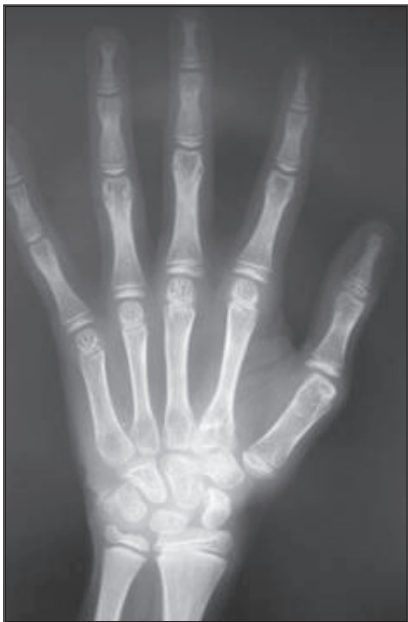

Figure 5. Hand-wrist radiograph: the estimated bone age (13 years old), determined by analysing a carpal x-ray using the Greulich & Pyle method was delayed in comparison to his chronological age (14 years and 9 months).

Table 1. Cephalometric Measurements: Case Report No. 1		
Cephalometric Measurements	Normal value	Patient value
SNA	82°	79.2°
SNB	80°	75.2°
ANB	2°	4.0°
NS.GoGN	32°	40.1°
NS.PIO	14°	17.8°
1/.NA	22°	27.4°
1/-NA	4 mm	7.3 mm
/1.NB	25°	27.2°
/1-NB	4 mm	10.1 mm

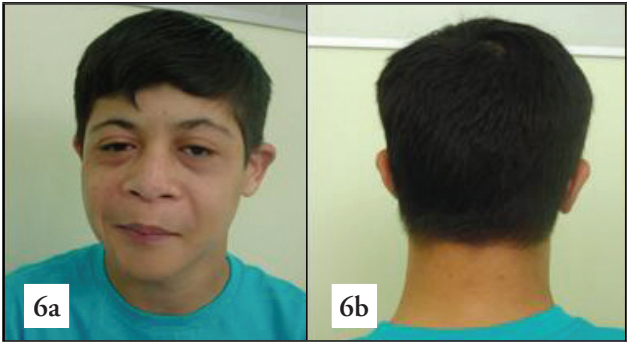

Figure 6a –6b. Phenotypic aspects: Observe the presence of a low-set hair, prominent and posteriorly rotated ears, hypertelorism, and a webbed neck.

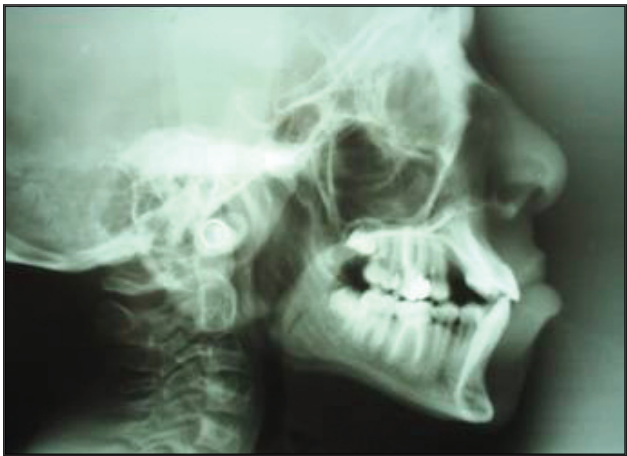

Figure 4. Cephalometric radiographs: maxillary and mandibular retrognathism; positive discrepancy between upper and lower jaws; vertical growth pattern; divergence of occlusal plane in relation to cranial base; buccal inclination and protrusion of upper and lower incisors.

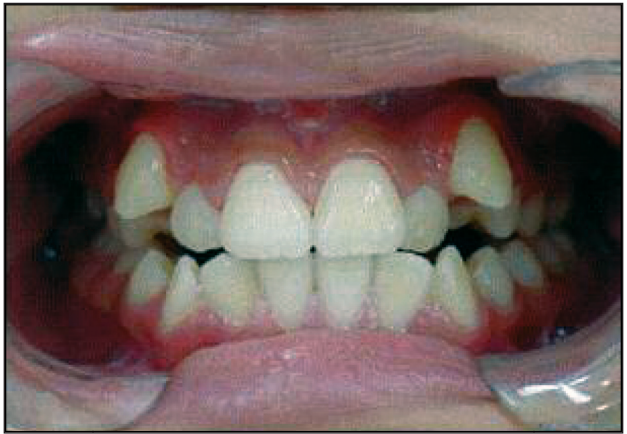

Figure 7. Intraoral aspect: mixed dentition, class II malocclusion, mild mandibular retrognathism, dental misalignment. The patient also presented with a high level of biofilm along with generalized gingival inflammation.

with generalized gingival inflammation (Figure 7). Numerical anomalies (supernumerary teeth) were detected (Figure 8).

Cephalometric analysis revealed the following: maxillary and mandibular prognathism (SNA/SNB), high positive discrepancy between the upper and lower jaws (ANB), vertical growth pattern (NS.GoGn), divergence of the occlusal plane in relation to the cranial base (NS.PIO), and lingual

inclination and retrusion of upper (1/.NA- 1/-NA) and lower incisors (/1.NB- /1-NB). (Table 2 and Figure 9)

The estimated bone age (11 years, 6 months), measured by carpal X ray, using the Greulich and Pyle method was delayed in comparison to his chronological age (13 years, 9 months), also (Figure 10).

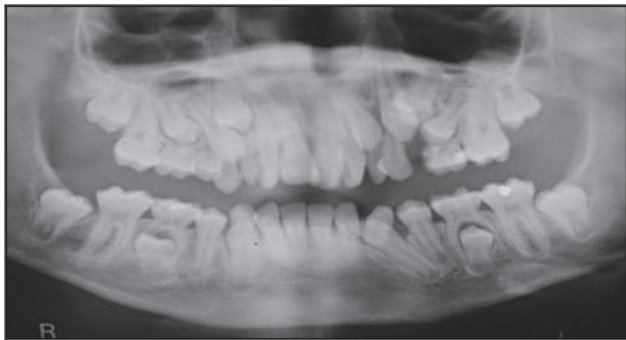


Figure 8. Orthopantomograph: numerical anomalies (supernumerary teeth). Transposition of the right maxillary canine and first premolar, delayed lower second deciduous molars exfoliation and odontogenesis of the lower second premolars.

Table 2. Cephalometric Measurements: Case Report No. 2		
Cephalometric Measurements	Normal value	Patient value
SNA	82°	92.4°
SNB	80°	81.1°
ANB	2°	11.3°
NS.GoGN	32°	34.4°
NS.PIO	14°	13.5°
1/.NA	22°	-2.0°
1/-NA	4 mm	1.1 mm
/1.NB	25°	34.9°
/1-NB	4 mm	7.9 mm

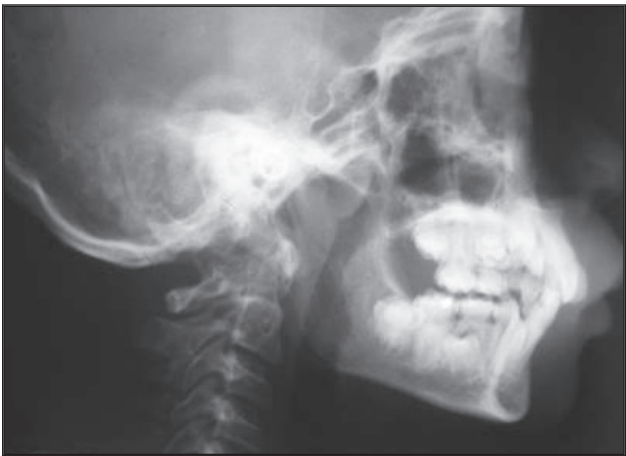

Figure 9. Cephalometric radiographs: maxillary and mandibular prognathism, high positive discrepancy between upper and lower jaws, vertical growth pattern, divergence of occlusal plane in relation to cranial base, lingual inclination and retrusion of upper and lower incisors.

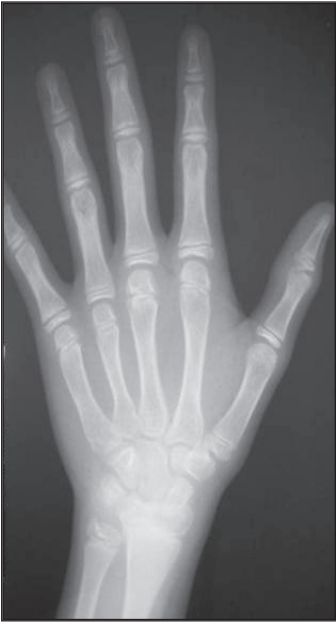

Figure 10. Hand-wrist radiograph: the estimated bone age (11y and 6m), measured with carpal x-ray, was delayed in comparison to his chronological age (13y and 9m), also using the Greulich & Pyle method.

DISCUSSION

Both patients involved in this evaluation presented with a characteristic phenotype. The differences in the intensity of expressions can be explained by expressivity of the gene. Some findings related in the literature are absent in these cases as skin manifestations “café-au-lait” spots, pigmented nevi, lentigo, and keratosis pilaris atrophicans faciei.⁴⁻⁶

Cardiac disease with risk of bacterial endocarditis seems to be common in NS. Therefore, before any invasive procedure, prophylactic antibiotic therapy was instituted according to the clinical guidelines of the American Heart Association.¹³ Other authors recommended that cardiac patients should have a dental examination and an efficient preventive dental program implemented to reduce the incidence of dental disease.¹⁴

Even though no surgical procedures were conducted on these patients, it is important to emphasize the need for laboratorial investigations (complete blood count, including platelet count; prothrombin time; partial thromboplastin time, and bleeding time). Staudt et al¹⁰ stated that if any abnormal results are obtained, a more extensive investigation is required. The next step is to measure the individual clotting factors, von Willebrand factor, and platelets’ function.

Although Torres-Carmona et al¹¹ described the occurrence of periodontal disease in NS patients, this pathology was not observed in these two cases. Due to the multifactorial etiology of periodontal disease, it is suggested that NS patients may exhibit sensitivity to periodontitis into the normal standards.

Cephalometric analysis revealed altered measurements and a peculiar occlusal pattern for each subject. Okada et al⁵ reported a case in which the patient presented a skeletal open bite malocclusion in association with an abnormal swallowing habit. Although Sugar et al⁶ described an individual with excessive mandibular prognathism, Class II malocclusion was found in the subjects of this paper. As also described by Okada et al,⁵ it also does not seem to be a typical occlusal pattern in the NS.

Hand-wrist radiographs showed the bone age slightly delayed compared to the chronological age when analyzed using the Greulich and Pyle method.¹⁵ As a standard for comparison, the authors used an atlas that is comprised of plates of "typical" hand-wrist radiographs at 6-month intervals of chronological age. Each bone of the subject's hand-wrist is compared with the corresponding bone in the atlas and is assigned an age in months. All ages are averaged yielding the "mean age" of the individual. Clinically, this approach is often shortened to a gross assessment to find the best match of the individual with one of the plates. It is common, however, for normal children to show differences in this method.¹⁶ Okada et al⁵ found the bone age in NS patients compatible with their chronological age, but another evaluation method was used.

NS patients exhibit mental deficiency beyond a mild degree, which was noticed in the present study, as well as some systemic conditions like: (1) pulmonary stenosis; (2) interatrial communication; and (3) epilepsy. To institute preventive dental procedures, which are painless and can be done with short-term patient cooperation, an emphatic professional attitude is required.¹⁷ Even though general practitioners and some pediatric dentists are reluctant to treat special-needs patients,^{18,19} Noonan syndrome does not represent a significant impediment to a successful clinical attendance.

CONCLUSIONS

Noonan syndrome patients present a peculiar clinical picture. Health care providers must be able to deal with such particularities, especially the systemic aspects. Occlusal aspects, cephalometric measurements, and bone age seem to be the result of other factors and not a specific consequence of the genetic syndrome.

ACKNOWLEDGEMENTS

The authors wish to thank Dr. Andréa Vianna Tessler for her clinical support to the case study patients and to Dr. Patrícia Valéria Cunha Georgevich for her radiographic images, both Specialists in Pediatric Dentistry, School of Dentistry, at the University of São Paulo, .

REFERENCES

1. OMIM, Online Mendelian Inheritance in Man. Available at: "<http://www.ncbi.nlm.nih.gov/entrez/query.fcgi?db=omim>". Accessed September 20, 2006.
2. Tartaglia M, Mehler EL, Goldberg R, Zampino G, Brunner HG, Kremer H, van der Burgt I, Crosby AH, et al. Mutations in PTPN11, encoding the protein tyrosine phosphatase SHP-2, cause Noonan syndrome. *Nature Genet.* 2001;29: 465-8. Note: Erratum In: *Nat Genet.* 2001;29:491.
3. MeSH, Medical Subject Heading Database. Available at: "<http://www.ncbi.nlm.nih.gov/entrez/query.fcgi?db=MeSH>". Accessed September 20, 2006. Search for: "Noonan Syndrome".
4. Shah N, Rodriguez M, St. Louis D, Lindley K, Milla PJ. Feeding difficulties and foregut dysmotility in Noonan syndrome. *Arch Dis Child* 1999;81:28-31.
5. Okada M, Sasaki N, Kaihara Y, Okada R, Amano H, Miura K, Kosai K. Oral findings in Noonan syndrome: Report of a case. *J Oral Sci* 2003;45:117-21.
6. Sugar A, Ezsias A, Bloom AL, Morcos WE. Orthognathic surgery in a patient with Noonan syndrome. *J Oral Maxillofac Surg* 1994;52:421-5.
7. Marino B, Digilio MC, Toscano MD, Giannotti A, Dallapiccola B. Congenital heart disease in children with Noonan syndrome: An expanded cardiac spectrum with a high prevalence of atrioventricular canal. *J Pediatr* 1999;13:703-6.
8. Uçar T, Atalay S, Tekin M, Tutar E. Bilateral coronary artery dilatation and supravulvar pulmonary stenosis in a child with Noonan syndrome. *Pediatr Cardiol* 2005;26:848-50.
9. Witt DR, McGillivray BC, Allanson JE, Hughes HE, Hathaway WE, Zipursky A, Hall JG. Bleeding diathesis in Noonan syndrome: A common association. *Am J Med Genet* 1988;31:305.
10. Staudt JM, Van der Horst CMAM, Peters M, Melis P. Bleeding diathesis in Noonan syndrome. *Scand J Plast Reconstr Surg Hand Surg* 2005;39:247-8.
11. Torres-Carmona MA, Arenas-Sordo ML, Saavedra-Ontiveros D, Sánchez-Guerrero MC. Enfermedad periodontal en el síndrome de Noonan. *Bol Méd Hosp Infant Mex* 1991;48:271-4.
12. Nirmal T, Muthu MS, Arranganal P, Chennai. Noonan syndrome: A case report. *J Indian Soc Pedod Prev Dent* 2001;19:77-9.
13. Dajani AS, Taubert KA, Wilson W, Bolger AF, Bayer A, Ferrieri P, Gewitz MH, Shulman ST, et al. Prevention of bacterial endocarditis. Recommendations by the American Heart Association. *JAMA* 1997;11; 227:1794-801.
14. Hayes PA, Fasules J. Dental Screening of pediatric cardiac surgical patients. *J Dent Child* 2001;68:255-8.
15. Greulich WW, Pyle SI. *Radiographic Atlas of Skeletal Development of Hand and Wrist*. 2nd ed. Stanford, Calif: Stanford University Press; 1959.

16. Cao F, Huang HK, Pietka E, Gilsanz V. Digital hand atlas and Web-based bone age assessment: system design and implementation. *Comput Med Imaging Graph* 2000; 24:297-307.
17. Yilmaz S, Özlü Y, Ekuklu G. The effect of dental training on the reactions of mentally handicapped children's behavior in the dental office. *J Dent Child* 1999;66:188-9.
18. Waldman HB, Swerdloff M, Perlman SP. Children with mental retardation: Stigma and stereotype images are hard to change. *J Dent Child* 1999;66:343-7.
19. Milano M, Seybold SV. Dental care for special-needs patients: A survey of Texas pediatric dentists. *J Dent Child* 2002;69:212-5.

Copyright of Journal of Dentistry for Children is the property of American Academy of Pediatric Dentistry and its content may not be copied or emailed to multiple sites or posted to a listserv without the copyright holder's express written permission. However, users may print, download, or email articles for individual use.