

Reconstruction and Recovery of Hemisectioned Teeth Using Direct Fiber-reinforced Composite Resin: Case Report

Zuhal Kırzioğlu, PhD

M. Semra Özay Ertürk, PhD

ABSTRACT

An increased wish by patients to maintain their dentition and recent advances in dentistry have led to the treatment and preservation of teeth that once would have been removed. Consequently, hemisections, root amputations, and bisections are procedures frequently used. The prognosis of endodontically treated teeth depends on the type of reconstruction as well as the success of the endodontic treatment. Along with technological improvements in adhesive resins, cements, and composite restoratives, the evolution of fiber-reinforced posts enables the rehabilitation of endodontically treated teeth with greater esthetics and virtually no predisposition to root fracture. The purpose of this report was to describe the endodontic, surgical, and restorative treatments of a mandibular first molar with an endodontically and periodontally diseased mesial root, for functional, orthodontic, and aesthetic reasons. This case report shows that the clinical application of fiber-reinforced composite resins in hemisectioned teeth may be a treatment choice for highly damaged teeth with endodontic and/or periodontal lesions. It also emphasizes the advantages of the elimination of orthodontic and prosthetic treatment needs by different treatment strategies, especially in adolescent patients. (J Dent Child 2008;75:95-8) Received January 9, 2007, Last Revision March 9, 2007 | Revision Accepted March 9, 2007.

KEYWORDS: HEMISECTION, FIBER-REINFORCED POST, FIBER-REINFORCED COMPOSITE RESIN, RIBBOND, TEETH PERMANENT

Advances in dentistry, as well as the wish patients to maintain their dentition, have led to the treatment and preservation of teeth that once would have been removed. Thus, hemisections, root amputations and bisections are treatments frequently used. Hemisection, which is commonly used, embodies 2 distinct therapeutic procedures root separation, and root removal. Periodontally and/or endodontically affected teeth with severe bone loss may well be retained by the removal of one or more of their roots.¹

The prognosis of endodontically treated teeth depends on the type of reconstruction as well as the success of the endodontic treatment. The amount of tooth structure remaining after hemisection and/or endodontic therapy and post preparation is of prime importance, as the strength and resistance to root fracture of an endodontically treated

tooth is directly related to the amount of residual dentine.² Therefore, restoration of root-filled and hemisectioned teeth is a critical final step for success of the treatment.

Traditionally, many root-filled teeth have been restored in conjunction with a post in the belief that they were reinforced, although there is little evidence to support this procedure.³ In fact, restoration of a tooth with a post has been shown by various authors to weaken the tooth rather than strengthen it.^{4,5} Along with technological improvements in adhesive resins, cements, and composite restoratives, the evolution of fiber-reinforced posts enables the rehabilitation of endodontically treated teeth with greater esthetics and virtually no predisposition to root fracture.^{6,7}

The purpose of this report was to describe the endodontic, surgical, and restorative treatments of a mandibular first molar tooth with an endodontically and periodontally diseased mesial root, for functional, orthodontic, and aesthetic reasons. This report emphasizes the advantages of the elimination of orthodontic and prosthetic treatment needs by means of different treatment strategies, especially in adolescent patients.

Dr. Kırzioğlu is professor and Dr. Ertürk is research assistant, both in the Department of Pediatric Dentistry, Faculty of Dentistry, Süleyman Demirel University, Isparta, Turkey. Correspond with Dr. Kırzioğlu at semrasila@gmail.com.

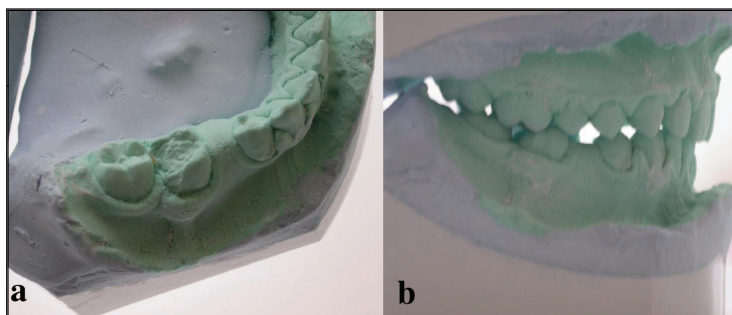


Figure 1.

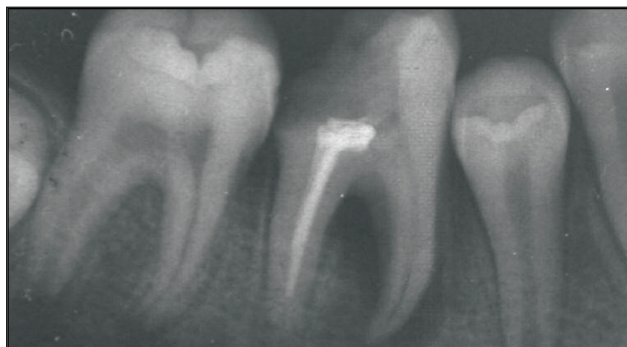

Figure 2.

CASE REPORT

A 15-year-old boy with a noncontributory medical history was referred to our pediatric dentistry clinic for treatment of his aching permanent molar. The patient complained of sensitivity on percussion, swelling, tooth mobility, and intermittent pain.

Intraoral examination revealed profound disto-occlusal caries, vestibular abscess of tooth no. 30, acute lymph adenopathy were observed. Tooth no. 29 was missing, and there was not enough space in the arch for this tooth to erupt (Figures 1a and 1b).

Radiographic examination revealed that the mesial root of tooth no. 29 had a widespread periapical lesion with bone loss reaching furcation, but the distal root was healthy. Besides this, tooth no. 30 might not have erupted due to space loss, despite its adequate root formation.

It was decided that, instead of extracting tooth no. 29, an attempt should be made to partially preserve it by hemisection and also to enable the eruption of tooth no. 29 without any orthodontic interference. The authors decided that the tooth's mesial half would be removed, followed by restoration with an intracanal application of fiber-reinforced and coronal application of a condensable hybrid composite resin.

The patient and his parents consented to the proposed treatment plan after being comprehensively informed about the treatment's methods and risks. The tooth was isolated with a rubber dam, the access cavity was prepared, and the pulp was extirpated. The pulp chamber and root canals were irrigated with sodium hypochlorite (2%). Oral antibiotic therapy was initiated, and oral hygiene instructions were given.

After the tooth was observed to be asymptomatic, the distal root canal filling was introduced by lateral

condensation with gutta percha and a calcium hydroxide-containing sealer (Sealapex, Kerr, Langenau, Germany; Figure 2). The mesial root canals were frequently irrigated with 5% sodium hypochlorite solution, and the tooth was temporarily restored.

Hemisection was performed 3 weeks later, and the coronal tooth portion was filled temporarily with glass ionomer cement (Ketac-Cem, 3M ESPE, St Paul, Minn) until the application of intracanal fiber-reinforced composite resin and the final coronal restoration (Figures 3 and 4).

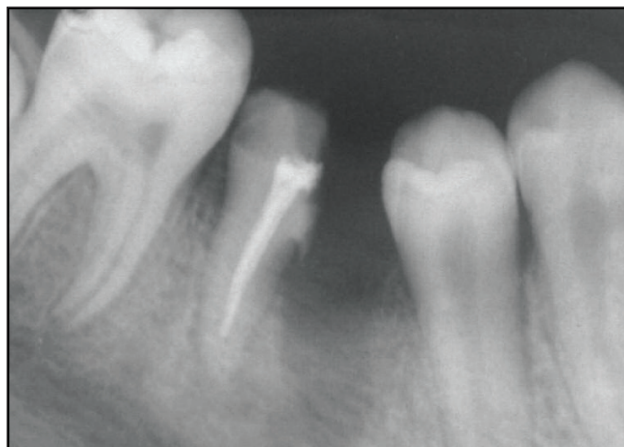

Figure 3.

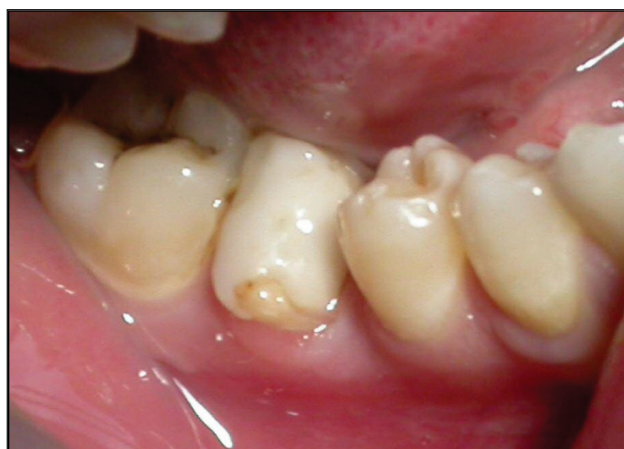

Figure 4.

Healing was uneventful, and tooth no. 29 was observed to erupt following the hemisection procedure. Approximately two thirds of the root canal filling of tooth no. 30 was removed and a thin layer of glass ionomer cement (Ketac-Cem, 3M ESPE) was placed (Figures 5 and 6). The root canal was irrigated and dried, and all surfaces were treated with 34.5 % phosphoric acid (Vococid, Voco, Cuxhaven, Germany) for 15 seconds and washed thoroughly for over 15 seconds. Subsequently, sterile paper points were used to dry the surface. The required 2-mm-wide length of Ribbond (Ribbond Inc, Seattle, Wash) was cut with the special scissor supplied by the manufacturer to prevent unraveling and then saturated with a few drops of bonding agent

(Scotchbond Multi-Purpose, 3M ESPE Dental AG, Seefeld, Germany).

The Ribbond post was prepared and applied by following the manufacturer's instructions. Chemically cured translucent composite resin (Alfacomp, Voco, Germany) was used to fix the Ribbond post into the root canal. The coronal part of Ribbond was covered with a light-cured condensable hybrid composite resin (Surefil, Dentsply-De-Trey, Germany), and a core was built up. Finally, the coronal restoration was finished (Figures 7a and 7b). To decrease the extra space in the dental arc for the hemisected tooth, the overcontoured final restoration at its mesial and distal surfaces was stripped regularly.

The patient was pleased with the function and esthetics of his treated tooth, and patient's orthodontic and prosthetic treatment needs were eliminated and tooth no. 29 was now able to erupt without any orthodontic interference.

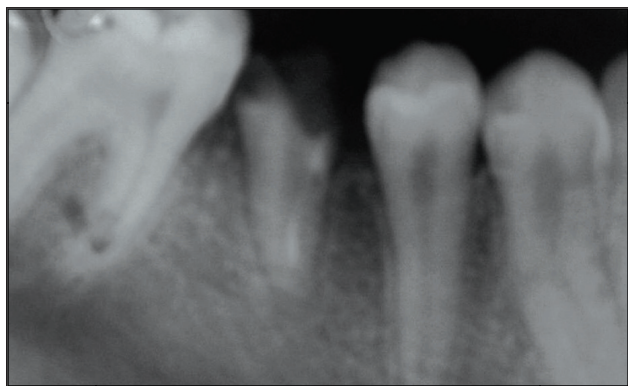


Figure 5.

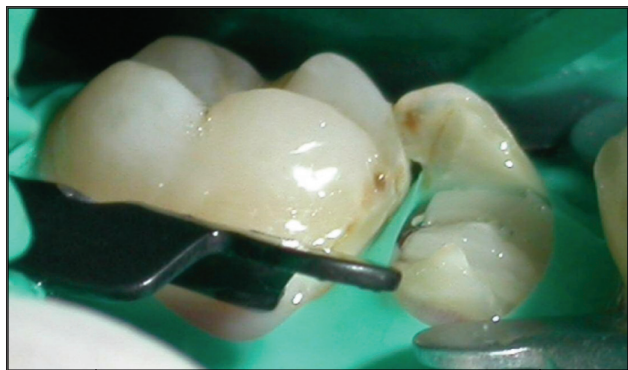

Figure 6.

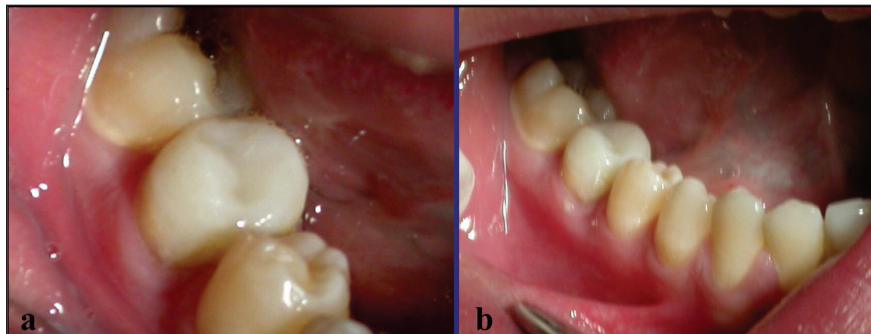


Figure 7.

The patient was followed-up for 12 months, with appointments given at 3-month intervals, and it was observed that there was no symptom relevant to tooth no. 30. Figure 8 showed the periapical radiograph of tooth no. 30 taken 12 months later.

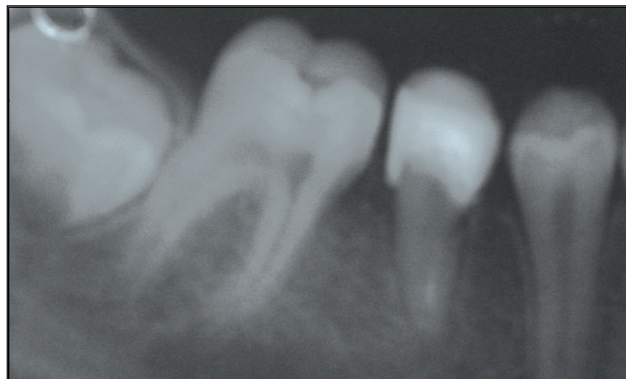

Figure 8.

DISCUSSION

Hemisection of multirooted teeth may be a viable treatment option when widespread periapical lesion and bone loss reaching furcation has occurred at one root and the other root is healthy. There are many reports of successful hemisection cases aimed at preserving multirooted teeth in the literature.^{8,10} This treatment option will maintain the natural dentition by preserving the health of the teeth with similar endodontic and periodontal problems.

Ribbond is a biocompatible, esthetic material made from a high-strength polyethylene fiber. The various advantages of this material include ease of adaptation to dental contours, ease of manipulation during the bonding process, and acceptable strength because of good integration of fibers with the composite resin, which leads to good clinical longevity.¹¹

Because of these advantages, Ribbond was preferred for post preparation and reconstruction of this tooth.

Preserving the natural dentition is important, especially during the adolescence age period, since several long-term developmental processes take place in the maxillofacial area. Invasive treatment alternatives like tooth extraction during this period could lead to complicated orthodontic and/or prosthetic treatments.

REFERENCES

1. Ingle JI, Bakland LK. *Endodontics*. Baltimore, Md: Williams & Wilkins; 1994:21.
2. Solomon CS, Osman YI. Aesthetic restoration of the compromised root: A case report. *SADJ* 2003;58:373-6.
3. Gusy GE, Nicholas JI. In vitro comparison of intact endodontically treated teeth with and without endo-post reinforcement. *J Prosthet Dent* 1979;42:39-44.
4. Lu YC. Comparisons of the fractures of pulpless teeth. *Clin Dent J* 1987;6:26-31.
5. Trope M, Maltz DO, Tronstad L. Resistance to fracture of restored endodontically treated teeth. *Endod Dent Traumatol* 1985;1:108-11.
6. Grandini S, Goracci C, Tay FR, et al. Clinical evaluation of the use of fiber posts and direct resin restorations for endodontically treated teeth. *Int J Prosthodont* 2005;18:399-404.
7. Monticelli F, Grandini S, Goracci C, et al. Clinical behavior of translucent-fiber posts: A 2-year prospective study. *Int J Prosthodont* 2003;16:593-6.
8. Burke FJ, Crooks L. Reconstruction of a hemisectioned tooth with an adhesive ceramic restoration using intraradicular retention. *Dent Update* 1999;26:448-52.
9. Haueisen H, Heidemann D. Hemisection for treatment of an advanced endodontic-periodontal lesion: A case report. *Int Endod J* 2002;35:557-72.
10. Haskell EW, Stanley HR. Vital hemisection of a mandibular second molar: A case report. *J Am Dent Assoc* 1981;102:503-6.
11. Strassler HE, Haeri A, Gulta JP. New-generation bonded reinforcing materials for anterior periodontal tooth stabilization and splinting. *Dent Clin North Am* 1999;43:106-25.

Copyright of Journal of Dentistry for Children is the property of American Academy of Pediatric Dentistry and its content may not be copied or emailed to multiple sites or posted to a listserv without the copyright holder's express written permission. However, users may print, download, or email articles for individual use.