

# Intraoral Findings of Papillon–LeFevre Syndrome

**Emin Murat Canger, DDS, PhD    Peruze Celenk, DDS, PhD**  
**Inci Devrim, DDS, PhD    Murat Yenisey, DDS, PhD**  
**Omer Gunhan, DDS, PhD**

## ABSTRACT

Papillon-LeFevre syndrome (PLS) is a rare autosomal, recessive condition characterized by hyperkeratosis of palms and soles of the feet and elbows and by rapid formation of periodontitis and hypermobility, migration and exfoliation of the teeth of primary and permanent dentition. The purpose of this report was to describe the case of an 8-year-old boy who presented to the Department of Oral Diagnosis and Radiology of Faculty of Dentistry of Ondokuz Mayıs University with a chief complaint of mobility and rapid loss of teeth. Hyperkeratosis of palms and soles were realized. His gingivae were hyperemic and edematous, and the teeth were mobile. Histopathological examination of the specimen taken from the thickened skin was reported to be consistent with PLS. All teeth with poor prognosis were extracted and extensive periodontal therapy was administered, and a special denture was constructed. (J Dent Child 2008;75:99-103) Received January 26, 2007 | Last Revision February 16, 2007 | Revision Accepted February 17, 2007.

**KEYWORDS:** PAPILLON-LEFEVRE SYNDROME, PALMOPLANTAR HYPERKERATOSIS, PREMATURE TOOTH LOSS, PERIODONTAL DESTRUCTION

Papillon-LeFevre syndrome (PLS) was first described in 1924. It is a rare autosomal recessive situation and have an incidence of between 1 and 4 persons per million.<sup>1-5</sup>

PLS is characterized by hyperkeratosis of palms and soles of the feet, elbows, and knees and with distinctive intraoral findings with rapid destruction of alveolar bone and periodontium of both primary and secondary dentition. At the beginning, thickening of skin may be regarded as a dermatological problem. After the loss of teeth, dermatological manifestations will continue to exist. Skin lesions are present as well demarcated red and scaly patches on the affected skin. Lesions affect the palms extending to the thenar eminences and the volar wrist. The soles are more

severely affected than the other regions. Some other findings of the syndrome are retardation of somatic development, follicular hyperkeratosis, nail dystrophy, hyperhidrosis and liver abscess, and calcifications in the falx cerebri and choroid plexus.<sup>1-8</sup>

The aetiology of PLS is not completely understood. Both genders are equally affected, which has no racial predominance. In particular ethnic groups with high incidence of consanguinity marriages, the prevalence becomes higher.<sup>2-6</sup> Anatomical defects, microbial factors, viral agents, and host response are suspected as causative factors.<sup>(1-6)</sup> Some aetiological specific subgingival pathogens are *Actinobacillus actinomycetemcomitans* (higher prevalence), *Porphyromonas gingivalis*, *Fusobacterium nucleatum*, *Bacterioides forsythus*, *Troponema denticola* and *Prevotella intermedia*.<sup>2-6,8,9</sup>

The purpose of this article is to present a PLS case which was diagnosed with intraoral signs and treated periodontally and prosthetically.

## CASE REPORT

A 8-year-old-boy was referred to Department of Oral Diagnosis and Radiology of Faculty of Dentistry of Ondokuz

**Dr. Canger is research assistant, and Dr. Celenk is professor, both in the Department of Oral Diagnosis and Radiology and Dr. Devrim is assistant associate professor, Department of Periodontology, and Dr. Yenisey is assistant associate professor, Department of Prosthodontics, all in the Faculty of Dentistry, Ondokuz Mayıs University, Samsun, Turkey. Dr. Gunhan is professor, Department of Pathology, Gulhane Military Academy of Medicine, Ankara, Turkey. Correspond with Dr. Canger at mcanger@gmail.com.**

Mayis University, Samsun, Turkey, with a chief complaint of teeth mobility and rapid teeth loss that caused nutritional problems.

The patient had lost his primary teeth at the age of 3. His father, informed that hyperkeratotic lesions had been present since 1 year of age of and were occasionally exacerbated. The parents were cousins, and the patient had 4 siblings. The dental structure and the periodontal condition of his parents and siblings were normal.

Extraoral examination revealed hyperkeratosis of the palms and soles. The nails were also hypoplastic. (Figure 1a, 1b)

Intraoral examination revealed that only 10 permanent teeth were present in the mouth: permanent maxillary centrals, permanent maxillary molars, permanent mandibular centrals, permanent mandibular laterals, and permanent mandibular molars.

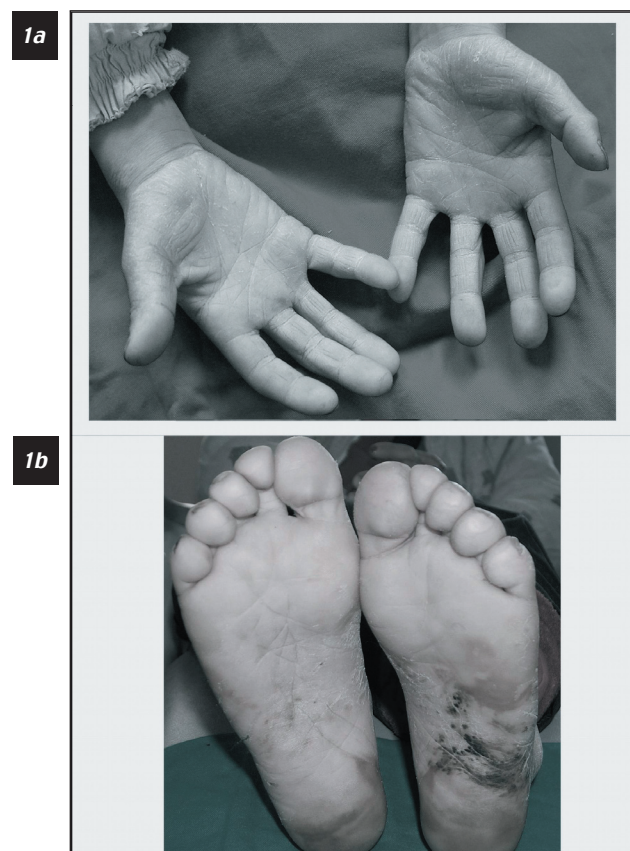The gingivae were edematous and hyperemic and bled easily upon probing. Sulcular purulante exudate was also present. The pocket depths were measured at 6 sides of the teeth by using a Williams probe. They were between the range of 3,5 mm.-8,5 mm. (Figure 2a, 2b)

Radiographic examination indicated that severe alveolar bone loss affecting all teeth and the appearance of “floating in the air” around the permanent maxillary molars, and permanent mandibular left first molar teeth. In addition it was realized that permanent maxillary lateral incisors, permanent maxillary and mandibular canines, permanent

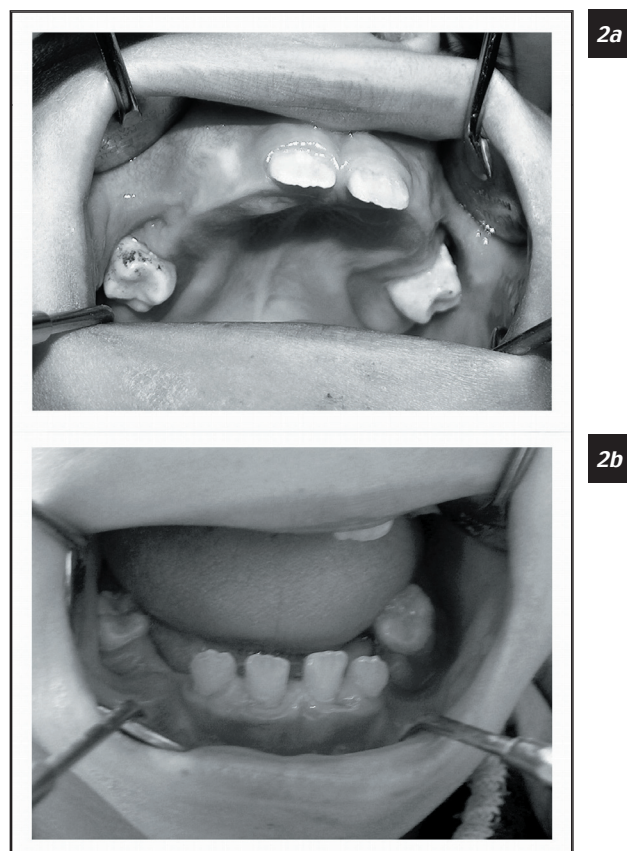
maxillary and mandibular premolars, and permanent maxillary and mandibular molars were in process of eruption. (Figure 3)

Presence of the skin lesions combined with periodontitis and premature primary tooth loss, indicated Haim-Munk and PLS as the possible diagnoses. Haematological investigation included full blood count (CBC), serum calcium, phosphate, alkaline phosphatase (ALP) levels to check the patient's blood profile. The hematocrit, mean corpuscular volume (MCV), and mean corpuscular hemoglobin (MCH) values were lower than normal. ALP and phosphate results, however, were within the normal limits. These results helped eliminate the conditions such as hypophosphatasia, leukemia, various neutropenias. Also, since the dermatological condition of Haim-Munk syndrome patients is more severe with a later onset, the initial diagnose was thought as PLS. To confirm this, specimens were taken from gingival mucosa and hyperkeratotic skin. The histopathological examination of the skin specimens revealed acantosis, papillomatosis and evident parakeratosis and orthokeratosis.

Additionally, focal inflammatory cell infiltration in the dermis consisted of edematous connective tissue and lymphocytes was observed. This histopathological appearance was consistent with PLS. Histopathological examination of gingiva also revealed active-chronic inflamed tissue. Histopathological examination also supported the initial diagnose. (Figure 4)

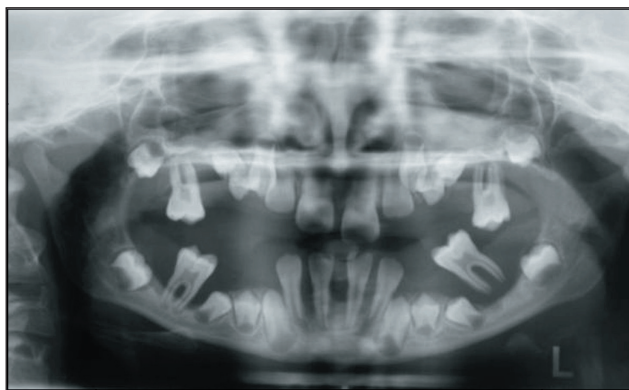


**Figure 1a, 1b.** Kerathosis of the palms of the both hands and soles of the both feet.

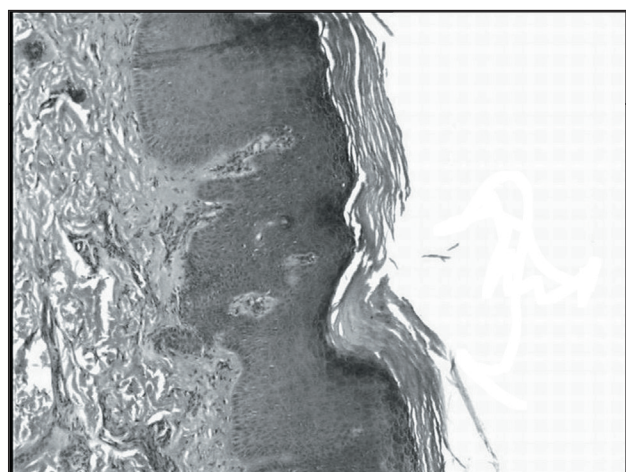


**Figure 2a, 2b.** Appearance of the upper and lower jaw indicating present teeth and severe periodontal status.

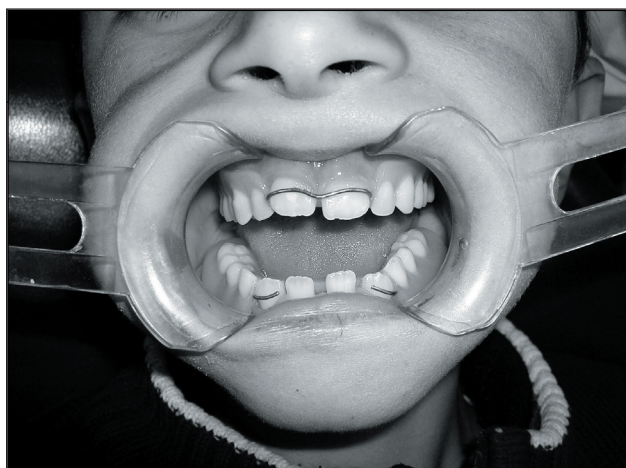



**Figure 3.** Orthopantomograph indicating multifocal sites of bone loss in all four quadrants and eruption process of the non-erupted permanent teeth.



**Figure 4.** Photomicrograph of the skin specimens showing evident parakeratosis and orthokeratosis (HEX100).



**Figure 5.** The specially designed and constructed partial denture.

The teeth with poor prognosis (permanent maxillary molars, and permanent mandibular left first molar teeth) were extracted and periodontal therapy was initiated-consisting of scaling, root planning under local anesthesia, 0.12% chlorhexidine mouth wash twice daily and detailed oral hygiene instructions. This treatment regime was repeated

three more times. Broad spectrum antibiotics (a combination of amoxicilline and metronidazole: 250 mg of each, three times daily for 10 days) were also prescribed. To assure function and esthetic, a partial denture was constructed using heat polymerized acrylic resin (Paladent® 20, Heraeus Kulzer GmbH, Hanau/Germany) with clasps.

The patient was followed-up monthly. After 3 months, he adapted well to the dentures. Eruption of the permanent teeth was controlled radiographically at every follow-up session and necessary adjustments were made. For the skin lesions, he was also directed to the Department of Dermatology, Faculty of Medicine of Ondokuz Mayıs University. (Figure 5)

## DISCUSSION

According to Haneke<sup>13</sup>, three criteria are used to classify a case as PLS: palmoplantar hyperkeratosis, loss of permanent and primary teeth, and autosomal recessive inheritance. Our case matched the first 2 criteria but we could not confirm the third criterion due to lack of cooperation with the family. Since there is parental consanguinity in our case, the parents can be assumed to be recessive carriers, because there is a 25% chance of offspring of recessive carrier parents have PLS<sup>2</sup>. Consanguinity between parents has been reported in approximately one third of cases studied.<sup>4,8</sup>

In PLS patients, skin lesions are present from 6 months to 3 years of age, approximating the time of primary tooth eruption. Soles of the feet are also frequently affected more severely than the other regions.<sup>1,2,6</sup> In our case, the skin lesions had begun to appear at 1 year of age.

The pathognomic dental findings of PLS are looseness, hypermobility, drifting, migration and exfoliation of the teeth without sign of root mobility. Development and eruption of the primary dentition is completed uneventfully, at the age of 2½ to 3, when gingivae become erythematous and edematous and ulceration can potentially happen. This situation is followed by severe and rapid form of periodontitis. At 4 or 5 years of age, all primary teeth are exfoliated or extracted. With the loss of primary dentition, gingivae return to their normal healthy state. After the permanent teeth erupt, the same cycle of events begins. By 13 to 15 years of age, all the permanent teeth are lost.<sup>1,2,4,8,9,11,12</sup> The patient in the present case study had also lost his all primary teeth when he was 3 years old.

The recently identified genetic defect in PLS has been mapped to the chromosome 11q14 and involves mutation on gene encoding dipeptidyl peptidase I (DDPI), formerly known as cathepsin C, lack of which host response against bacteria in dental plaque will be reduced.<sup>1,3,4,6,13</sup>

There will be increased susceptibility to infections like otitis media, pneumonia, bronchitis, tonsillitis, frunculosis and pyogenic infections of the skin due to some dysfunction of lymphocytes and leukocytes. Approximately 20-25% of patients show this sensitivity.<sup>2,6,11,13</sup> Our patient also had an unidentified skin lesion that was treated at 2 years of age.

**Table. Differential diagnose of PLS with the conditions characterized with the premature loss of primary/permanent teeth**

Condition	Clinical Findings	Miscellaneous Findings
Acrodynia	Cold, clammy skin on hands, ears, nose, feet; ulcerative gingivitis, premature loss of teeth	Severe sweating, hypertension, tachycardia
Ehlers-Danlos Syndrome Type VIII	Soft, hyperextensible skin; hypermobile joints; early-onset periodontal disease	Pulp stones on dental radiographs
Haim-Munk Syndrome	More severe skin manifestations than PLS with later onset; periodontium is less severely affected; arachnodacty, atrophic changes of nails	Mutations in Cathepsin G
Histiocytosis X	Ulcerative or proliferative gingival lesions; advanced alveolar bone loss ; loosening of teeth	Proliferation of histiocyte-like cells (Langerhans cells)
Hypophosphatasia	Rapidly destructive periodontal disease, lack of cementum production in primary teeth	Decrease in serum alkaline phosphates level
Leukemia	Ulceration of gingival mucosa; diffuse gingival enlargement in the myelomonocytic type; infiltration of the periapical tissues, simulating periapical inflammatory disease	Reduction in the number of normal red and white blood cells
Neutropenias	Ulcerations involving gingival mucosa; rapid periodontal destruction	Decrease in the number of circulating neutrophils
Acatalasia	Progressive gangrenous lesions involving gingival and periodontal tissues	Deficiencies in the catalase enzyme of red blood cells
Chediak-Higashi Syndrome	Hypopigmentation in skin and hair, recurrent bacterial infections of the skin and respiratory tract; neuropathy; ataxia; gingival-periodontal disease	Giant blue-gray granules in the cytoplasm of granulocytes

The following treatment regimens have been suggested for PLS;

- 1) Primary teeth are extracted to obtain a pathogen free environment for permanent teeth to erupt. If deciduous teeth are removed after the eruption of some permanent teeth, however, problems tend to persist because erupted permanent teeth can provide the causative pathogens and endanger the survival of permanent teeth. This also allows an appropriate base for subsequent constructions of dentures.
- 2) A combined regimen of conventional periodontal therapy (correction of oral hygiene, scaling, curettage) and appropriate antibiotics is also recommended. In patients exhibiting resistance to antibiotics, however, continued breakdown of periodontium may be seen, antibiotic prescription is shown to be advantageous.
- 3) Prescription of synthetic retinoids (analogues of vitamin A) can have positive effects also on periodontal disease.
- 4) Prosthodontic rehabilitation may be necessary. This is an age-specific approach involving placement of complete or partial dentures initially, and later implant-supported dentures constructed in the future.<sup>2,5,12-16</sup>

Cagli et al<sup>5</sup>, Lundgren and Renvert<sup>8</sup>, Mahajan et al<sup>13</sup>, Ahuja et al<sup>15</sup>, and Veena and Parkash<sup>16</sup> treated their cases according to the aforementioned periodontal treatment regime and Fardal et al<sup>11</sup> added surgical periodontal approach, and the results were reported to be satisfactory. Ulbro et al<sup>12</sup> indicated that the age treatment was an important factor in the success of treatment and the patients treated at earlier ages would show significantly fewer signs of periodontal diseases and lost fewer permanent teeth than the patients who begun treatment at an older age. In addition, Mahajan et al<sup>13</sup> and Veena and Parkash<sup>16</sup> constructed dentures, and their patients reportedly adapted well to their dentures. We preferred a combination of extraction, periodontal therapy and prosthetic rehabilitation.

Differential diagnosis of PLS must be done to differentiate periodontitis and systemic diseases associated with periodontitis, such as Haim-Munk syndrome; histiocytosis X, hypophosphatasia, leukemia, various neutropenias, acatalasia, Chediak-Higashi syndrome, and Ehlers-Danlos syndrome Type VIII<sup>1-3,7,17,18</sup> (Table 1).

## CONCLUSION

Since the aetiology of PLS is unknown, it's diagnose and treatment is difficult. Several treatment regimens have been recommended, but a mutually understood protocol has not yet been established yet. In this paper, the patient was treated with a combined regime and still being followed-up. He appears to be free of problems and to have adapted to dentures.

## REFERENCES

1. Gorlin RJ, Cohen MM, Hennekan RC. *Syndromes of head and neck*. 4<sup>th</sup> ed. New York: Oxford University Press; 2001:1101-3.
2. Patel S, Davidson LE. Papillon-LeFevre syndrome: a report of two cases. *Int J Paed Dent* 2004;14:288-94.
3. Drucker DB, Marshall R, Bird PS. Aetiology of Papillon-LeFevre syndrome. *Anaerobe* 2001;7:151-8.
4. Hattab FN, Amin WA. Papillon-LeFevre syndrome with albinism: a review of the literature and report of 2 brothers. *Oral Surg Oral Med Oral Pathol Oral Radiol Endod* 2005;100:709-16.
5. Cagli NA, Hakki SS, Dursun R, Toy H, Gökalp A, Ryu OH, et al. Clinical, genetic, and biochemical findings in two siblings with Papillon-LeFevre syndrome. *J Periodontol* 2005; 76:2322-9.
6. Hattab FN, Rawashdeh MA, Yasin OM; Al-Momani AS, Al-Ubosi M. Papillon-LeFevre syndrome: a review of the literature and report of 4 cases. *J Periodontol* 1995;66:413-20.
7. Sollecito TP, Sullivan KE, Pinto A, Steward J, Korostoff J. Systemic conditions associated with periodontitis in childhood and adolescence. *Med Oral Pathol Oral Cir Bucal* 2005;10:142-50.
8. Lungren T, Renvert S. Periodontal treatment of patients with Papillon-LeFevre syndrome: a 3-year follow-up. *J Clin Periodontol* 2004;31:933-38.
9. Fıratlı E, Gürel N, Efeoğlu A, Badur S. Clinical and immunological findings in 2 siblings with Papillon-LeFevre syndrome. *J Periodontol* 1996;67:1210-5.
10. Haneke E. The Papillon-LeFevre syndrome: keratosis palmoplantaris with periodontopathy: report of a case and review of the cases in the literature. *Hum Genet* 1979; 51:1-35.
11. Fardal Q, Drangsholt E, Olsen I. Palmar plantar keratosis and unusual periodontal findings. Observations from a family of 4 members. *J Clin Periodontol* 1998;25:181-84.
12. Ulbro C, Brown A, Twetman S. Preventive periodontal treatment regimen in Papillon-LeFevre syndrome. *Pediatr Dent* 2005;27(3): 226-32.
13. Mahajan VK, Thakur NS, Sharma NL. Papillon-LeFevre syndrome. *Indian Pediatr* 2003;40:1197-200.
14. Porter S. Letter to editor. Cathepsin C involvement in the aetiology of Papillon-LeFevre syndrome. *Int J Paed Dent* 2004;14:466-7.
15. Ahuja V, Shin RH, Mudgil A, Nanda V, Schoor R. Papillon-LeFevre syndrome: a successful outcome. *J Periodontol* 2005;76:1996-2001.
16. Veena J, Gupta R, Parkash H. Prosthodontic rehabilitation of Papillon-LeFevre syndrome: a case report. *J Ind Soc Pedod Prev Dent* 2005;23:96-8.
17. Neville BW, Damm DD, Allen CM, Bouquot JE. *Oral & maxillofacial pathology*. 2<sup>nd</sup> ed. Philadelphia: WB Saunders Co.; 2003:273, 505-6, 510-5.
18. Greenberg MS, Glick M. *Burket's oral medicine. Diagnosis and treatment*. 10<sup>th</sup> ed. Hamilton, Ontario: BC Decker Inc; 2003:441-2, 460.

Copyright of Journal of Dentistry for Children is the property of American Academy of Pediatric Dentistry and its content may not be copied or emailed to multiple sites or posted to a listserv without the copyright holder's express written permission. However, users may print, download, or email articles for individual use.