

Multidisciplinary Treatment of a Subgingivally Fractured Tooth with Indirect Composite Restoration: A Case Report

Ayca T. Ulusoy, DDS, PhD **Emine Sen Tunc, DDS, PhD**
Feride Cil, DDS **Devrim İsci, DDS, PhD**
Muge Lutfioglu, DDS, PhD

ABSTRACT

In pediatric patients, anterior teeth with fractures that extend subgingivally require a complex treatment plan that addresses biologic, esthetic, and functional factors, such as mastication and speech. The purpose of this clinical report was to describe a technique using indirect composite restoration to restore a subgingivally fractured permanent maxillary right central incisor in a 10-year-old boy. Due to the complex nature of the treatment, a multidisciplinary approach was used to restore the tooth. The crown fragment was removed, and endodontic treatment was performed. The tooth was then extruded orthodontically. A glass fiber post was placed to improve retention, and an indirect composite restoration was placed. A clinical and radiographic evaluation at a follow-up appointment 1 year later confirmed that the technique used in this case can be a good option for restoring anterior teeth with subgingival fractures. (J Dent Child 2012;79(2):79-83)

Received June 17, 2010; Last Revision May 23, 2011; Revision Accepted May 23, 2011.

KEYWORDS: CROWN-ROOT FRACTURE, ORTHODONTIC EXTRUSION, INDIRECT COMPOSITE, GLASS-FIBER POST

Trauma with accompanying fracture of permanent incisors occurs more frequently in children than adults, more likely as a result of sport activities, car and bicycle accidents, fights, or being struck with foreign bodies.¹ Crown root fractures comprise up to 5% of all traumatic injuries and are usually caused by direct trauma to the anterior teeth. Maxillary anterior teeth are most often affected due to their anterior and labial relationship with the mandibular incisors.² Teeth fractures below the gingival attachment may include enamel, dentin, and/or cementum, and pulpal involvement frequently exists.

Indication of the type of treatment depends on the level of the fracture line and the amount of remaining

tooth structure.³ The treatment strategy for subgingivally fractured teeth is complex, due to difficulties preserving the gingival biologic width.⁴ The treatment decisions in pediatric patients should be made according to available technical capability, behavior management, continuing growth guidance, and motivation of the patients throughout a comprehensive and multidisciplinary treatment plan.⁵

The purpose of this report was to present a case of multidisciplinary management of a subgingivally fractured tooth using orthodontic extrusion, periodontal surgery, and a final restoration with indirect composite restoration.

CASE REPORT

A 10-year-old boy was referred to the Pediatric Dentistry Clinic of Ondokuz Mayıs University Faculty of Dentistry, Samsun, Turkey, with a chief complaint of a subgingivally fractured permanent maxillary right central incisor as a result of a bicycle accident 1 month previously. His medical history was noncontributory. Reportedly, he had

Drs. Ulusoy and Tunc are assistant professors, and Dr. Cil is a research assistant, Department of Pedodontics; Dr. İsci is an assistant professor, Department of Orthodontics; and Dr. Lutfioglu is an assistant professor, Department of Periodontics, all in the Faculty of Dentistry, Ondokuz Mayıs University, Samsun, Turkey.

Correspond with Dr. Ulusoy at aycaulusoy@yahoo.com

been referred to the local dental office where he received an initial pulpectomy treatment and the mobile coronal portion of the permanent maxillary right incisor was splinted to its adjacent teeth using composite resin (Figure 1a). During the recall appointment, the dentist realized there was a subgingival oblique fracture in the permanent maxillary right central incisor and suggested that further treatment should be performed by a specialist. Upon clinical examination, the crown fragment of the subgingivally fractured maxillary right incisor was mobile but still connected to the tooth by some dentin and cementum on both palatal and buccal aspects. Additionally, the marginal gingiva was inflamed due to poor oral hygiene. The tooth was tender to palpation. Periapical radiographs taken from different angulations revealed an oblique crown-root fracture that extended approximately one-third of the entire root length; however, there was no apparent periapical pathology (Figure 1b). The apices of the central incisors were nearly completely formed. Clinical and radiographic findings showed no pathological signs in the adjacent teeth.

It was decided to initiate orthodontic extrusion of the root in order to facilitate placement of a coronal restor-

ation. The patient and his mother were informed about the advantages and possible complications of the treatment plan, such as loss of the coronal tooth fragment due to repeated trauma or chewing. Apexification was performed temporarily with a radiopaque calcium hydroxide paste (Sultan Healthcare Inc, Englewood, NJ, USA), as apical root formation was not yet complete. Since only the coronal portion was mobile, the composite splint was left in place throughout the permanent endodontic treatment to prevent contamination of the root canal by blood and/or oral fluids. After 3 months an apical stop was created and the root canal was filled with gutta percha and AH Plus Sealer (Dentsply, Konstanz, Germany). The adhesive splint and crown fragments were removed (Figure 2).

Orthodontic extrusion of the fractured permanent maxillary central incisor was required to move the palatal fracture line approximately 3 mm above the alveolar crest in order to regain the lost biologic width. For the orthodontic extrusion, 0.22 MBT brackets (GAC International, Bohemia, NY, USA) were attached on the permanent maxillary right lateral incisor, permanent maxillary left central incisor, and permanent maxillary left lateral incisor teeth. After a 0.019 x 0.025 inch rectangular stainless steel arch wire was bent to achieve the tooth extrusion, a steel "J" hook was cemented in the root canal and the power chain was applied axially from

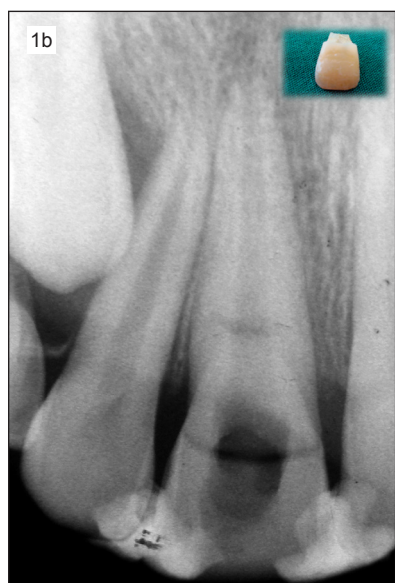
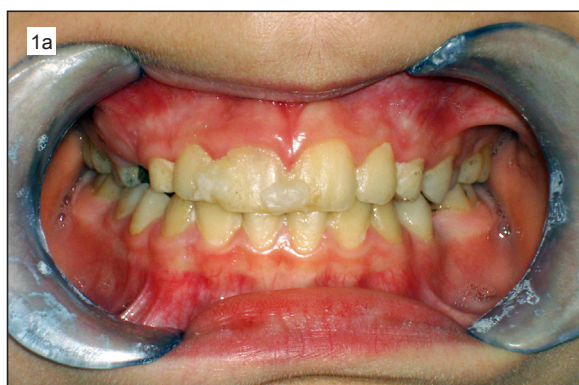

Figure 1. (a) Preoperative clinical view. (b) Radiographic view of the traumatized incisor; Inner picture: The extracted crown fragment.

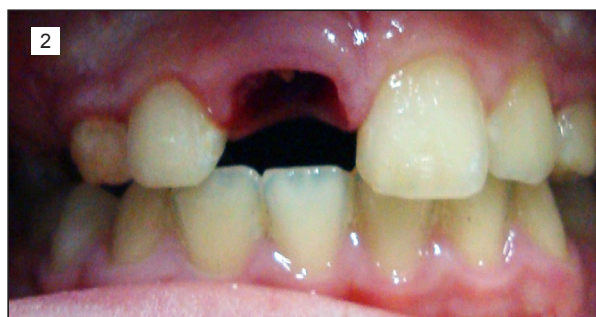

Figure 2. Clinical view after removal of the adhesive splint and crown fragment.

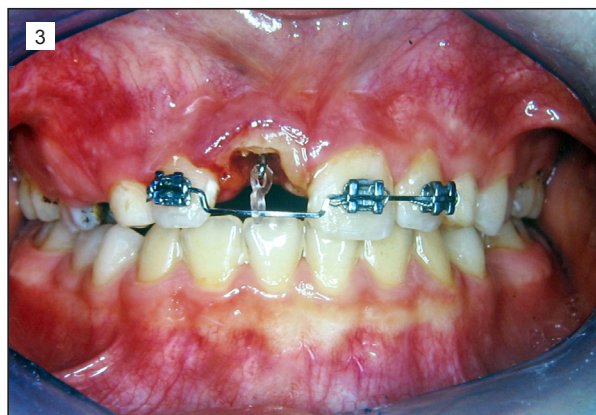


Figure 3. Initial orthodontics' eruption procedure.

the steel hook to arch wire with 75 gram force (Figure 3). The power chain was changed every 3 weeks. An extrusion of approximately 3 mm was obtained within 2 months. The extruded tooth was retained with the same arch wire for 60 days to prevent any relapse.

At the end of the retention period, gingivectomy and gingivoplasty were performed to expose the palatal margin of the fracture line; also, supra-alveolar fibers were disrupted by an incision through the bottom of the periodontal pocket to the border of the alveolar bone to prevent a post-treatment relapse. Afterward, two thirds of the length of the endodontic material was removed from the root using a drill of a diameter similar to the premanufactured glass fiber post with a low-speed instrument. A glass fiber post (Fiber Kor

Post System, Pentron Clinical Technologies, Wallingford, UK) was placed using a dual-cure composite (Panavia, Kuraray Medical, Kurashiki, Okayama, Japan). The post core was built up with a composite system (Grandia, Voco, Cuxhaven, Germany), and the excess composite material was removed using a high-speed, watercooled diamond bur (Acurata, G+K Mahnhardt Dental, Thurmansbang, Germany) to maintain approximately 2.0 mm incisal, 1.5 mm buccal, and 1.5 mm palatal space for the indirect composite tooth crown.

To minimize the amount of tooth preparation, the palatal margin border was located at the fracture level on the palatal surface, and the buccal margin was prepared at the cervical level on the buccal surface with a 1.5-mm wide butt joint and a rounded internal line angle for acceptable esthetic results. All sharp angles were slightly rounded to minimize stress concentration. A retraction cord (Ultrapak 0, Ultradent Products Inc, South Jordan, Utah, USA) was used to obtain clear margins for the impression (Figure 4a-b). A medium viscosity silicon material (Lasticomp, Kettenbach GmbH and Co, Eschenburg, Germany) was used for a definitive impression and an irreversible hydrocolloid material (Xantalgin, Heraeus Kulzer, Hanau, Germany) was used for the opposing arch impression. The shade of the indirect composite crown was determined.

An indirect composite crown restoration (Tescera ATL, Bisco Inc, Schaumburg, Ill., USA) was made by a dental technician. The indirect composite crown was placed definitively within 3 days of taking the impression. During the time it took to construct the indirect composite crown, the tooth was restored with a temporary crown.

The prepared indirect composite crown was tried in initially to check the proximal points and occlusal adaptation and adjusted with a diamond disk (Soft-Lex Pop-On Discs, 3M/ESPE, St. Paul, Minn., USA) where necessary. Before cementation procedures, the crown's undersurface was roughened with an air abrasion unit to enhance the bond strength.

The operating site was isolated with cotton rolls, the temporary glass ionomer cement was removed, and the prepared tooth was cleaned with a rubber cup and pumice. The adhesive system (Ed Primer II A&B, Kuraray Medical) was applied according to the manufacturer's instructions. The dual-cure composite material (Panavia, Kuraray Medical) was mixed and then applied to the crown's internal surface. The indirect composite crown was seated with gentle finger pressure to the prepared tooth. While keeping constant occlusal pressure, the excess composite material was removed immediately. The crown was light cured for 40 seconds from both buccal and palatal aspects with a visible light source (Elipar Free Light II, 3M/ESPE; Figure 5).

The outcome of the treatment fulfilled the esthetic expectations for both the patient and his parents. The

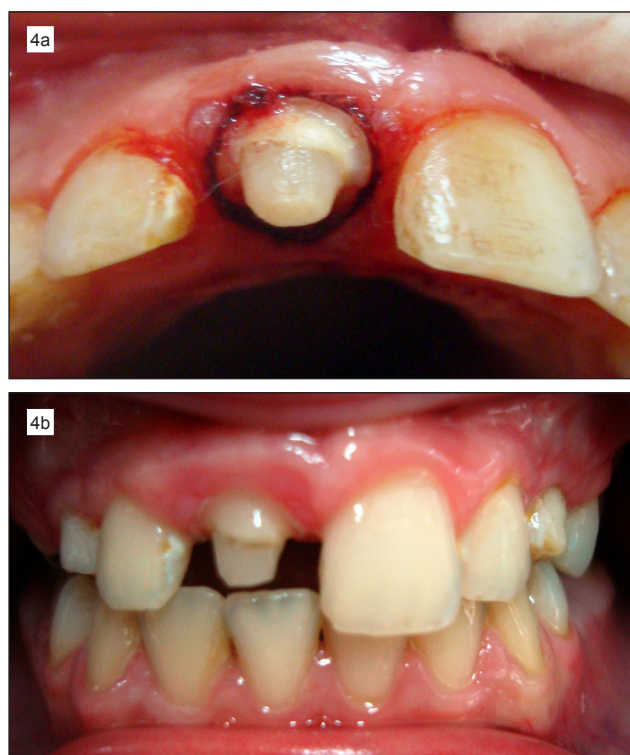


Figure 4. (a) Occlusal view of the tooth structure prepared for indirect composite crown. (b) Vestibular view of the tooth structure prepared for indirect composite crown.

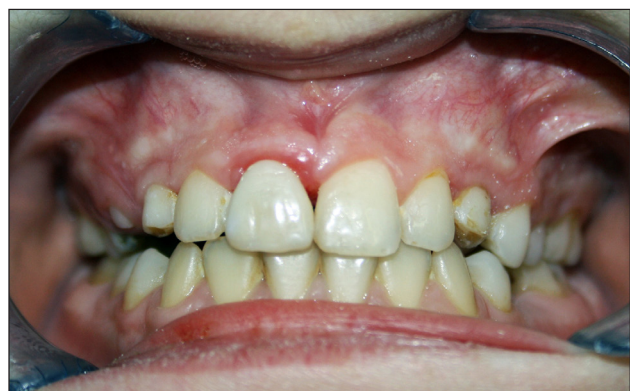

Figure 5. Clinical view of the indirect composite crown after cementation.

patient was examined 1, 3, 6, 9, and 12 months after treatment. Clinically, the indirect composite crown has served as a good restoration, as evidenced by sufficient stability, maintenance of its esthetics with no discoloration, no occurrence of marginal carious lesions, and no apparent radiographic failure for 12 months (Figure 6a-b).

DISCUSSION

The location of the fracture line in fractured teeth affects not only the treatment options but also the prognosis.² The clinical outcomes and prognosis of teeth that are fractured in the subgingival area have been found to be the most bleak because of the loss of the coronal fragment stability and pulpal vitality.⁶

Different treatment approaches have been indicated for subgingivally fractured anterior teeth in young adults:

1. natural tooth crown reattachment as a temporary or permanent restoration⁷;
2. adhesive restoration⁸ or prosthetic crown restoration⁹ after an orthodontic or surgical extrusion; and
3. extraction¹⁰ and/or decoronation¹¹ of the tooth followed by an immediate child denture.¹⁰

The favorable clinical outcome of these kinds of cases, however, often implies a multidisciplinary approach of orthodontic, endodontic, periodontal, and prosthetic therapy with patient cooperation. The treatment approach must be focused on exposure of the subgingivally fractured margins so that all clinical procedures can be managed with strict control of moisture and blood contamination. The possible treatment alternatives include surgical or orthodontic extrusion to expose the fracture line.

In this case, orthodontic extrusion was used instead of a surgical extrusion to re-establish the biological width, expose the fractured subgingival margins, and access the root canal. This is because orthodontic extrusion is considered a safe procedure with respect to the occurrence of root resorption and does not involve loss of periodontal support or bony tissue of the surrounding teeth.^{12,13} The root length of the fractured incisor must allow the tooth to undergo the necessary amount of extrusion and still retain a crown-root ratio of approximately 1:1. This ratio is favorable for maintaining periodontal support.¹⁴ In this case report, the root length of the fractured incisor was enough for orthodontic extrusion.

The purpose of this clinical report was to present an indirect composite restoration as a conservative alternative procedure to direct resin composite and adhesive fragment reattachment build-up for restoring esthetics and function of traumatized teeth in young adults. The indirect composite restoration is a good alternative, since adhesive fragment reattachment cannot be considered a durable procedure for the management of

extensive fractures.^{14,15} Additionally, the fracture line may become visible over time due to discoloration of the adhesive and composite used for both the reattachment and the direct composite procedure.¹⁶

In the present case, a glass fiber-reinforced composite root canal post and a composite core were utilized. The bonding of a fiber post to the tooth structure should improve the prognosis of the restored tooth by increasing post retention and reinforcing the tooth structure, especially in the lack of coronal tooth structure. Moreover, satisfactory esthetic appearance with no risk of gingival discoloration is an important advantage of glass fiber posts.¹⁷

Physical and mechanical properties of modern composite resins have improved, but polymerization shrinkage still limits the longevity of direct restorations. Moreover, direct restorations incur technical difficulties, such as re-establishing contact points and creating satisfactory contours that can contribute to restoration failures. The indirect restoration technique requires 2 clinical sessions, but the chair time is reduced, which is better for the

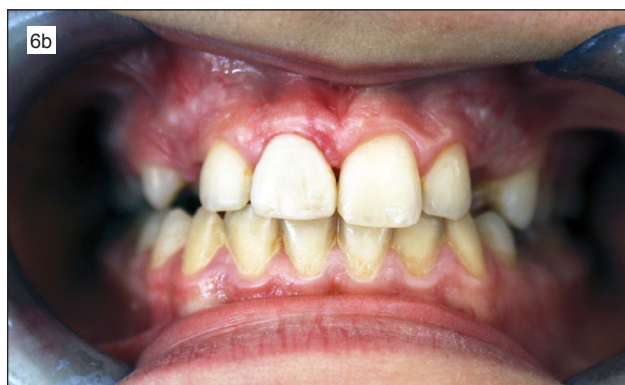
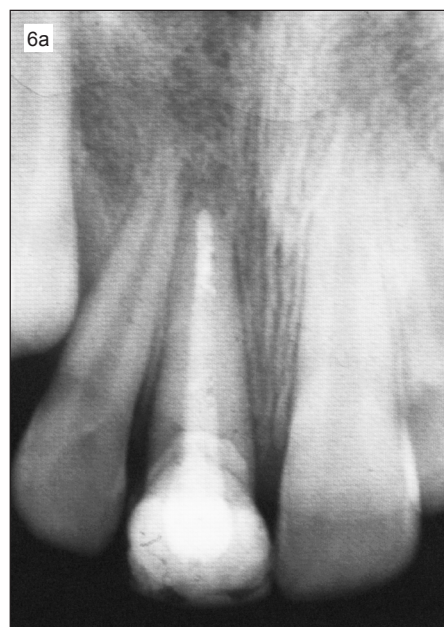
Figure 6. (a) Radiographic view of the indirect composite crown after cementation. (b) Clinical view of the indirect composite crown after 12 months.

child. In addition, the indirect technique allows for a better proximal contour and marginal adaptation where polymerization shrinkage is better controlled during the extraoral fabrication.¹⁸

Also, when marginal adaptation for direct and indirect placement of composite was compared, the indirect composite technique showed better marginal seal for the cervical restoration not only in Class I but also in Class II restorations.¹⁹⁻²¹ Finally, another positive benefit of the indirect technique is the secondary polymerization through heat that improves the physical properties of the composite resin restoration.²²

The necessity for a multidisciplinary approach in the treatment of complicated dental traumas should be considered in respect to biological, functional, and esthetic aspects. Finally, the use of an indirect composite restoration is effective in preventing marginal leakage and could be a reliable alternative to the use of a direct composite restoration for the treatment of subgingivally fractured anterior teeth in young adults.

REFERENCES

- Hollan G, Shmueli Y. Knowledge of physicians in hospital emergency rooms in Israel on their role in cases of avulsion of permanent incisors. *Int J Paediatr Dent* 2003;13:13-9.
- Andreasen JO, Andreasen FM. Textbook and Color Atlas of Traumatic Injuries to the Teeth. Copenhagen, Denmark: Blackwell Munksgaard; 2008.
- Saito CT, Guskuma MH, Gulinelli JL, Sonoda CK, Garcia-Junior IR, Filho OM, Panzarini SR. Management of a complicated crown root fracture using adhesive fragment reattachment and orthodontic extrusion. *Dent Traumatol* 2009;25:541-4.
- Padbury A, Eber R, Wang HL. Interactions between the gingiva and the margin of restorations. *J Clin Periodontol* 2003;30:379-85.
- Caliskan MK. Surgical extrusion of a cervically root fractured tooth after apexification treatment. *J Endod* 1999;25:509-13.
- Welbury R, Kinirons MJ, Day P, Humpury K, Gregg TA. Outcomes for root-fractured permanent incisors: A retrospective study. *Pediatr Dent* 2002; 24:98-102.
- Canoglu H, Gungor HC, Cehreli ZC. Management of a cervical root fracture using orthodontic extrusion and crown reattachment: A case report. *Oral Surg Oral Med Oral Pathol Oral Endod* 2007; 104:46-9.
- Turgut MD, Gonul N, Altay N. Multiple complicated crown root fracture of a permanent incisor. *Dent Traumatol* 2004;20:288-92.
- Villat C, Machtou P, Naulin C. Multidisciplinary approach to the immediate esthetic repair and long-term treatment of an oblique crown root fracture. *Dent Traumatol* 2004;20:56-60.
- Ulusoy AT, Cereli ZC. Provisional use of a natural tooth crown following failure of reimplantation. *Dent Traumatol* 2008;24:96-9.
- Sapir S, Shapira J. Decoronation for the management of an ankylosed young permanent tooth. *Dent Traumatol* 2008;24:131-5.
- Bach N, Baylard JF, Voyer R. Orthodontic extrusion: Periodontal considerations and applications. *J Can Dent Assoc* 2004;70:775-80.
- Emerich-Poplatek K, Sawicki L, Bodal M, Adamowicz-Klepalska B. Forced eruption after crown/root fracture with a simple and aesthetic method using the fractured crown. *Dent Traumatol* 2005;21:265-9.
- Caliskan MK, Pehlivan Y. Prognosis of root-fractured permanent incisors. *Endod Dent Traumatol* 1996;12:129-36.
- Andreasen FM, Noren JG, Andreasen JO, Engelhardt S, Lindh-Stromberg U. Long-term survival of fragment bonding in the treatment of fractured crowns: A multi-center clinical study. *Quintessence Int* 1995;26:669-81.
- Macedo GV, Diaz PI, De OFCA, Ritter AV. Reattachment of anterior teeth fragments: A conservative approach. *J Esthet Restor Dent* 2008;20:5-18.
- Vitale MC, Caprioglio C, Martignone A, Marchesi U, Botticelli AR. Combined technique with polyethylene fibers and composite resins in restoration of traumatized anterior teeth. *Dent Traumatol* 2004;20:172-7.
- Ferreira MC, Vieira RS. Marginal leakage in direct and indirect composite resin restorations in primary teeth: An in vitro study. *J Dent* 2008;36:322-5.
- Douglas WH, Fields RP, Fundingsland J. A comparison between the microleakage of direct and indirect composite restorative systems. *J Dent* 1989; 17:184-8.
- Sheth PJ, Jensen ME, Sheth JJ. Comparison of three resin inlay techniques: Microleakage studies. *Quintessence Int* 1989;20:831-6.
- Shortall AC, Baylis RL, Baylis MA, Grundy JR. Marginal seal comparisons between resin bonded Class II porcelain inlays, posterior composite restorations, and direct composite resin inlays. *Int J Prosthodont* 1989;2:217-23.
- Shinkai K, Suzuki S, Leinfelder KF, Katoh Y. How heat treatment and thermal cycling affect wear of composite resin inlay. *J Am Dent Assoc* 1994;125: 1467-72.

Copyright of Journal of Dentistry for Children is the property of American Academy of Pediatric Dentistry and its content may not be copied or emailed to multiple sites or posted to a listserv without the copyright holder's express written permission. However, users may print, download, or email articles for individual use.