

Achieving Optimal Esthetics in a Patient with Severe Trauma: Using a Multidisciplinary Approach and an All-Ceramic Fixed Partial Denture

JOSÉ-LUIS RUIZ, DDS*

ABSTRACT

The treatment of traumatic injuries can be difficult, especially when the patient's expectations are too high or unreasonable. Such cases require extremely clear communication with the patient before beginning the case, including an explanation of the final results, based on the patient's goals. Taking over a case from another colleague adds more complications and requires that close attention is paid to the reason for the original dissatisfaction between the former dentist and patient to avoid repeating the same mistakes. Clinically, patients with thin, fragile gingiva are extremely challenging if they require a fixed partial denture in the esthetic zone since the most common material, a ceramometal bridge, requires infragingival margins; if any recession occurs, a catastrophic esthetic failure will result. The case presented here underscores all these special issues. Proper multidisciplinary management, good patient communication, and the use of an all-ceramic fixed partial denture system can provide an excellent final result.

CLINICAL SIGNIFICANCE

Replacing teeth in the esthetic zone is complicated, especially when trauma has caused severe damage to the surrounding bone and gingiva. Satisfying a demanding patient requires a multidisciplinary approach and psychological management, as are exemplified in this article.

(*J Esthet Restor Dent* 17:285–292, 2005)

Today patients' esthetic demands are extremely high; even patients with severe traumatic injuries and a significant loss of tissue expect a full recovery. Dramatic improvements in plastic surgery are now possible, repairing severe traumatic injuries to almost preinjury levels; this, in turn, makes patients believe that we should be able to accomplish the same results in dentistry. Patients may not fully understand

the high degree of difficulty in repairing severe traumatic damage—not only the loss of teeth but also the damage to bone and soft tissues. The decision to treat a patient with these complicated conditions needs to be carefully assessed to avoid not meeting his or her idea of the expected outcome. Accordingly, this case report discusses some of the diagnostic principles and the sequence necessary to

achieve optimal results using careful treatment planning, a multidisciplinary approach, and a new all-ceramic fixed partial denture.

CASE REPORT

Background

A 35-year-old female patient presented with the desire to replace her missing anterior teeth (Figure 1). The patient reported that she had been in an automobile accident

*Private practice, Los Angeles, CA, USA; clinical instructor, University of Southern California, Los Angeles, CA, USA

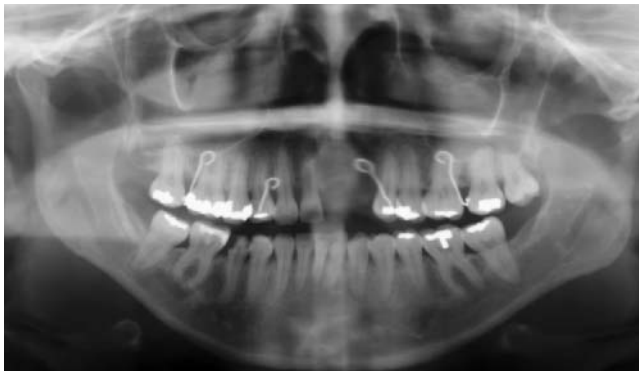

Figure 1. Panoramic radiograph showing that the right maxillary canine and lateral and central incisors and left maxillary central incisor are missing.

that caused severe facial injuries and the loss of the right maxillary canine and lateral and central incisors as well as the left maxillary central incisor. She also reported having started dental treatment 3 years earlier to replace her anterior teeth. That treatment plan included orthodontics and subsequent implant treatment. After completing the orthodontic phase of the treatment, the patient became disillusioned because she was unhappy with her smile and stated that her entire smile had become “crooked” and that the midline was “very off to the left” (Figure 2).

The patient had become quite knowledgeable about dentistry and aware of the complexity of her case. Her esthetic demands were very high, and she indicated that her “life’s dream” had been to have a beautiful and natural smile and that she would not be happy with something that appeared “fake.” The

patient’s overall health was adequate; finances were an issue, but a “natural” result was her main goal.

Evaluation

The intraoral evaluation yielded the following findings: the right maxillary canine and lateral and central incisors, and the left maxillary central incisor were missing; there was a severe ridge defect in the area; and both hard and soft tissues had been lost owing to the traumatic injury. The previous orthodontist had attempted to move the entire dentition forward to close the edentulous space as much as possible. At the end of the treatment, only two pontics were needed because the right bicuspid had replaced canine and the left lateral had replaced the left central incisor. However, the patient was left with a severe occlusal cant (the right side was much higher than the left) and a posterior crossbite and anterior open bite. The left lateral incisor

had been moved to the left central position but remained 3 mm from the midline; as a consequence, the temporary removable partial that was fabricated by the previous dentist had a severe midline discrepancy. The patient was aware and unhappy about these problems.

In addition, gingival recession was evident on most of the maxillary teeth, possibly because of the large amount of tooth movement during orthodontics, along with thin and fragile gingival tissues. Other than the above-noted findings, the patient’s periodontal health was good. Periodontal pockets were all below 3 mm, and the patient maintained adequate oral hygiene.

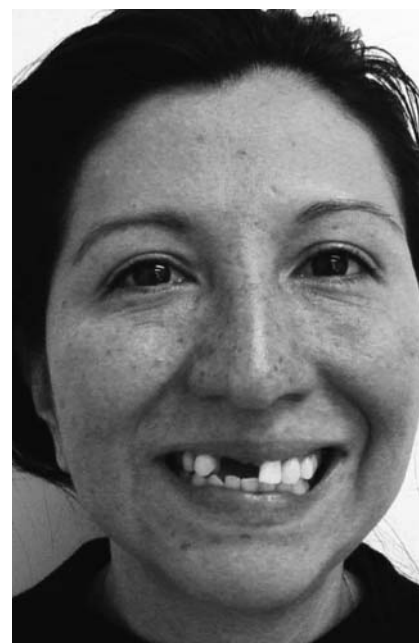

Figure 2. Portrait before treatment, showing midline discrepancy.

When diagnosing and planning treatment for this case, several items needed to be considered: the severity of the ridge loss (bone and soft tissue) attributed to the trauma, poor tooth position, the level of gingival display when the patient smiled, the patient's age, and so on. Most notably, a "red flag" was raised when the patient mentioned "my life's dream is..." since this indicated that excessive attention would be placed on the final result. In addition, it had to be taken into account that the patient had started treatment, including orthodontics, and had become disillusioned with the results. In part, this happened because of her high expectations; however, a lack of communication between the previous restorative dentist, the orthodontist, and the patient had apparently led to a breakdown in trust, making this a high-risk case.

It is imperative that, in such cases, proper emotional management of the patient is addressed, including a discussion of realistic goals and the finished outcome. The patient needs to be made aware of the level of difficulty of each step and that his or her expectations should be realistic; in addition, those issues should be reinforced throughout the treatment.

Treatment Plan

Good treatment planning should always begin with excellent records

including a detailed written narrative that outlines the treatment steps and the expected results. Using all data available, the restorative dentist needs to develop a plan, refer the patient to a specialist as needed, and then consult with the specialist. In this way, the restorative dentist acts as the "quarterback."¹

In this particular case, a set of the casts was mounted on a semi-precision articulator, along with a face-bow (Panadent, Los Angeles, USA) (Figure 3), and a full set of photographs was taken. These records are indispensable when developing a treatment plan as both a diagnostic tool and a communication tool for the patient and the esthetic team.

The patient was presented with two treatment options. The first plan included additional ortho-

dontic treatment to improve the occlusal cant and midline, ridge-augmentation surgery to allow for appropriate tooth length, and the development of ovate pontics on a fixed partial denture.^{2,3} The second treatment plan included orthodontics, hard and soft tissue grafting procedures, and implants to replace the missing teeth. The patient opted for the fixed partial denture, using an all-ceramic bridge system. She was particularly concerned that there would be no visible metal margins along the gum line and liked the idea that no metal would ever show and that esthetics can be superior to those with a metaloceramic bridge. Concerns regarding her thin gingival tissues and the apparent tendency toward gingival recession, in conjunction with her young age, made an all-ceramic bridge the most desirable option. A highly sintered zirconia porcelain system of

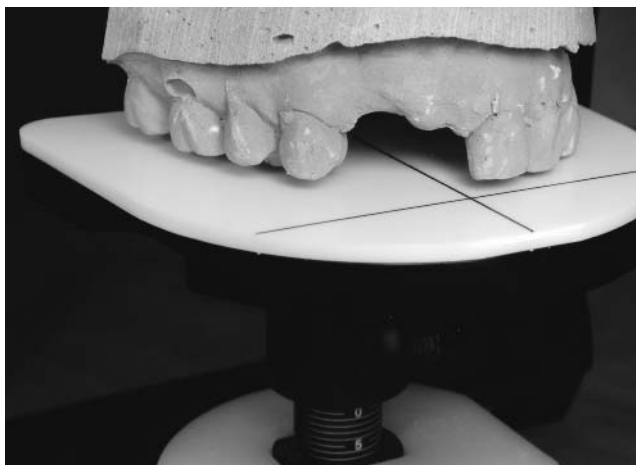


Figure 3. Mounted cast, using the Panadent diagnostic platform to reveal the midline discrepancy.

Lava crowns and bridges (3M ESPE, St. Paul, MN, USA) was chosen because of its flexural strength, which is in excess of 1,200 MPa, more than twice that of gold,⁴ making it a safe choice. Also its excellent translucency and the many available core shades make this bridge the most esthetic available.

The patient was informed that since the Lava bridge is relatively new, a long-term history of its use is not available, but that porcelain is similar to the ceramics used for hip replacements, which are strong enough to support an entire body weight and are extremely biocompatible. In addition, the patient was informed of the added benefit in esthetics and the minimum tissue irritation or minimum need for cord packing. The patient opted for what would provide her the maximum esthetic benefits.

Clinical Procedure

The first phase of the treatment was limited to orthodontics (Figure 4). At the end of the first year of treatment, the patient was happy to see that the occlusal cant had almost disappeared and the midline was much closer to the middle.

The second phase included the making of new mounted models and records, an ideal wax-up, and a set of acrylic laboratory-processed provisionals with ovate pontics (Figure 5). Available literature confirms that with properly designed

ovate pontics and excellent oral care, ideal health can be restored and maintained.^{5,6} The teeth were prepared according to appropriate prosthodontic principles for all porcelain crowns, with a 2 mm occlusal reduction, a 1.5 mm axial reduction, and round internal angles and a butt cavosurface margin. The provisionals were relined

and cemented with TempBond Clear (Kerr Manufacturing Co., Orange, CA, USA).

The third phase of the treatment involved sending the patient to a periodontist for the ridge-augmentation surgery.⁷⁻⁹ The provisionals served as the surgical guide for how much tissue needed

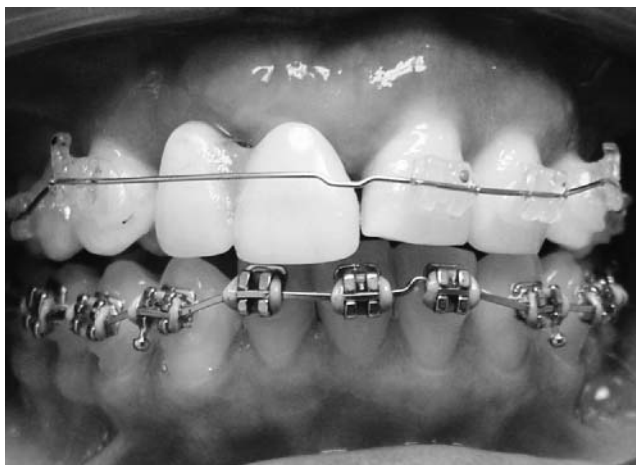

Figure 4. Orthodontics were performed to correct the midline discrepancy and occlusal cant.

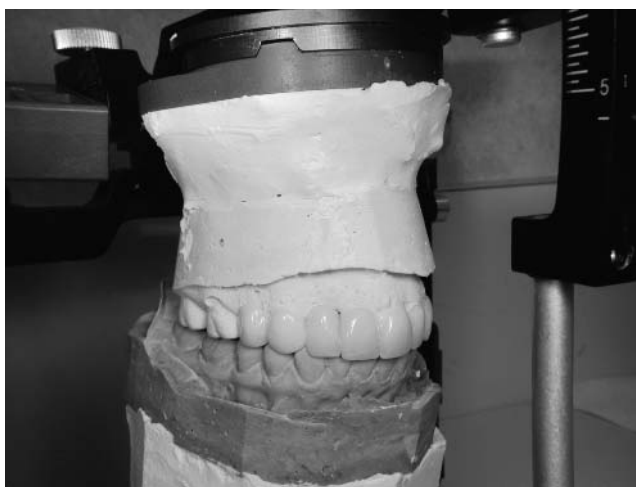


Figure 5. Laboratory-made provisional.

to be augmented (Figure 6) and also revealed that to achieve ideal symmetry, some crown-lengthening surgery was necessary. This underscores the importance of good communication among members of the esthetic dental team (specialists, technicians, and restorative dentist) and how proper records and provisionals are needed to properly plan, communicate, and achieve the ultimate result.^{1,10}

After approximately 8 weeks of healing, the patient was referred back from the periodontist for final impressions. At this appointment, the preparations were refined and the impression was taken using Impregum Penta Soft Impression Material (3M ESPE) because it is the most hydrophilic material and best reproduces the developed ovate site. An additional impression of the provisional was taken with Position Penta Quick Preliminary Impression Material (3M ESPE) (Figure 7), reproducing the custom-developed pontics and half of the internal portion of the abutment. (This becomes the matrix that the laboratory uses to reproduce the carefully developed pontic sites.)

The tremendous strength of the core material on the completed Lava bridge (Figure 8) allows for options in the choice of cement. Conventional cements can be used in cases where sufficient mechanical retention is available^{11,12}; there is no need to bond the ceramic core

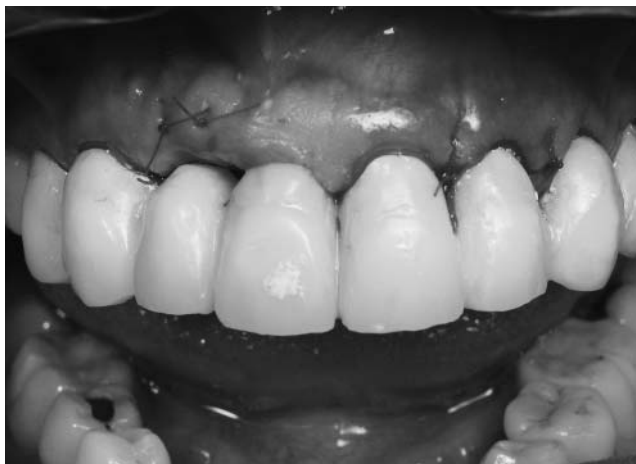

Figure 6. Provisionals act as the guide for ridge augmentation.

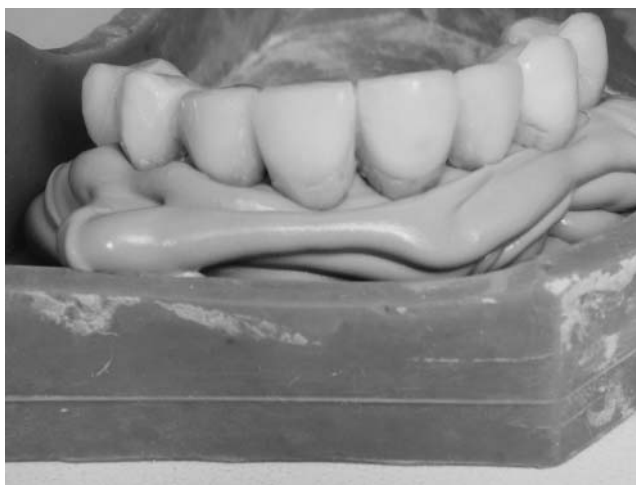

Figure 7. Fabrication of the ovate pontic matrix.

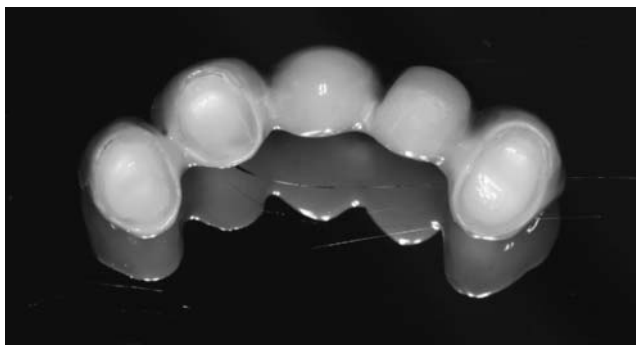


Figure 8. Lava bridge.

using resin cements. In this case, the bridge and other crowns were cemented with RelyX Luting Cement (3M ESPE) because of its

long clinical history and easy clean up. The patient was extremely satisfied with the results, as shown in the final photograph, taken 2 weeks

postoperatively; there is a sharp contrast between the preoperative and postoperative photographs (Figures 9–12).

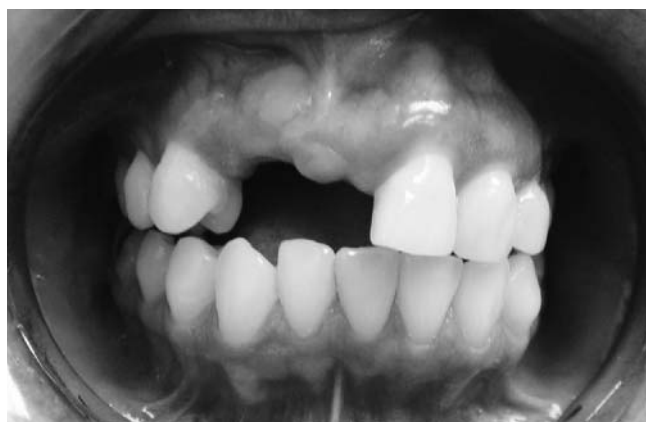

Figure 9. Preoperative retracted close-up.

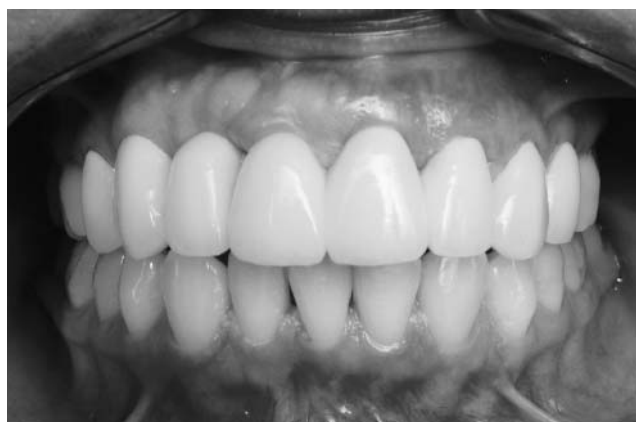

Figure 10. Retracted close-up, 2 weeks postoperatively.



Figure 11. Preoperative full face, smiling.



Figure 12. Postoperative full face; patient is satisfied with the results.

CONCLUSIONS

With proper treatment planning, a multidisciplinary approach, and the support of the entire esthetic team, excellent patient results can be achieved. Advances in technology also are helping. New ceramic materials have become available that, when used correctly, can yield more superior esthetic results than can porcelain fused to metal. However, it is important to remember that perfection is impossible to achieve. In this particular case, for example, although the results are extremely satisfactory, we were unable to create the illusion of a papilla between the left maxillary lateral and the central incisors. Thanks to proper patient emotional management and constant reminders of the high level of difficulty of this case, the patient was able to overlook and dismiss this small imperfection and focus on the overall excellent result.

It is of vital importance that restorative dentists identify patients with

very high expectations and either manage them properly or choose to refer them. This avoids not meeting a patient's unrealistic expectations and the possibility of ending end up in conflict with the patient.

DISCLOSURE AND
ACKNOWLEDGMENT

The author does not have any financial interest in the companies whose materials are discussed in this article. Special thanks to Dr. Ronald Lascoe, periodontist, and Burbank Dental Laboratory for all their exquisite work.

REFERENCES

1. Shillingburg H Jr, Hobo H, Whitsett LD, et al. *Fundamentals of fixed prosthodontics*. 3rd Ed. Carol Stream, IL: Quintessence Publishing Co. Inc, 1997.
2. Arnold JF. Accreditation bridge technique for optimal anterior esthetics: a case report. *J Cosmet Dent* 2003; 18(4):52–60.
3. Dylina TJ. Contour. Determination for ovate pontics. *J Prosthet Dent* 1999; 82:136–142.
4. Tinschert Zvez D, Marx R, Anusavice KJ. Structural reliability of alumina-feldspar-, leucite-, mica- and zirconia-based ceramics. *J Dent* 2000; 28:529–535.
5. Zitzmann NU, Marinello CP, Berglundl T. The ovate pontic design: a histologic observation in humans. *J Prosthet Dent* 2002; 88:375–380.
6. Tripodakis AP, Constantinides A. Tissue response under hyperpressure from convex pontics. *Int J Periodontics Restorative Dent* 1990; 10:408–414.
7. Johnson GR, Leary JM. Pontic design and localized ridge augmentation in fixed prosthodontics design. *Dent Clin North Am* 1992; 36:591–605.
8. Miller MB. Aesthetic anterior reconstruction using a combined periodontal/restorative approach. *Pract Periodontics Aesthet Dent* 1993; 5:33–40.
9. Johnson GK, Leary JM. Pontic design and localized ridge augmentation in fixed partial denture design. *Dent Clin North Am* 1992; 36:591–605.
10. Derbabian K, Chee WL. Simple tools to facilitate communication in esthetic dentistry. *CDA Journal* 2003; 31(7):542–73.
11. Snider MD, Lang BR, Razzog ME. The efficacy of luting all-ceramic crowns with resin-modified glass ionomer cement. *J Am Dent Assoc* 2003; 134:609–612.
12. Lindquist TJ, Connolly J. In vitro microleakage of luting cements and crown foundation material. *J Prosthet Dent* 2001; 85:292–298.

*Reprint requests: J.-Luis Ruiz, DDS,
1226 West Olive Avenue, Burbank, CA,
USA, 91506; e-mail: ruiz@drruiz.com*
©2005 BC Decker Inc

Copyright of Journal of Esthetic & Restorative Dentistry is the property of B.C. Decker Inc.. The copyright in an individual article may be maintained by the author in certain cases. Content may not be copied or emailed to multiple sites or posted to a listserv without the copyright holder's express written permission. However, users may print, download, or email articles for individual use.