

# Clinical Evaluation of Direct Cuspal Coverage with Posterior Composite Resin Restorations

SIMONE DELIPERI, DDS\*  
DAVID N. BARDWELL, DMD, MS†

## ABSTRACT

*Background:* Composite resins have esthetic properties; they join the ability to preserve and reinforce sound tooth structure. Conservation is becoming popular for both small to medium defects and more compromised teeth.

*Purpose:* This study aimed to evaluate the clinical performance of Class II cuspal coverage direct composite restorations.

*Materials and Methods:* Twenty patients, 18 years or older, were included in this clinical trial restoring 25 vital molar teeth with one or two missing cusps. Criteria for inclusion are two or three surface restorations, replacement of composite and amalgam fillings (secondary decay, fracture of either filling material or tooth structure, aesthetic considerations), or virgin teeth with decay undermining a cusp. Teeth with residual cavity walls less than 1 mm or with complete loss of the clinical crown were excluded.

Teeth were restored using a combination of Ultra-Etch 35% phosphoric acid, PQ1 adhesive system, and Vit-l-escence microhybrid composite resin (Ultradent Products, Inc., South Jordan, UT, USA). The enamel peripheral skeleton of the restoration was built up first, followed by dentin and enamel occlusal surface stratification. Wedge-shaped increments of composite resin were placed and cured using the variable intensity polimerizer (VIP) light (Bisco Inc., Schaumburg, IL, USA) through a combination of a pulse and progressive curing technique.

*Results:* All 25 restorations were evaluated at 6-month intervals during the 30-month period using a modified US Public Health Service (USPHS) criteria by two independent evaluators pre-calibrated at 85% reliability. No failures were reported and alpha scores were recorded for all parameters. Statistical analysis was performed using a Chi-square test ( $\chi^2$ ) and the Fisher's exact test. Sixteen of the 25 samples (64%) exhibited preoperative sensitivity to air ( $\chi^2 = 10.6$ ;  $p = 0.001$ ). A significant difference in tooth sensitivity was reported after completion of the restorations. No teeth exhibited sensitivity both at the 2-week recall and the 30-month follow-up ( $\chi^2 = 23.5$ ;  $p < 0.0001$ ).

*Conclusion:* Microhybrid composite resin demonstrated excellent clinical performance in direct cuspal coverage at completion of a 30-month evaluation.

## CLINICAL SIGNIFICANCE

In selected clinical situations, cuspal coverage direct posterior composite restorations may represent a valid alternative to conventional indirect restorations.

(*J Esthet Restor Dent* 18:256–267, 2006)

\*Visiting instructor and research associate, Tufts University School of Dental Medicine, Boston, MA, USA;  
Private practice, Cagliari, Italy  
†Associate clinical professor of restorative dentistry, Tufts University School of Dental Medicine, Boston, MA, USA

## INTRODUCTION

Single-appointment direct posterior resin-bonded composite (RBC) restorations should ideally be restricted to small to medium-size intracoronal lesions.<sup>1</sup> This assumption is based on the poor wear characteristic and marginal behavior of early RBC.<sup>2</sup>

However, a recent literature review reported no significant difference in the longitudinal clinical behavior of both direct and indirect composite resin over a 3-year evaluation period.<sup>3</sup> The increased predictability of direct RBC has encouraged clinicians to progressively abandon amalgam in the last decade.<sup>4</sup> This is the consequence of three different phenomena: (1) continuous development of total-etch adhesive systems<sup>5,6-8</sup> and improvement of RBC physical and mechanical properties<sup>3,9</sup>; (2) patient demand for esthetic restorations; and (3) patients' increasing desire to save remaining sound tooth structure, along with the inability to afford an indirect restoration in those large posterior and anterior situations. Clinicians are asked to stretch clinical indications for direct RBC restorations.<sup>10,11</sup> As a consequence, clinical indications for anterior and posterior RBC restorations are expanding. Clinicians are starting to re-evaluate the dogma of traditional restorative dentistry. They are looking for new materials, techniques, and alternative methods to

build up teeth directly with RBC. These restorations are being considered in both vital and nonvital teeth.<sup>10-13</sup>

Lately, increasing attention has been focused around the use of direct RBC for cusp replacement.<sup>14,15</sup>

The purpose of this study was to evaluate the clinical performance of direct composite restorations when a microhybrid composite resin was used in the reconstruction of molar teeth with missing cusps (direct inlay/onlay posterior composite restorations).

We hypothesized that a 90% composite resin retention rate could be expected at the 2-year recall.

## MATERIALS AND METHODS

Twenty patients, 18 years or older, were included in this clinical trial to reconstruct 25 molar teeth with one or two missing cusps.

Only restorations having the following requirements were included in the study:

1. replacement of amalgam fillings because of secondary decay, fracture of either the filling material or tooth structure, or esthetic reasons
2. placement in virgin teeth with gross caries destroying a cusp at the middle or cervical third

3. placement in teeth with opposing occlusion and proximal contacts
4. two to four surface restorations

All subjects received a dental prophylaxis 2 weeks prior to the start of the study.

Patients with severe internal discoloration (tetracycline stains, fluorosis teeth), smokers, and either pregnant or nursing women were excluded from the study; patients unable to attend recall and having a gingival index score greater than 1 were excluded from entering the trial. Teeth having thickness of remaining cavity walls less than 1 mm and with complete loss of clinical crown were also excluded.

Before starting each restoration, preoperative pictures were taken and occlusion was checked (Figures 1 and 2).

**Restorative Procedure**

A rubber dam was placed and cavity was prepared in a very conservative manner—just removing decay and/or the existing restoration with a #245 bur (Shofu Dental Corporation, San Marcos, CA, USA), rounding sharp angles with #2 and #4 burs (Shofu Dental Corporation), and without placement of bevels either on the occlusal or gingival surface. A circular matrix (Automatrix, Dentsply/Caulk, Mildford, DE,

USA) was placed around the tooth and tightened (Figure 3). Interproximal matrix adaptation was secured using wooden wedges. Cavity was disinfected using a 2% chlorexidine antibacterial solution (Consepsis, Ultradent Products, Inc., South Jordan, UT, USA). Tooth was etched for 15 seconds using 35% phosphoric acid (Ultra-Etch, Ultradent Products, Inc., South Jordan, UT,

USA) (Figure 4); etchant was removed and cavity water sprayed for 30 seconds being careful to maintain a moist surface. A fifth-generation 40% filled ethanol-based adhesive system (PQ1, Ultradent Products, Inc.) was placed in the preparation, gently air thinned until the milky appearance disappeared, and light-cured for 20 seconds using a quartz-tungsten-

halogen curing light (VIP, Bisco Inc., Schaumburg, IL, USA) (Figure 5).

Vit-l-escence microhybrid composite resin (Ultradent Products, Inc.) was used to restore the teeth. Stratification with multiple 1- to 1.5-mm triangular-shaped (wedge-shaped), apico-occlusal placed layers of Pearl Amber or Pearl Smoke plus Pearl

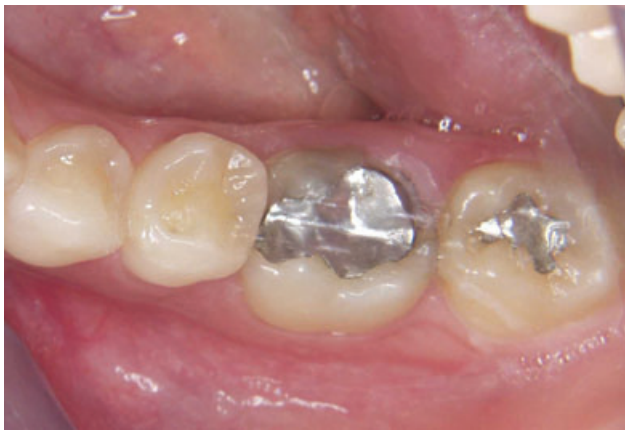

Figure 1. Preoperative view of tooth #30 with fracture of the linguo-distal wall.

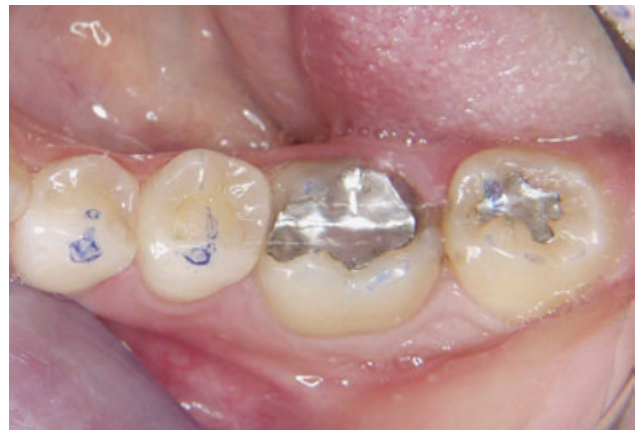

Figure 2. Before starting anesthesia, occlusion was checked and centric stops were recorded.

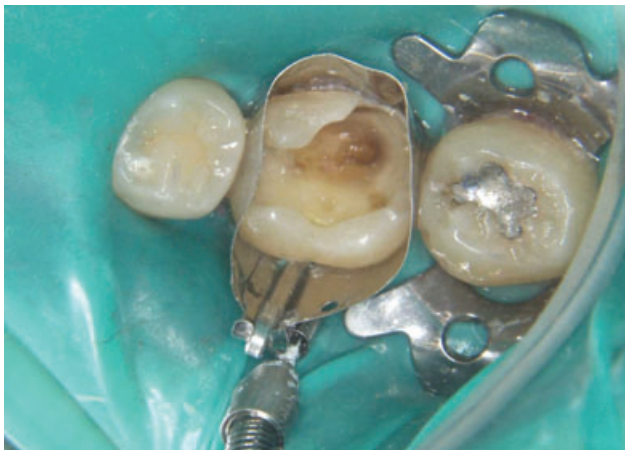

Figure 3. Cavity preparation was completed and a circular matrix was placed.

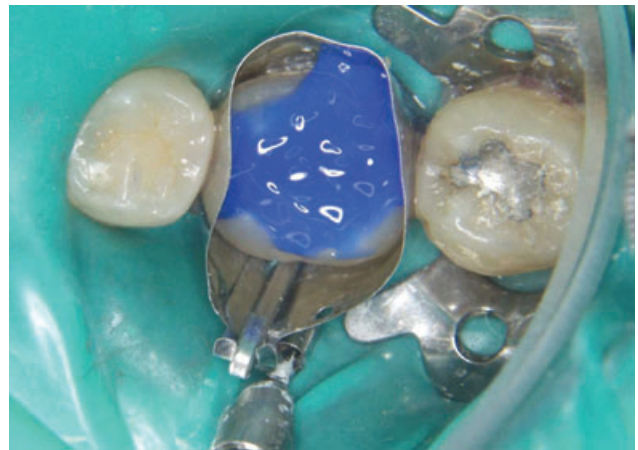

Figure 4. Etching was performed using 35% phosphoric acid.

Frost (PF) or Pearl Neutral (PN) Vit-I-escence shades to reconstruct the enamel portion of the proximal surface first and then the enamel external shell of each cusp (Figure 6). At this point, stratification of dentin was started by placing a 1- to 1.5-mm even layer of flowable composite (PermaFlo, Ultradent Products, Inc.) on deeper dentin, followed by

the application of dentin wedge-shaped increments strategically placed to a single surface, decreasing the C-factor ratio (Figure 7).<sup>16,17</sup> An enamel layer of PF or PN was applied to the final contour on the occlusal enamel surface (Figure 8). In order to avoid microcrack formation on the remaining wall and reduce stress from polymerization shrinkage, the

authors used a previously described polymerization technique, based on a combination of a pulse and progressive curing technique<sup>16,17</sup> (Table 1).

Rubber dam was removed, the occlusion was checked, and the restoration was finished using the Ultradent Composite Finishing Kit (Ultradent Products, Inc.)

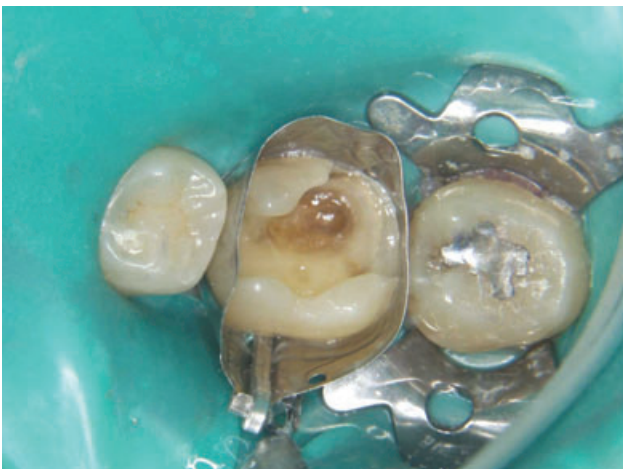

Figure 5. An ethanol-based adhesive system was applied on both the enamel and dentin.

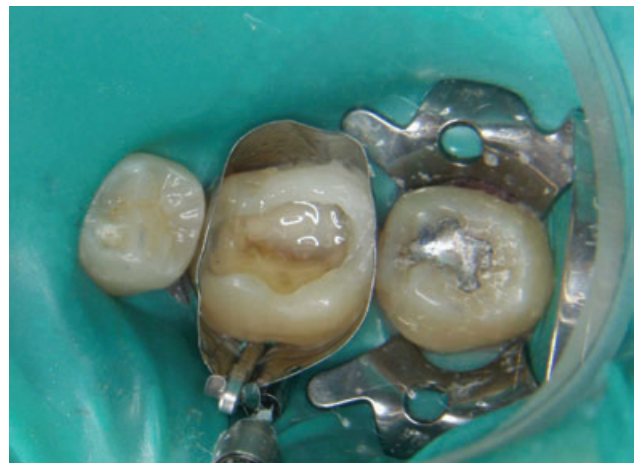

Figure 6. The peripheral enamel skeleton was built up using wedge-shaped increments of Pearl Smoke and Pearl Frost shades; dentin stratification was started placing a 1-mm layer of A2 flowable composite resin.

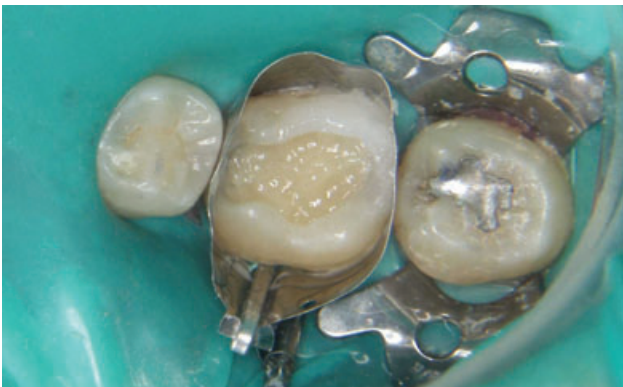

Figure 7. Dentin stratification was completed by using wedge-shaped increments of dentin shades.

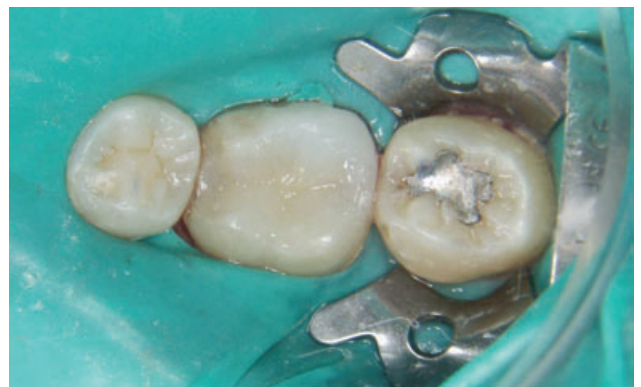

Figure 8. Restoration was completed with the application of Pearl Frost shade to the final contour of the occlusal surface.

(Figure 9). Polishing was performed using impregnated silicon rubber cups and points, while final polishing was performed using diamond and silicon carbide impregnated cups, points, and brushes (Finale Polishing System, Ultradent Products, Inc.).

### Clinical Evaluation

Three expert investigators were involved: the first investigator restored the teeth and the restorations were then evaluated by two investigators precalibrated at 85% reliability. Disagreement was resolved with a consensus. Twenty-five restorations were placed in 20 patients during a 2-month period (Table 2).

The restorations were evaluated every 6 months during a 30-month period using a modified USPHS criteria by two independent evaluators (Table 3). Photos were taken at each recall.

**TABLE 2. MAIN CHARACTERISTICS OF CAVITY PREPARATION BEFORE FINAL RESTORATION.**

Patient	Tooth #	Missing Cusp	Level of Fracture Line (Middle/Cervical Third)	Existing Restoration	Decay	Missing Marginal Ridge
1	02	DP	Cervical	Amalgam	+	D
2	19	ML	Cervical	Reinforced GI	+	M
	30	ML, DL	Cervical	Reinforced GI	-	M
	31	DL	Middle	Reinforced GI	-	M-D
3	19	DL	Middle	Amalgam	-	D
4	19	DL	Cervical	Amalgam	+	M-D
5	19	DL	Cervical	Composite	+	D
6	14	DP	Cervical	Amalgam	+	M
7	19	DL-ML	Cervical	Reinforced GI	-	—
8	18	DL-ML	Cervical	Amalgam	+	D
9	14	DP	Cervical	Reinforced GI	+	M-D
	02	DP		Amalgam	+	D
10	18	DL-ML	Cervical	Amalgam	+	M
	31	ML-MF		Composite	+	M-D
11	18	DL	Middle	Amalgam	-	D
12	19	DL, MF	Cervical	Amalgam	-	M-D
13	30	ML	Cervical	Amalgam	-	M
14	18	DL, DV	Cervical	Amalgam	+	M-D
15	19	ML	Middle	Amalgam	-	M
16	30	DL	Cervical	Amalgam	-	D
17	14	DP	Cervical	Amalgam	-	D
18	19	DL	Cervical	Amalgam	-	D
19	19	DL	Cervical	Amalgam	+	D
20	30	DL	Cervical	Amalgam	+	D
	18	DL	Middle	Amalgam	-	M

DP = disto-palatal; ML = mesio-lingual; DL = disto-lingual; MF = mesio-facial; GI = glass-ionomer; D = distal; M = mesial.

**TABLE 1. PHOTOCURING TIMES AND INTENSITIES USED TO POLYMERIZE ENAMEL AND DENTIN BUILDUP.**

Buildup Location	Composite Shade (Vit-I-escence)	Polymerization Technique	Intensity (mW/cm <sup>2</sup> )	Time (seconds)
Palatal/lingual and proximal enamel	Pearl Amber/Pearl Smoke	Pulse + Progressive curing	200 + 300	3 + 40
Dentin	A5-A4-A3.5-A3-A2-A1	Progressive curing	300	40
Occlusal enamel	Pearl Frost/Pearl Neutral	Pulse	200 + 600	3 + 10 (occlusal) 10 (facial) 10 (palatal)

### Statistical Analysis

Data sets were treated as nominal and the Chi-square test ( $\chi^2$ ) and the Fisher's exact test were performed. Statistical analysis was conducted using the Statistical Package for the Social Sciences (SPSS Inc., Chicago, IL, USA).

### RESULTS

At the 30-month recall, all patients returned for composite resin restoration re-evaluation (Figure 10). No failures were reported and alpha scores were recorded for all parameters. However, a slight marginal chipping of the composite

resin in one tooth, related to an occlusal discrepancy, was recorded at the 2-week recall. Occlusion was adjusted and no further chipping was observed going forward.

Statistical analysis was performed using a Chi-square test ( $\chi^2$ ) and the

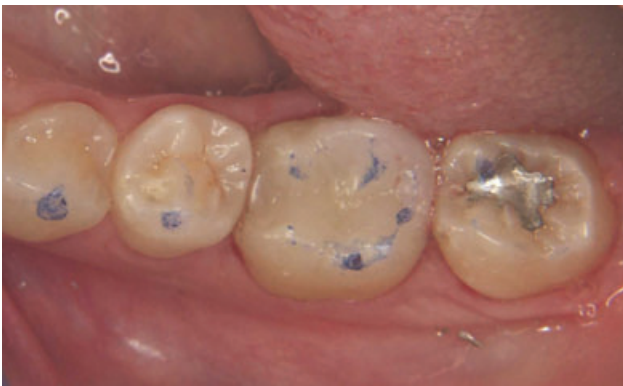

Figure 9. Postoperative occlusal view of the final restorations after occlusion checking.

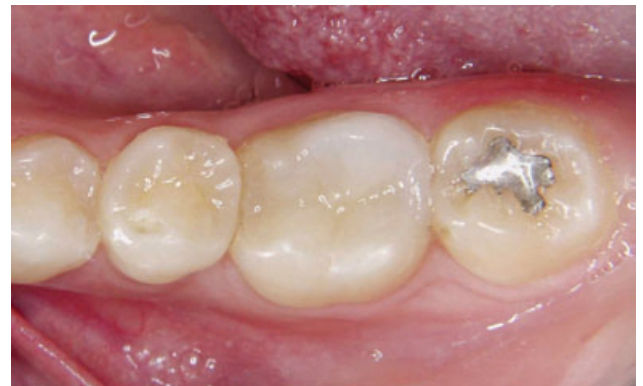

Figure 10. Result at the 30-month recall.

TABLE 3. MODIFIED USPHS CRITERIA USED FOR DIRECT CLINICAL EVALUATION OF THE RESTORATIONS.

Score	Alfa	Bravo	Charlie	Delta
Surface texture	Sound	Rough	—	—
Anatomical form	Sound	Slight loss of material (chipping, clefts), superficial	Strong loss of material (chipping, clefts), profound	Total or partial loss of the bulk
Marginal integrity (enamel)	Sound	Positive step, removable by finishing	Slight negative step, not removable, localized	Strong negative step in major parts of the margin, not removable
Marginal discoloration (enamel)	None	Slight discoloration, removable by finishing	Discoloration, localized, not removable	Strong discoloration in major parts of the margin, not removable
Secondary caries	None	Caries present	—	—
Gingival inflammation	None	Slight	Moderate	Severe
Restoration color stability	No change	Change of color in comparison with baseline condition	—	—
Preoperative sensitivity (air)	None	Yes	—	—
Postoperative sensitivity (air)	None	Moderate	Severe	—

Fisher's exact test. Sixteen out of 25 teeth (64%) exhibited preoperative sensitivity to air ( $\chi^2 = 10.6$ ;  $p = 0.001$ ). A significant difference in tooth sensitivity was reported after completing the restoration, with no tooth exhibiting sensitivity both at the 2-week recall and the 30-month follow-up ( $\chi^2 = 23.5$ ;  $p < 0.0001$ ) (Figure 11).

DISCUSSION

An indirect restoration is considered the treatment of choice when a cusp is lost.<sup>18</sup> However, amalgam has been the material of choice in the restoration of direct cuspal coverage of posterior teeth. Smales and Hawthorne<sup>19</sup> found a 66.7% survival rate after 10 years and a 47.8% survival rate after 15 years for large cusp-covered amalgam restorations; Plasmans and colleagues<sup>20</sup> observed a retention rate of 88% after 8 years for similar restorations and reported a higher failure rate for patients older than

30 years. McDaniel and colleagues<sup>21</sup> reported the result of a survey which revealed that the leading cause of failure among cuspal coverage amalgam restorations was tooth fracture. They assumed the main reason for failure was a too-conservative tooth preparation; they recommended replacing weak cusps with restorative material when placing large amalgam restorations. Alternatively, a catastrophic failure of the tooth can occur, resulting in nonrestorability.

Previous laboratory studies on cusp-replacing RBC indicated that the tooth-restoration interface failure was more probable than composite material failure.<sup>22-24</sup> These findings suggest that both physical and mechanical properties of composite resins have dramatically improved in the last decade.<sup>25</sup>

Neither long-term nor short-term data are available on the clinical

performance of direct cusp-replacing RBC restorations. The latter have been considered as interim restorations for teeth with questionable prognosis and placed in patients with financial limitations or medically compromised histories.<sup>14,26</sup> Minimal sacrifice of sound tooth structure is required when selecting RBC restorations, even in severely compromised teeth; cusps with 1- to 1.5-mm remaining enamel-dentin thickness were preserved in this study. No retention or resistance forms were included in the cavity preparation; RBC restoration retention relied only on the adhesion of the composite resin to the tooth structure. The use of modern adhesive systems and composite resin may enable the reinforcement of residual tooth structure.<sup>27</sup> Further clinical evaluation is required to assess the durability of the composite bond to both enamel and dentin over time in a similar scenario. This consideration is valid for both direct and indirect restorations that require an adhesive cementation protocol.

Although this study references a short observation period and a limited patient sample, a similar clinical performance may be considered satisfactory, even for conventional two-surface RBC restorations. Surprisingly, no postoperative sensitivity was experienced both at the 2-week and 30-month recall. Postoperative sensitivity has been a concern when placing posterior RBC

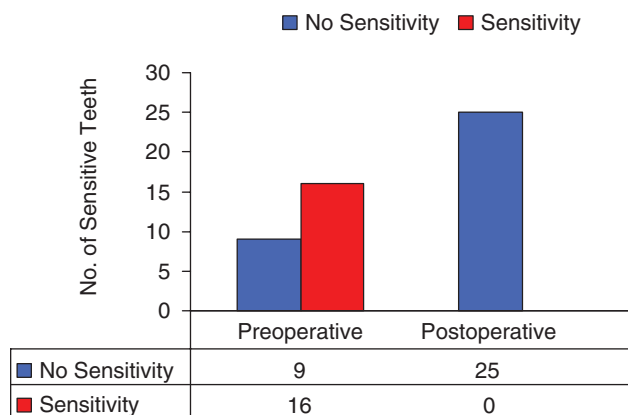


Figure 11. Comparison between preoperative and postoperative tooth sensitivity with no sensitivity recorded at the 2-week and 30-month follow-up.

restorations for over 15 years.<sup>28</sup> Polymerization shrinkage of RBC may result in the formation of a gap at the restoration cavosurface margin; increased incidence of symptoms from masticatory forces and/or cold stimuli have been reported. Several factors may be responsible for the reduced post-operative sensitivity reported in this study. In an effort to overcome this issue, particular attention was paid on adopting accurate layering and curing protocols<sup>16</sup>; the correct use of modern adhesive systems may also contribute positively to the final outcome.

Alpha scores were reported for all USPHS parameters. Interestingly, no cusp fracture was observed for molar teeth with both one and two missing cusps. One patient reported composite chipping at the 2-week recall, related to incorrect occlusion; once adjusted, no further chipping was recorded. It is key to carefully analyze and balance occlusion both in static and dynamic relation; the enamel–dentin thickness of both the fractured and remaining cusps is also paramount in achieving adequate clinical success. Teeth having cavity wall thickness less than 1 mm, as well as patients with para-functional habits, were excluded from the study.

Early direct RBCs experienced high wear rates. This loss of anatomic shape led to the deleterious expo-

sure of cavity margins; moreover, marginal breakdown and marked technical sensitivity resulted in compromised RBC restorations, especially in the molar region.<sup>2</sup>

Conversely, present-day RBCs exhibit mechanical and physical properties superior to those of their predecessors. Wear of current direct composite resin is estimated to be around 10 to 15  $\mu\text{m}$  per year<sup>29</sup>; and amalgam at about 10  $\mu\text{m}$  per year more than occlusal enamel.<sup>4</sup>

Kuijs and colleagues<sup>25</sup> reported that ceramic, indirect composite resin, and direct composite resin restorations used for cusp-replacing adhesive restorations provide comparable fatigue resistance and exhibit comparable failure modes in case of fracture. Clinical studies corroborate this laboratory finding.<sup>28,30,31</sup> However, indirect restorations were considered as the ideal alternative to direct RBC restorations in the last two decades.

Direct chairside composite resin inlay/onlay restorations have gained popularity in the 1980s. The restoration is formed directly in the cavity; after an initial cure, it is removed from the cavity and postcured in a heat-and-light oven. Improved mechanical and physical properties are expected compared with direct light-cured-only composite, mainly due to the overall increase in conversion.<sup>32,33</sup> Higher

stress relaxation and improved marginal adaptation is also expected. Shrinkage is limited to a thin luting composite resin layer.<sup>34,35</sup>

Short-term clinical evidence has showed little or no failure for direct inlay/onlays.<sup>36–38</sup> However, Wassell and colleagues<sup>39</sup> reported a greater number of episodes of postoperative sensitivity and a trend toward higher failure rates for direct inlays. The same findings were reported by other authors.<sup>28</sup> Peutzfeldt and Asmussen<sup>40</sup> reported that improved physical properties produced by postcuring are composite dependent. It was suggested that the superior mechanical strength of heat-treated composite resin was only short-lived.<sup>41,42</sup> This was confirmed by long-term clinical studies reporting no difference in clinical mechanical properties between direct and direct heat-treated composite resin inlay/onlay restorations.<sup>28,43,44</sup> Indirect laboratory-processed composites also gained increased popularity over the last decade. Heat, pressure, and nitrogen atmospheric treatment may be combined to form a relatively void-free well-polymerized resin matrix, in an attempt to improve the wear resistance of composite resin. However, the basic chemistry of indirect RBCs remains similar to that of the direct materials; differences in mechanical properties are minimal and not expected to be clinically significant.<sup>30</sup>



Mandikos and colleagues<sup>45</sup> reported no improvement of second-generation indirect RBCs' (Artglass, belleGlass, Sculpture, Targis) mechanical properties when compared with a first-generation indirect RBC (Concept).

Ceramic restorations are even more costly and require elaborate and time-consuming techniques than direct composite resin restorations.<sup>46</sup> Success depends on factors influencing the strength of a ceramic restoration such as the design of a cavity preparation, the shape of the restoration, and internal fit. Wear of the resin cement is a concern when placing ceramic restorations. Optimum marginal fit is mandatory in achieving longevity. A detectable wear of luting composite resin after 8 months of clinical service was reported by Pallesen and van Dijken.<sup>47</sup> After 8 years, they found clinically marked wear and minor chipping of both the enamel and ceramic inlays. Similar findings were reported by Kramer and Frankenberger.<sup>48</sup> This phenomenon may not be relevant at the cavosurface margins of an indirect composite resin inlay.<sup>49</sup>

Thordrup and colleagues<sup>31</sup> reported no significant difference in survival between direct and indirect composite resin and ceramic inlays after 5 years of clinical service. Although the survival rate of the different types of inlay was considered acceptable, it was comparable

to the survival rate of direct RBC fillings reported in controlled clinical studies.<sup>49,50</sup> The authors questioned the premise that the cost benefit of indirect restorations is superior to direct RBC restorations. A recent literature review reported no significant difference in the longitudinal clinical behavior of posterior direct and indirect composite resin over a 3-year evaluation period.<sup>51</sup>

#### CONCLUSION

The evolution of adhesive and conservative dentistry has fostered the development of minimally invasive treatment alternatives for indirect restorations. The inherent limitations of this clinical study, related to both patient sample and short observation periods, may be impacted with technological advancement of dental materials. Steady improvement of adhesive systems, along with advances in composite resin and light-curing technology, may render the use of direct RBC in reconstructing severely damaged teeth commonplace among tomorrow's clinicians. Further laboratory and clinical studies are needed to help confirm the positive clinical performance reported in this study.

#### DISCLOSURE AND ACKNOWLEDGMENT

The authors do not have any financial interest in the companies whose materials are discussed in this article.

The authors would like to express their gratitude to Ultradent Inc. for providing the materials.

#### REFERENCES

1. ADA Council On Scientific Affairs. Statement on posterior resin based composite. ADA Council on Dental Benefit Program. *J Amer Dent Assoc* 1998;129:1627-8.
2. Roulet JF. Benefits and disadvantages of tooth-coloured alternatives to amalgam. *J Dent* 1997;25:459-73.
3. Hickel R, Manhart J. Longevity of restorations in posterior teeth and reasons for failure. *J Adhes Dent* 2001;3:45-64.
4. Christensen GJ. Amalgam vs. composite resin. *J Amer Dent Assoc* 1998;129:1757-9.
5. Swift EJ Jr., Perdigao J, Wilder AD, et al. Clinical evaluation of two one-bottle dentin adhesives at three years. *JADA* 2001;132:1117-23.
6. Van Meerbeek B, Peumans M, Verschueren M, et al. Clinical status of ten dentin adhesive systems. *J Dent Res* 1994;73:1690-702.
7. Van Meerbeek B, Perdigao J, Lambrechts P, Vanherle G. The clinical performance of adhesives. *J Dent* 1998;26:1-20.
8. Van Meerbeek B, Vargas M, Inoue S, et al. Adhesives and cements to promote preservation dentistry. *Oper Dent* 2001;Supplement 6:119-44.
9. Hickel R, Manhart J, Garcia Godoy F. Clinical results and new developments of direct posterior restorations. *Am J Dent* 2000;13:41D-54D.
10. Liebenberg WH. Assuring restorative integrity in extensive posterior resin restorations: pushing the envelope. *Quintessence Int* 2000;31:153-64.
11. Deliperi S, Bardwell DN. Two-year clinical evaluation of non vital tooth whitening and resin composite restorations. *J Esthet Restor Dent* 2005;17:369-79.
12. Krejci I, Duc O, Dietschi D, de Campos E. Marginal adaptation, retention and fracture resistance of adhesive composite restorations on devital teeth with and without posts. *Oper Dent* 2003;28:127-35.

13. Deliperi S, Bardwell DN, Coiana C. Reconstruction of devital teeth using direct fiber-reinforced composite resins: a case report. *J Adhes Dent* 2005;7:165-71.
14. Denehy G, Cobb D. Impression matrix technique for cusp-replacement using direct composite resin. *J Esthet Restor Dent* 2004;16:227-34.
15. Deliperi S, Bardwell DN. Direct cuspal-coverage posterior composite resin restorations: a case report. *Oper Dent* 2006;31:143-50.
16. Deliperi S, Bardwell DN. An alternative method to reduce polymerization shrinkage in direct posterior composite restorations. *J Amer Dent Assoc* 2002; 133:1387-98.
17. Deliperi S, Bardwell DN, Congiu MD. A clinical challenge: reconstruction of severely damaged endo/bleached teeth using a microhybrid composite resin. Two year case report. *Pract Proced Aesthet Dent* 2003;15:221-6.
18. Shillingburg HT, Hobo S, Whitsett LD, et al. *Fundamentals of fixed prosthodontics*. Chicago (IL): Quintessence Publishing Books; 1997.
19. Smales RJ, Hawthorne WS. Long-term survival and cost-effectiveness of five dental restorative materials used in various classes of cavity preparations. *Int Dent J* 1996;46:126-30.
20. Plasmans PJJM, Creugers NHJ, Mulder J. Long-term survival of extensive amalgam restorations. *J Dent Res* 1998;77:453-60.
21. McDaniel JR, Davis RD, Murchison DF, Cohen RB. Causes of failure among cuspal-coverage amalgam restorations: a clinical survey. *J Amer Dent Assoc* 2000;131:173-7.
22. Kuijjs RH, Fennis WM, Kreulen CM, et al. Does layering minimize shrinkage stresses in composite restorations? *J Dent Res* 2003;82:967-71.
23. Fennis WM, Kuijjs RH, Kreulen CM, et al. Fatigue resistance of teeth restored with cuspal-coverage composite restorations. *Int J Prosthodont* 2004;17:313-7.
24. Fennis WM, Kuijjs RH, Barink M, et al. Can internal stresses explain the fracture resistance of cusp-replacing composite restorations? *Eur J Oral Sci* 2005; 113:443-8.
25. Kuijjs RH, Fennis WM, Kreulen CM, et al. A comparison of fatigue resistance of three materials for cusp-replacing adhesive restorations. *J Dent* 2006;34:19-25.
26. Magne P. Conservative restoration of compromised posterior teeth with direct composites: a 7-year report. *Pract Periodontics Aesthet Dent* 2000;12:747-9.
27. Roeters JJ. Extended indications for directly bonded composite restorations: a clinician's view. *J Adhes Dent* 2001;3:81-7.
28. Pallesen U, Qvist V. Composite resin fillings and inlays. An 11-year evaluation. *Clin Oral Investig* 2003;7:71-9.
29. Leinfelder KF, Yarnell G. Occlusion and restorative materials. *Dent Clin North Am* 1995;39:355-61.
30. Swift EJ Jr. Processed composites. *J Esthet Restor Dent* 2001;13:284.
31. Thordrup M, Isidor F, Horsted-Bindslev P. A 5-year clinical study of indirect and direct resin composite and ceramic inlays. *Quintessence Int* 2001;32:199-205.
32. Wendt SL Jr. The effect of heat used as a secondary cure upon the physical properties of three composite resins. I. Diametral tensile strength, compressive strength, and marginal dimensional stability. *Quintessence Int* 1987;18:265-71.
33. Wendt SL Jr. The effect of heat used as secondary cure upon the physical properties of three composite resins. II. Wear, hardness, and color stability. *Quintessence Int* 1987;18:351-6.
34. Wendt SL Jr. Microleakage and cusp fracture resistance of heat-treated composite resin inlays. *Am J Dent* 1991;4:10-14.
35. Shortall AC, Baylis RL. Microleakage around direct composite inlays. *J Dent* 1991;19:307-11.
36. Wendt SL Jr., Leinfelder KF. Clinical evaluation of a heat-treated resin composite inlay: 3-year results. *Am J Dent* 1992;5:258-62.
37. Krejci I, Guntert A, Lutz F. Scanning electron microscopic and clinical examination of composite resin inlays/onlays up to 12 months in situ. *Quintessence Int* 1994;25:403-9.
38. van Dijken JWV. A 6-year evaluation of a direct composite resin inlay/onlay system and glass ionomer cement-composite resin sandwich restorations. *Acta Odontol Scand* 1994;52:368-76.
39. Wassell RW, Walls AW, McCabe JF. Direct composite inlays versus conventional composite restorations: three-year clinical results. *Brit Dent J* 1995; 179:343-9.
40. Peutzfeldt A, Asmussen E. The effect of postcuring on the quantity of remaining double bonds, mechanical properties, and in vitro wear of two resin composites. *J Dent* 2000;28:447-52.
41. Ferracane J, Condon JR. Post-cure heat treatment for composites: properties and fractography. *Dent Mat* 1992;8:290-5.
42. Kildal KK, Ruyter IE. How different curing methods affect mechanical properties of composites for inlays when tested in dry and wet conditions. *Eur J Oral Sci* 1997;105:353-61.
43. van Dijken JWV. Direct resin composite inlays/onlays: an 11 year follow-up. *J Dent* 2000;28:299-306.
44. Wassell RW, Walls AW, McCabe JF. Direct composite inlays versus conventional composite restorations: 5-year follow-up. *J Dent* 2000;28:375-82.
45. Mandikos MN, McGivney GP, Davis E, et al. A comparison of the wear resistance and hardness of indirect composite resins. *J Prosthet Dent* 2001;85:386-95.
46. Liebenberg WH. Partial-coverage posterior ceramic restorations. Part 1: a return to diligence. *J Esthet Restor Dent* 2001;13:296-303.
47. Pallesen U, van Dijken JWV. An 8-year evaluation of sintered ceramic and glass ceramic inlays processed by the Cerec CAD/CAM system. *Eur J Oral Sci* 2000;108:239-46.
48. Kramer N, Frankenberger R. Leucite-reinforced glass-ceramic after six years: wear of luting composites. *Oper Dent* 2000;25:466-72.
49. Rasmusson CG, Lundin SA. Class II restorations in six different posterior composite resins: five-year results. *Swed Dent J* 1995;19:173-82.
50. Barnes DM, Blank LW, Thompson VP, et al. A 5- and 8-year clinical evaluation of a posterior composite resin. *Quintessence Int* 1991;22:143-51.
51. Hickel R, Manhart J. Longevity of restorations in posterior teeth and reasons for failure. *J Adhes Dent* 2001;3:45-64.

---

Reprint requests: Dr. Simone Deliperi, Via G. Baccelli, 10/b 09126 Cagliari, Italy; Tel.: +39 347 953 3259; Fax: +39 070 302588; e-mail: [simone.deliperi@tufts.edu](mailto:simone.deliperi@tufts.edu)  
©2006 Blackwell Publishing, Inc.

Copyright of Journal of Esthetic & Restorative Dentistry is the property of Blackwell Publishing Limited and its content may not be copied or emailed to multiple sites or posted to a listserv without the copyright holder's express written permission. However, users may print, download, or email articles for individual use.