

Predictable Periimplant Gingival Esthetics: Use of the Natural Tooth as a Provisional following Implant Placement

ROBERT C. MARGEAS, DDS*

ABSTRACT

Maintaining the interdental papilla and bone height following implant placement has been a challenge for the restorative dentist. Bone resorption following anterior tooth extraction is common and often compromises the esthetics of the final restoration. The tissue must be maintained during the surgical and healing phases to achieve an esthetic outcome. Using the patient's natural tooth as a provisional can help maintain the volume and support the papilla. This article describes a technique to achieve maximum esthetics and preservation of tissue following tooth extraction and implant placement.

CLINICAL SIGNIFICANCE

By using the patient's extracted natural tooth, the tissue should maintain itself with minimal recession. This will allow for a more esthetic outcome.

(J Esthet Restor Dent 18:5–12, 2006)

Patients' esthetic demands and expectations are becoming greater every day. The clinician must be able to deliver uncompromised esthetics along with ideal function following implant surgery.

An implant that is osseointegrated does not always have esthetic success.¹ To be considered successful, an implant-supported restoration must achieve a harmonious balance between functional, esthetic, and biologic imperatives. This concept has resulted in the development of "restoration-driven implant placement," in which implants are positioned in relation

to anticipated requisites of the restorative phase rather than the availability of bone.²

If there is not adequate bone available where the implant must be placed, alternative procedures such as bone augmentation must be performed. Since the implant replaces the root of the missing tooth, the transition between the properly sized implant and the anatomic crown must be harmonious to establish an esthetic emergence profile.³

To achieve natural soft tissue esthetics, the contour, height, and width of the gingiva at the implant

site must correspond to the soft tissues that surround the adjacent teeth. Adequate bone must exist for placement of the implant, along with proper soft tissue framing that consists of interproximal papillae and an adequate zone of attached gingiva.³

A patient's goal is not just successful integration but being able to function and have an esthetic restoration. Since esthetics in the anterior region is critical, the use of the patient's natural tooth as a provisional allows the tissue to heal in the exact cervical contour and emergence profile of the definitive

*Adjunct professor, Department of Operative Dentistry, University of Iowa College of Dentistry, Iowa City, and private practice, Des Moines, IA, USA

prosthesis. Immediate placement of the extracted natural tooth crown following implant placement will maintain the volume and profile of the soft tissue contour.⁴

Clearly, immediate implantation in extraction sites can no longer be considered an experimental technique. Numerous studies have shown short- and medium-term survival rates that are comparable to those with conventional techniques involving delayed implantation.^{5,6}

Defining a strict protocol is imperative to produce consistent results. As outlined in his report of 14 cases, Wohrle immediately loaded only those implants that torqued to 45 Ncm or more.⁷ Similarly, Malo and colleagues, using machined-surface implants, required an insertion torque of 40 Ncm.⁸ Although 40 Ncm is necessary during immediate loading, it is not sufficient to establish a perfect diagnosis of stability. The success of the immediate implant placement procedure depends on the primary stability of the implant, attained by drilling the bone beyond the extraction site. It is not early loading that creates the effect of fibrosis encapsulation but, rather, micromovements at the bone-implant interface resulting from inadequate primary stability.⁹ In both studies the occlusion was protected by adjacent teeth. All

occlusal, working, and non-working contacts were eliminated.

Recession following tooth removal presents a unique restorative challenge. The most difficult area to preserve is the papilla. We must do everything possible to maintain the volume of tissue and prevent shrinkage. The most effective way of maintaining papilla and soft tissue height is to prevent its loss at the time of extraction. The gingival architecture must be maintained and supported immediately following extraction. This requires a precise surgical technique that does not remove interproximal or facial bone. The extraction must be as atraumatic to the tissue as possible. In the ideal situation, incising of the papilla should not occur.

Flapless surgery is more difficult because of the lack of visibility of the bone level. Sometimes the implant can be placed deeper than is ideal owing to limited visual access.

Critical to the preservation of tissue height is control of the gingival embrasure at the time of extraction. If the embrasure space is not filled with a provisional that is equal in volume to that of the extracted tooth, the papilla and surrounding tissue will lack support, causing the gingival scallop to flatten and the interproximal papilla to recede.¹⁰

Before extraction of the tooth, the gingival form and bony architecture must be evaluated. If the tissue and bone are acceptable, then the objective is to preserve as much of the original form as possible. If there is facial bone loss, a degree of recession can be expected. The bone is needed to maintain and support the overlying tissues. The predictability of treatment is also influenced by the thickness of the periodontium as thicker tissues have a reduced tendency to recede.

This article presents a technique to minimize the duration of treatment time and preserve the hard and soft tissue contours. This procedure also eliminates the necessity of a removable provisional prosthesis as it involves immediate placement and the provisionalization of a single-stage implant using the patient's extracted tooth. Although a removable partial denture could be used as a provisional restoration, there is a greater risk of effecting tissue changes owing to the movement of the prosthesis. When incorporating this current procedure, the patient must be compliant and understand that no occlusal force can be applied on the provisional.

CASE REPORT

A 50-year-old male presented with apical resorption and discomfort of his lower right cuspid. The patient reported a history of trauma to the

area several years earlier. Upon consultation with an endodontist, it was determined that the tooth had a questionable prognosis for long-term success. The patient was given several treatment options, including a fixed partial denture, removable appliance, or single-tooth implant restoration. The patient opted for a single-tooth implant with a cemented restoration.

Both clinical and radiographic examinations revealed no signs of active infection. Probing depths were within normal limits. The patient was informed that possible modifications to the tissue might be necessary if there were significant gingival changes following surgery. The patient presented with an ideal tissue type—thick with excellent bony support. Approximately 85% of the population present with thick, flat periodontal forms, whereas the periodontal architecture of the remaining population is

thin and scalloped.¹¹ Although the amount of postoperative soft tissue modification is generally minimal for patients with thick and flat gingiva, significant changes have been observed in those with the thin and scalloped type.¹²

The projected interproximal tissue height depends on the interproximal bone height of the adjacent teeth. Bone sounding of the teeth adjacent to the failing tooth can ascertain predictable interproximal tissue height.

Maintenance of gingival tissues and papillae can be a demanding task when using a full periosteal flap reflection. Several reports have proposed implant placement without flap elevation to minimize bone loss.^{13,14} Although initial results appear promising, the lack of direct visibility in flapless surgery may present limitations that require careful evaluation of the osseous

topography as well as meticulous surgical execution.¹⁵

Prior to the extraction of the tooth, stone models were made and a putty index was formed over the teeth (Figure 1). This was later used to help guide the tooth onto the implant abutment in the proper orientation following surgery.

Local anesthetic was administered, and periostomes were used to loosen the periodontal ligament. The tooth was removed atraumatically without reflecting a flap.

A 13 mm Straumann (Straumann, Basel, Switzerland) standard-diameter 4.1 mm implant with a 4.8 mm collar was inserted with the top of the implant placed 3 mm from the final proposed gingival margin. A 16 mm guide is shown in Figure 2. Ideally, the 1 mm polished collar should be above the bone level. With a

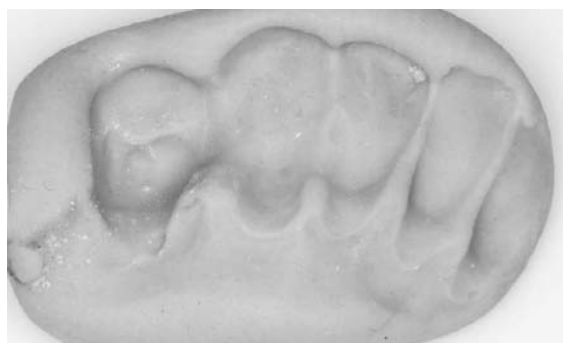

Figure 1. Fabrication of a putty matrix prior to the extraction of the tooth.

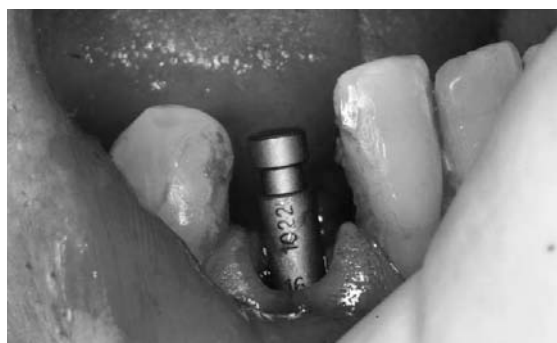

Figure 2. A guide pin is used to measure the depth of the implant.

flapless surgery, this is sometimes difficult to visualize.

A Straumann 7.0 mm solid abutment was placed and hand torqued, being careful not to turn the implant (Figure 3). No preparation was necessary as this is a stock component and the occlusion did not interfere.

The patient's extracted tooth was to serve as the provisional restoration while healing occurred (Figure 4).

The root was sectioned horizontally with a diamond bur (Brasseler, USA, Savannah, GA, USA) 3 mm from the cementoenamel junction (Figure 5). The tooth was hollowed out to fit over the abutment (Figure 6). After confirming an accurate fit, the tooth was etched for 30 seconds (Figure 7). A bonding agent (Bisco D/E resin, Bisco Inc., Schaumburg, IL, USA) was applied (Figure 8) and light cured for 20 seconds (Figure 9). A bis-acryl material (Temptation, Clinician's Choice, New Milford,

CT, USA) was injected into the tooth (Figure 10), which was then placed onto the abutment with the use of the putty index (Figure 11). This was allowed to fully polymerize for 2 minutes. It is difficult to get an accurate margin when relining a provisional, so it is necessary to reline the margins out of the mouth with a flowable resin. This resin adheres to the bis-acryl material well. A laboratory implant analog with an actual 7 mm solid abutment was later used to reline

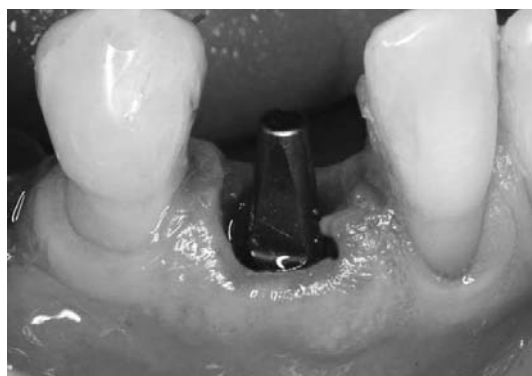

Figure 3. A 7.0 mm solid abutment is hand tightened on the implant.

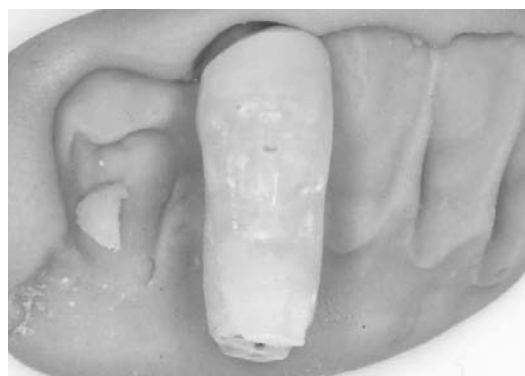


Figure 4. Patient's extracted tooth.

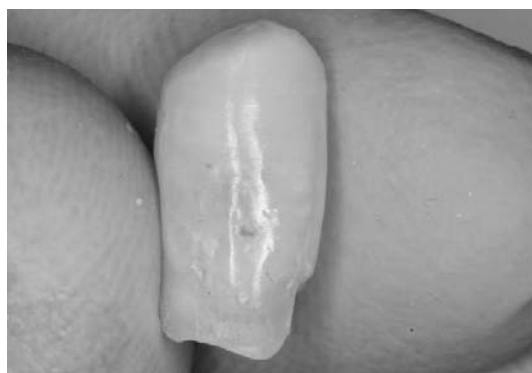

Figure 5. The root is sectioned horizontally 3 mm from the cementoenamel junction.

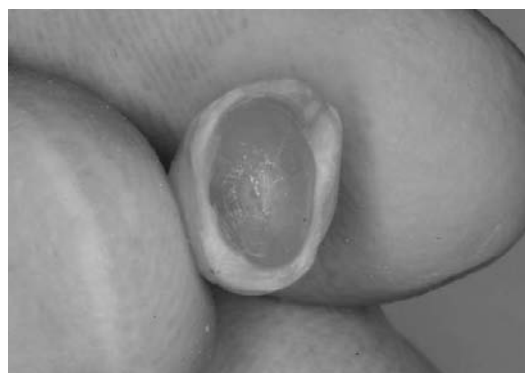

Figure 6. The tooth is hollowed out to fit over the abutment.

the final margins (Figure 12). The provisional did not fit the margins accurately, as is seen in Figure 13. The flowable resin was manipulated around the margins (Figure 14) and light cured. Once the flowable resin had polymerized, it was polished with finishing burs and disks. The final relined is shown in Figure 15. A thin layer of Zone temporary cement (Dux Dental, Oxnard, California, USA) was placed in the provisional (Figure 16), which was then put on the laboratory analog

to remove the excess cement prior to placing it in the mouth (Figure 17). This procedure allows only a minimal amount of cement to engage the abutment and prevents excess cement from irritating the tissue (Figure 18).

It is important to have a fairly flat emergence profile on the facial aspect to help decrease tissue recession. Interproximal support should be carefully achieved. The tooth was out of occlusion and there were

no contacts in centric or excursive movements. The tooth on the day of surgery is shown in Figures 19 and 20.

The patient was advised against using the surgical site and that care should be taken when performing oral hygiene. After 2 months of healing, the patient returned for a tissue check. The free gingival margin had maintained itself without recession (Figures 21 and 22). The 2-month postoperative radiograph

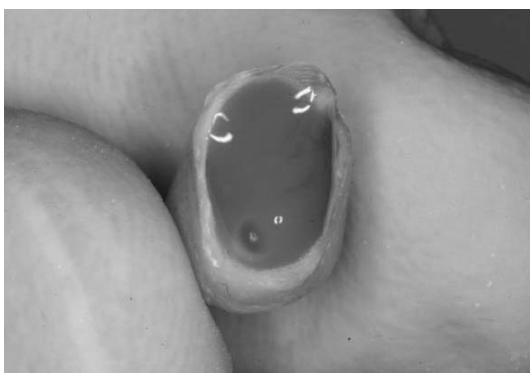

Figure 7. The tooth is etched for 30 seconds.

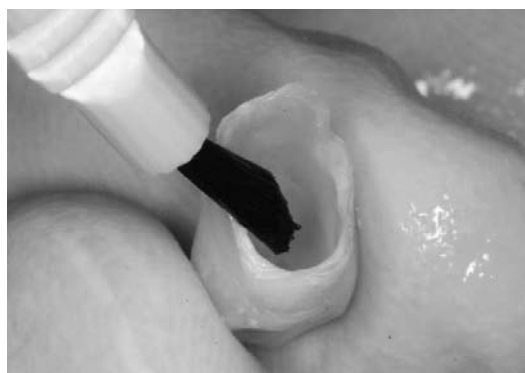

Figure 8. A bonding agent is applied and air dried.

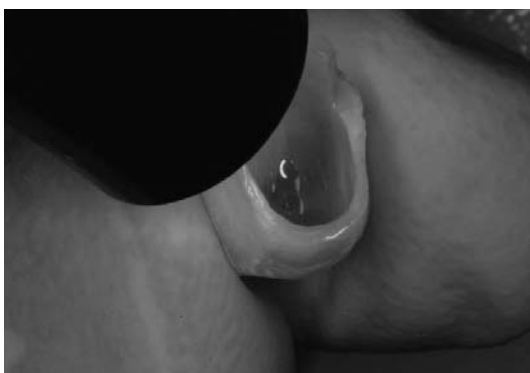

Figure 9. The bonding agent is light cured for 20 seconds.

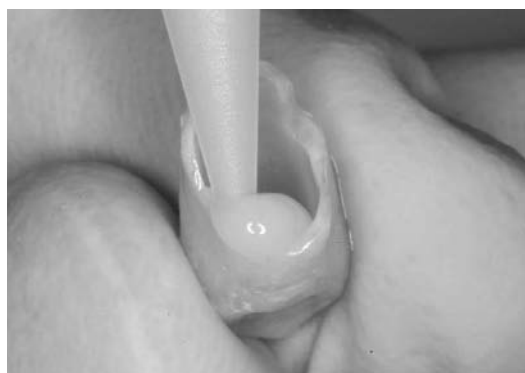

Figure 10. A bis-acryl is applied to the inside of the tooth.

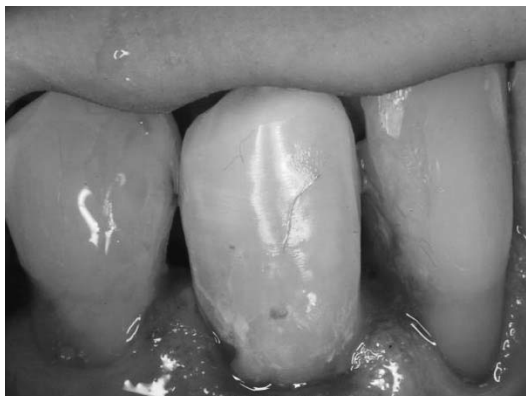

Figure 11. The tooth is placed on the abutment and allowed to cure for 2 minutes.



Figure 12. An implant analog with corresponding abutment is used later to reline the provisional because of inaccurate margins.



Figure 13. The provisional does not fit the margins accurately.

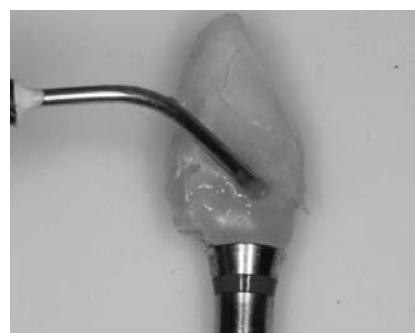

Figure 14. A flowable resin is used to reline the margins.



Figure 15. Final reline of provisional margins.

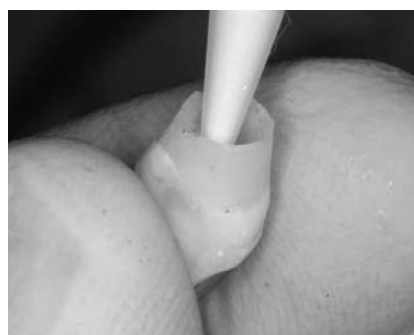

Figure 16. Zone cement is injected into the provisional.

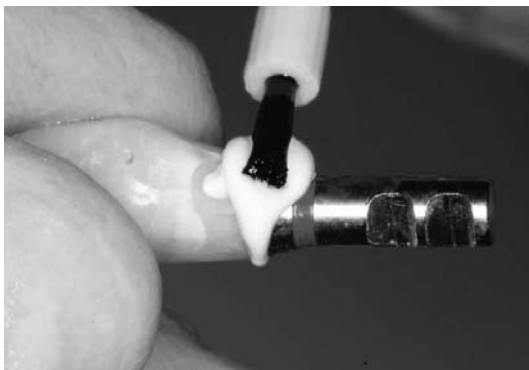


Figure 17. The provisional is placed on the implant analog abutment, and excess cement is removed prior to placement of the provisional in the mouth (as first described by Frank Higginbottom, DDS).

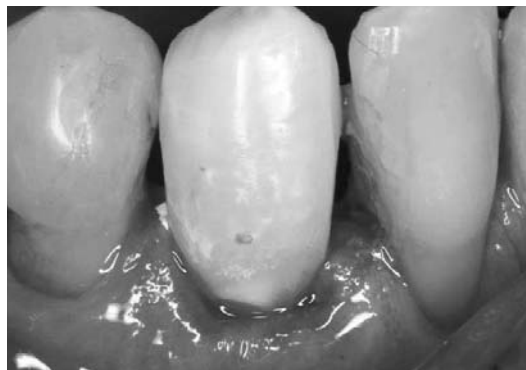

Figure 18. The provisional is placed on the abutment with minimal excess cement.

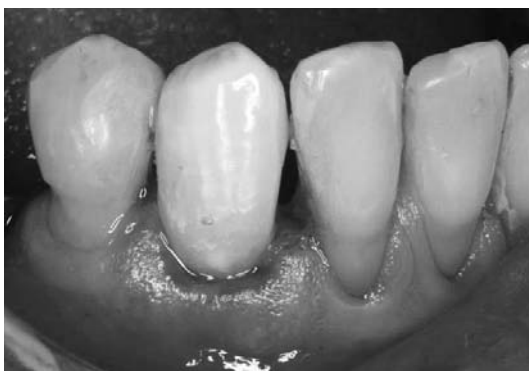

Figure 19. Tooth cemented on the abutment on the day of surgery.

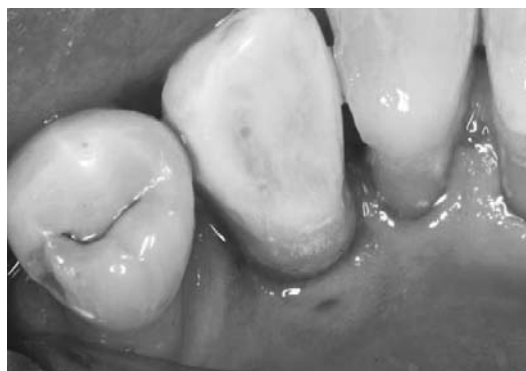

Figure 20. Lingual view on the day of surgery.

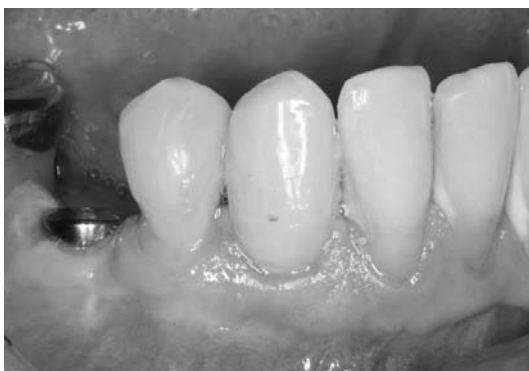

Figure 21. Provisional at 2 months postoperative.

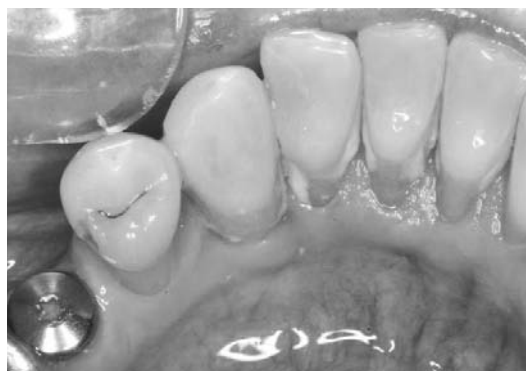

Figure 22. Lingual view at 2 months postoperative.

(Figure 23) reveals a perfect fit of the provisional restoration. The placement of the final restoration could begin.

CONCLUSIONS

Immediate implantation in extraction sites can no longer be considered an experimental technique. When indicated, immediate implant placement and provisionalization after extraction enable the maintenance of esthetics and phonetics during the healing phase. The combined approach, with a single-stage implant and non-loaded provisional, reduces the number of surgeries, delivers significant comfort, and reduces

the healing time for the final restoration versus the two-stage approach. More importantly, this approach achieves the preservation of the gingival architecture and papillae.

DISCLOSURE AND ACKNOWLEDGMENTS

The author would like to acknowledge the expertise of oral surgeon John Maletta, DDS, MS.

The author does not have any financial interest in the companies whose materials are discussed in this article.

REFERENCES

1. Saadoun AP. The key to peri-implant esthetics: hard and soft tissue management. *Dent Implantol Update* 1997;8(6):41-6.
2. Garber DA, Belser UL. Restoration-driven implant placement with restoration-generated site development. *Compend Contin Educ Dent* 1995;6:796-804.
3. Saadoun AP, LeGall M, Touati B. Selection and ideal tridimensional implant position for soft tissue aesthetics. *Pract Periodontics Aesthet Dent* 1999;11:1063-72.
4. Garber DA, Salama H, Salama MA. Two stage versus one stage—is there really a controversy? *J Periodontol* 2001;72:417-21.
5. Schwartz-Arad D, Chaushu G. Placement of implants into fresh extraction sites: 4 to 7 years retrospective evaluation of 95 immediate implants. *J Periodontol* 1997;68:1110-6.
6. Polizzi G, Grunder U, Goene R, et al. Immediate and delayed implant placement into extraction sockets: a 5-year report. *Clin Implant Dent Relat Res* 2000;2:93-9.
7. Wohrle PS. Single tooth replacement in the aesthetic zone with immediate provisionalization: fourteen consecutive case reports. *Pract Periodontics Aesthet Dent* 1998;10:1107-16.
8. Malo P, Rangert B, Dvarsater L. Immediate function of Branemark implants in the esthetic zone: a retrospective clinical study with 6 months to 4 years of follow-up. *Clin Implant Dent Relat Res* 2000;2:138-46.
9. Szmukler-Moncler S, Piattelli A, Favero GA, et al. Considerations preliminary to the application of early and immediate loading protocols in dental implantology. *Clin Oral Implants Res* 2000;11:12-25.
10. Meyenberg KH, Imoberdorf MJ. The aesthetic challenges of single tooth replacement: a comparison of treatment alternatives. *Pract Periodontics Aesthet Dent* 1997;9:727-35.
11. Olsson M, Lindhe J. Periodontal characteristics in individuals with varying form of the upper central incisors. *J Clin Periodontol* 1991;18(1):78-82.
12. Salama H, Salama M. The role of orthodontic extrusive remodeling in the enhancement of soft and hard tissue profiles prior to implant placement. *Int J Periodontics Restorative Dent* 1993;13:312-33.
13. Wilderman MN. Exposure of bone in periodontal surgery. *Dent Clin* 1964;3:23-36.
14. Lansberg CJ, Bichacho N. Implant placement without flaps. A single-stage surgical protocol—part 1. *Pract Periodontics Aesthet Dent* 1998;10:1033-9.
15. al Ansari BH, Morris RR. Placement of dental implants without flap surgery. A clinical report. *Int J Oral Maxillofac Implants* 1998;13:861-5.

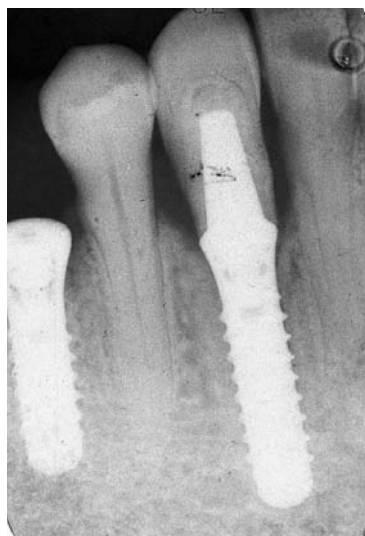

Figure 23. Radiograph at 2 months postoperative.

Reprint requests: Robert C. Margeas, DDS, 1233 63rd Street, Des Moines, IA, USA 50311; e-mail: rcmarge@aol.com

©2006 BC Decker Inc

Copyright of Journal of Esthetic & Restorative Dentistry is the property of Blackwell Publishing Limited and its content may not be copied or emailed to multiple sites or posted to a listserv without the copyright holder's express written permission. However, users may print, download, or email articles for individual use.