

## PROFILE



Ariel J. Raigrodski,  
DMD, MS

### Current Occupation

Director, Graduate Prosthodontics  
Extramural part-time private practice

### Education

Hebrew University School of Dental  
Medicine, Israel (1985–1988), BMedSc  
(1988)  
Hebrew University School of Dental  
Medicine, Israel (1988–1991), DMD (1991)  
Louisiana State University School of  
Dentistry, New Orleans, LA (1996–1999),  
Certificate in Prosthodontics (1999)  
School of Graduate Studies Louisiana State  
University Health Sciences Center, New  
Orleans, LA (1998–1999), MS (1999)  
Department of Prosthodontics, LSU School  
of Dentistry Fellowship in Esthetics and  
Implants, New Orleans, LA (1999–2000),  
Certificate (2000)

### Academic and Other Affiliations

Associate Professor and Director, Graduate  
Prosthodontics  
Private Practice Limited to Implant, Esthetic  
and Reconstructive Dentistry, Kenmore,  
WA

### Professional Memberships

Academy of Osseointegration  
American Academy of Fixed Prosthodontics  
American College of Prosthodontics  
International Association of Dental Research  
Washington State Society for  
Prosthodontics

### Positions Held

Member of Editorial Board, *Practical  
Procedures and Aesthetic Dentistry*  
(2001–Present)  
Member of Editorial Review Board, *Journal  
of Prosthodontics* (2004–Present)  
Member of Editorial Review Board, *Journal  
of Prosthetic Dentistry* (2004–Present)  
Member of Editorial Board, *Journal of  
Esthetic and Restorative Dentistry*  
(2003–Present)  
President, New Orleans Chapter of the  
American Association of Dental Research  
(2003–2004)

### Honors/Awards

Diplomate of the American Board of  
Prosthodontics (2001)  
Fellow of the American College of  
Prosthodontists (2001)  
Recipient of the "Claude R. Baker Faculty  
Award 2004" American Academy of Fixed  
Prosthodontics (2004)  
Fellow of the International College of  
Dentists (2007)

### Publications

More than 50 scientific publications,  
including peer-reviewed articles, research  
abstracts, book chapters, and textbooks.

### Hobbies/Personal Interests

Music, swimming, biking, and tennis

### Notable Contribution(s) to Dentistry

Involved with clinical and basic research of  
all-ceramics and CAD/CAM technology.

## Masters of Esthetic Dentistry

### Managing the Challenge of Crowning the Single Central Maxillary Incisor

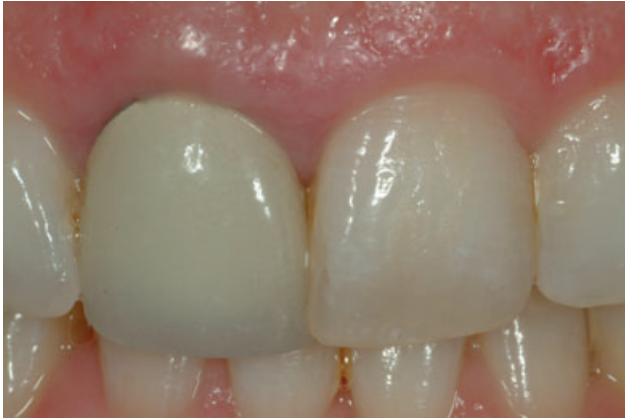ARIEL RAIGRODSKI, DMD, MS\*

Esthetic restorative dentistry presents multiple challenges for the restorative team. One of the most significant challenges is achieving an accurate match of a single maxillary central incisor crown. This procedure may very well be one of the most critical procedures in esthetic restorative dentistry. Accurate shade selection and shade matching are a paramount step for achieving a natural blending of the restoration with the adjacent dentition and the supporting tissues.<sup>1</sup> Clinicians and dental ceramists have been using multiple methods (including photos with shade guides, photos with customized shade tabs, computerized shade matching devices, and visits of the patient to the ceramist's office) to try and facilitate shade communication as well as an accurate reproduction of a restoration that generally mirrors the adjacent maxillary central incisor.

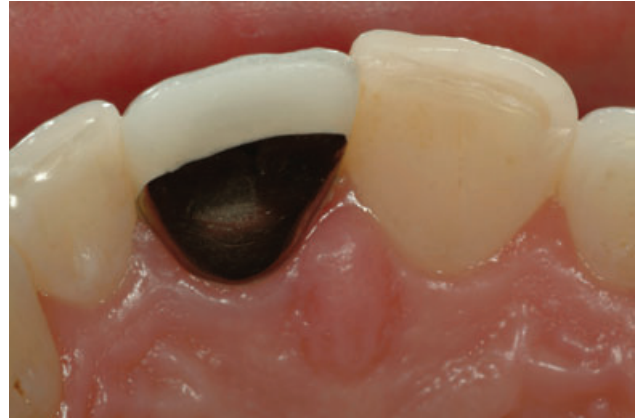The dilemma in shade selection, particular when a single maxillary

incisor has to be matched with a crown, lies primarily in the accuracy, predictability, and consistency of the shade selection process as related primarily to the value, hue, and chroma. However, the reproduction of other parameters such as accurate surface characterization, translucency and opacity, surface gloss, and internal and external characterizations must not be ignored in the attempt to achieve the perfect restoration.<sup>2,3</sup> The variety of new all-ceramic restorative materials, which not only present with different mechanical properties and different technologies of fabrication, but with different optical properties for both the core and the veneering porcelains, may contribute to the magnitude of the challenge the restorative team has to address. In addition, the increased chair time often required for the procedure does not guarantee a predictable result, and with increasing patients demand for immediate esthetic results, the need to try and

\*Associate professor and director, Graduate Prosthodontics, Department of Restorative Dentistry, University of Washington, Seattle, WA



*Figure 1. A frontal view of a failing metal-ceramic crown tooth #8. Note the exposed metal at the margins, the mismatch in shade, and the overlap with tooth #9.*



*Figure 2. An occlusal view of a failing metal-ceramic crown tooth #8. Note the palatal inclination of the crown.*

reproduce the restoration several times until the restorative dentist, the ceramist, and the patient are all satisfied, may be the cause of patients losing trust in the restorative team.

Conventional shade matching is a combination of art, science, and experience of both the restorative dentist and the dental ceramist. Many variables, such as metamerism, variations in lighting and illumination type, individual characterizations, and shade evaluator variations, have all contributed to the reduced predictability of providing the desired shade and characterizations for the prospective maxillary central incisor crown.<sup>4-6</sup>

Numerous shade guides have been developed through the years in order to enhance shade selection for

different types of porcelains and to enhance the communication between the restorative dentist and the dental ceramist.<sup>7-12</sup> However, the degree of success of these types of shade tabs is dependent not only on the illumination conditions and the level of tooth characterization but mostly on the subjective assessment and skill of the clinician in terms of accurate documentation of the desired shade and characterizations as well as the level of communication with the dental ceramist.

Generally, shade is communicated to the ceramist with a conventional shade prescription using the shade guide of choice and digital images. The supporting tissues must be healthy and not inflamed, and the dentition must be presented without plaque and debris. A digital image of the adjacent central incisor is taken with the

shade tab of choice (incisal edge to incisal edge) under controlled lighting conditions to visually acquire the information required to generate a shade prescription. The teeth must stay hydrated throughout the procedure to prevent a shift in the shade as well as in the internal characterization. However, care must be taken not to have excess saliva covering the dentition. Occlusal and frontal digital images with and without the shade tabs are taken as well as images of the prepared tooth. The images are used to draw a shade map with all internal characterizations, variations in chroma and translucency, as well as crack lines and decalcifications. Black and white digital images are used to facilitate the selection of the correct value, which is the most important color component for matching dental restorations (Figures 1–4).

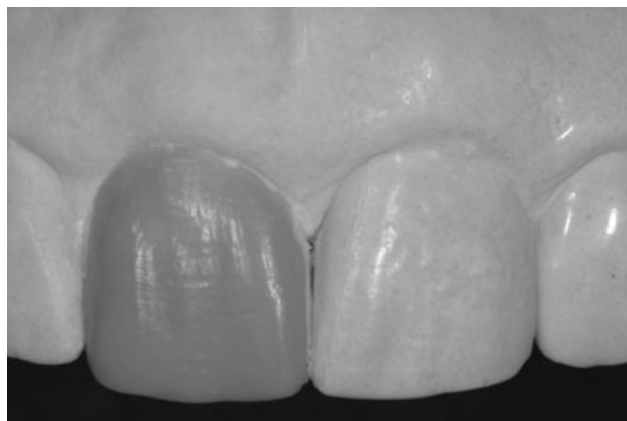

Figure 3. A frontal view of the diagnostic wax-up. Note the reproduction in wax of the surface texture and contours of the adjacent maxillary incisor.

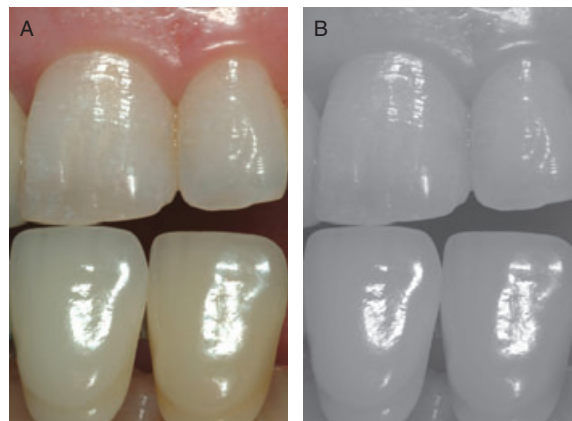


Figure 4. A,B, A frontal of Vita Lumin (Vita Zahnfabrik, Bad Sackingen, Germany) shade tabs with A1 and A2 tabs. Note the value is similar to the value of the tooth to be matched.

In an effort to reduce such variables related to shade selection and to reduce the subjective component of the procedure while facilitating the level of communication between the members of the restorative teams, several computerized shade selection devices have been developed to enhance an objective assessment of the shade of a tooth and to map it in different levels. Systems such as ShadeVision (X-Rite, Grandville, MI, USA), ClearMatch (Clarity Dental Corporation, Salt Lake City, UT, USA), ShadeEye NCC (Shofu Dental Corporation, Menlo Park, CA, USA), ShadeScan (Cynovad, Saint Laurent, Quebec, Canada), Spectro-Shade (MHT Optic Research AG, Niederhaslo, Switzerland), and others have gained certain popularity in the dental market. Most of these devices use either colorimeter or spectrophotometer technology,

which coincides with the Standard Commission Internationale de L'Eclairage  $L^*a^*b$  color space. However, scientific data on the ability of such devices to provide a consistent and predictable tooth shade matching are limited; although anecdotal evidence supports their use, studies have demonstrated that such devices can serve only as an adjunct to traditional shade selection procedures.<sup>13-15</sup> Thus, to date, computerized chair-side shade assessment systems may be considered a step forward in minimizing subjective variables for the fabrication of esthetic restorations; many of these systems provide a quality control feature for assessing the shade of the definitive restoration in the lab as compared to the image of the tooth to be matched, in an attempt to ensure adequate shade match prior to sending the restoration to

the clinician. However, one must bear in mind that the two-dimensional highly detailed maps generated by computerized shade assessment devices may not be regarded by the ceramist as an instant recipe for the tridimensional ceramic buildup over a metal or a ceramic coping. Rather, they may be regarded as an adjunct tool for facilitating the fabrication of a predictable restoration.

Other variables related to adequate matching rather than to the shade exclusively are critical for a challenging restoration such as that of the maxillary central incisor. Adequate shape and surface texture reproduction must be taken into account, and so the definitive impression should not only capture the prepared tooth and the supporting tissues, but it must accurately reproduce the surface

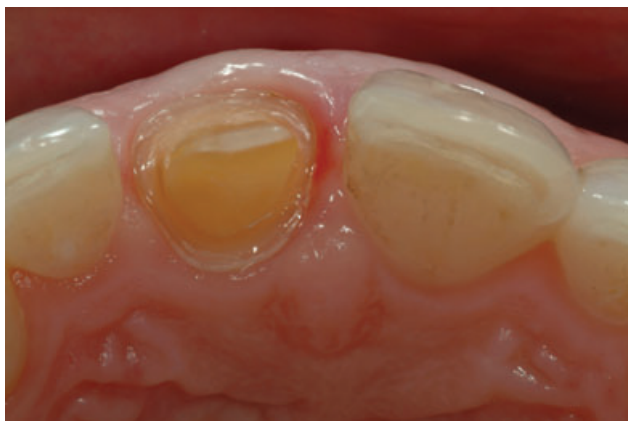

Figure 5. An occlusal view of the definitive preparation creating adequate space for the restorative material while managing the health of gingival tissues.

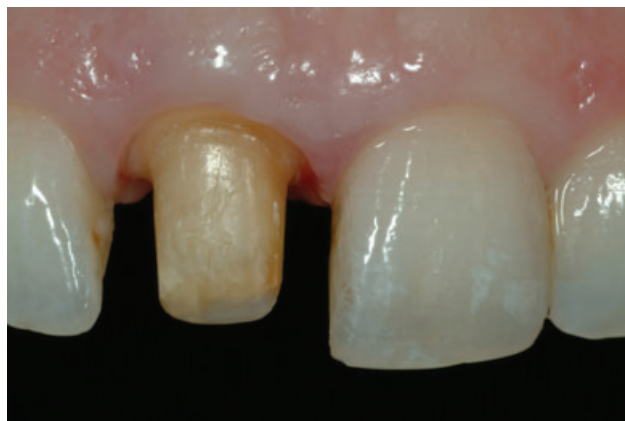

Figure 6. The tooth preparation has been refined with a rounded shoulder finish line. Note the color of the abutment tooth which may affect the definitive outcome based on the material selection.

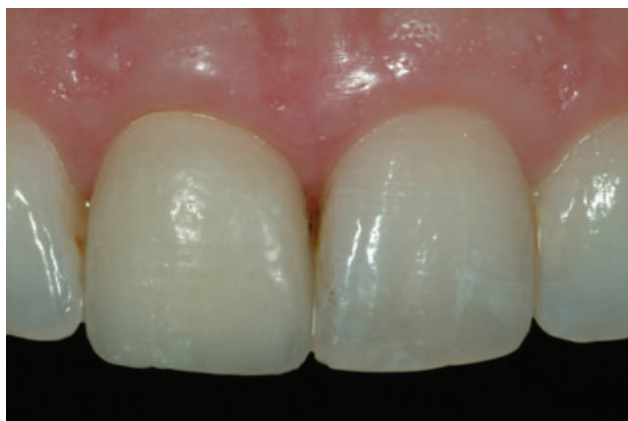

Figure 7. The provisional restoration generated of the diagnostic wax-up is placed to assess contours, surface texture and characterizations, soft-tissue integration, and shade.

characterization and the form of tooth to be matched, so it may serve as a reference for those variables. Digital images of the tooth prior to preparation as well as of the complete abutment are critical particularly if a decision is made to use an all-ceramic crown (Figures 5–7). Some materials are

more translucent than others and, as such, may facilitate a more esthetic result while restoring translucent abutments. The use of such translucent all-ceramic materials to try and restore a discolored abutment may result in a restoration with a lowered value, whereas other all-ceramic semiopaque

materials may be better used in such a clinical scenario to conceal the discoloration without compromising the value of the definitive result.<sup>16</sup>

In the quest of mimicking the adjacent natural tooth, internal and external characterizations, as well as hypocalcifications, and irregularities of the incisal edge must all be recorded while evaluating the digital images made. Moreover, a discussion with the patient regarding the level of reproduction of such features is essential to facilitate patient acceptance and success. Crack lines and hairline fractures, dentin lobes, mamelons, and the presence of incisal halo or secondary dentin, as well as variations in chroma at different areas of the reference tooth, must also be identified, recorded, and communicated to the dental ceramist.



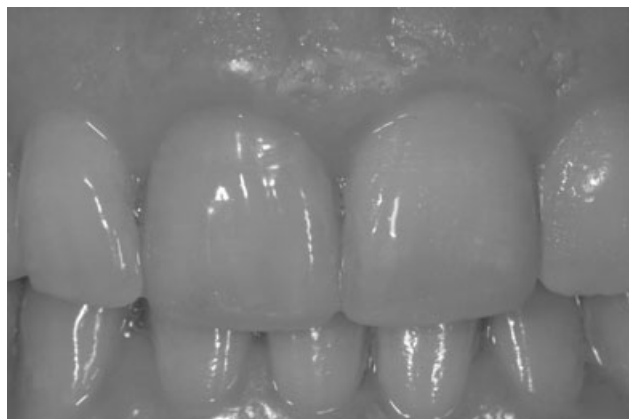

Figure 8. A frontal view of the completed restoration in the patient's mouth 2 years after cementation. Note the value of the restoration as related to the adjacent dentition.

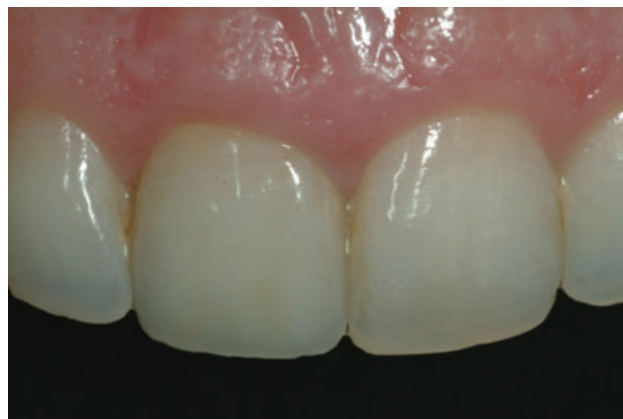

Figure 9. A frontal view of the completed restoration in the patient's mouth 2 years after cementation.

Evaluating cervical contours and the presence of a recession will affect the prospective integration of the restorations with the supporting tissues as well as with the adjacent tooth using the fabrication of a cements/enamel junction and mimicking the root or the use of surgical root coverage. Variations in shape and proportions, crowding, rotations, and diastemata must all be discussed with the patient and taken into account by the dental ceramist while fabricating the restoration. Many times, because of the complexity of the tooth to be matched, the best possible solution is to have the ceramist see the patient and to actively participate in the restoration matching process while also fabricating custom shade tabs as needed.

In summary, although discussed numerous times in the dental

literature, the process of matching a central maxillary incisor crown is still a challenge to all members of the restorative team. Patient education is critical for facilitating patient acceptance and understanding of what is required to achieve an ideal maxillary central incisor crown that perfectly mimics and naturally blends with the adjacent maxillary central incisor and the supporting tissues (Figures 8 and 9). Although technological advances have been made and have continued to be made in the field of computerized matching devices, the experience and the communication level between the ceramist and the restorative dentist via dental photography and elaborated shade prescriptions are still paramount for the success of such restorations.

#### ACKNOWLEDGMENTS

The author would like to express his gratitude to Mr. Andreas M.

Saltzer, CDT. Ceramic Design, Wisssemburg, France, for the fabrication of the all-ceramic crown presented in the article.

#### REFERENCES

1. Chiche GJ, Pinault A. Esthetics of anterior fixed prosthodontics. Carol Stream, IL: Quintessence; 1994. pp. 115–42.
2. Clark BE. An analysis of tooth color. J Am Dent Assoc 1931;18:2093–103.
3. Bergen SF. Color in aesthetics. N Y State Dent J 1985;51(8):470–71.
4. Jinoian V. The importance of proper light source in metal ceramics. In: Preston JD, editor. Proceedings of the 4th International Symposium of Ceramics. Carol Stream, IL: Quintessence Publishing; 1985. pp. 209–18.
5. Kurseja R. Translucency and esthetics. In: Preston JD, editor. Proceedings of the 4th International Symposium of Ceramics. Carol Stream, IL: Quintessence Publishing; 1985. pp. 267–72.
6. Vryonis P. Aesthetics in ceramics: perceiving the problem. In: Preston JD, editor. Proceedings of the 4th International Symposium of Ceramics. Carol Stream, IL: Quintessence Publishing; 1985. pp. 237–49.

7. Toreskog S, Svedmyr A. A color system the Swedish way. In: Preston JD, editor. *Proceedings of the 4th International Symposium of Ceramics*. Carol Stream, IL: Quintessence Publishing; 1985. pp. 219–28.
8. Sorensen JA, Torres TJ. Shade determination and communication: a team approach. In: Preston JD, editor. *Proceedings of the 4th International Symposium of Ceramics*. Carol Stream, IL: Quintessence Publishing; 1985. pp. 279–84.
9. Vryonis P. A custom shade guide system. In: Preston JD, editor. *Proceedings of the 4th International Symposium of Ceramics*. Carol Stream, IL: Quintessence Publishing; 1985. pp. 285–90.
10. Ahmad I. Three-dimensional shade analysis: perspectives of color—part I. *Pract Periodontics Aesthet Dent* 1999;11:789–96.
11. Ahmad I. Three-dimensional shade analysis: perspectives of color—part II. *Pract Periodontics Aesthet Dent* 2000;12(6):557–64.
12. Paravina RD. New shade guide for tooth whitening monitoring: visual assessment. *J Prosthet Dent* 2008;99:178–84.
13. Dancy WK, Yaman P, Dennison JB, et al. Color measurements as quality criteria for clinical shade matching of porcelain crowns. *J Esthet Restor Dent* 2003;15(2):114–22.
14. Raigrodski AJ, Chiche GJ, Aushima H, Spiekerman CH. Efficacy of computerized shade selection system in matching the shade of anterior metal ceramic crowns—a pilot study. *Quintessence Int* 2006;37:793–802.
15. Li Q, Wang YN. Comparison of shade matching by visual observation and an intraoral dental colorimeter. *J Oral Rehabil* 2007;34:848–54.
16. Raigrodski AJ. Materials selection for complete coverage all-ceramic restorations. In: Cohen M, editor. *Interdisciplinary treatment planning principles design implementation*. Hanover Park, IL: Quintessence Publishing; 2008. pp. 383–406.

---

*Reprint requests:* Ariel J. Raigrodski, DMD, MS, Department of Restorative Dentistry, School of Dentistry, University of Washington, D 780 Health Sciences Center, 1959 NE Pacific Street Box 357456, Seattle, WA 98195. Tel.: (206)543-5923; Fax: (206)543-7783; email: [araigrod@u.washington.edu](mailto:araigrod@u.washington.edu)

Copyright of Journal of Esthetic & Restorative Dentistry is the property of Blackwell Publishing Limited and its content may not be copied or emailed to multiple sites or posted to a listserv without the copyright holder's express written permission. However, users may print, download, or email articles for individual use.

Copyright of Journal of Esthetic & Restorative Dentistry is the property of Blackwell Publishing Limited and its content may not be copied or emailed to multiple sites or posted to a listserv without the copyright holder's express written permission. However, users may print, download, or email articles for individual use.