

# Esthetic Considerations in Interdental Papilla: Remediation and Regeneration

ANITA ANGELA SHARMA, DMD, DHSc\*

JAE HYUN PARK, DMD, MSD, MS, PhD†‡

## ABSTRACT

This article reviews the etiology and treatment of open gingival embrasures or black triangles. An open gingival embrasure or black triangle occurs as a result of a deficiency of papilla beneath the contact point. The treatment of open embrasures may require restorative, orthodontic and periodontal considerations depending on the underlying etiology. The authors reviewed a total of 42 articles including review of literature, radiographic, cross-sectional, and retrospective studies in Ovid search engine using the terms “open gingival embrasure,” “interdental papilla,” and “black triangle.” The studies provided information regarding etiology, diagnosis, and treatment of open embrasures. There are several risk factors leading to the development of open gingival embrasures. These factors include aging, periodontal disease, loss of height of the alveolar bone relative to the interproximal contact, length of embrasure area, root angulations, interproximal contact position, and triangular-shaped crowns. Treatment of open embrasures requires an interdisciplinary approach of orthodontic, periodontic, and restorative treatment.

## CLINICAL SIGNIFICANCE

Open gingival embrasures are complex esthetic and functional problems. An interdisciplinary team approach with the general dentist, orthodontist, and periodontist is critical. Management of open embrasures requires careful evaluation of the underlying etiology.

(*J Esthet Restor Dent* 22:18–30, 2010)

## INTRODUCTION

Preserving papilla in the gingival embrasure of the esthetic zone is a key consideration in restorative and orthodontic treatment. Today, with an aging adult population with a history of periodontal disease, open gingival embrasures

are a common occurrence. Black triangles occur in more than one-third of adults and therefore, should be discussed with the patient prior to initiating dental treatment.<sup>1,2</sup> Not only are black triangles unesthetic, but they also contribute to retention of food debris, and can adversely affect the

health of the periodontium.<sup>1</sup> Understanding the underlying etiology and customizing patient treatment is essential to reducing the frequency and severity of open gingival embrasures. Gingival embrasure is defined as the embrasure cervical to the interproximal contact.<sup>2</sup> It is open if the embrasure

\*Former postgraduate orthodontic resident, Postgraduate Orthodontic Program, Arizona School of Dentistry & Oral Health, A.T. Still University, Mesa, AZ, USA

†Associate professor and chair, Postgraduate Orthodontic Program, Arizona School of Dentistry & Oral Health, A.T. Still University, Mesa, AZ, USA

‡International scholar, the Graduate School of Dentistry, Kyung Hee University, Seoul, Korea  
Anita Angela Sharma is now in private practice in Calgary, Canada

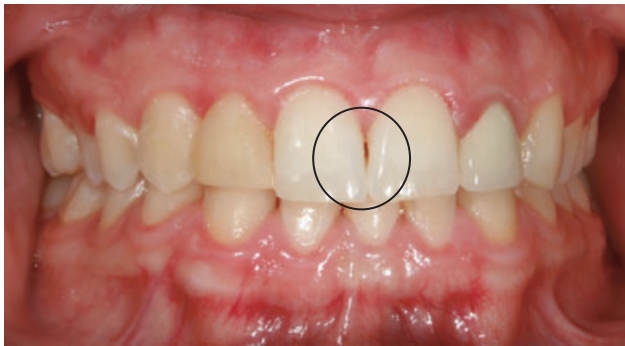

Figure 1. Open gingival embrasure between the maxillary central incisors is an esthetic problem.

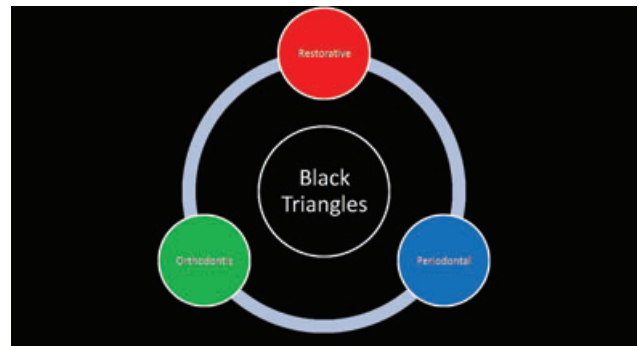


Figure 2. Interdisciplinary approach to addressing black triangles. Restorative, periodontal, and orthodontic treatment are all involved when treating black triangles.

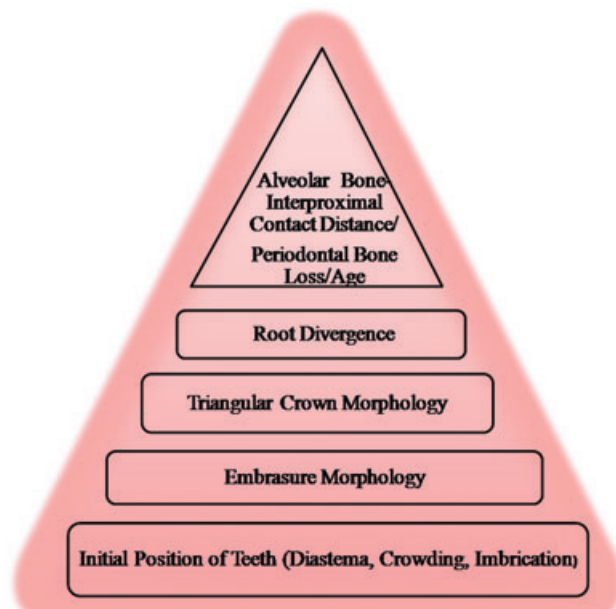


Figure 3. Hierarchy of risk factors for black triangle. Increasing levels of the pyramid pose a greater risk for black triangles.

space is not completely filled by the gingiva (Figure 1). Open gingival embrasures are more common in the adult population and occur in 38% of the adult orthodontic patients.<sup>1</sup> Open gingival embrasures occur in 15% of the general

adolescent population and 41.9% in adolescent patients who are treated for maxillary incisor crowding.<sup>3</sup> Open gingival embrasures are associated with periodontal disease, periodontal surgery, and orthognathic surgery, which

could account for the higher prevalence in adults.<sup>2</sup>

Esthetically, open gingival embrasures can affect a patient's smile. In one study,<sup>4</sup> orthodontists rated a 2-mm open gingival embrasure as noticeably less attractive than an ideal smile with normal gingival embrasure. Open gingival embrasures slightly greater than 3 mm were considered less attractive by both general dentists as well as the general population. It is important to note that open embrasures are visible and do not go unnoticed. Corrective action should be taken to minimize or prevent open embrasures. Restorative, periodontal, and orthodontic treatment planning can play a significant role in the closure of gingival embrasures (Figure 2).

The etiology of open gingival embrasures is multifactorial. Potential causes include dimensional

changes of papilla during orthodontic alignment, loss of periodontal attachment resulting in recession, loss of height of the alveolar bone relative to interproximal contact, length of embrasure area, root angulations, interproximal contact position, and triangular-shaped crowns (Figure 3).<sup>5</sup> The interproximal contact between the maxillary central incisors is composed of the actual tooth contact and soft tissue papilla. Open embrasures are found to be age related. Studies<sup>2,6</sup> have shown that patients over 20 years of age are more susceptible than people below 20 years of age. Open embrasures were found in 67% of the population over 20 years of age compared with 18% in the population under 20 years of age.<sup>2</sup> This is because of the thinning of oral epithelium, decrease in keratinization, and reduction in papilla height as a result of aging. Age is a significant risk factor leading to wide and long embrasure spaces in adults. Embrasure morphology also plays a role in the occurrence of central papilla. Black triangles occur increasingly in short narrow, long narrow, long wide, and short wide embrasure morphologies.<sup>6</sup>

#### ORTHODONTIC CONSIDERATIONS

Divergent roots have a strong association with open gingival embrasures. One study<sup>1</sup> showed that mean root angulations in normal

gingival embrasures converge at  $3.65^\circ$  and an increase in root divergence by  $1^\circ$  raises the probability of an open gingival embrasure from 14 to 21%. With orthodontic treatment, maxillary incisor roots could be paralleled to reduce or eliminate open gingival embrasures (Figure 4). Diverging roots can be caused by improper bracket placement. In adults with worn incisal edges, the bracket slot must be perpendicular to the long axis of the tooth and not parallel to the incisal edges. It is important to review the periapical radiograph prior to bracket placement, especially in patients with attrition.<sup>7</sup> Bonding based on incisal position will result in greater root divergence, contributing to an open gingival embrasure. Bonding the bracket so that the slot is perpendicular to the long axis of the tooth will allow roots to converge, and may require the worn distoincisor edges to be restored. As roots become more parallel, the contact point will lengthen and move apically toward

the papilla.<sup>7</sup> The crowns of each incisor will move closer, causing the stretched transeptal fibers to relax and fill in the gingival embrasure.<sup>8</sup> This will reduce the probability and severity of open embrasures.

Patients with triangular crown morphology are more susceptible to open embrasure spaces (Figure 5A). The crowns of the central incisors can be much wider incisally than cervically, resulting in an abnormal contact position. Interproximal contact between central incisors is located at the incisal 1 mm of the crown. Interproximal reduction (IPR) of enamel on triangular crowns will convert a point contact to a broader contact area that will reduce open gingival embrasures (Figure 5B,C). One method for correction of the black triangle is the reduction of interproximal enamel with a reducing diamond strip to recontour the mesial surfaces of the central incisors (Figure 6).

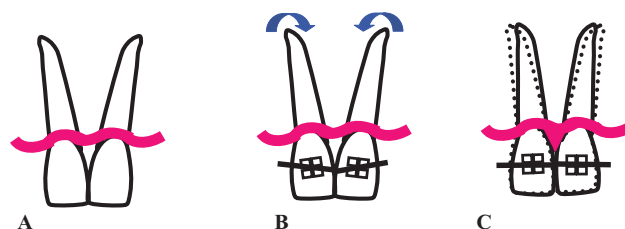


Figure 4. Paralleling divergent roots will decrease a black triangle. A, Divergent roots with open black triangle. B, Bracket positioning to follow long axis of the tooth and correct black triangle. C, Converged roots with closed black triangle after orthodontic treatment.

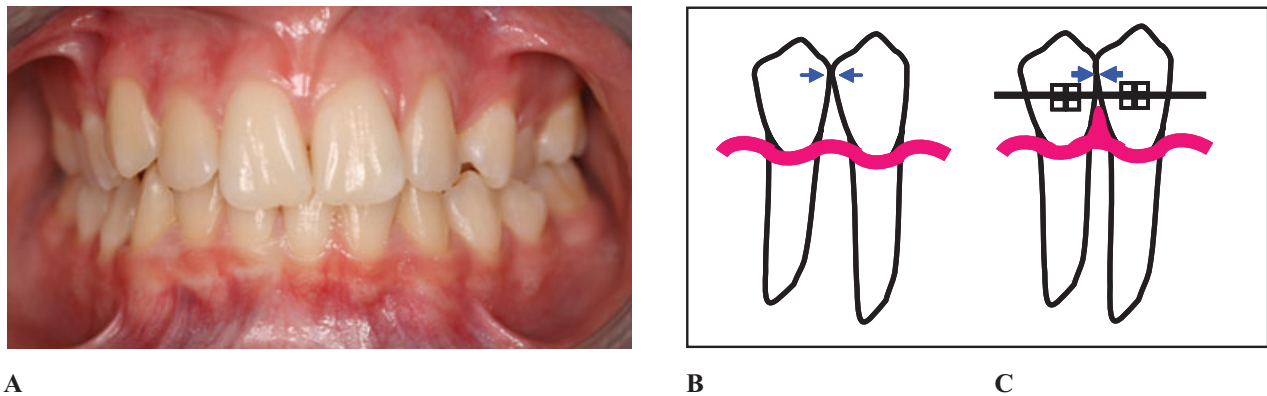


Figure 5. Triangular crowns can be reduced interproximally and the space closed to reduce open embrasures. A, Patient with triangular crown morphology. Reducing black triangle by changing point contact (B) to a broader surface (C) by interproximal reduction. Orthodontic space closure and soft tissue filling the gingival embrasure.

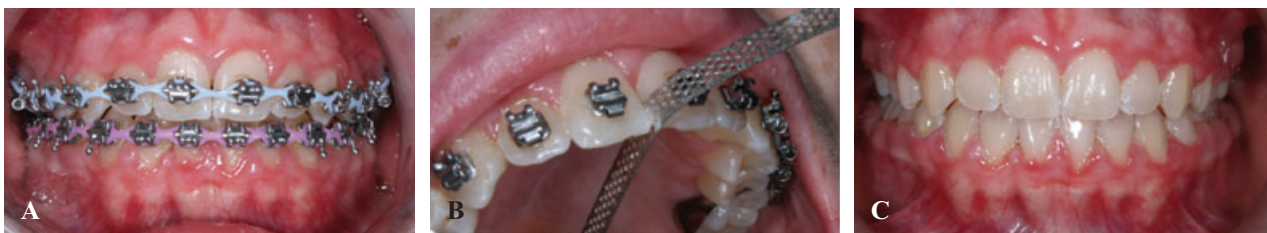

Figure 6. Reduction of black triangle with interproximal reduction. A, Point contact with black triangle present between central incisors. B, Interproximal reduction with medium diamond strip. C, Posttreatment. Complete fill of soft tissue in gingival embrasure by closing space and creating a broader contact that is closer to the alveolar crest.

Typically, 0.5 to 0.75 mm of the enamel is removed with IPR.<sup>9</sup> IPR and space closure will lengthen the contact point and move the contact gingivally.

Gingival embrasures are affected by the direction of tooth movement and by the labiolingual thickness of the supporting bone and soft tissue, following orthodontic treatment. During lingual tooth movement, the gingival tissue will thicken and move occlusally on the facial aspect of the tooth. In

contrast, moving a tooth labially will cause the tissue to thin and move apically.<sup>10</sup> Therefore, patients with a Class II Division 2 malocclusion would be more prone to open gingival embrasure spaces than Class II Division 1 with flared incisors. Labial movement of palatally placed and imbricated teeth may also be predisposed to gingival recession following orthodontic treatment.

Imbricated incisors are arranged in an overlapping manner so that one

incisor may be placed palatally or labially, relative to the other incisor (Figure 7). Interestingly, maxillary incisor imbrication and rotation have a controversial association with open gingival embrasure spaces.<sup>1,3,10</sup> Orthodontists are recommended to inform patients with imbricated maxillary incisors that they may be predisposed to an open gingival embrasure following orthodontic treatment.

Severity of crowding plays only a minimal role in open embrasures.



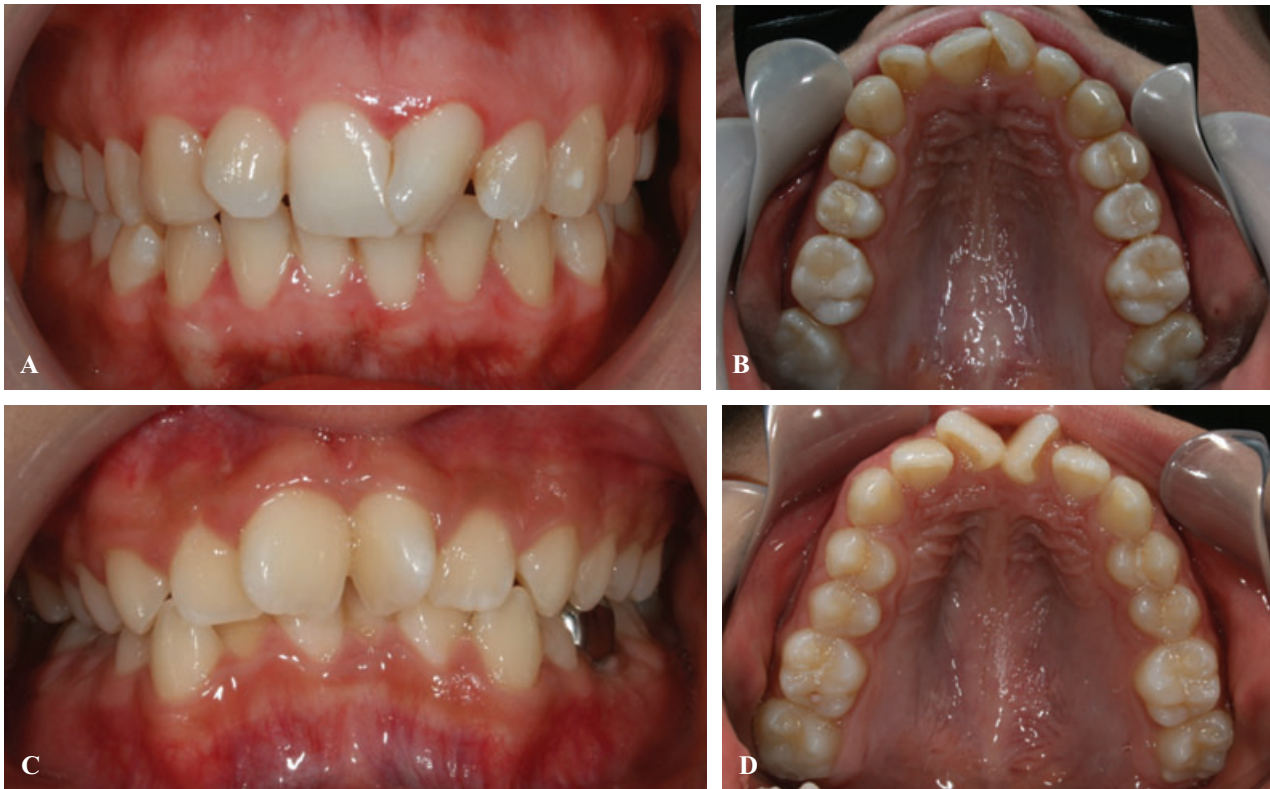

Figure 7. Imbricated incisors have been associated with black triangles. A, Mesially rotated-out overlapping maxillary incisors initially. B, Orthodontic movement will require lingual movement of the mesial of the maxillary central incisors and, therefore, has a lower probability of black triangles. C, Mesial rotated-in overlapping maxillary incisors initially. D, Orthodontic movement will require labial movement of the mesial of the central incisors that has been linked to black triangles.

Ko-Kimura et al.<sup>2</sup> found that open embrasures occurred in a similar percentage of patients with incisor crowding of less than 4 mm and those with 4 to 8 mm of incisor crowding. When crowding was more than 8 mm, the occurrence of open gingival embrasures increased by 7%. However, these results were considered insignificant. In addition, duration of orthodontic treatment had no effect on open gingival embrasures.

The volume of soft tissue in the gingival embrasure will depend on existing tissue, bone levels, and the severity of the diastema. Closing a diastema orthodontically will compress the soft tissue to come together and fill in the embrasure area (Figure 8). Minor diastema closure during the retention phase can be simplified with a removable orthodontic appliance (Figure 9). However, large diastema closure may result in an open gingival embrasure requiring

additional orthodontic and/or restorative treatment.

#### PERIODONTAL CONSIDERATIONS

Periodontal disease has been associated with loss of the interdental papilla because of alveolar bone loss. Although the occurrence of plaque and gingivitis is probably higher in people with crowding, host susceptibility and other factors may also play a role in open embrasures, especially in patients who have been previously

### Esthetic Considerations in Interdental Papilla: Remediation and Regeneration

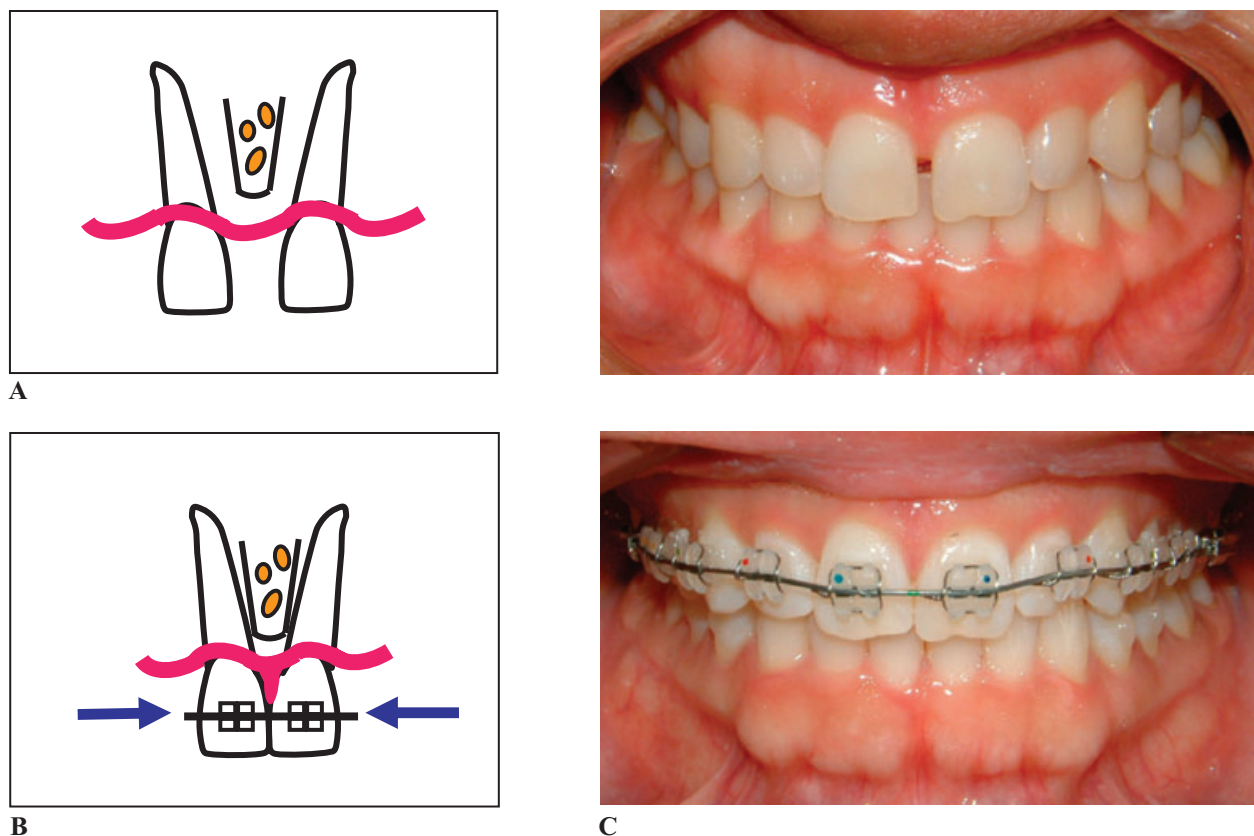


Figure 8. Diastema closure and regeneration of papilla. A, Pretreatment with diastema. B, Orthodontic closure of space. C, Formation of papilla to fill gingival embrasure.

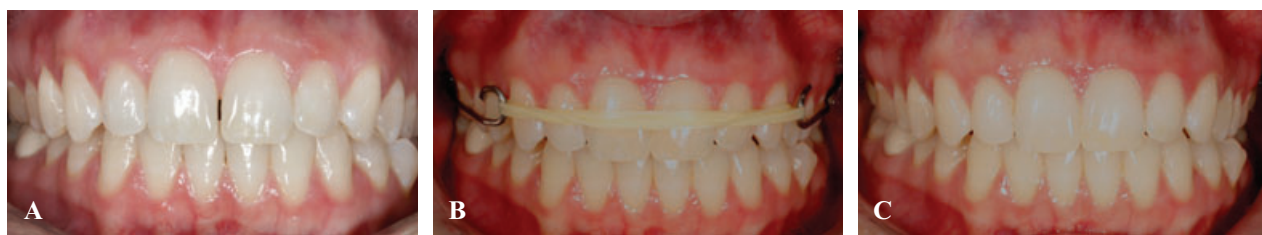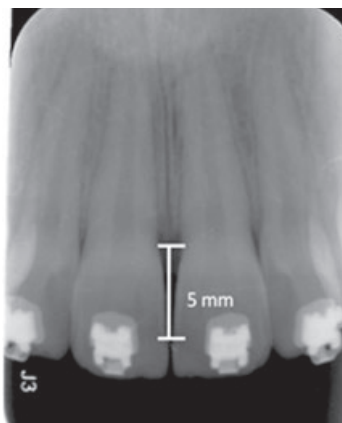


Figure 9. Limited orthodontic treatment to close a diastema. A, Pretreatment with diastema. B, Modified maxillary Hawley retainer with extended arms. Elastics (3/8", 3.5 oz; 3M Unitek, Monrovia, CA, USA) are worn across the teeth from right arm to left arm of the retainer. C, Posttreatment after 4 weeks of treatment.

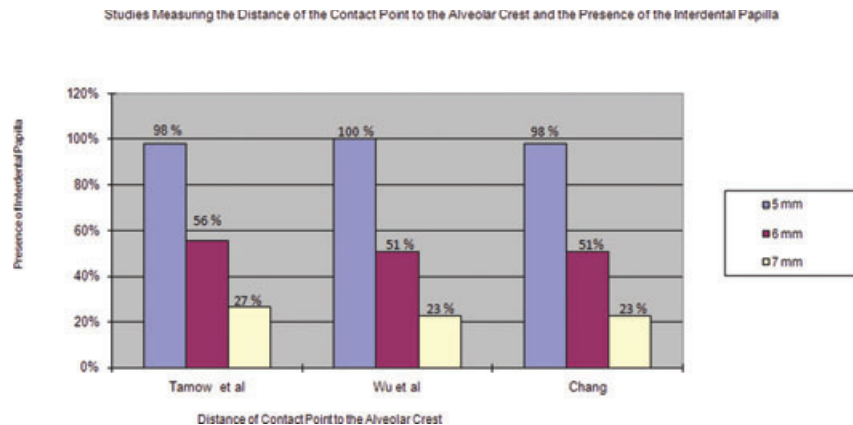
treated for periodontal disease. Increased periodontal maintenance and oral hygiene is very important to prevent bone loss and recession.

A distance of 5 mm from the alveolar crest to contact point is considered periodontally healthy.<sup>11</sup> However, pocket depths greater

than 3 mm will lead to increased plaque retention, inflammation, and recession.<sup>11</sup> In periodontal disease, it is the loss of bone that



A



B

Figure 10. A, The distance of alveolar crest to contact point (white) is critical in determining the presence of an open embrasure. A distance greater than 5 mm is associated with black triangle. B, Summary of several studies measuring the distance from alveolar crest to contact point. Increasing distance will increase the frequency of an open embrasure.

increases the distance between contact point and alveolar crest, resulting in an open gingival embrasure.

The distance from the base of the contact point to the alveolar crest in central incisors is a strong indicator of open embrasures (Figure 10A). A classic study by Tarnow et al.<sup>12</sup> found an association between black triangles and the distance of the contact point to the alveolar crest of the bone. Another study observed that a distance of 5, 6, and 7 mm resulted in an open embrasure in 2, 44, and 73% of the cases, respectively.<sup>7</sup> These observations indicate that, if the distance from the alveolar crest to contact point was 5 mm or less, papilla was present in almost 100% of the cases. However, when the distance was more than 7 mm,

papilla was missing in most of the cases. At 6 mm, papilla was present in half of the cases.<sup>7</sup> Other studies<sup>7,13</sup> have shown similar results (Figure 10B). Adult patients with open gingival embrasures have increased alveolar bone–interproximal contact distance of 5.5 mm or more.<sup>1</sup> A 1-mm increase in distance between the alveolar bone and interproximal contact increases the probability of an open gingival embrasure by 78 to 97%. As a rule, a distance between 5 and 6 mm from contact point to alveolar crest is most critical and determines the presence or absence of an open gingival embrasure.<sup>7</sup>

Chronic periodontitis and tooth-brush trauma may also cause open embrasures. If the loss of papillary height is because of trauma during tooth brushing, interproximal

cleaning should be discontinued until the tissue can recover.<sup>14</sup> Currently, there are no predictable surgical procedures to augment papilla.<sup>15–21</sup> Surgical papillary reconstruction may result in contraction and necrosis of the grafted tissue. The unpredictability is because of tissue fragility and low blood supply to interdental papilla.<sup>7</sup> However, case studies<sup>22,23</sup> have demonstrated some success with subepithelial connective tissue grafts and orthodontic therapy. Flap pedicles have shown better results than free gingival grafts.<sup>7</sup> For surgical success, it is important that there is the presence of a thick biotype gingiva and there is no loss of insertion at the periodontal attachment.<sup>14</sup> Patients with a thin biotype of gingiva are more susceptible to recession and therefore, to open gingival embrasures.

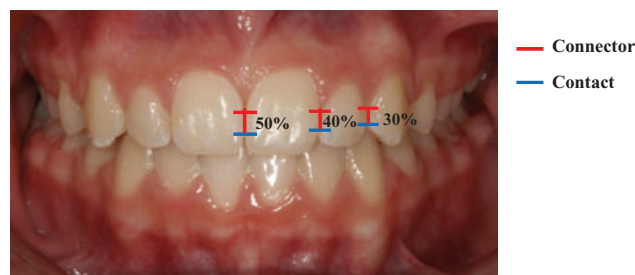
Patients with thin periodontium are shown to have long narrow upper central incisors, whereas patients with a thick biotype have short and wide central incisors.<sup>24</sup> In addition, the thick periodontal biotype has a thick osseous structure with flat morphology and a thick gingival tissue with short wide papilla. In contrast, the thin biotype is characterized by a scalloped appearance with long interdental papilla.<sup>25</sup> Typically, the thick biotype has a better vascular supply and biological tissue memory that helps the tissue to rebound, whereas the thin biotype usually results in permanent recession.<sup>20</sup> Interdental gingival recession may occur, causing reduced height and thickness of the free gingiva, with a resulting long clinical crown. This recession is precipitated by plaque and toothbrush trauma. Nontraumatic plaque control is recommended for patients susceptible to black triangles.<sup>10</sup>

#### RESTORATIVE CONSIDERATIONS

There are several considerations in planning restorative treatment for large open embrasures. Mesiocervical restorations or veneers will reduce the appearance of open embrasures by altering the crown form. The composite resin can be inserted into the gingival sulcus to guide the shape of the interdental papilla, much like a provisional crown for an implant. Care must be taken not to impinge on the

interdental tissue or harbor plaque. Typically, maxillary central incisors have an 80% width : height ratio, which is considered ideal. Restorative treatment alone to reduce a large space may result in divergence of this ratio, resulting in an unsatisfactory treatment outcome. A combination of orthodontic and restorative treatment may be required.

Restorative treatment requires maintaining an appropriate ratio of crown height between connector and central incisor. The connector is where teeth appear to contact, the contact point is where the teeth actually connect. The connector of maxillary anterior teeth has a proportional relationship to the height of the central incisors (Figure 11). The ratio of connector to tooth height for the central, lateral, and canine is 50, 40, and 30%, respectively.<sup>26</sup> Teeth with greater crown

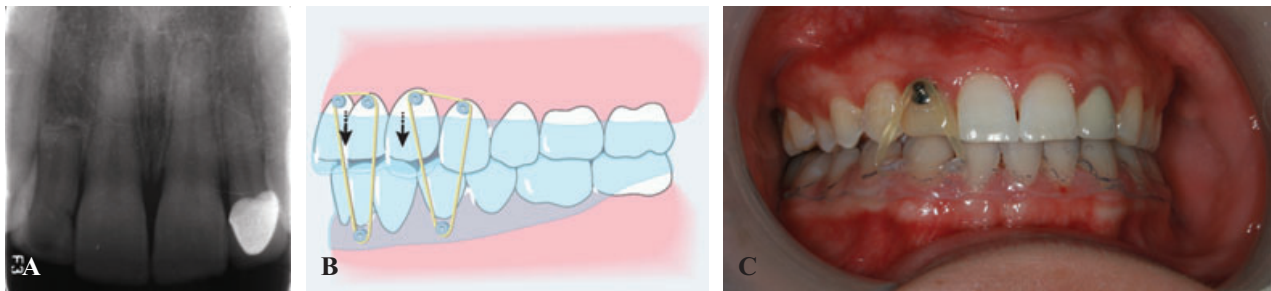


*Figure 11. Connectors and interproximal contact. Connectors (red) are where teeth appear to meet. Contact (blue) between teeth is where they actually meet. Appropriate ratio for a connector between maxillary central incisors is 50% of central incisor height, ratio between central–lateral connector is 40% of central incisor height, and ratio between lateral–canine connector is 30% of central incisor height.*

height will have longer connectors. Also, embrasures are smaller between the central incisors and increases progressively toward the posterior. To hide severe tissue defects, application of pink-colored porcelain or a removable appliance is recommended.<sup>12</sup> A comprehensive understanding of anterior esthetics is critical in determining the appropriate treatment.<sup>27–31</sup>

Single tooth implants have a significant chance of papilla loss because of increasing distance from the contact point to the alveolar crest.<sup>32–37</sup> To preserve implant papilla, it is important to keep the distance from the contact point to bone level at 5 mm or less. The distance of adjacent natural tooth to the alveolar crests is most critical, whereas the height of the implant contact to the bone is less important.<sup>32</sup> Choquet et al.<sup>33</sup>





*Figure 12. Extrusion of the maxillary right lateral incisor to maximize bone and soft tissue prior to implant placement. A, Mobility and devitalized maxillary right lateral incisor as a result of trauma was the treatment planned for extraction and implant. B, A thermoformable plier can create buttons on the buccal of a clear aligner tray to provide attachments for elastics. C, A button is bonded to the maxillary right lateral incisor for extrusion. The patient is instructed to wear an elastic from the mandibular clear aligner to the maxillary lateral incisor. The patient returns every 2 weeks for incisal reduction of the lateral to allow further extrusion.*

showed the presence of papilla at 100 and 50% level in healthy teeth when the distance from the alveolar crest to the contact point of single implant in the maxillary anterior was at 5 and 6 mm, respectively.<sup>28</sup> Above 7 mm, a significant increase in black triangles was observed.<sup>24</sup> Some clinicians believe that tissue healing around an immediate provisional abutment helps in proper tissue contouring. Ryser et al.<sup>32</sup> has demonstrated that there is no difference in papilla loss if an implant has immediate provisionalization. Extrusion of a tooth prior to implant placement will allow the bone to extrude with the tooth, resulting in an increase of soft tissue. Tooth extrusion can be performed with intermaxillary elastics and a clear removable appliance (Figure 12).<sup>36</sup> However, previous tissue loss prior to implant placement will usually result in an open embrasure following final restoration.

Jemt<sup>38</sup> found that the volume of soft tissue around anterior single tooth implants can be expected to undergo soft tissue shrinkage on the buccal; however, there is an increase in soft tissue volume in 80% of cases after 1.5 years. Similarly, Grunder et al.<sup>39</sup> demonstrated a 0.375-mm increase in soft tissue volume after 1 year, although 0.6 mm of soft tissue shrinkage occurred on the buccal side of the implant crown. In order to compensate for the buccal soft tissue shrinkage, the implant clinical crown length should be 0.5 to 0.75 mm shorter at the time of crown insertion.

Black triangles are even more pronounced when two adjacent implants are placed. This soft tissue deficiency of 1 to 2 mm arises from the biological width around an implant being apical to the platform for the abutment.<sup>40</sup> As a result, the biological width of

implants is found subcrestally instead of supracrestally, as is the case in natural teeth.<sup>29</sup> Ideally, maxillary anterior implants should be 4 mm apical to the alveolar crestal bone. Furthermore, to prevent bone loss and subsequent papilla loss, it is important that the distance between two adjacent implants exceeds 3 mm.<sup>32</sup> This allows the interproximal bone to be maintained above the implant shoulder. In the anterior region, it is difficult to obtain this ideal mesio-distal distance. One method for compensating the loss of interproximal bone is to augment the buccal bone in the papillary area.<sup>41,42</sup> However, a distance greater than 3 mm will not ensure a complete papilla. There are several considerations that may not allow papilla regeneration but may help prevent additional interproximal bone loss. Placing two adjacent implants in an esthetic zone should be avoided to prevent bone

loss and the inevitable appearance of a black triangle. Therefore, two healthy adjacent teeth, or one implant and a healthy tooth, will have a more favorable esthetic treatment outcome. Recommended treatment for patients missing two adjacent teeth in the esthetic zone includes placing an implant with a cantilever pontic and performing soft tissue graft, interproximal bone augmentation, or a three unit bridge involving the implant.<sup>34</sup>

#### CONCLUSION

The etiology of open gingival embrasure is multifactorial. Increased distance between alveolar bone-interproximal contact and divergent root angulations appears to be the most significant factor in open gingival embrasure. To determine the ideal treatment for the patient, the dentist must first evaluate whether it is a soft tissue or a hard tissue problem. An interdisciplinary team approach including general dentist, orthodontist, periodontist, and prosthodontist is critical for restoration of open gingival embrasures.

#### DISCLOSURE

The authors have no financial interest in any of the companies whose products are included in this article.

#### REFERENCES

1. Kurth J, Kokich V. Open gingival embrasures after orthodontic treatment in adults: prevalence and etiology. *Am J Orthod Dentofacial Orthop* 2001;120:116–23.
2. Ko-Kimura N, Kimura-Hayashi M, Yamaguchi M, et al. Some factors associated with open embrasures following orthodontic treatment. *Aust Orthod J* 2003;19:19–24.
3. Burke S, Burch J, Tetz J. Incidence and size of pretreatment overlap and post-treatment gingival embrasure space between maxillary central incisors. *Am J Orthod Dentofacial Orthop* 1994;105:506–11.
4. Kokich V, Kiyak A, Shapiro P. Comparing the perception of dentists and lay people to altered dental esthetics. *J Esthet Dent* 2005;17:311–24.
5. Cardaropoli D, Re S. Interdental papilla augmentation procedure following orthodontic treatment in a periodontal patient. *J Periodont* 2005;76:655–61.
6. Chang L. The association between embrasure morphology and central papilla recession: a noninvasive assessment method. *Chang Gung Med J* 2007;30:445–52.
7. Wu Y, Tu Y, Huang S, Chan C. The influence of the distance from the contact point to the crest of bone on the presence of the interproximal dental papilla. *Chang Gung Med J* 2003;26:822–8.
8. Kokich V. Excellence in finishing : modifications for the perio-restorative patient. *Semin Orthod* 2003;9:184–203.
9. Kokich V. Esthetics: the orthodontic-periodontic restorative connection. *Semin Orthod* 1996;2:21–30.
10. Kandasamy S, Goonewardene M, Tennant M. Changes in interdental papilla heights following alignment of anterior teeth. *Aust Orthod J* 2007;23:16–23.
11. Zetu L, Wang Z. Management of interdental/inter-implant papilla. *J Clin Periodontol* 2005;32:831–9.
12. Tarnow D, Wagner AW, Fletcher P. The effect of the distance from the contact point to the crest of bone on the presence or absence of the interproximal dental papilla. *J Periodontol* 1992;63:995–6.
13. Chang L. Assessment of parameters affecting the presence of the central papilla using a non-invasive radiographic method. *J Periodontol* 2008;79:603–9.
14. Tanaka OM, Furquim B, Pascotto C, et al. The dilemma of the open gingival embrasure between maxillary central incisors. *J Contemp Dent Pract* 2008;9:1–9.
15. Ravon N, Handelsman M, Levine D. Multidisciplinary care: periodontal aspects to treatment planning in the anterior esthetic zone. *J Calif Dent Assoc* 2008;36:575–84.
16. Lee D, Kim C, Park K, et al. Non-invasive method to measure the length of soft tissue from the top of the papilla to the crestal bone. *J Periodontol* 2005;76:1311–4.
17. Azzi R, Takei H. Root coverage and papilla reconstruction using autogenous osseous and connective tissue grafts. *Int J Periodontics Restorative Dent* 2001;21:141–7.
18. Oringer R, Iacono V. Current periodontal plastic procedures around teeth and dental implants. *N Y State Dent J* 1999;6:26–31.
19. Blatz M, Hurzeler M, Strub J. Reconstruction of the lost interproximal papilla-presentation of surgical and non-surgical approaches. *Int J Periodontics Restorative Dent* 1999;19:395–406.
20. Van der Velden U. Regeneration of the interdental soft tissue following denudation procedure. *J Clin Periodontol* 1982;9:455–9.
21. Roy B. Improving prosthetic results through periodontal procedures. *J Indiana Dent Assoc* 1998;77:17–20, 33–5.
22. Checchi L, Montevecchi M, Checchi V, Bonetti A. A modified papilla preservation technique, 22 years later. *World J Orthod* 2009;40:303–11.
23. Nemcovsky C. Interproximal papilla augmentation procedure: a novel surgical approach and clinical evaluation of 10 consecutive procedures. *Int J Periodontics Restorative Dent* 2001;21:553–9.
24. Olsson M, Lindhe J, Marinello CP. On the relationship between crown form and

- clinical features of the gingival in adolescents. *J Clin Periodontol* 1993;20:570–7.
25. Chang L. The association between embrasure morphology and central papilla recession. *J Clin Periodontol* 2007;34:432–6.
  26. Raj V, Heymann H. The apparent contact dimension and covariates among orthodontically treated and nontreated subjects. *J Esthet Restor Dent* 2009; 21:96–112.
  27. Kokich V. Esthetics and anterior tooth position: an orthodontic perspective part III: mediolateral relationships. *J Esthet Dent* 1995;5:200–7.
  28. Sarver DM. Principles of cosmetic dentistry in orthodontics: part 1. Shape and proportionality of anterior teeth. *Am J Orthod Dentofacial Orthop* 2004;126: 749–53.
  29. Kokich V. Esthetics and vertical tooth position: orthodontic possibilities. *Compendium* 1997;18:1225–31.
  30. Cardaropoli D, Re S, Corrente G. The papilla presence index (PPI): a new system to assess interproximal papillary levels. *Int J Periodontics Restorative Dent* 2004;24:489–92.
  31. Martegani P, Silvestri M, Mascarello F, et al. Morphometric study of the interproximal unit in the esthetic region to correlate anatomic variables affecting the aspect of soft tissue embrasure space. *J Periodontol* 2007;78:2260–5.
  32. Ryser M, Block M, Mercante D. Correlation of papilla to crestal bone levels around single tooth implants in immediate or delayed crown protocols. *J Oral Maxillofac Surg* 2005;63:1184–95.
  33. Choquet V, Hermans M, Andriaenssens P, et al. Clinical and radiographic evaluation of the papilla level adjacent to single-tooth dental implants. A retrospective study in the maxillary anterior region. *J Periodontol* 2001;72:1364–71.
  34. Tarnow D, Elian N, Fletcher P, et al. Vertical distance from the crest of bone to the height of the interproximal papilla between adjacent implants. *J Periodontol* 2003;74:1785–8.
  35. Price R, Price D. Esthetic restoration of a single-tooth dental implant using a sub-epithelial connective tissue graft: a case report with 3-year follow-up. *Int J Periodontics Restorative Dent* 1999;19:93–101.
  36. Park JH, Kim TW. Open-bite treatment utilizing clear removable appliances with intermaxillary and intramaxillary elastics. *World J Orthod* 2009;10:130–4.
  37. Ikeda T, Yamaguchi M, Meguro D, Kasai K. Prediction and causes of open gingival embrasure spaces between the mandibular central incisors following orthodontic treatment. *Aust Orthod J* 2004;20:87–92.
  38. Jemt T. Regeneration of gingival papillae after single-implant treatment. *Int J Periodontics Restorative Dent* 1997;17:327–33.
  39. Grunder U, Gracis S, Capelli M. Influence of the 3-D bone-to-implant relationship on esthetics. *Int J Periodontics Restorative Dent* 2005;25:112–9.
  40. Tarnow D, Cho S, Wallace S. The effect of inter-implant distance on the height of inter-implant bone crest. *J Periodontol* 2000;71:546–9.
  41. Grunder U, Spielman H, Gaberthuel T. Implant-supported single tooth replacement in the aesthetic region: a complex challenge. *Pract Periodont Aesthet Dent* 1996;8:835–42.
  42. Grunder U. Stability of the mucosal topography around single-tooth implants and adjacent teeth: 1-year results. *Int J Periodontics Restorative Dent* 2000; 20:11–7.

---

*Reprint requests: Jae Hyun Park, DMD, MSD, MS, PhD, Postgraduate Orthodontic Program, Arizona School of Dentistry & Oral Health, A. T. Still University, 5855 East Still Circle, Mesa, AZ, USA 85206; email: jpark@atsu.edu*

*This article is accompanied by commentary, "Esthetic Considerations in Interdental Papilla: Remediation and Regeneration," William Becker, DDS, MSD, DOI 10.1111/j.1708-8240.2009.00308.x*

Copyright of Journal of Esthetic & Restorative Dentistry is the property of Blackwell Publishing Limited and its content may not be copied or emailed to multiple sites or posted to a listserv without the copyright holder's express written permission. However, users may print, download, or email articles for individual use.