

Enameloplasty and Esthetic Finishing in Orthodontics—Identification and Treatment of Microesthetic Features in Orthodontics Part I

DAVID M. SARVER, DMD, MS*†

ABSTRACT

Interdisciplinary treatment also has expanded to include not only soft tissue assessment of the periodontal components of the dentition and smile, but of the face as well. The next level of esthetic enhancement certainly will include facial proportionality as a key component in our patient evaluation. This paper expands the diagnostic vision of the dentist to include facial proportions and relationships of hard and soft tissues to improve diagnosis and treatment of dental and facial esthetics.

CLINICAL SIGNIFICANCE

Diagnosis and treatment in orthodontics has shifted to assess tooth shape and form in the analysis of an orthodontic problem. There are principles of esthetic dentistry that orthodontists can use to enhance their finishes in order to provide a superior esthetic outcome. Because orthodontists have benefited from much technological advancement in diagnosis, wires, and brackets, often resulting in more efficient treatment times, there is more time for identifying microesthetic characteristics and enhancing the final outcomes to a degree previously not attainable.

(J Esthet Restor Dent 23:296–302, 2011)

INTRODUCTION

Patients today seeking esthetic treatment are looking for enhancement of their appearance for improved quality of life. We advocate the use of the term “appearance” in conjunction with the term “esthetics” because it involves a broader assessment of the patient other than the smile. So, in orthodontic diagnosis and treatment planning we have created an approach in evaluation divided into three divisions (Figure 1):

- 1 Macroesthetics—this include the profile, vertical facial dimensions—in other words—the face
- 2 Miniesthetics—the smile attributes—buccal corridors, smile arc, incisor display, etc.
- 3 Microesthetics—the teeth and their many attributes such as contacts and connectors, embrasures, gingival shape and contour

In cosmetic dentistry, orthodontics, and orthognathic surgery, if the esthetic outcome is not satisfactory to the patient then they consider the case a failure. Orthodontists do not perform cosmetic dental procedures such as composite bonding, veneers, and crowns. However, we all recognize that in some instances when orthodontic treatment is finished, not all the smiles “look right.” Not all patients want or can afford veneers, and certainly not all of them need them. But there are principals of cosmetic dentistry that orthodontists can use to enhance their finishes in order

*Department of Orthodontics, University of North Carolina, Chapel Hill, NC, USA

†Department of Orthodontics, University of Alabama, Birmingham, AL, USA

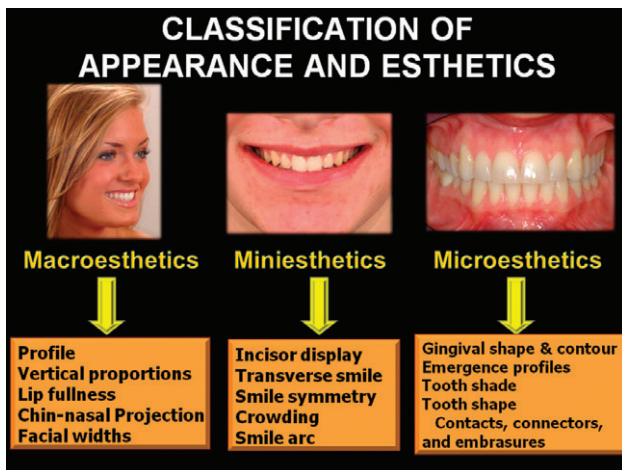


FIGURE 1. Embracing a more global and comprehensive approach to appearance and esthetics, we have an expanded definition of esthetics into macroesthetics (the face), miniesthetics (the smile), and microesthetics (the teeth).

to provide a superior esthetic outcome.¹⁻³

Orthodontists have benefited from much technological advancement in diagnosis, wires, and brackets, often resulting in more efficient treatment times. This gives us time for identifying microesthetic characteristics and enhancing our outcomes to a degree we have never been able to do before.

The purpose of this paper is to briefly review some of the principals of ideal tooth shape and morphology and to demonstrate how to utilize tooth reshaping through enameloplasty to treat and finish orthodontic cases to much more esthetic conclusions.

Esthetic dentistry has for many years defined tooth shape and morphology in terms of ideal ratios of tooth dimensions, and definitions of shape and contour—what we refer to as microesthetics. The purpose of this paper is not to review these definitions and parameters, since these are well researched and established in esthetic dentistry.^{1,4-19} Figure 2 is a general summary illustration of these features to serve as a mental image at the beginning of this paper to serve as a reference of our definition used throughout this article.

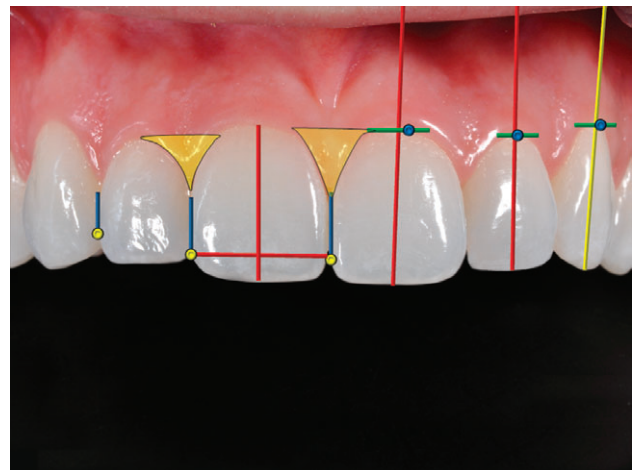

FIGURE 2. Generally accepted values for ideal tooth dimension of anterior teeth: 8:10 height/width ratio for the central incisors (short red lines), contact placement (yellow dot), connector length (blue line), papilla height (yellow highlight), axial inclination of the crown and root (long axis; long red/yellow lines), and gingiva shape and contour with zenith placement (blue dot).




FIGURE 3. This patient presented with a chief complaint of protruding teeth. She had been treated as a child to a good occlusion and acceptable smile esthetics.

CASE I

The patient in Figure 3 presented with a chief complaint of protruding teeth. She had been treated as a child and her occlusion was in an acceptable Class I relationship. Her smile displayed many pleasing attributes such as her smile width and smile arc, but the close-up smile (Figure 4) revealed some esthetic deficiencies:

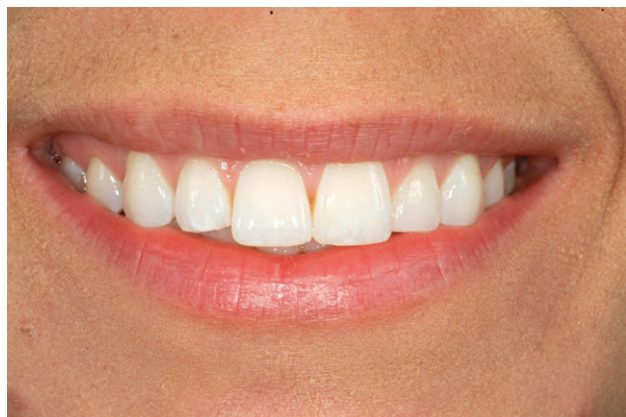

FIGURE 4. The close-up smile revealed (1) disparate incisal edges and gingival margins; (2) the right central incisor had a 1:1 height/width ratio, the left more appropriate at 8:10; (3) an excessive gingival embrasure.

- 1 The vertical relationships of the anterior teeth (incisal edges and gingival margins) were disparate
- 2 The height/width ratios of the central incisors were not the same
- 3 The central incisors were disproportionately larger than the lateral incisors
- 4 An excessive gingival embrasure between the maxillary centrals resulting in an unesthetic black triangle

The intraoral image (Figure 5) demonstrates well-aligned teeth and good overbite/overjet. To define the issues that need to be addressed, the anterior teeth were analyzed using a microesthetic assessment. Figure 6 illustrates the anterior teeth in detail with pertinent analysis:

- 1 Excessive gingival embrasure between the maxillary central incisors
- 2 Short connector length between central incisors (28%)
- 3 Differential incisal edge placement between the four incisors
- 4 Differing crown height/width ratios of the incisors

The right central was slightly shorter than the left, and the long axis of the maxillary left central incisor was slightly more distal than the right central. The height/width ratio revealed that the right central was 9.3 mm

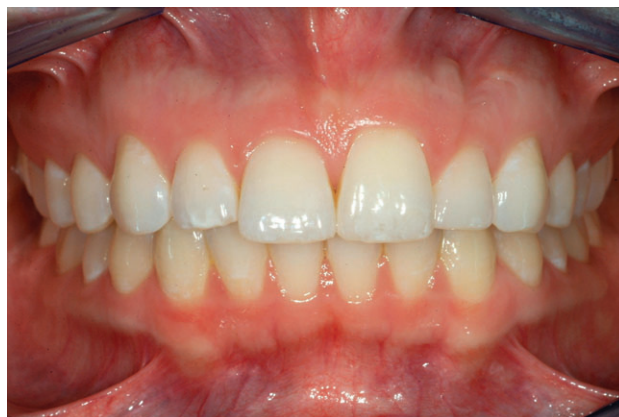

FIGURE 5. The intraoral image demonstrated reasonably well-aligned teeth with good overbite/overjet but with the previously described esthetic shortcomings.

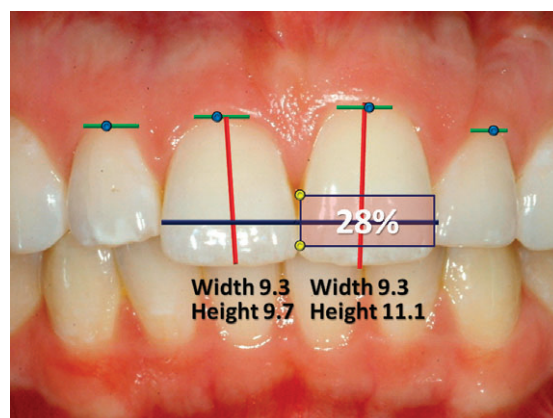


FIGURE 6. The microesthetic assessment of the anterior teeth demonstrated that the excessive gingival embrasure was a result of a short connector, and the height/width ratios between the central incisors were significantly different.

wide and 9.7 mm in height (height/width ratio of 96%), while the left central had a more desirable ratio of 81%. Evaluation of contacts, connectors, and embrasures demonstrated that the contact point is reasonable, while the connector length was short at 28%.

ENAMELOPLASTY TO IMPROVE SMILE APPEARANCE

It is important to note that we do not recommend reshaping unless the teeth are well aligned before the tooth reshaping begins. This is because if a tooth is

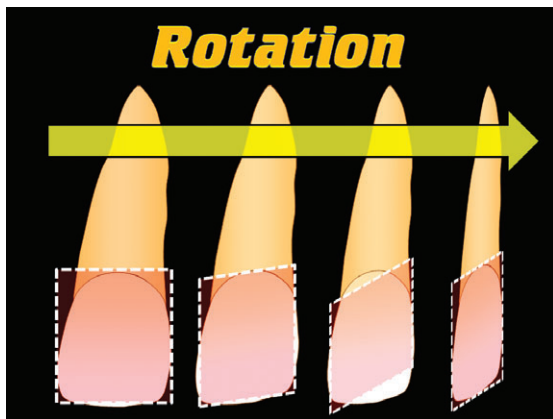


FIGURE 7. The teeth are aligned before tooth reshaping begins. If a tooth is rotated, our perception of its width is changed while the height is not, giving a misleading height/width ratio.

rotated, our perception of its width is changed while the height is not, giving a misleading height/width ratio as illustrated in Figure 7.

Step 1: Establish Height

Before removing any enamel, we recommend that the soft tissue be addressed and finalized first. The right central incisor had an unfavorable height/width ratio. Because the left central incisor was the proper height/width ratio, it was logical that the right central needed to be lengthened, if possible. Since the height of the right central was shorter than normal, after periodontal probing we decided that the right central was a good candidate for a simple laser-assisted gingivectomy (Figure 8). The gingival depth was 3 mm, and with laser assistant gingivectomy, we felt we could gain a millimeter or more of height on that tooth.

Step 2: Address the Width

Once the gingival apparatus healed and reestablished its final vertical position; we were ready to reduce the width of the two central incisors. Using a fine carbide bur (Braessler E23 AA Carbide Needle, Brasseler USA, Savannah, GA, USA) we started the process by reshaping the connector between the central incisors, elongating it between the maxillary central incisors (Figure 9). The bur has a “safe tip” as it is rounded on

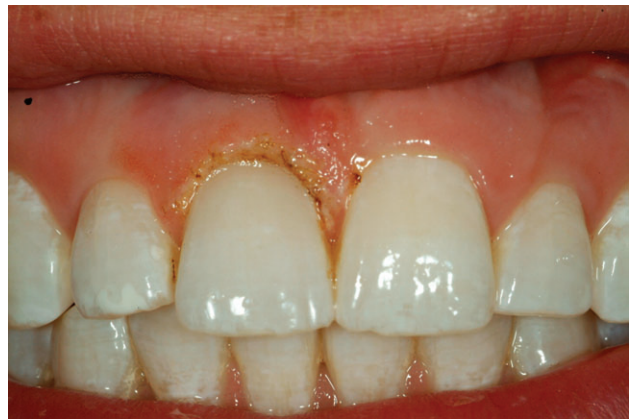

FIGURE 8. Since the height of the right central was shorter than normal, after periodontal probing, we decided that the right central was a good candidate for a simple laser-assisted gingivectomy.

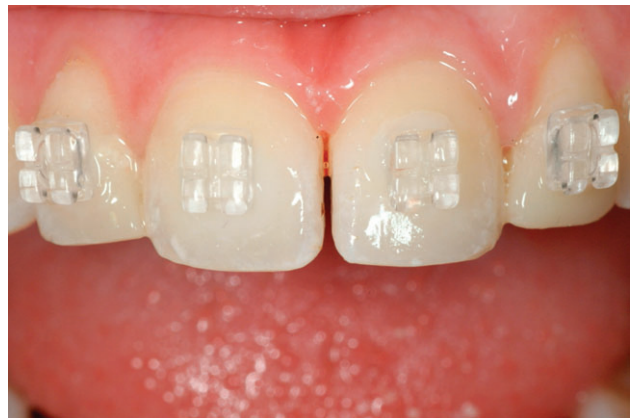

FIGURE 9. Using a fine carbide bur, we started the process by lengthening the connector between the central incisors.

the tip so that it avoids leaving an inadvertent ledge into the tooth. We perform the procedure applying the bur to the enamel in quick vertical motions to avoid any heat buildup. We also don't use local anesthesia so the patient can signal any discomfort. Occasionally, a topical anesthetic is applied if we anticipate any contact between the instrumentation and the gingival tissues in order to reduce any discomfort.

Step 3: Check the Length of the Connector

Rather than getting a measuring device to measure the length of the connector, we simply squeezed the teeth together (Figure 10). This immediately reveals any

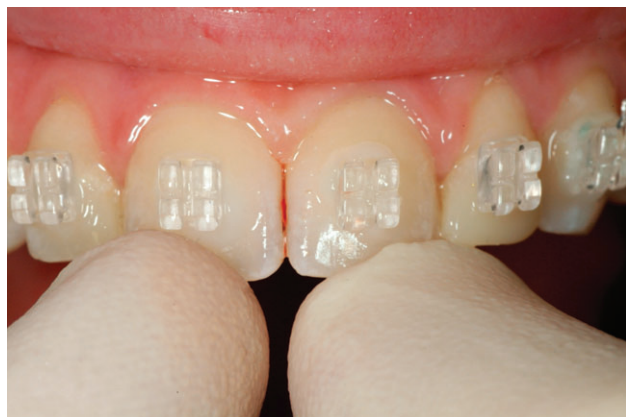

FIGURE 10. Rather than using a measuring device to measure the length of the connector, we simply squeezed the teeth together to assess connector length.

interferences and the contact length the preparation resulted in. Further incremental adjustments are made in this way.

Step 4: Round the Line Angles

Once we have worked our way through the facial and the palatal of the upper incisors with the carbide bur, the resulting line angles required finishing. We may opt to do this a number of ways, including discs and hand held strips. Our preference is to use a cone-shaped diamond (Braessler 8833 031 Diamond) and follow the connector with this bur to round the line angles (Figure 11) since this is much more efficient than hand strips. Some hand finishing is desirable, however, for a finer interproximal polish.

Step 5: Close the Space Created by the Interproximal Enamelplasty

The space created between the teeth is then closed with elastomeric chain on the orthodontic appliances (Figure 12).

Step 6: Create and Refine Embrasures

Once the space has been closed between all the teeth which have been reshaped, the embrasures are ready to finish. The embrasures are formed with the same cone-

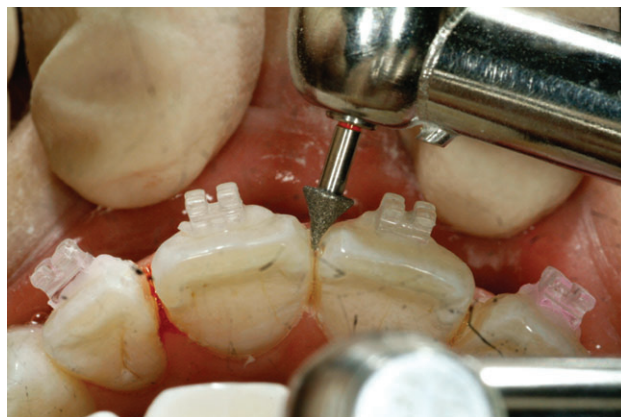

FIGURE 11. Interproximal reshaping results in line angles that required finishing. We prefer to use a cone-shaped diamond and follow the connector with this bur to round the line angles.

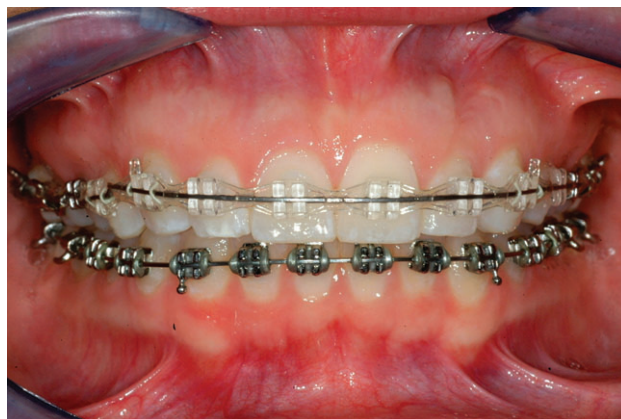


FIGURE 12. The space created between the teeth was then closed with elastomeric chain on the orthodontic appliances.

shaped diamond (8833 031 Diamond, Braessler) used to refine the line angles and embrasures (Figure 13).

Step 7: Polish to Finish

We use the 848L10 Carbide Long Flame (Braessler) followed with a rubber polishing tip to refine the enamel surface to finish.

The final results depicted in Figures 14–18. The patient's smile presentation was enhanced remarkably by the attention to the finishing details utilizing tooth reshaping to attain the microesthetic characteristics of esthetic teeth.

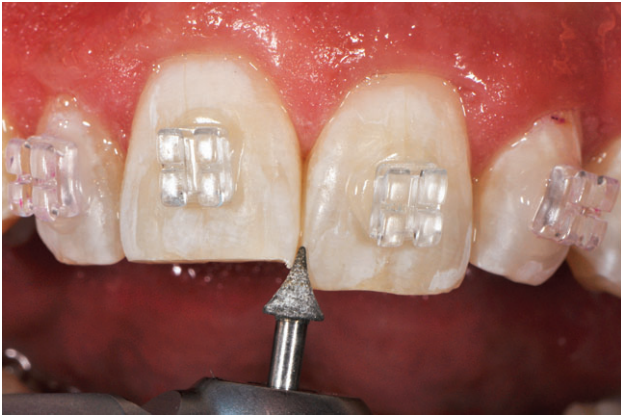

FIGURE 13. Once the space was closed, the embrasures were finished with the same cone-shaped diamond used to refine the embrasures and line angles on the facial and palatal aspects.

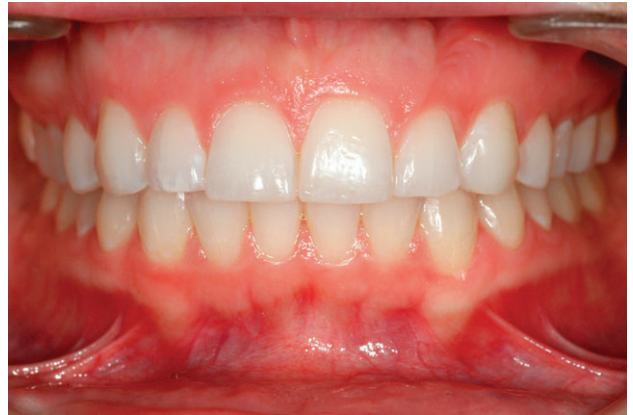

FIGURE 14. The final overjet/overjet was now ideal.

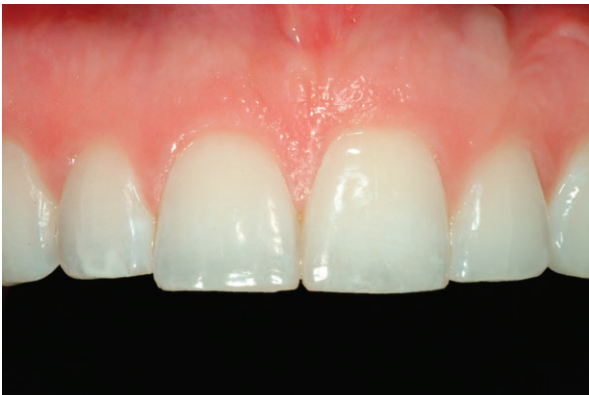

FIGURE 15. The desired contact placement, embrasures, and connector length were successfully attained. There was a slight height differential between the central not considered significant.




FIGURE 16. The final smile.

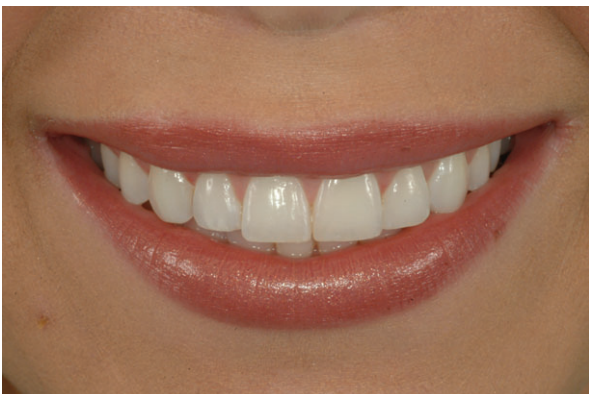

FIGURE 17. The final close-up smile.



FIGURE 18. Three years after treatment, the patient displayed a real pride in her smile and appearance.

CONCLUSION

This case demonstrates the significant improvement to a smile orthodontists can achieve if they understand the principles of dental esthetics. The actual reshaping of the teeth may be a procedure the orthodontist may be uncomfortable with, since they leave their handpieces with cutting burs behind when they leave dental school. If that is true, then at least recognition of the issues and potential solutions is important. The interdisciplinary collaboration may involve the dentist providing the enameloplasty in the appropriate order of treatment. I personally am comfortable with the reshaping and feel quite comfortable making incremental adjustments as treatment progresses.

DISCLOSURE

The author does not have any financial interest in the companies whose materials are included in this article.

REFERENCES

1. Sarver DM. Principles of cosmetic dentistry in orthodontics: part 1. Shape and proportionality of anterior teeth. *Am J Orthod Dentofacial Orthop* 2004;126:749–53.
2. Sarver DM, Yanosky MR. Principles of cosmetic dentistry in orthodontics: part 2. Soft tissue laser technology and cosmetic gingival contouring. *Am J Orthod Dentofacial Orthop* 2005;127:85–90.
3. Sarver DM, Yanosky MR. The incorporation of soft tissue lasers in orthodontic practice. Part 3. Laser treatments for tooth eruption and soft tissue problems. *Am J Orthod Dentofacial Orthop* 2005;127(2):262–4.
4. Lombardi RE. The principles of visual perception and their clinical application to denture esthetics. *J Prosthet Dent* 1973;29:358–82.
5. Takei HH. The interdental space. *Dent Clin North Am* 1980;24:169–76.
6. Takei H, Yamada H, Hau T. Maxillary anterior esthetics. Preservation of the interdental papilla. *Dent Clin North Am* 1989;33:263–73.
7. Rufenacht CR. *Fundamentals of esthetics*. Chicago (IL): Quintessence; 1990.
8. Goldstein RE. *Esthetics in dentistry*. Hamilton, Ontario: BC Decker; 1998.
9. Snow SR. Esthetic smile analysis of maxillary anterior tooth width: the golden percentage. *J Esthet Dent* 1999;11:177–84.
10. American Academy of Cosmetic Dentistry. Accreditation examination criteria, number 21: is there a progressive increase in the size of the incisal embrasures? Madison (WI): American Academy of Cosmetic Dentistry; 1999.
11. Rufenacht CR. *Principles of esthetic integration*. Chicago (IL): Quintessence; 2000.
12. Morley J, Eubank J. Macroesthetic elements of smile design. *J Am Dent Assoc* 2001;132:39–45.
13. Ward DH. Proportional smile design using the recurring esthetic dental (red) proportion. *Dent Clin North Am* 2001;45:143–54.
14. Lavacca MI, Tarnow DP, Cisneros GJ. Interdental papilla length and the perception of aesthetics. *Pract Proced Aesthet Dent* 2005;17:405–12.
15. Ahmad I. Anterior dental aesthetics: dental perspective. *Br Dent J* 2005;199:135–41.
16. Spear FM, Kokich VG, Mathews DP. Interdisciplinary management of anterior dental esthetics. *J Am Dent Assoc* 2006;137:160–9.
17. Chu SJ. Range and mean distribution frequency of individual tooth width of the maxillary anterior dentition. *Pract Proced Aesthet Dent* 2007;19:209–15.
18. Chu SJ, Tarnow DP, Tan JH, Stappert CF. Papilla proportions in the maxillary anterior dentition. *Int J Periodontics Restorative Dent* 2009;29(4):385–93.
19. Stappert CFJ, Tarnow DP, Tan JH-P, Chu SJ. Proximal contact areas of the maxillary anterior dentition. *Int J Periodontics Restorative Dent* 2010;30(5):471–7.

Reprint requests: David M. Sarver, DMD, MS, 1705 Vestavia Parkway, Vestavia Hills, AL 35216, USA; Tel.: 205-979-7072; Fax: 205-979-7140; email: sarverd@sarverortho.com

This article is accompanied by commentary, Enameloplasty and Esthetic Finishing in Orthodontics Part 1 and Part 2, Dan Grauer, DDS, PhD, Gavin Heymann, DDS, MS
DOI 10.1111/j.1708-8240.2011.00448.x

Copyright of Journal of Esthetic & Restorative Dentistry is the property of Wiley-Blackwell and its content may not be copied or emailed to multiple sites or posted to a listserv without the copyright holder's express written permission. However, users may print, download, or email articles for individual use.