

Contemporary Issues


CROWN MARGINS IN THE ESTHETIC ZONE

Guest Expert

Edward P. Allen, DDS, PhD*

Associate Editor

Edward J. Swift, Jr., DMD, MS



Editor's Note: If you have a suggestion for any topic to be discussed in *Contemporary Issues*, please direct it to the Associate Editor, Dr. Edward J. Swift, Jr. We will forward suggestions to appropriate experts and print the answers in this regular feature.

Dr. Edward J. Swift, Jr.
Department of Operative Dentistry
University of North Carolina
CB#7450, Brauer Hall
Chapel Hill, NC 27599-7450
Telephone: 919-966-2770; Fax: 919-966-5660
E-mail: ed_swift@dentistry.unc.edu

In determining where to place a crown margin in the presence of gingival recession, soft tissue grafting would cover the root completely and allow crown margin placement at the new gingival level, thus providing ideal esthetics. However, complete root coverage is not always possible.

Complete root coverage is highly predictable only at sites without loss of interdental tissue according to the Miller Classification.¹ If there is loss of interdental tissue fill, only partial root coverage can be expected.

So, how can you determine how much root coverage to expect at

sites with loss of papilla fill? The dimensions of the papillae adjacent to the teeth with recession will predict the amount of root coverage that can be achieved. The papilla is the triangular gingival tissue between the teeth. Soft tissue grafting can bring the facial gingival margin to within 3 mm of the papilla tip, providing that the

*Private practice, Dallas, TX, USA; Adjunct Professor, Department of Periodontics, Baylor College of Dentistry, Texas A&M University System Health Science Center, Dallas, TX, USA; and Director, Center for Advanced Dental Education, Dallas, TX, USA

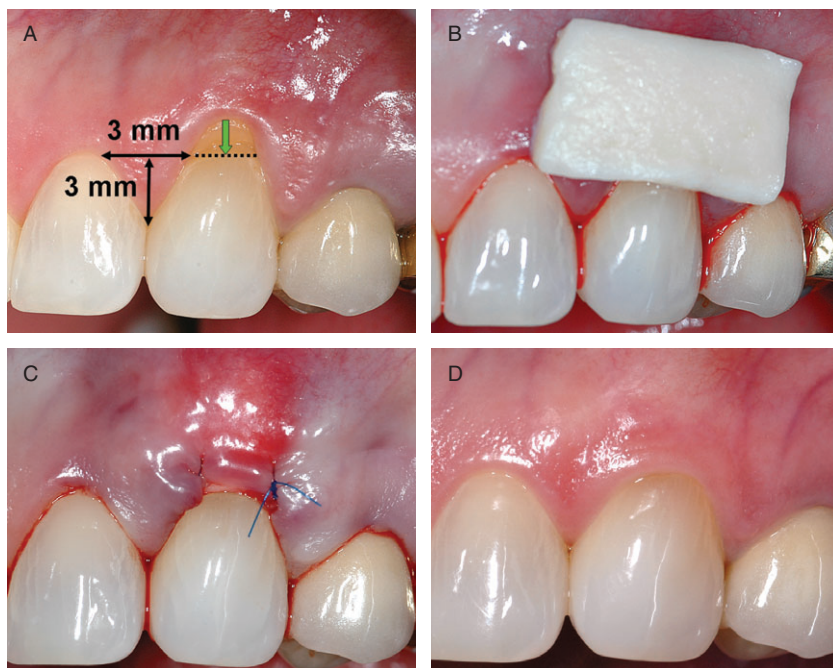

Figure 1. A, Root coverage can be achieved to a level 3 mm apical to the papilla tip providing the papilla is 3 mm wide at that level. B, AlloDerm graft on the surface before insertion into the pouch recipient site. C, AlloDerm graft inserted into pouch and sutured. D, Complete root coverage achieved as seen at 4 years after surgery.

papilla has a width of at least 3 mm at its base. The papilla base is located at a point 3 mm apical to the papilla tip (Figure 1). If the papilla is narrower than 3 mm at its base, it will not support the graft over the root at this level and less root coverage will be achieved.

If a provisional crown must be placed on a tooth with gingival recession before soft tissue grafting, the margin should not extend more apically than 3 mm apical to the adjacent papillae tips. This will

allow the surgeon to graft to the restoration margin. If less root coverage is achieved, the finish line may be extended after maturation of the graft, usually 6 months after grafting surgery.

Root coverage with coronally advanced flaps results in an excellent match of tissue color and form.² However, coronally advanced flaps alone are not as effective in achieving complete root coverage as coronally advanced flaps augmented by a graft.^{3,4} In sites of root exposure where full

crowns are planned, it is advisable to coronally advance the marginal tissue completely over a graft rather than use a coronally advanced flap alone or an exposed graft. This combined grafting method will improve root coverage and enhance resistance to recurrent recession while achieving the esthetic outcome associated with coronally advanced flaps.

Today's minimally invasive site preparation techniques and the use of AlloDerm (LifeCell Corporation, Branchburg, NJ, USA) as a substitute for palatal donor tissue have achieved root coverage results comparable to palatal connective tissue grafts (Figures 1 and 2).⁵ The newer allograft techniques reduce the morbidity associated with earlier grafting techniques and encourage patients to complete the ideal care rather than choose the less desirable alternative of extending a crown margin over an exposed root surface.⁶

REFERENCES

1. Miller PD Jr. A classification of marginal tissue recession. *Int J Period Restor Dent* 1985;5:9–13.
2. Zucchelli G, De Sanctis M. Treatment of multiple recession-type defects in patients with esthetic demands. *J Periodontol* 2000;71:1506–14.
3. Woodyard JG, Greenwell H, Hill M, et al. The clinical effect of acellular dermal matrix on gingival thickness and root coverage compared to coronally positioned flap alone. *J Periodontol* 2004;75:44–56.

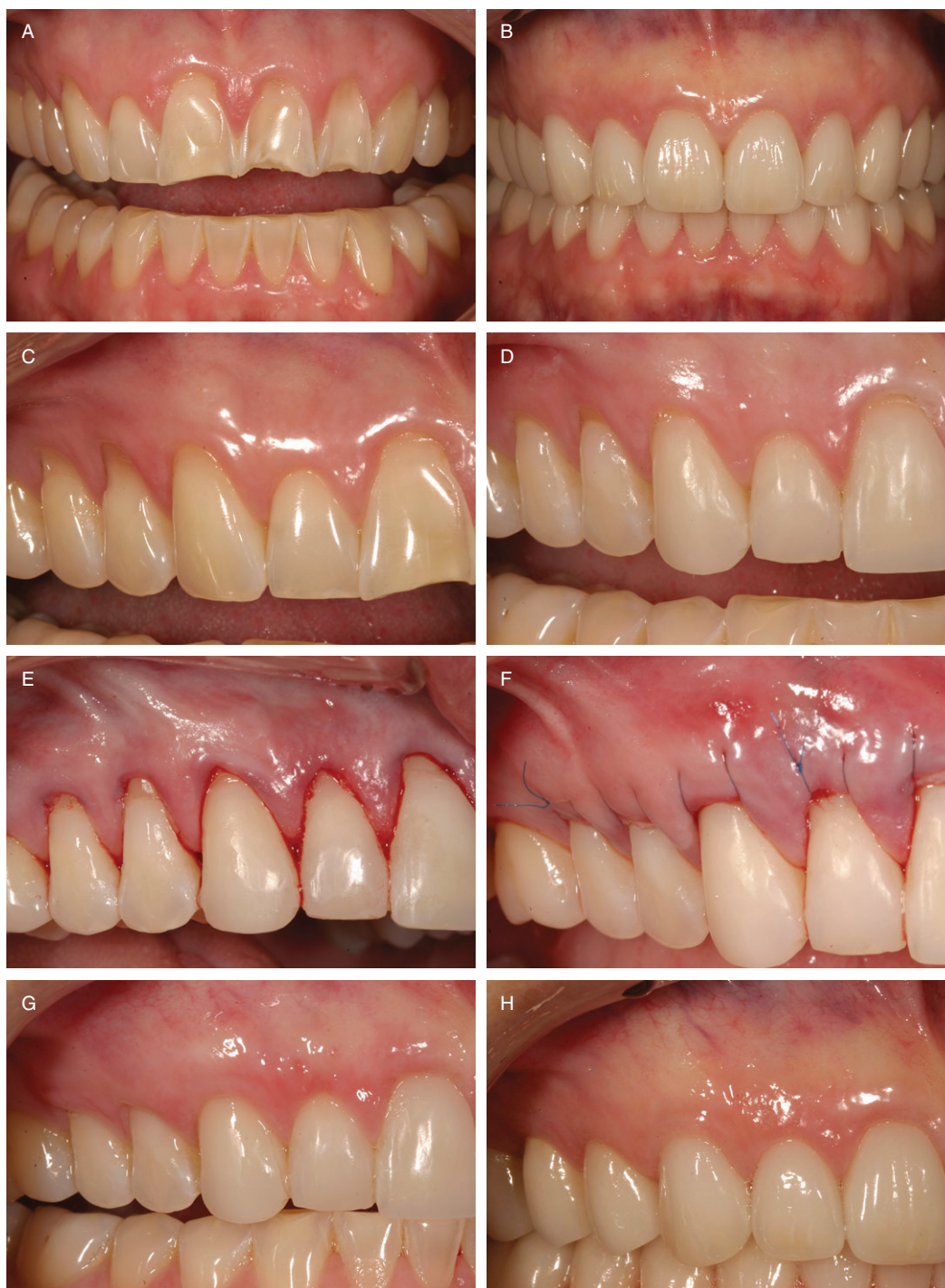

Figure 2. A, Generalized erosion, abrasion, and tooth wear requiring full-coverage restorations complicated by generalized gingival recession. B, Restoration of ideal tooth form with full-coverage restorations made possible by root coverage grafting resulting in enhanced esthetics. C, Maxillary right quadrant prior to treatment. D, Composite bonding restores the areas of lost enamel without extending onto root surfaces. The bonding will serve as provisional restorations during the healing period after soft tissue grafting. E, A tunnel recipient site is prepared facial to the incisors, canine, and premolars and root planing is completed. F, An 8 × 42-mm AlloDerm graft has been secured facial to the incisors, canine, and premolars within the tunnel with a subpapillary continuous sling suture. G, Complete root coverage to the composite margins has been achieved. H, At 6 months after surgery, final full-coverage porcelain restorations have been placed.

4. Cortellini P, Tonetti M, Baldi C, et al. Does placement of a connective tissue graft improve the outcomes of coronally advanced flap for coverage of single gingival recessions in upper anterior teeth? A multi-center, randomized double-blind, clinical trial. *J Clin Perio* 2009;36:68–79.
5. Gapski R, Parks CA, Wang H-L. Acellular dermal matrix for mucogingival surgery: a meta-analysis. *J Periodontol* 2005;76:1814–22.
6. Allen EP. Subpapillary continuous sling suturing method for soft tissue grafting with the tunneling technique. *Int J Periodontics Restorative Dent* 2010;30:479–86.

Reprint requests: Edward P. Allen, DDS, PhD, 8335 Walnut Hill Lane, Suite 210, Dallas, TX 75231; email: epallen@epallendds.com
Restorative dentistry by Robert R. Winter, DDS and ceramics by Winter Laboratory, Scottsdale, AZ.

Editor's Note: If you have a suggestion for any topic to be discussed in Contemporary Issues, please direct it to the Associate Editor, Dr. Edward J. Swift, Jr. We will forward suggestions to appropriate experts and print the answers in this regular feature.

Dr. Edward J. Swift, Jr.
 Department of Operative Dentistry
 University of North Carolina
 CB#7450, Brauer Hall
 Chapel Hill, NC 27599-7450
 Telephone: 919-966-2770; Fax: 919-966-5660
 E-mail: ed_swift@dentistry.unc.edu

Copyright of Journal of Esthetic & Restorative Dentistry is the property of Wiley-Blackwell and its content may not be copied or emailed to multiple sites or posted to a listserv without the copyright holder's express written permission. However, users may print, download, or email articles for individual use.