

Treatment Concept with CAD/CAM-Fabricated High-Density Polymer Temporary Restorations

JAN-FREDERIK GÜTH, DMD*, JÚNIO S. ALMEIDA E SILVA, DMD†, MARC RAMBERGER‡, FLORIAN BEUER, PhD§, DANIEL EDELHOFF, Prof. PhD¶

ABSTRACT

Tooth wear in younger patients is perceived worldwide as an increasing problem. Its etiology is multifactorial (erosion, abrasion, attrition), and its treatment is challenging for the dental practitioner specifically when a great loss of the vertical dimension of occlusion has occurred.

The aim of this article is to present a treatment approach for complex cases with high loss of tooth structure using computer-aided design/computer-aided manufacturing (CAD/CAM)-fabricated temporary high-density polymer restorations without any preparations.

New manufacturing technologies and innovative materials such as high-density polymers offer good possibilities for restorations during the pretreatment period. This is especially important in circumstances requiring massive corrections of color, form, or position. Pretreatment periods are indispensable in refining important factors such as lip-position dynamics as well as the correct position of the smile line, which cannot be adequately assessed in the dental laboratory. In the presented case report, CAD/CAM-fabricated non-preparation restorations were adhesively placed on the worn dentition without any further loss of tooth structure.

Such an approach provides the opportunity to “test-drive” the new restoration design in terms of function, phonetics, and esthetics, thus improving the predictability of the definitive restorations design. If any change in the design is required, it can be cost-effectively achieved through simple modification or replacement of the restorations.

CLINICAL SIGNIFICANCE

The prolonged pretreatment phase using CAD/CAM-fabricated high-density polymer temporaries can help the practitioner turn challenging treatments into more predictable ones with respect to function and esthetics.

(J Esthet Restor Dent 24:310–320, 2012)

INTRODUCTION

Tooth wear, a pathological loss of tooth tissue by a disease process other than dental caries,¹ is perceived worldwide as an increasing problem. It stands as a great

challenge for the practitioner as far as diagnosing the condition, identifying the etiological factors, executing an adequate treatment, and instituting preventive measures.² The etiology of tooth wear is multifactorial and is based on mechanical processes, such as attrition,

*Dentist, Assistant Professor, Department of Prosthodontics, Dental School of the Ludwig-Maximilians University, Munich, Germany

†Dentist, PhD student, Department of Operative Dentistry, Federal University of Santa Catarina, Florianópolis; Visiting Researcher, Department of Prosthodontics, Dental School of the Ludwig-Maximilians University, Munich, Germany

‡Master Dental Technician, Department of Prosthodontics, Dental School of the Ludwig-Maximilians University, Munich, Germany

§Privatdozent, Dentist, Associate Professor, Department of Prosthodontics, Dental School of the Ludwig-Maximilians University, Munich, Germany

¶Dentist, Tenured Associate Professor, Department of Prosthodontics, Dental School of the Ludwig-Maximilians University, Munich, Germany

abrasion, and abfraction and also on a chemical process, which is dental erosion.^{3–5} Although dental erosion might play a major role in tooth wear, it becomes apparent that the patho-dynamical mechanisms of tooth wear lie in a combined action of mechanical and chemical processes during the interocclusal activity.^{3,6,7}

As tooth wear is a highly prevalent condition,^{8–10} it is paramount to establish early diagnosis and preventive measures. In order to prevent or reduce the tooth wear, it is important first of all, to recognize that the problem is present, then grade its severity, diagnose the likely cause or causes, and finally, monitor the progress of the disease in order to assess the success, if any, of preventive measures.^{11,12}

Besides diagnosis and monitoring of tooth wear, complex rehabilitations provide a challenge for the restorative team, especially in cases where a new vertical dimension of occlusion (VDO) has to be designed and reestablished. New manufacturing technologies and innovative materials such as high-density polymers offer new treatment possibilities. Many manufacturers offer high-density polymers based on a highly cross-linked polymethylmetacrylate (PMMA) or composite for computer-aided design/computer-aided manufacturing (CAD/CAM).¹³ Due to its industrial manufacturing, high-density polymer-based restorations show increased physical properties compared to provisional restorations directly manufactured at the office or at the dental laboratory.^{14,15} The aim of this article is to present a treatment approach for complex cases with high loss of tooth structure using CAD/CAM-fabricated temporary high-density polymer restorations without any preparations.

CASE REPORT

Treatment Plan

A 28-year-old female patient was referred to the Department of Prosthodontics at Ludwig-Maximilian University (LMU) in Munich with a chief complaint of

severe tooth wear and unesthetic dental appearance. General anamnesis revealed bulimia nervosa lasting for almost 12 years. Even though the general medical history was noncontributory, the attending psychotherapist validated that the patient was stable in terms of bulimia nervosa and affirmed further prosthodontic treatment.

Extraoral examination revealed a misbalance of the facial proportion with a decreased height of the lower facial third. Clinical intraoral examination showed generalized severe tooth wear with substantial loss of tooth structure, displaying exposed dentin, a collapsed VDO, as well as multiple unsatisfactory restorations (Figures 1–5). After discussing several treatment alternatives, the restorative team along with the patient decided on the following procedures, as described by Edelhoff and Brix.¹⁶

- 1 Restorative and endodontic treatment with replacement of unsatisfactory restorations (Figures 6 and 7).
- 2 Evaluation of the proposed restoration design with increased VDO by using a full-mouth wax-up (Figure 8) and mock-up “esthetic try-in” (Figure 9).
- 3 Three-step splint therapy with different thicknesses (3 mm, 5 mm, 7 mm) for 9 months in order to increase the VDO (Figure 10).
- 4 Reconstruction of the teeth with adhesively placed, non-preparation CAD/CAM-fabricated high-density-polymer long-term temporaries.
- 5 Long-term evaluation (possibly up to 2 years) of the new restorative design in terms of function, phonetics, and esthetics.

Wax-up and Three-Step Splint Technique

Plaster models made of both arches were articulated after facial bow registration. The occlusion was functionally analyzed, and a new VDO was defined, followed by a full-mouth wax-up. In order to evaluate the new restorative design and to validate the newly created VDO a mock-up was conducted. For this purpose, a polyester-based diagnostic template was manufactured in the dental laboratory of the wax-up

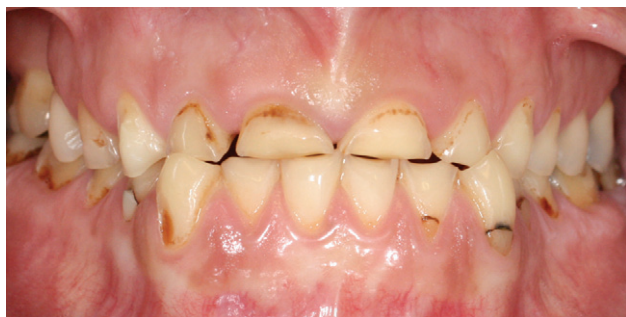

FIGURE 1. Preoperative view: severe tooth wear with loss of vertical dimension of occlusion, unsatisfactory restorations, and unpleasant esthetic appearance.

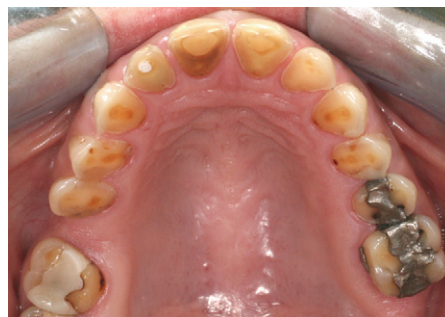

FIGURE 2. Occlusal view of the maxilla: large areas of exposed dentin with prominent restorations elevated above the surrounding tissue ("amalgam islands").

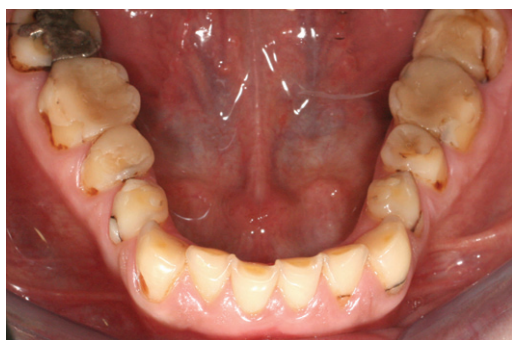

FIGURE 3. Occlusal view of mandible: large areas of exposed dentin and extensive restorations.

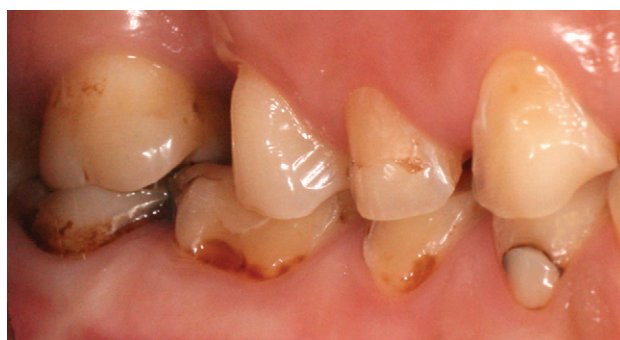

FIGURE 4. Vestibular view right: combined cervical caries/erosive lesions.

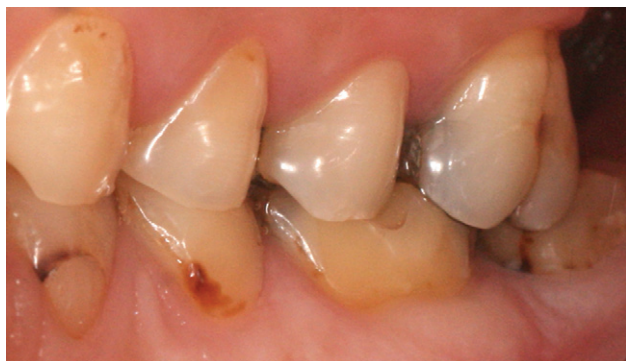

FIGURE 5. Vestibular view left.

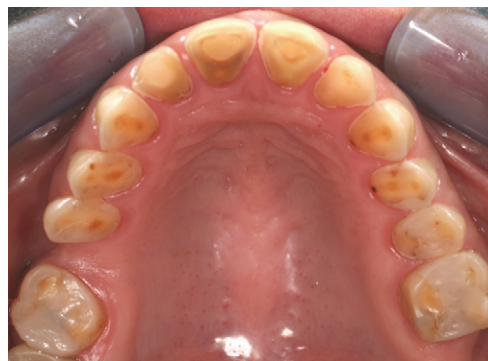

FIGURE 6. Occlusal view of the maxilla after replacement of all unsatisfactory restorations.

and afterwards filled up with temporary material from a dispenser (Protemp 4, 3M ESPE, Seefeld, Germany), and the template was seated in the patient's mouth (Figure 9). As the mock-up was acceptable, the three-step splint therapy was implemented. The three-step splint technique consisted of a gradual

increase of VDO by means of three splints with increasing thicknesses (3 mm, 5 mm, 7 mm) based on the estimation of the required space for the reconstruction of VDO on the articulator. The patient was given the first 3-mm-thick splint and was instructed to use it as much as possible for 3 months,

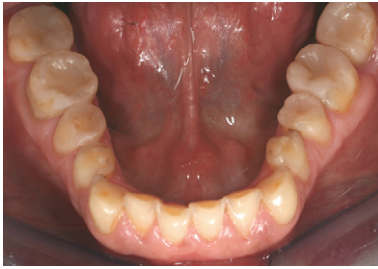

FIGURE 7. Occlusal view of the mandible after replacement of all unsatisfactory restorations.

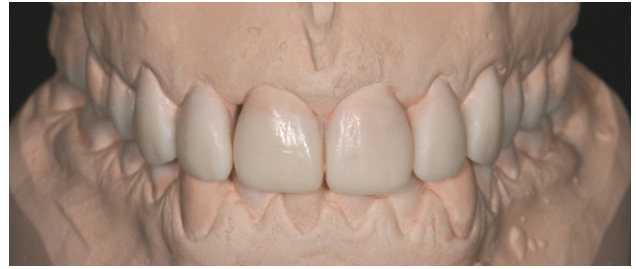

FIGURE 8. Full-arch wax-up of maxilla and mandible for the first proposal in the articulator: after a functional analysis, the vertical dimension of occlusion was raised 7 mm.

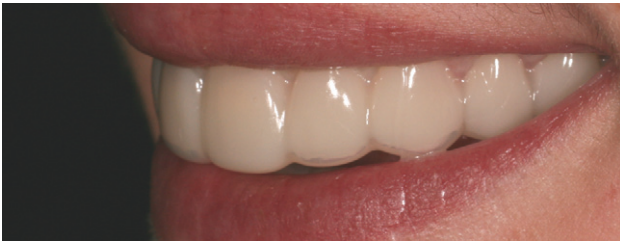

FIGURE 9. “Esthetic try-in.” Transfer of the wax-up by diagnostic template (polyester) with provisional material from a dispenser system for intraoral evaluation of the treatment objective.

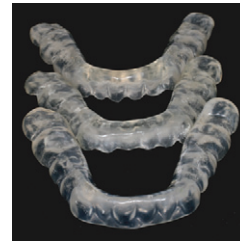

FIGURE 10. The elevation of the vertical dimension of occlusion was carried out by a three-step splint therapy using removable splints of 3 mm, 5 mm, and 7 mm for 3 months each.

and then the other splints were used for the same period, so the patient's masticatory system could get accustomed to the reconstructed VDO during the 9-month period.

After determining that the patient could tolerate the increased VDO without any problems over 9 months, the restorative team decided to transfer the existing VDO into temporary restorations using high-density polymers. No preparation was performed in order to avoid a further loss of the worn tooth structure. Abandoning preparation was feasible because of the good machining and physical properties of the high-density polymer.

Impression Taking and Restorations Placement

In order to take impressions, retraction cords were needed in some palatal areas to expose some tooth surfaces, in which tooth wear had reached gingival level. A retraction cord (No. 0, Ultrapak, Ultradent Products, Inc., South Jordan, UT, USA) was inserted, and retraction

of the gingival tissues was carried out for 4 minutes. Then, a full-mouth impression with polyether (Impregum, 3M ESPE) was taken of both maxillary and mandibular dentitions. Subsequently, plaster models were obtained and digitized by a D700 Scanner (3shape, Copenhagen, Denmark) (Figures 11 and 12).

The restorations were designed using the Cara-System (Heraeus Kulzer, Hanau, Germany) (Figures 13 and 14) and centrally fabricated at Heraeus (material: Cara PMMA Provisional, Heraeus Kulzer) (Figures 15 and 16) and finished at the dental laboratory of the Department of Prosthodontics of LMU. Bite transfer was performed by the “test-driven” last splint, which was separated in half for the transfer to the articulator and finally polymerized again into one piece for the period until the placement of the high-density polymer restorations. The restorations were adhesively placed by means of a total etch technique and Variolink II (Ivoclar Vivadent, FL-Schaan, Liechtenstein). The placement technique was carried out by sectioning the 7 mm splint into two halves between the central

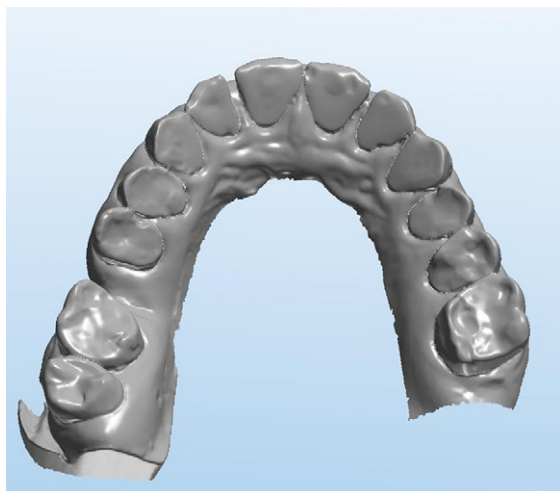


FIGURE 11. Occlusal view of the digitized maxilla model. For digitalization, the D-700 3Shape dental scanner were combined with the Cara computer-aided design/computer-aided manufacturing (CAD/CAM) system.

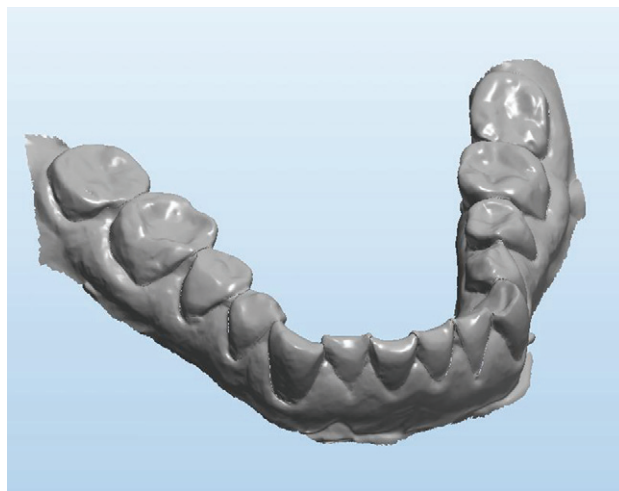


FIGURE 12. Occlusal view of the digitized mandible model as the basis for further design and construction of the long-term temporaries.

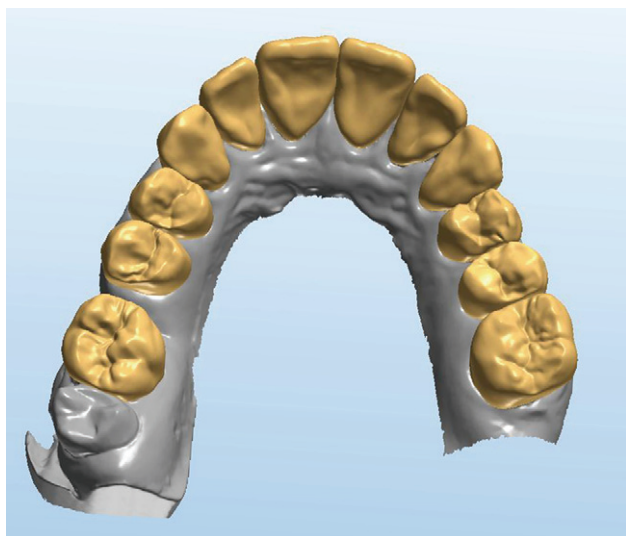


FIGURE 13. Designed maxilla restorations using dental designer software.

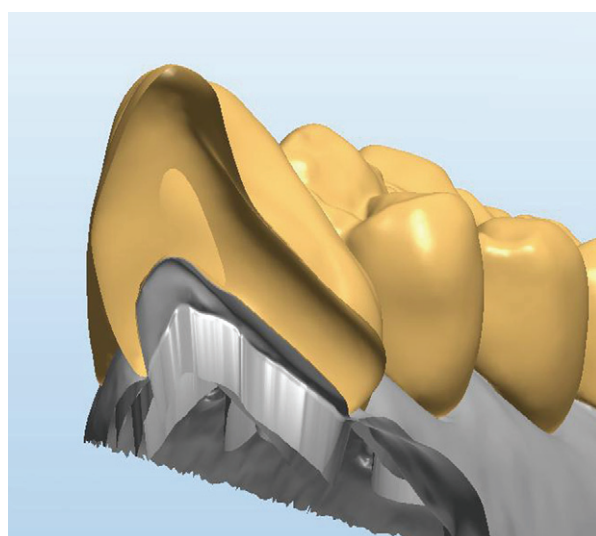


FIGURE 14. Profile view of the upper jaw restoration of tooth #21 (World Dental Federation, FDI) showing the possibility of seating the crown without preparation and supragingival margins.

incisors. One half splint was seated in the patient's mouth, and the maxillary and mandibular posterior restorations were placed on the contralateral free hemi-arch so that the corrected occlusion could be maintained by the divided splint (Figures 17 and 18). The final aspect of the long-term provisional restorations in situ is displayed on Figures 19 through 23.

DISCUSSION

The treatment of tooth wear with high loss of the VDO represents a great challenge for the restorative team, especially in relation to functional and esthetic issues. The presented treatment begins with the esthetic try-in.¹⁶ This procedure provides an estimation of the

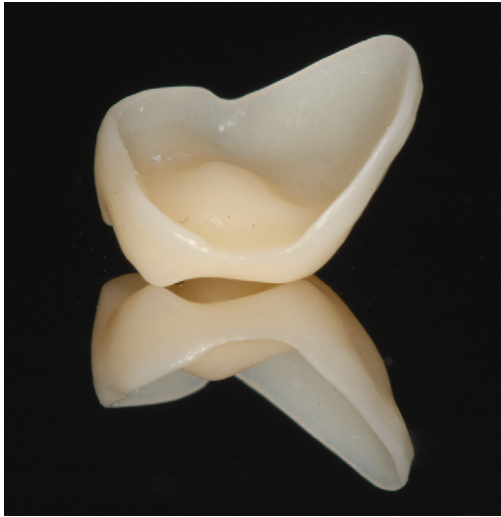

FIGURE 15. High-density polymer long-term-temporary partial crown of tooth #45 (World Dental Federation, FDI). The good CAD/CAM properties of the material allow milling the margins of the restorations extremely thin.

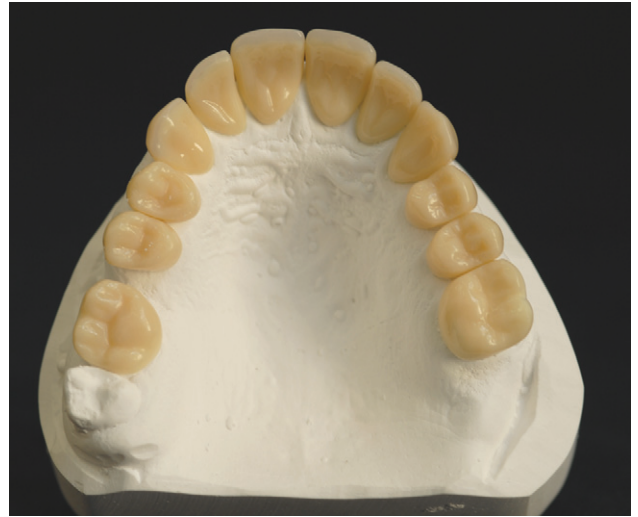

FIGURE 16. Occlusal view of the maxillary restorations in the dental laboratory.

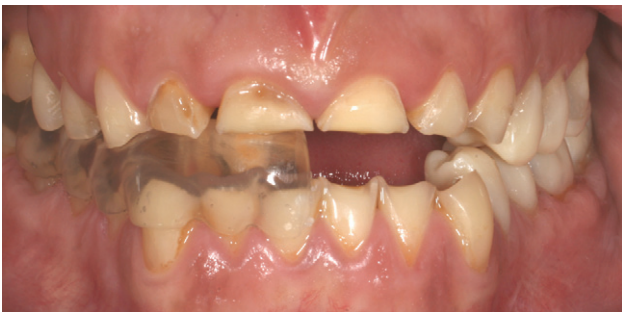

FIGURE 17. First step of seating procedure: the occlusal contacts and bite relation of the restorations placed with total etch technique are checked with the help of the divided splint that is no longer needed to get the correct jaw relation.

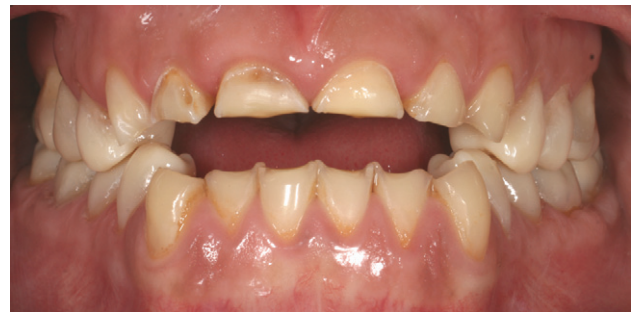

FIGURE 18. Second step of seating: evaluation of occlusal contacts and jaw relation in orientation to the already seated and correctly permanently adapted temporaries.

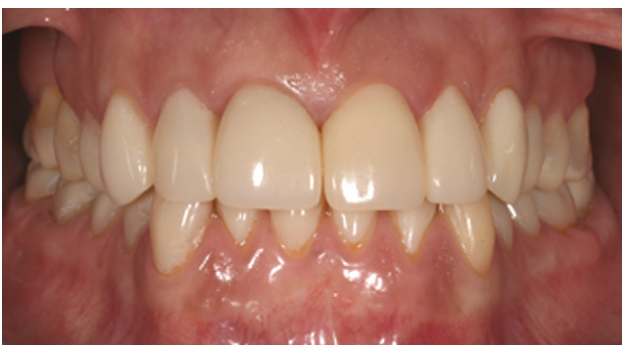

FIGURE 19. Facial view of the definitely placed long-term temporaries.

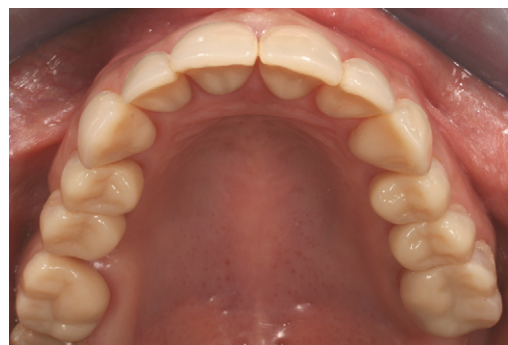

FIGURE 20. Occlusal view of the definitely placed temporaries in the maxilla.

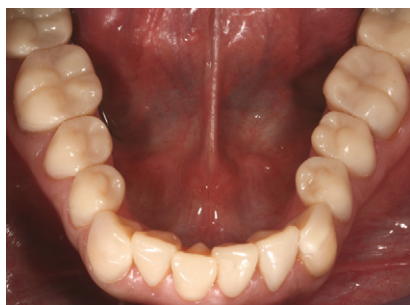

FIGURE 21. Occlusal view of the definitively placed temporaries in the mandible.

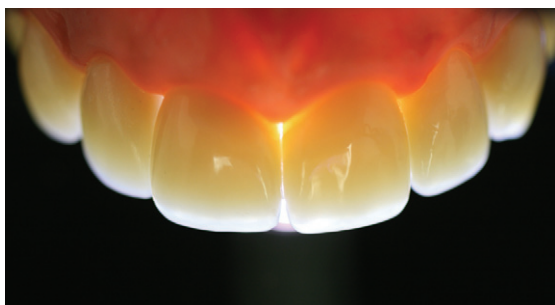


FIGURE 23. Light transmission through the definitively placed anterior restorations.

final restorative result for the patient and the restorative team and might act as a motivational tool for the patient.

After acceptance of the full-mouth wax-up and “esthetic try-in,” the 9-month three-step splint therapy to increase the VDO was initiated. Once the increased VDO was comfortable for the patient, the final splint position was transferred into long-term CAD/CAM-fabricated polymer restorations that were adhesively placed without further loss of tooth structure. By stretching the pretreatment period, the presented procedure can improve the predictability of the definitive restorations by making it feasible to “test-drive” the new restoration design with reference to function, phonetics, and esthetics.¹⁷ In circumstances where extensive corrections of color, form, or tooth position in the esthetic area are required, extended pretreatment periods are indispensable to evaluate and control factors like lip-position dynamics and the correct position of the smile line, which cannot be adequately estimated in the dental laboratory.

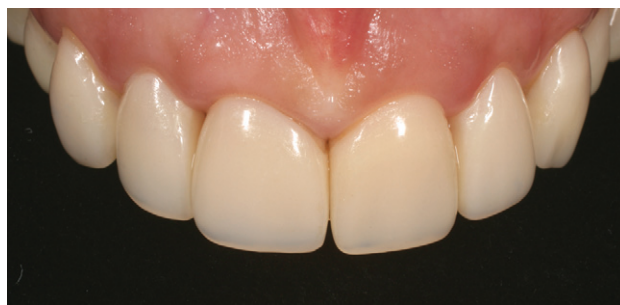

FIGURE 22. Facial view of the definitively placed restorations in the anterior maxilla.

Moreover, periodontological treatments, endodontically treated teeth, buildups, and evaluation of the abutment quality can be integrated during the pretreatment phase. Thus, if any change in the design is required, it can be cost-effectively done by easy modification or replacement of the temporary restorations. Besides, the temporary restoration represents a communication between patient, dentist, and dental technician at this treatment stage.¹⁷ From the functional standpoint, it provides a means to transfer the successfully adjusted jaw position, e.g., after occlusal splint therapy for the reconstruction of the VDO into a stable, long-term temporary.¹⁸ After the satisfying reevaluation of the occlusion and esthetics, the temporary restorations can be replaced by definitive restorations quadrant by quadrant with the aid of the divided splint placement technique. The industrially manufactured polymer restorations might remain in situ as core buildups for definitive restorations as well.

Because in this case, no tooth preparation was performed, a slight overcontour of the emergence profile was expected. From a clinical standpoint, all the designed margins should be primarily located supragingivally, in order to prevent periodontal disorders, and milled to a featheredge. PMMA or composite-based high-density polymers can be milled in a precise outline and to a very thin thickness without compromising their strength or cracking during the milling process, which might happen with ceramics. The authors made the experience, that high-density polymers can be milled to a minimal thickness of 0.3 mm.

The proposed technique is based on temporaries with no need for tooth preparation. However, if undercuts such as cervical non-carious lesions are present, there are three options: (1) selective tooth preparation could be done, such that a correct axial insertion angle is achieved, (2) the restoration's margin could be adapted to the tooth's anatomical condition to avoid placement in undercut areas, and (3) the undercuts could be eliminated by composite restorations in such areas. This has to be considered during the planning phase.

CAD/CAM high-density polymer restorations are industrially fabricated and present enhanced properties compared to lab-fabrication methods. For instance, CAD/CAM polymers exhibit higher homogeneity by less infiltration of pollutants and bubbles, higher fracture resistance, and enhanced color stability. In addition, the CAD/CAM process avoids an air-inhibited surface layer on conventional self-cure or visible light cure (VLC) acrylics, as well as polymerization shrinkage.¹⁸

Treatments based on the Dahl concept¹⁹ to restore the worn dentition wherein reduced crown height and VDO loss are present have been reported.^{20,21} Although adverse effects seldom seem to occur, good compliance by the patient is required for successful treatment, which can take up to an 18- to 24-month period.²⁰ Moreover, adhesively fixed nickel-chrome restorations,²² ceramic onlays, and direct composite restorations have also been used in similar cases.^{23–26} However, the laboratory manufacturing of metal or porcelain restorations presents disadvantages of cost and extensive required clinical time. The inherent impreciseness and difficulties of free hand increased VDO with direct composite restorations and inferior composite resin mechanical properties stand as major drawbacks of such a technique.

A 6-month follow-up has been done, and the restorations in the present case were in good condition so far. There were no clinical signs of microleakage, secondary caries, staining, discoloration, and plaque accumulation, and no restoration fractures were

observed. Moreover, the patient did not show any signs of craniomandibular dysfunction.

Even though long appointments are necessary for adhesive placement of the restorations and their current cost might be drawbacks, this approach seems to be a promising and easier technique for the rehabilitation of generalized worn dentition as well as for any large rehabilitation.²⁷ Future perspectives hold numerous paths such as integration with digital impression for a totally digital workflow and development of the high-density polymers toward definitive restorations with little or no preparation.

In addition to the restorative treatment, eliminating the cause and establishing preventive measures are of great importance and represent the initial steps in the management of tooth wear.² That is to say, diminishing the frequency and severity of the acid challenge, enhancing the defense mechanisms of the body (increasing salivary flow), enhancing remineralization, improving chemical protection, decreasing abrasive forces, providing mechanical protection and monitoring.

CONCLUSIONS

The described concept offers a comparatively easier way to manage severe cases of tooth wear. The prolonged pretreatment phase by use of high-density polymer temporaries can help the practitioner to turn challenging treatments into more predictable ones with respect to function and esthetics. Furthermore, it is a less stressful procedure for both patients and dentists on a daily basis.

DISCLOSURE AND ACKNOWLEDGEMENTS

The authors of this paper do not have any financial interest in any of the companies whose products are discussed in this paper.

The second author was supported by the Brazilian Federal Agency for Support and Evaluation of Graduate Education (grant no. BEX 2354101).

REFERENCES

1. Lussi A. Erosive tooth wear—a multifactorial condition of growing concern and increasing knowledge. In: Lussi A, editor. *Dental erosion—from diagnosis to therapy*. Bern: Karger; 2006, pp. 1–8.
2. Gandara BK, Truelove EL. Diagnosis and management of dental erosion. *J Contemp Dent Pract* 1999;1(1):16–23.
3. Grippo JO, Simring M, Scheriner S. Attrition, abrasion, corrosion and abfraction revisited: a new perspective on tooth surface lesions. *J Am Dent Assoc* 2004;135(8):1109–18.
4. Moss SJ. Dental erosion. *Int Dent J* 1998;48(6):529–39.
5. Ganss C. Definition of erosion and links to tooth wear. In: Lussi A, editor. *Dental erosion—from diagnosis to therapy*. Bern: Karger; 2006, pp. 9–16.
6. Bartlett DW, Shah P. A critical review of non-carious cervical (wear) lesions and the role of abfraction, erosion, and abrasion. *J Dent Res* 2006;85(4):306–12.
7. Pegoraro LF, Sclaro JM, Conti PC, et al. Noncarious cervical lesion in adults: prevalence and occlusal aspects. *J Am Dent Assoc* 2005;136(12):1694–700.
8. Nunn JH, Gordon PH, Morris AJ, et al. Dental erosion—changing prevalence? A review of British national childrens' surveys. *Int J Paediatr Dent* 2003;13(2):98–105.
9. Jaeggi T, Lussi A. Prevalence, incidence and distribution of erosion. In: Lussi A, editor. *Dental erosion—from diagnosis to therapy*. Bern: Karger; 2006, pp. 44–65.
10. Borcic J, Anic I, Urek MM, Ferreri S. The prevalence of non-carious cervical lesions in permanent dentition. *J Oral Rehabil* 2004;31:117–23.
11. Holbrook WP, Ganss C. Is diagnosing exposed dentine a suitable tool for grading erosive loss? *Compend Contin Educ Dent* 2004;25(9 Suppl 1):40–3.
12. Bartlett DW. Retrospective long term monitoring of tooth wear using study models. *Br Dent J* 2003;194(4):211–3.
13. Stawarczyk B, Sailer I, Sapina B, et al. Quo Vadis Provis? *Dent Dialogue* 2009;10:30–48.
14. Stawarczyk B, Ender A, Trottmann A, Hämmerle CHF. Einfluss der Verbinderquerschnittfläche auf die Bruchlast von dreigliedrigen Provisorien. *Konventionell versus CAD/CAM. Quintessenz Zahntech* 2009;36:922–8.
15. Jakob F, Jungbauer G, Schneider J, et al. Biocompatibility of new CAD/CAM machinable materials for provisional long-term restorations. 45th Meeting IADR Barcelona 2010, Abstract 134462.
16. Edelhoff D, Brix O. All-ceramic restorations in different indications—a case series. *J Am Dent Assoc* 2011;142(Suppl 2):14S–19S.
17. Rieder CE. The use of provisional restorations to develop and achieve esthetic expectations. *Int J Periodontics Restorative Dent* 1989;9:122–39.
18. Fasbinder DJ. Materials for chairside CAD/CAM restorations. *Compend Contin Educ Dent* 2010;31(9):702–4, 706, 708–9.
19. Dahl BL, Krogstad O, Karlsen K. An alternative treatment of cases with advanced localised attrition. *J Oral Rehabil* 1975;2:209–14.
20. Poyser NJ, Porter RWJ, Briggs PFA, et al. The Dahl Concept: past present and future. *Br Dent J* 2005;198(11):669–76.
21. Hemmings KW, Darbar UR, Vaughan S. Tooth wear treated with direct restorations at an increased vertical dimension: results at 30 months. *J Prosthet Dent* 2000;83:287–93.
22. Harley KE, Ibbetson RJ. Dental anomalies—are adhesive castings the solution? *Br Dent J* 1993;174:15–22.
23. Foreman PC. Resin-bonded acid-etched onlays in two cases of gross attrition. *Dent Update* 1988;15:150–3.
24. Vailati F, Belser UC. Full-mouth adhesive rehabilitation of a severely eroded dentition: the three-step technique. Part 1. *Eur J Esthet Dent* 2008;3(1):30–44.
25. Vailati F, Belser UC. Full-mouth adhesive rehabilitation of a severely eroded dentition: the three-step technique. Part 2. *Eur J Esthet Dent* 2009;3(2):128–46.
26. Vailati F, Belser UC. Full-mouth adhesive rehabilitation of a severely eroded dentition: the three-step technique. Part 3. *Eur J Esthet Dent* 2009;3(3):236–57.
27. Stumbaum M, Konec D, Schweiger J, Gernet W. Reconstruction of the vertical jaw relation using CAD/CAM. *Int J Comput Dent* 2010;13:9–25.

Reprint requests: Jan-Frederik Güth, Department of Prosthodontics, Dental School of the Ludwig-Maximilians University, Munich, Goethestrasse 70, 80336 Munich, Germany; Tel.: 0049 (0)89 1609576; Fax: 0049 (0)89 1609502; email: jan_frederik.gueth@med.uni-muenchen.de
 This article is accompanied by commentary, Treatment Concept with CAD/CAM-Fabricated High-Density Polymer Temporary Restorations, Dennis J. Fasbinder, DDS
 DOI 10.1111/j.1708-8240.2011.00497.x

Copyright of Journal of Esthetic & Restorative Dentistry is the property of Wiley-Blackwell and its content may not be copied or emailed to multiple sites or posted to a listserv without the copyright holder's express written permission. However, users may print, download, or email articles for individual use.