

A Contemporary Review of White Spot Lesions in Orthodontics

GAVIN C. HEYMANN, DDS, MS*, DAN GRAUER, DDS, PhD†

ABSTRACT

White spot lesions (WSL) associated with fixed orthodontic appliances are a common adverse effect of orthodontic treatment and represent a significant challenge to achieving esthetic excellence. The purpose of this article is to review the current evidence regarding diagnosis, risk assessment, prevention, intratreatment management, and postorthodontic treatment of WSL, and to provide clinical recommendations useful for both the orthodontist and the general dentist. Caries risk assessment should be incorporated into initial evaluations of orthodontic patients, and risk-specific prevention and management protocols can help to eliminate or minimize this clinical problem. There are multiple options for treatment of WSL, ranging from conservative to invasive techniques; the severity of lesions is a determinant of which option is most appropriate.

CLINICAL SIGNIFICANCE

White spot lesions associated with orthodontic treatment are a common problem that can be minimized with appropriate prevention, management, and treatment approaches.

(J Esthet Restor Dent 25:85–95, 2013)

Not all outcomes in orthodontics are positive. White spot lesions (WSL) are one of the most common adverse effects of orthodontic treatment and can have lasting negative effects on dental esthetics. WSL is a broad term that includes:

- Developmental enamel lesions (fluorosis, enamel hypoplasia, etc.)
- Localized areas of demineralization/caries in nonorthodontic patients
- Localized areas of demineralization/caries related to orthodontic appliances

The scope of this article is limited to WSL associated with orthodontic appliances. Such lesions are not distinct types of carious lesions; rather they are the

result of enamel demineralization as a stage of the carious process occurring around orthodontic fixed appliances. Fejerskov and Kidd defined WSL as the “first sign of a caries lesion on enamel that can be detected with the naked eye.”¹ The opaque, white, chalky appearance of WSL is due to an optical phenomenon caused by mineral loss in the surface and subsurface enamel, and is exaggerated by drying (Figure 1).² These lesions also tend to appear rough and porous compared with noncarious white spots that are generally smooth and shiny.¹ The purpose of this article is to review the current evidence regarding diagnosis, risk assessment, prevention, intratreatment management, and postorthodontic treatment of WSL, and to provide clinical recommendations useful for both the orthodontist and the general dentist. WSL

*Private practice, Chapel Hill and Durham, NC, USA

†Assistant Professor, University of Southern California and Private Practice, Los Angeles, CA, USA

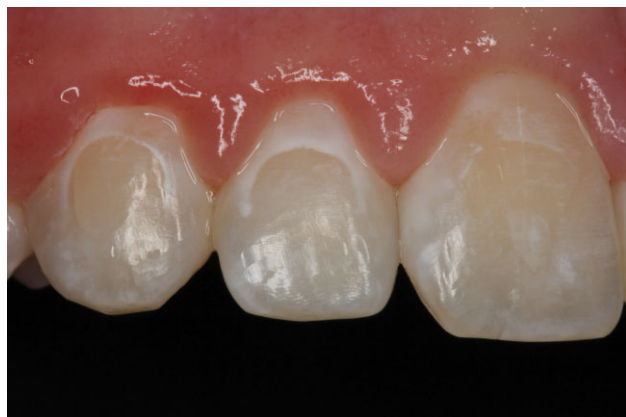

FIGURE 1. Orthodontic white spot lesions (WSL) on enamel surfaces; these were adjacent to labial fixed orthodontic appliances. The white, opaque appearance is due to change in the refractive index of the subsurface enamel.

caused by developmental or acquired conditions other than orthodontic fixed appliances are beyond the scope of this article.

EPIDEMIOLOGY

The prevalence of WSL has been reported to range from 2% to 96%.^{2–5} This wide range is likely due to the inconsistent operational definitions of a WSL among different studies. The sensitivity in the discrimination of a WSL depends on the method of detection. Studies employing quantitative light-induced fluorescence (QLF) report higher prevalence of lesions than studies where these lesions are defined by a visual inspection.⁶ It has been reported that the prevalence of WSL prior to orthodontic treatment ranges from 15.5% to 40%,^{2,7,8} whereas most studies report the incidence of new clinically visible WSL occurring during orthodontic treatment to range between 30% and 70% of patients.^{4,5,7,9–11} Maxillary anterior teeth are most commonly affected with the order of incidence being lateral incisors, canines, premolars, and central incisors^{2,7,12}; however, all teeth are potentially at risk. Risk factors for the development of WSL include: poor pretreatment and intratreatment oral hygiene, age (preadolescent at start of treatment), increased decayed, missing, or filled teeth, etching time and surface area, and caries/restorative status of first molars.^{10,12–15}

ETIOLOGY

Environment

Fixed orthodontic appliances create an increased challenge for excellent oral hygiene and provide greater surface area for adherence of plaque; the irregular shapes of the appliances also limit the self-cleansing ability of saliva, lips, tongue, and cheeks. These obstacles can lead to increased risk of incipient caries on dental surfaces not usually prone to carious attack. This phenomenon is well illustrated by the reduced incidence of WSL in orthodontic patients treated with lingual appliances, where the tongue and saliva flow are able to provide better self-cleansing of the tooth surfaces adjacent to the fixed appliances.¹⁶

Host

Not all individuals display the same caries risk. Caries progression is a dynamic process that is the result of an imbalance in the natural enamel demineralization/reminerization cycle. Enamel lesions can progress from initial demineralization to noncavitated carious lesions, to cavitated lesions.¹ One of the most clinically significant factors of WSL is the potential for rapid formation, with clinically visible lesions developing in as little as 4 weeks.⁵ Individual caries risk is multifactorial. It can be puzzling to see a patient with oral hygiene that appears to be acceptable still develop WSL, whereas one who has extremely poor hygiene may develop none. Individual host factors including salivary flow and composition, enamel solubility, immune response, genetic susceptibility, diet, and medication history are all important determinants of overall caries risk.

Cariogenic Bacteria

Acidogenic bacteria have long been identified as the primary causative agents in the caries process. Specifically, *Streptococcus mutans* and *Lactobacilli* are the primary microbial agents in the caries process. The types and numbers of bacteria in dental biofilms are not static. Closer evaluation of how pH influences the

ecological shift in dental biofilms is important to understanding the dynamic nature of the caries process. The microflora on healthy enamel is composed mostly of nonmutans streptococci, and acidification of the biofilm is mild and infrequent. However, frequent exposure to fermentable carbohydrates leads to more intense and frequent acidification of the biofilm. This in turn leads to the adaptive and selective modification of the biofilm to favor more acidogenic and aciduric strains of microflora. This negative modification of the biofilm leads to a shift in the demineralization/remineralization cycle toward a net mineral loss.¹⁷ It has been demonstrated that cariogenic bacteria are present in plaque at higher levels in orthodontic patients than in nonorthodontic patients, resulting in a caries progression that is more rapid than in patients without fixed appliances.¹⁸

DIAGNOSIS

Visual

The visual diagnosis of WSL may actually begin prior to the initiation of orthodontic treatment. Identification of existing nondevelopmental WSL prior to orthodontic treatment is an important part of the risk-assessment process. The presence of such lesions in a patient

without a history of orthodontic appliances should be noted in the dental history and automatically increases the risk category of the individual.

Intratreatment evaluation for WSL is important so that proper management approaches can be implemented as soon as a visual diagnosis has been made. It is easy to overlook early WSL unless arch wires, ligatures, elastomeric chains, or other auxiliaries are removed, and teeth are free of plaque and debris, and have been dried. The presence of gingival inflammation that reduces the amount of visible enamel between the bracket and gingival margin can also make it difficult to visualize WSL during treatment. For this reason, many WSL are not identified until after fixed appliances are removed. It is recommended that the orthodontist evaluate high-risk teeth at each visit in an attempt to identify lesions early, so as to more readily address lesions that have already been started (Figure 2).

QLF

QLF is a diagnostic method that relies on the autofluorescence of teeth when they are exposed to high-intensity blue light. The fluorescence of the tooth is closely related to the mineral content of the enamel, with demineralization showing less fluorescence.¹⁹ This relationship allows for the quantification of

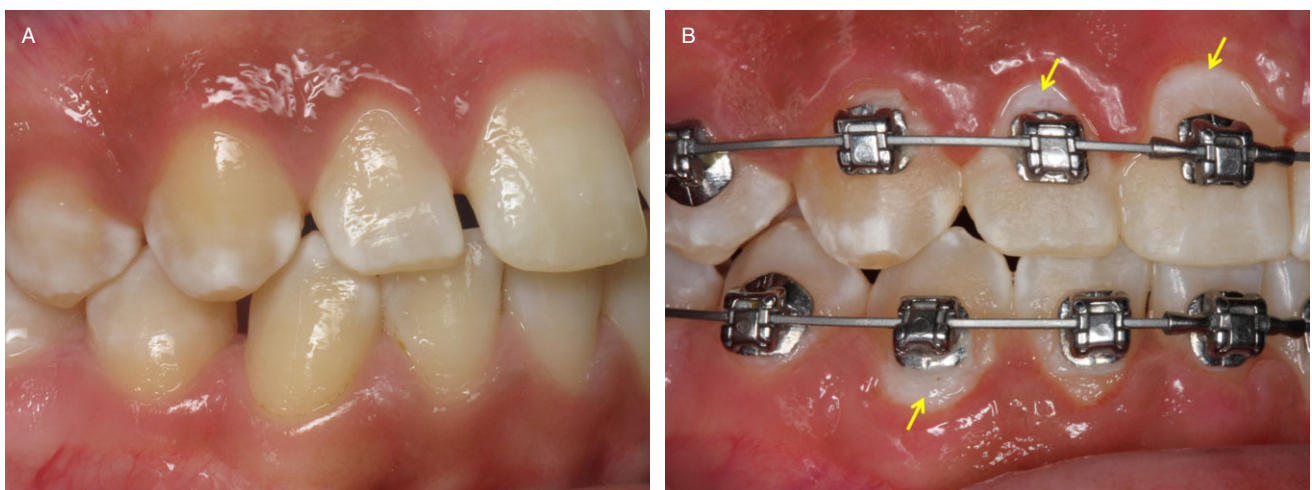


FIGURE 2. A, Pretreatment presentation of patient with developmental white spot lesions (WSL) and good oral hygiene. B, Intratreatment WSL in same patient—note suboptimal oral hygiene with plaque accumulation and gingival inflammation.

demineralization or remineralization at one time point or over time. QLF is a highly sensitive diagnostic test, but it has largely been limited to research applications and may not be practical for routine diagnosis of WSL in patients undergoing orthodontic treatment.

RISK ASSESSMENT

Before appliances are placed, a risk assessment should be performed, and patients should be classified into one of two groups: low risk or high risk. Because of the multifactorial nature of WSL, there is no single approach to risk determination. It is the authors' method to establish the risk group based on the detection of both protective and risk factors. If a patient presents two or more factors from the high-risk category, that individual will be classified as high risk. If a patient develops an intratreatment WSL, they will automatically be classified as high risk (Table 1).

PREVENTION

It has been documented that patients, parents, general dentists, and orthodontists perceive that the

TABLE 1. Risk assessment for development of white spot lesions (WSL)*

Low risk	High risk
No previous WSL	Existing WSL
Good oral hygiene	Poor oral hygiene
Low dietary sugar exposure	High dietary sugar exposure
Short treatment time	Long treatment time
Controlled etching	Excessive etching
Lingual appliances	Labial appliances
No/minimal DMFT	High DMFT score
No intratreatment lesion(s)	Intratreatment lesion(s)
DMFT = decayed, missing, or filled teeth. *If a patient presents two or more factors from the high-risk category, that individual will be classified as high risk. If a patient develops an intratreatment WSL, they will automatically be classified as high risk—no matter what their initial risk category was.	

responsibility for prevention of WSL lies with the patient.²⁰ However, the orthodontist and general dentist play an important role in identifying high-risk patients and directing them toward an appropriate preventive regimen. There are multiple approaches to preventing WSL, and a combination of all approaches may yield the greatest success in prevention (Table 2).

Disruption of Bacterial Biofilm

Given the high risk of WSL in patients who display poor oral hygiene prior to the initiation of orthodontic treatment, it is imperative that baseline plaque scores be improved to acceptable levels before appliance placement. Tooth brushing and flossing are more difficult and time consuming in patients with fixed appliances, so detailed oral hygiene instructions are crucial in educating patients how to maintain adequate home care. Particular focus should be placed on teaching patients to clean around each individual bracket—especially between brackets and gingival margins. Although not essential to maintaining excellent hygiene, electric toothbrushes may represent a benefit to patients who have higher plaque scores.²¹ In patients who have normal to low risk of developing WSL, an oral hygiene protocol that utilizes an initial prophylaxis, nutritional counseling, consistent oral hygiene instruction, patient education, and fluoridation is likely adequate to prevent demineralization. However, high-risk patients may benefit from a more involved hygiene protocol that should include more frequent prophylaxis (every 3 months rather than every 6 months), which includes scaling, irrigation of subgingival pockets with chlorhexidine, and fluoride application.¹⁵

Inhibition of Demineralization/Promotion of Remineralization

Fluoride Toothpastes

Whereas the efficacy of conventional fluoride toothpastes (1,000 ppm) has been widely reported, toothpastes with higher fluoride concentrations (1,500–5,000 ppm) have been shown to have greater ability to inhibit demineralization and promote remineralization.²² A modified fluoride toothpaste

TABLE 2. Measures for prevention, intratreatment management, and treatment of white spot lesions (WSL)

Prevention protocols		Intratreatment management (once WSL are noticed)	Postorthodontic treatment options for WSL
Normal/low risk	High risk (initial risk or poor compliance intratreatment)		
<ul style="list-style-type: none"> • Tooth brushing (modified technique) with 1,000-ppm fluoride toothpaste 2 to 3 times daily • Prophylaxis every 4 months • Fluoride varnish every 4 months • 0.5% NaF rinse daily at bedtime 	<ul style="list-style-type: none"> • Tooth brushing (modified technique 2–3 times daily): 5,000-ppm fluoride toothpaste before bedtime and 1,000-ppm all other times using mechanical brush • Prophylaxis every 3 months • Fluoride varnish every 3 months • Xylitol chewing gum 3 to 5 pieces per day for at least 10 minutes per chew • Chlorhexidine rinse (2-week regimen) 30-second rinse daily after brushing before bedtime 	<ul style="list-style-type: none"> • Tooth brushing (modified technique 2–3 times daily) with 5,000 ppm at bedtime and 1,000 ppm all other times • Prophylaxis every 3 months • Fluoride varnish every 3 months • MI Paste Plus (GC America, Alsip, IL, USA) application nightly after brushing teeth • Xylitol chewing gum 3 to 5 pieces per day for at least 10 minutes per chew • If above techniques have been utilized and still have progression of WSL and poor compliance, then proceed with EARLY APPLIANCE REMOVAL 	<ul style="list-style-type: none"> • No treatment/monitoring with natural resolution • Tooth whitening • Resin infiltration technique • Microabrasion/macroabrasion • Tooth preparation and restoration (direct resin or indirect veneers)

WSL = white spot lesion.

technique involving twice daily brushing for 2 minutes followed by vigorous swishing of the toothpaste slurry for 30 seconds without rinsing with water, and avoidance of eating or drinking for 2 hours, has also been shown to reduce the incidence of new caries in orthodontic patients.²³

Fluoride Rinses

Daily 0.5% sodium fluoride rinse in conjunction with fluoridated dentifrice is perhaps the most common fluoride regimen recommended by orthodontists.²⁴ This recommendation comes from research that shows this approach to significantly reduce caries rates in *nonorthodontic* adolescent patients; however, the evidence is weak and mixed with regard to efficacy of fluoride rinses in prevention of WSL in orthodontic patients. For fluoride rinses to be successful in prevention of WSL, they must be used consistently, and there is evidence to suggest that compliance with such rinses is poor.²⁵

Fluoride-Releasing Bonding Materials

Although there is some evidence, although weak, that glass ionomers (GIs) and resin-modified GIs may provide some resistance to WSL compared with acrylic-based composite resins, there are also studies that show no significant difference in the protective ability of the materials.²⁶ It has been documented that GIs exhibit an initial burst of fluoride release that rapidly diminishes to levels that are unlikely to have a clinically significant effect on caries inhibition. Although this approach certainly appears to have some promise, the evidence is inconclusive with regard to the efficacy of WSL prevention.

Fluoride Varnish

Fluoride varnish placed around orthodontic brackets during treatment has been shown to reduce the incidence and prevalence of WSL.²⁷ It is recommended that high-risk patients have topical application of fluoride varnish at least around anterior teeth—perhaps at every orthodontic adjustment appointment. One of the benefits of fluoride varnish is that it works in the presence of plaque; thorough cleaning of the tooth surfaces is not necessary prior to application of varnish. This approach represents a relatively simple way to

increase fluoride exposure to high-risk patients at more frequent intervals as are associated with regular orthodontic appointments.

Amorphous Calcium Phosphate (ACP)

Amorphous calcium phosphate (ACP) is thought to have the potential to both prevent and resolve enamel demineralization in patients with high caries risk. MI Paste (GC America, Alsip, IL, USA) is a product that contains casein phosphopeptide ACP, a milk-derived protein that helps to promote high rates of enamel remineralization. MI Paste Plus is the same product, but also contains 900 ppm of fluoride. A recent randomized controlled trial demonstrated that orthodontic patients who applied MI Paste Plus nightly via a fluoride delivery tray for 3 to 5 minutes following brushing showed fewer and less severe WSL than controls.²⁸

It has been suggested that ACP may aid in the remineralization of WSL after the completion of orthodontic treatment, although there is some evidence that shows no significant advantage for use of ACP supplementary to normal oral hygiene.^{29,30} That is, there was no significant difference in the reduction of WSL size between patients who used MI Paste and those who used regular oral hygiene including 1,000-ppm toothpaste.

Favorable Modification of Oral Environment

Diet

Although a nutritional assessment is not a common part of most orthodontists' initial evaluation and diagnosis, it may play a valuable role in the identification of patients at higher risk of developing WSL. The role of refined carbohydrates in the caries progression progress has been well documented, and simple diet evaluation and counseling may be useful ways to inform patients of the need to reduce exposure to refined carbohydrates—especially sugared beverages including soft drinks, sports drinks, and juices.³¹ These beverages not only serve as a source of fermentable sugars for cariogenic bacteria, but many are quite acidic as well. It has been demonstrated that enamel

demineralization begins to occur when the pH drops below 5.5, and the pH of some popular soft drinks and sports drinks are in the range of pH 2 to 3. Even diet soft drinks, although eliminating the presence of fermentable sugars, may have a pH below 3. The combination of high sugar content and low pH serve as extremely unfavorable modifiers of the oral environment with regard to potential for WSL development. Among fermentable carbohydrates, it appears that sucrose is the most problematic with regard to its ability to negatively affect dental biofilm. It has been shown that biofilms formed in the presence of sucrose have lower concentrations of Ca, P_i, and F, all of which are important ions for remineralization of enamel.³²

Modification of Biofilm pH

An increase in the pH of the oral environment and particularly the dental biofilm may be helpful in shifting the microflora toward less acidogenic and aciduric strains, and therefore reducing caries risk. Products such as Cavistat mints (Orettek Therapeutics, Inc., Roslyn, NY, USA) and Carifree rinses (Oral Bio Tech, Albany, OR, USA) attempt to favorably modify the biofilm by increasing pH.^{33,34} Although there is no published evidence of using this approach for the prevention of WSL, it would seem that potential exists for it to be a valuable adjunct in the management of high-risk patients.

Probiotics

The use of probiotics is relatively new to dentistry, but the concept involves populating the oral environment with noncariogenic microorganisms that compete with both cariogenic bacteria and periodontal pathogens, and reduce their numbers. Although there is a scarcity of data on this topic and none with specific application to WSL prevention, preliminary reports show potential for products such as ProBiora 3 (Oragenics, Tampa, FL, USA) to positively affect the oral environment by reducing *S. mutans* and certain periodontal pathogens.³⁵

Carbamide Peroxide

There is evidence that salivary and plaque pH are increased by urea, which is a component of carbamide

peroxide. This increase in pH along with the antimicrobial effect of hydrogen peroxide may suppress plaque formation.³⁶ Patient compliance with periodic use of carbamide peroxide whitening agents during orthodontic treatment may be enhanced because of the perceived added benefits of tooth whitening on the part of the patient. There is currently no published evidence of the use of carbamide peroxide products preventing WSL in orthodontic patients, but it would seem that this approach may have promising potential.

Xylitol

A polyol carbohydrate, xylitol is not metabolizable by *S. mutans* and is therefore noncariogenic. It also appears to have antimicrobial properties that help to prevent *S. mutans* attachment to tooth surfaces. It has been demonstrated that the use of xylitol chewing gum can reduce the risk of caries compared with gums containing sucrose or sorbitol, and chewing gum also has been shown to increase the production of stimulated saliva, which has higher phosphate and calcium concentrations than nonstimulated saliva.^{37–39} High-risk patients may benefit from chewing xylitol gum 3 to 5 times per day for a minimum of 10 minutes each, although this potential benefit must be weighed with the possibility for increased bracket bond failures associated with chewing gum.³⁸

Protective Barrier for Enamel

There are several products that are designed to bond to etched enamel and serve as a physical barrier to the acidic attack of enamel. There is some evidence to support that bonded resin barriers such as pit and fissure sealants may provide protection against the development of WSL.⁴⁰ Filled resin sealants such as Pro Seal (Reliance Orthodontic Products, Itasca, IL, USA) may have potential to provide even greater protection as a physical barrier because of their increased wear resistance compared with unfilled resin sealants, but their removal after orthodontic treatment can be tedious and requires the use of a high-speed rotary instrument.⁴¹

MANAGEMENT DURING TREATMENT (INTRATREATMENT ACTION PLAN ONCE INITIAL WSL ARE NOTICED)

It is common for orthodontists to have a prevention protocol that is applied to all orthodontic patients, but how should the clinician handle high caries risk patients, or those who develop noticeable WSL during treatment? The first step is to inform the patient and/or parent that WSL have been noticed, and explain the approaches that will be taken to prevent further damage (Table 2). Thorough documentation of these steps is recommended. A careful reevaluation of the risk factors and potential changes in lifestyle including diet should be reviewed to see if such changes may have contributed to the development of WSL. Continued reinforcement of oral hygiene instructions and more frequent recalls between regular adjustments are recommended so that the orthodontist can monitor for the progression of new lesions. A more rigorous fluoride regimen including the prescription of 5,000-ppm fluoride gel or toothpaste, and in-office application of fluoride varnish every 3 months or perhaps at every orthodontic visit should be adopted. In patients who have been noncompliant with other oral hygiene regimens, chlorhexidine rinses may be used in conjunction with a fluoride regimen to reduce the numbers of cariogenic pathogens and further inhibit demineralization.^{18,22} These rinses are recommended to be used in a 2-week regimen, with the patient swishing for 30 seconds prior to bedtime. As with all chlorhexidine products, there is a tendency for extrinsic staining of teeth, which patients should be informed of. MI Paste, MI Paste Plus, or similar products may also be used as part of a more intense regimen to increase remineralization. These products should be applied in a pea-sized amount around teeth and orthodontic appliances after brushing teeth. If traditional 1,000-ppm fluoride toothpaste is used, then MI Paste Plus is recommended, whereas MI Paste should be used if 5,000-ppm fluoride gels or pastes are used.

Early Removal of Appliances

When all appropriate preventive and management measures have been attempted and patients still fail to

improve their home care, or the progression of WSL is evident, the orthodontist must use good judgment in deciding when fixed appliances should be removed ahead of schedule. If WSL are developing in the middle of treatment despite all efforts to prevent and manage them, then removing all barriers to improved home care should become a priority—even if the orthodontic goals have yet to be completely achieved. Patients should be informed that in these case scenarios, further risk of enamel damage outweighs the reward of continuing with orthodontic treatment at this time. Patients may be placed in retention and advised that when motivation to maintain excellent home care improves, they can resume orthodontic treatment.

TREATMENT OF THE LESIONS (POSTORTHODONTICS)

Once orthodontic appliances are removed and WSL exist, the orthodontist must inform the patient of the available treatment options. There are multiple options that range from very conservative (natural resolution) to more invasive (tooth preparation and restoration) (Table 2). The determination of the severity of WSL may be helpful in planning which treatment is most appropriate. A system for quantifying the severity of clinically visible WSL based on their surface area and presence or absence of cavitation was developed by Gorelick,² but a recent study suggests that the color or intensity of the WSL may be a better predictor of the actual depth of the lesion than surface area alone.⁴²

Natural Resolution/Remineralization

Visible WSL that exist after completion of orthodontic treatment tend to decrease in area and improve in their appearance over the first 1 to 2 years after debonding.^{43–45} The status of the lesions largely determines the potential for improvement, with active lesions having a better prognosis than arrested lesions. Active lesions are more porous and allow for easier infiltration of calcium and phosphorous into the enamel during the remineralization process, whereas arrested lesions often appear shiny white and may even have a brown surface appearance due to the formation of a

remineralized layer in the outer part of the enamel. Although high-concentration fluorides are important for prevention, their use on active WSL may arrest the lesions and actually lead to the staining of the enamel. Most WSL that exist after orthodontic treatment have already undergone a demineralization and remineralization cycle, so even if some of the lesions are active at the end of treatment, it is likely that there has already been some remineralization as well.

Resin Infiltration

Resin infiltration of incipient carious lesions is a relatively new approach that shows potential to improve the appearance of WSL. The white, opaque appearance of WSL is the result of an optical phenomenon that is due to the difference between the refractory index of healthy enamel and that of demineralized enamel, which is left with voids filled by water or air. The idea behind resin infiltration is that the porous nature of active WSL allows a low-viscosity resin to permeate into the previously demineralized enamel matrix and fill in many of the voids with resin rather than air or water. This creates a refractory index that is more similar to healthy enamel, and the result is an improvement in appearance of the lesion. Icon (DMG America, Englewood, NJ, USA) is currently the only product on the market that uses this approach. The clinical protocol involves etching of WSL with 15% hydrochloric acid for 2 minutes under rubber dam isolation, followed by thorough rinsing, desiccation of the enamel lesion with an ethanol drying agent, and then the application of the very low-viscosity resin, removal of gross excess, and light-curing for 40 seconds. This approach appears to be more successful in lesions that have not been completely arrested. Although data on the efficacy of this technique are limited to date, early studies show this technique to be successful in improving or completely masking WSL (Figure 3).^{46,47}

Whitening

Vital bleaching of teeth with inactive WSL is a commonly suggested approach to improving the

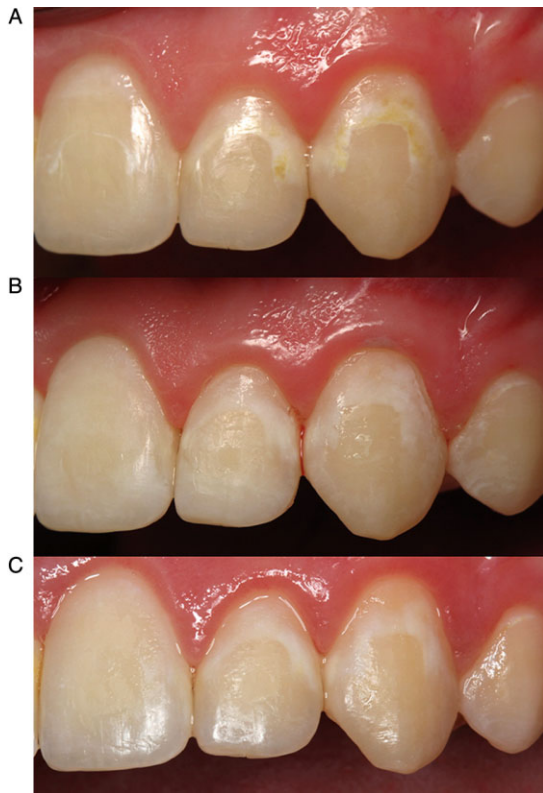


FIGURE 3. A, Multiple white spot lesions (WSL) in a patient after removal of fixed appliances and immediately prior to resin infiltration procedure. B, Immediately following resin infiltration procedure—note that teeth are still partially dehydrated. C, Two months following resin infiltration procedure—note improvement, yet incomplete resolution of WSL.

appearance of affected teeth, but does it work? It has been demonstrated that whitening can be successful, but both the WSL and unaffected enamel become lighter. The good news is that unaffected enamel appears to increase in lightness significantly more than the WSL, which may often result in less contrast between the lesion and the surrounding unaffected enamel.¹⁴

Microabrasion

WSL of a developmental origin as well as those related to orthodontic treatment have been successfully treated with microabrasion. This technique involves using a slurry of pumice or silicon carbide particles and hydrochloric acid to create surface dissolution of

enamel, and is effective in removing superficial stains or defects.⁴⁸ Successful removal of WSL by this technique is possible if the lesion does not exceed 0.2 to 0.3 mm in depth.⁴⁹

Resin Restorations/Indirect Restorations

Patients with cavitated lesions, or more severe WSL who have already attempted more conservative esthetic treatments without significant improvement may benefit from the preparation of the affected tooth surfaces and restoration with either direct resin restorations or indirect porcelain restorations.

CONCLUSION

WSL represent a significant challenge to excellence in clinical orthodontics. The risk-assessment methods and recommendations for prevention and intratreatment management of WSL outlined in this review may help to minimize this common problem in your patients; however, no matter how hard we strive, it is unlikely that we can completely eliminate this problem. For this reason, it is imperative for both orthodontists and general practitioners to have consistent protocols for caries risk assessment, prevention, intratreatment management, and treatment of WSL. Clinicians should take care to include discussion of WSL risk as part of any orthodontic informed consent process, and thorough documentation of preventive measures, as well as assessment of compliance with oral hygiene is essential.

DISCLOSURE AND ACKNOWLEDGEMENTS

The authors do not have any financial interest in any of the companies whose products are included in this review.

REFERENCES

1. Fejerskov ONB, Kidd E. Dental caries: the disease and its clinical management. 2nd ed. Copenhagen: Blackwell Munksgaard; 2003.

2. Gorelick L, Geiger AM, Gwinnett AJ. Incidence of white spot formation after bonding and banding. *Am J Orthod* 1982;81(2):93–8.
3. Mitchell L. Decalcification during orthodontic treatment with fixed appliances—an overview. *Br J Orthod* 1992;19(3):199–205.
4. Mizrahi E. Enamel demineralization following orthodontic treatment. *Am J Orthod* 1982;82(1):62–7.
5. Ogaard B, Rolla G, Arends J, ten Cate JM. Orthodontic appliances and enamel demineralization. Part 2. Prevention and treatment of lesions. *Am J Orthod Dentofacial Orthop* 1988;94(2):123–8.
6. Boersma JG, van der Veen MH, Lagerweij MD, et al. Caries prevalence measured with QLF after treatment with fixed orthodontic appliances: influencing factors. *Caries Res* 2005;39(1):41–7.
7. Artun J, Brobakken BO. Prevalence of carious white spots after orthodontic treatment with multibonded appliances. *Eur J Orthod* 1986;8(4):229–34.
8. Lovrov S, Hertrich K, Hirschfelder U. Enamel demineralization during fixed orthodontic treatment—incidence and correlation to various oral-hygiene parameters. *J Orofac Orthop* 2007;68(5):353–63.
9. Enaia M, Bock N, Ruf S. White-spot lesions during multibracket appliance treatment: a challenge for clinical excellence. *Am J Orthod Dentofacial Orthop* 2011;140(1):e17–24.
10. Richter AE, Arruda AO, Peters MC, Sohn W. Incidence of caries lesions among patients treated with comprehensive orthodontics. *Am J Orthod Dentofacial Orthop* 2011;139(5):657–64.
11. Tufekci E, Dixon JS, Gunsolley JC, Lindauer SJ. Prevalence of white spot lesions during orthodontic treatment with fixed appliances. *Angle Orthod* 2011;81(2):206–10.
12. Chapman JA, Roberts WE, Eckert GJ, et al. Risk factors for incidence and severity of white spot lesions during treatment with fixed orthodontic appliances. *Am J Orthod Dentofacial Orthop* 2010;138(2):188–94.
13. Al Maaitah EF, Adeyemi AA, Higham SM, et al. Factors affecting demineralization during orthodontic treatment: a post-hoc analysis of RCT recruits. *Am J Orthod Dentofacial Orthop* 2011;139(2):181–91.
14. Knosel M, Bojes M, Jung K, Ziebolz D. Increased susceptibility for white spot lesions by surplus orthodontic etching exceeding bracket base area. *Am J Orthod Dentofacial Orthop* 2012;141(5):574–82.
15. Zimmer BW, Rottwinkel Y. Assessing patient-specific decalcification risk in fixed orthodontic treatment and its impact on prophylactic procedures. *Am J Orthod Dentofacial Orthop* 2004;126(3):318–24.
16. van der Veen MH, Attin R, Schwestka-Polly R, Wiechmann D. Caries outcomes after orthodontic treatment with fixed appliances: do lingual brackets make a difference? *Eur J Oral Sci* 2010;118(3):298–303.
17. Takahashi N, Nyvad B. The role of bacteria in the caries process: ecological perspectives. *J Dent Res* 2011;90(3):294–303.
18. Lundstrom F, Krasse B. Caries incidence in orthodontic patients with high levels of *Streptococcus mutans*. *Eur J Orthod* 1987;9(2):117–21.
19. Heinrich-Weltzien R, Kuhnisch J, van der Veen M, et al. Quantitative light-induced fluorescence (QLF)—a potential method for the dental practitioner. *Quintessence Int* 2003;34(3):181–8.
20. Maxfield BJ, Hamdan AM, Tufekci E, et al. Development of white spot lesions during orthodontic treatment: perceptions of patients, parents, orthodontists, and general dentists. *Am J Orthod Dentofacial Orthop* 2012;141(3):337–44.
21. Heintze SD, Jost-Brinkmann PG, Loundos J. Effectiveness of three different types of electric toothbrushes compared with a manual technique in orthodontic patients. *Am J Orthod Dentofacial Orthop* 1996;110(6):630–8.
22. Derks A, Katsaros C, Frencken JE, et al. Caries-inhibiting effect of preventive measures during orthodontic treatment with fixed appliances. A systematic review. *Caries Res* 2004;38(5):413–20.
23. Al Mulla AH, Kharsa SA, Birkhed D. Modified fluoride toothpaste technique reduces caries in orthodontic patients: a longitudinal, randomized clinical trial. *Am J Orthod Dentofacial Orthop* 2010;138(3):285–91.
24. Derks A, Kuijpers-Jagtman AM, Frencken JE, et al. Caries preventive measures used in orthodontic practices: an evidence-based decision? *Am J Orthod Dentofacial Orthop* 2007;132(2):165–70.
25. Geiger AM, Gorelick L, Gwinnett AJ, Benson BJ. Reducing white spot lesions in orthodontic populations with fluoride rinsing. *Am J Orthod Dentofacial Orthop* 1992;101(5):403–7.
26. Benson PE, Parkin N, Millett DT, et al. Fluorides for the prevention of white spots on teeth during fixed brace treatment. *Cochrane Database Syst Rev* 2004;(3) CD003809.
27. Steckslen-Blicks C, Renfors G, Oscarson ND, et al. Caries-preventive effectiveness of a fluoride varnish: a randomized controlled trial in adolescents with fixed orthodontic appliances. *Caries Res* 2007;41(6):455–9.
28. Robertson MA, Kau CH, English JD, et al. MI Paste Plus to prevent demineralization in orthodontic patients: a prospective randomized controlled trial. *Am J Orthod Dentofacial Orthop* 2011;140(5):660–8.
29. Beerens MW, van der Veen MH, van Beek H, ten Cate JM. Effects of casein phosphopeptide amorphous calcium

- fluoride phosphate paste on white spot lesions and dental plaque after orthodontic treatment: a 3-month follow-up. *Eur J Oral Sci* 2010;118(6):610–7.
30. Brochner A, Christensen C, Kristensen B, et al. Treatment of post-orthodontic white spot lesions with casein phosphopeptide-stabilised amorphous calcium phosphate. *Clin Oral Investig* 2011;15(3):369–73.
 31. Marshall TA. Chairside diet assessment of caries risk. *J Am Dent Assoc* 2009;140(6):670–4.
 32. Paes Leme AF, Koo H, Bellato CM, et al. The role of sucrose in cariogenic dental biofilm formation—new insight. *J Dent Res* 2006;85(10):878–87.
 33. Acevedo AM, Montero M, Rojas-Sanchez F, et al. Clinical evaluation of the ability of CaviStat in a mint confection to inhibit the development of dental caries in children. *J Clin Dent* 2008;19(1):1–8.
 34. Nascimento MM, Gordan VV, Garvan CW, et al. Correlations of oral bacterial arginine and urea catabolism with caries experience. *Oral Microbiol Immunol* 2009;24(2):89–95.
 35. Zahradnik RT, Magnusson I, Walker C, et al. Preliminary assessment of safety and effectiveness in humans of ProBiora3, a probiotic mouthwash. *J Appl Microbiol* 2009;107(2):682–90.
 36. Lazarchik DA, Haywood VB. Use of tray-applied 10 percent carbamide peroxide gels for improving oral health in patients with special-care needs. *J Am Dent Assoc* 2010;141(6):639–46.
 37. Dawes C, Macpherson LM. Effects of nine different chewing-gums and lozenges on salivary flow rate and pH. *Caries Res* 1992;26(3):176–82.
 38. Isokangas P, Alanen P, Tiekso J, Makinen KK. Xylitol chewing gum in caries prevention: a field study in children. *J Am Dent Assoc* 1988;117(2):315–20.
 39. Makinen KK, Bennett CA, Hujoel PP, et al. Xylitol chewing gums and caries rates: a 40-month cohort study. *J Dent Res* 1995;74(12):1904–13.
 40. Benham AW, Campbell PM, Buschang PH. Effectiveness of pit and fissure sealants in reducing white spot lesions during orthodontic treatment. A pilot study. *Angle Orthod* 2009;79(2):338–45.
 41. Buren JL, Staley RN, Wefel J, Qian F. Inhibition of enamel demineralization by an enamel sealant, Pro Seal: an in-vitro study. *Am J Orthod Dentofacial Orthop* 2008;133(4 Suppl.):S88–94.
 42. Torlakovic L, Olsen I, Petzold C, et al. Clinical color intensity of white spot lesions might be a better predictor of enamel demineralization depth than traditional clinical grading. *Am J Orthod Dentofacial Orthop* 2012;142(2):191–8.
 43. Al-Khateeb S, Forsberg CM, de Josselin de Jong E, Angmar-Mansson B. A longitudinal laser fluorescence study of white spot lesions in orthodontic patients. *Am J Orthod Dentofacial Orthop* 1998;113(6):595–602.
 44. Mattousch TJ, van der Veen MH, Zentner A. Caries lesions after orthodontic treatment followed by quantitative light-induced fluorescence: a 2-year follow-up. *Eur J Orthod* 2007;29(3):294–8.
 45. Ogaard B. Prevalence of white spot lesions in 19-year-olds: a study on untreated and orthodontically treated persons 5 years after treatment. *Am J Orthod Dentofacial Orthop* 1989;96(5):423–7.
 46. Kim S, Kim EY, Jeong TS, Kim JW. The evaluation of resin infiltration for masking labial enamel white spot lesions. *Int J Paediatr Dent* 2011;21(4):241–8.
 47. Neuhaus KW, Graf M, Lussi A, Katsaros C. Late infiltration of post-orthodontic white spot lesions. *J Orofac Orthop* 2010;71(6):442–7.
 48. Croll TP. Enamel microabrasion for removal of superficial dysmineralization and decalcification defects. *J Am Dent Assoc* 1990;120(4):411–5.
 49. Heymann HO, Swift EJ, Ritter AV. *Sturdevant's art and science of operative dentistry*. 6th ed. St. Louis: Elsevier; 2013.

Reprint requests: Gavin C. Heymann, DDS, MS, 3206 Old Chapel Hill Rd., Durham, NC 27707, USA; email: heymanng@gmail.com

Copyright of Journal of Esthetic & Restorative Dentistry is the property of Wiley-Blackwell and its content may not be copied or emailed to multiple sites or posted to a listserv without the copyright holder's express written permission. However, users may print, download, or email articles for individual use.