

Malignant transformation in 1458 patients with potentially malignant oral mucosal disorders: a follow-up study based in a Taiwanese hospital

Shue-Sang Hsue¹, Wen-Chen Wang¹, Chung-Ho Chen², Cheng-Chung Lin¹, Yuk-Kwan Chen¹, Li-Min Lin¹

Departments of ¹Oral Pathology and ²Oral & Maxillofacial Surgery, School of Dentistry, College of Dental Medicine, Kaohsiung Medical University, Kaohsiung Medical University Hospital, Kaohsiung, Taiwan

BACKGROUND: It is generally accepted that the development of cancer in the oral mucosa is preceded by an identifiable non-invasive precursor lesion. The aim of this follow-up study was to estimate the rate and the time to transformation in a group of patients from southern Taiwan with potentially malignant oral epithelial lesions.

METHODS: The follow-up time is defined as the duration between the onset of the initial diagnosis and the occurrence of confirmed oral cancer. A total of 1458 patients with histological diagnoses of various pre-malignant oral lesions were followed up between 1991 and 2001. The average age at initial diagnosis was 47.5 years. The histological diagnoses were divided into six categories: epithelial dysplasia with hyperkeratosis/epithelial hyperplasia (8.85%); epithelial dysplasia with submucous fibrosis (2.54%); submucous fibrosis (27.57%); hyperkeratosis/epithelial hyperplasia (29.01%); lichen planus (9.80%) and verrucous hyperplasia (22.22%).

RESULTS: Within the cohort of 1458 patients, 44 patients progressed to oral cancer in the same site as the initial lesions with an overall transformation rate of 3.02% and a mean follow-up time of 42.64 months. Eight of the 166 patients with dysplastic lesions and 15 of 423 patients with hyperkeratosis/epithelial hyperplasia progressed to malignancy. The other patients with malignant transformation originated from various pre-cancerous oral lesions and conditions (submucous fibrosis, eight of 402; lichen planus, three of 143; verrucous hyperplasia, 10 of 324).

CONCLUSION: These results indicate that patients with pre-malignant oral lesions need long-term follow up.

J Oral Pathol Med (2007) 36: 25–9

Keywords: epithelial hyperplasia; hyperkeratosis; malignant transformation; oral epithelial dysplasia; oral squamous cell carcinoma; submucous fibrosis; verrucous hyperplasia

Introduction

It is generally accepted that cancer development in the oral mucosa may be preceded by an identifiable but non-invasive precursor lesion. However, it is still uncertain how many oral squamous cell carcinomas (OSCC) arise from precursor lesions and how many develop from apparently normal oral mucosa. Previous studies have shown that between 16% and 62% of OSCC are associated with oral leukoplakia, the best known oral pre-cancerous lesion (1). Furthermore, OSCC can also arise from other pre-cancerous oral lesions and conditions, such as verrucous hyperplasia (2), submucous fibrosis (3) and lichen planus (4). Oral epithelial dysplasia, not associated with any specific clinical appearance, is a term assigned to the histopathological changes associated with increased risk of malignant transformation. The presence of epithelial dysplasia is generally regarded as one of the most important predictors of malignant transformation in pre-malignant lesions (1).

To our knowledge, the rate and duration of malignant transformation in these pre-cancerous oral lesions have not been comprehensively examined in Taiwan. The aim of this study was to estimate the incidence and time to malignant transformation in a group of patients with potentially malignant oral epithelial lesions in southern Taiwan.

Materials and methods

The present follow-up study was based on histopathological records derived from oral biopsy specimens between the first of January 1991 and the end of December 2001 in the Department of Oral Pathology, Kaohsiung Medical University. Data sets were established

Correspondence: Dr Yuk-Kwan Chen, Oral Pathology Department, School of Dentistry, Kaohsiung Medical University, 100 Shih-Chuan 1st Road, Kaohsiung, Taiwan. Tel: +886 7 3121107 (ext 7007), Fax: +886 7 3210637, E-mail: k0285@ms22.hinet.net
Accepted for publication August 14, 2006

for oral epithelial dysplastic lesions, and other oral pre-cancerous lesions and conditions including submucous fibrosis, verrucous hyperplasia and lichen planus. The histopathological characteristics of epithelial dysplasia include: (i) basal layer hyperplasia; (ii) nuclear enlargement and hyperchromatism; (iii) loss of intercellular adhesion and normal polarization; (iv) abnormal mitoses above the basal cell layer; (v) individual cell keratinization within the spinous layer; (vi) cellular pleomorphism; (vii) drop-shaped epithelial ridges; (viii) irregular stratification and (ix) altered nuclear-cytoplasmic ratio (5). From these histological changes, the presence of basal cell hyperplasia, nuclear enlargement and hyperchromatism and drop-shaped rete-ridges are regarded as the minimal criteria for the histological diagnosis of epithelial dysplasia (6). Diagnosis was successfully achieved and the degrees of dysplasia were graded with reference to the following criteria (7): (i) mild epithelial dysplasia – dysplastic alterations confined to the lower third of the buccal epithelium; (ii) moderate epithelial dysplasia – dysplastic changes observed for up to two-thirds of the thickness of the buccal epithelium and (iii) severe dysplasia – dysplastic cells found within more than two-thirds but less than the whole thickness of the buccal epithelium. Hyperplastic and hyperkeratotic epithelial lesions were also included for clinical reasons because they should be considered to have significant malignant potential. This is because leukoplakia is most commonly associated with clinical diagnosis of epithelial hyperplasia/hyperkeratosis, the best known oral pre-malignant lesion (1). Initially, there are no signs of dysplasia in lichen planus lesions. All of the histological diagnoses in this study were confirmed and agreed between the two board-certified oral pathologists (Drs L. M. Lin and C. C. Lin). In order to establish which of the selected patients with potentially malignant oral epithelial lesions would actually progress to develop oral cancer, periodical follow-up assessments were arranged for all patients with a frequency based on the clinical features and the need for therapy. In general, patients were seen at least once a year and all the patients within the data sets were followed until 30 June 2001. Whenever malignant transformation was suspected, an incisional biopsy was performed. The transformation time to malignancy is defined as the time between the onset of initial diagnosis and the progression to confirmed oral cancer.

The data sets were verified in the cancer registry database of our hospital. The cancer registry committee in our hospital will check for those cases lost to follow up. Cases, which were lost to follow up, will check for whether there is malignant transformation with respect to medical charts or cancer registry database in the Department of Health, The Executive Yuan, Taiwan at the end of the study.

Two criteria must be fulfilled to diagnose a progression to oral cancer. The first is that the potential oral cancer must develop in the same site as the initial lesion. The second is that the time taken for this progression must exceed 6 months. This latency time is designed to exclude the possibility of concomitant presentations.

Consequently, these strict criteria could identify those patients that had lesions, which had undergone malignant transformation, as well as the time to malignant transformation. Equally, the incidence of patients with an immediate diagnosis of OSCC was also recorded for the same time period.

Results

According to the aforementioned selection criteria, over the 10-year period a total of 1458 patients (1291 male; 167 female) were recruited into the study. The average age of onset at initial diagnosis was 47.5 years (range: 17–86). All of these patients (with the exception of patients with lichen planus) were betel-quid chewers, and also drank alcohol and smoked cigarettes.

Of the 166 patients with dysplastic lesions, 138 patients had mild epithelial dysplasia, whereas 15 patients had moderate and 13 had severe epithelial dysplasia. In addition, amongst these 166 patients with epithelial dysplasia, 129 patients were combined with hyperkeratosis/epithelial hyperplasia and 37 patients with submucous fibrosis. In this way, the 1458 patients were divided into six categories: epithelial dysplasia with submucous fibrosis (2.54%), epithelial dysplasia with epithelial hyperplasia/hyperkeratosis (8.85%), submucous fibrosis (27.57%), lichen planus (9.80%), verrucous hyperplasia (22.22%) and hyperkeratosis/epithelial hyperplasia (29.01%). The buccal mucosa was the most common site for a lesion to develop (occurring in 68.93% of the patients), followed by the tongue dorsum (11.52%) and lower lip (7.06%).

During the same period, we identified 474 patients (447 male; 27 female) who had an initial diagnosis of OSCC (well differentiated: 402, 84.81%; moderately differentiated: 54, 11.39%; poorly differentiated: 18, 3.79%), with an average age of 51.4 years (range: 27–82).

Amongst these 1458 patients with various potentially malignant oral epithelial lesions, 44 patients (38 male; six female; average age 52 years; range: 32–70) were found to progress to oral carcinoma proper (41 OSCC; three verrucous carcinoma). This gives an overall transformation rate of 3.02% and a mean time for transformation of 42.6 months (Table 1). The annual transformation rate is illustrated in Fig. 1 and Table 2.

The majority of these 41 patients with lesions that transformed to OSCC were well differentiated ($n = 32$, 78.05%); the remaining nine patients (19.5%) were moderately differentiated. Eight of the 166 patients with dysplastic lesions (4.82%) were found to have transformation to OSCC (six mild epithelial dysplasia, two moderate epithelial dysplasia). Significantly, 15 of 423 patients (3.55%) with histologically innocent hyperkeratosis/epithelial hyperplasia were found to transform to oral cancer (14 OSCC, one verrucous carcinoma). For those 10 in 324 patients (3.09%) with verrucous hyperplasia that progressed to oral cancers, eight were OSCC and two were verrucous carcinoma. The remaining 11 patients with malignant transformation to OSCC were derived from submucous fibrosis, eight of 402 (1.9%); and lichen planus, three of 143 (2.10%; Table 1).

Table 1 Number, rate and mean time to malignant transformation in the 44 potentially malignant oral epithelial lesions with different histological diagnoses

Histological diagnosis	Number of transformation	Rate of transformation	Mean duration of transformation (months)
Epithelial dysplasia with submucous fibrosis	2 ^c	2/37 (5.4%)	40.0
Epithelial dysplasia with hyperkeratosis or epithelial hyperplasia	6 ^c	6/129 (4.65%)	28.2
Submucous fibrosis	8	8/402 (1.9%)	52.3
Lichen planus	3	3/143 (2.10%)	14.7
Verrucous hyperplasia	10 ^a	10/324 (3.09%)	54.6
Hyperkeratosis or epithelial hyperplasia	15 ^b	15/423 (3.55%)	41.3
Overall	44	44/1458 (3.02%)	42.6

^aTwo were verrucous carcinoma.

^bOne was verrucous carcinoma.

^cOne was moderate epithelial dysplasia with different histological diagnoses.

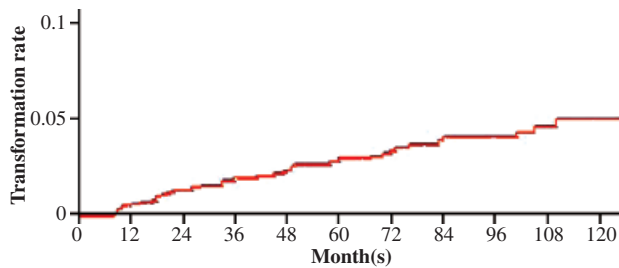


Figure 1 The annual malignant transformation rate of this study.

Table 2 Annual malignant transformation rate (Kaplan–Meier estimates) of this study

Time (year)	Transformation rate	Standard error	95% confidence interval	
			Lower	Upper
1	0.00490	0.00152	0.00267	0.00899
2	0.01027	0.00235	0.00655	0.01605
3	0.01580	0.00298	0.01091	0.02283
4	0.02144	0.00357	0.01545	0.02967
5	0.02714	0.0042	0.02002	0.0367
6	0.03289	0.00491	0.02452	0.04399
7	0.03868	0.00572	0.0289	0.05159
8	0.04449	0.00664	0.03315	0.05947
9	0.05031	0.00766	0.03726	0.06762
10	0.05615	0.00877	0.04124	0.07602

The mean time to malignant transformation in lesions with epithelial dysplasia was shorter than those without epithelial dysplasia; however, this difference was not statistically significant ($P = 0.34$, log-rank test). The transformation rate was not significantly associated with epithelial dysplasia ($P = 0.21$, log-rank test).

Discussion

There are two critical parameters needed to assess the potential for malignant transformation in oral epithelial lesions: the initial (pre-malignant) histopathological diagnosis and the time it has been *in situ*. All of the potentially pre-malignant oral lesions included in the present study have been studied histologically. Furthermore, subsequent progression to oral cancer must occur

at least 6 months later and also must develop in the same site as the original biopsy. Overall, approximately 3% of the potentially malignant oral epithelial lesions in this study progressed to oral cancer (Table 1). This proportion is low compared with other studies based on the clinical diagnosis of leukoplakia (8, 9). This may be due to the fact that this study contained a much wider range of oral pre-malignant epithelial lesions and conditions, and thus would not be easy to compare with studies based solely on the clinical diagnosis of leukoplakia (8, 9). Alternatively, it may be because this study is derived from hospital-based biopsy results. Furthermore, these results may be affected by patients failing to attend appointments, or clinicians to diagnose those that did. The former is a more likely explanation in Taiwan, because many people still rely solely on Traditional Chinese Medicine in these instances. Finally, strict inclusion criteria in this study may also lead to a lower incidence.

During the same follow-up period, a total of 474 patients were diagnosed with OSCC from the initial biopsy. Therefore, the percentage of the cases known to have progressed to carcinoma as a proportion of the latter OSCC group is about 10% (44 of 474, 9.28%). This figure is higher than the value (6%) from a similar biopsy-based follow-up study in Northern Ireland (10). This difference may reflect a geographic difference or because a greater variety of pre-malignant lesions and conditions (such as verrucous hyperplasia and submucous fibrosis) were included in our study. On the other hand, the age of patients in our present study who later progressed to oral cancer were comparable with those who did not; average age 51.95 years (range: 32–70) and 51.38 years (range: 27–82), respectively. Analysis of gender revealed a male predominance in cases of progression to oral cancer and cases of OSCC in the initial biopsy, reflecting the predominantly male habit of betel-quid chewing in the Taiwanese population (11).

Epithelial dysplasia is considered to be a critical factor in determining malignant potential. The presence of moderate or severe dysplasia has been accepted to have the greatest likelihood for malignant transformation, although it is also known that progression to cancer is not inevitable (12–14). In this study, only eight of the 166 patients with dysplastic lesions (4.82%) were

identified to become malignant, and none of the cases of severe epithelial dysplasia transformed during our follow-up period. This figure is low compared with a similar study in an Irish population (14%; 10). This may be because the majority of our dysplastic lesions belong to the mild category (83.13%), which is thought to have a relatively lower malignant transformation potential. However, it should be noticed that the follow-up period in these cases with severe epithelial dysplasia in our study were all limited to 1 year. Consequently, there may be a possibility that lesions were removed before malignant transformation occurred.

The percentage of malignant transformation in the categories of submucous fibrosis, lichen planus, verrucous hyperplasia and hyperkeratosis/epithelial hyperplasia was approximately 2–3%, whilst the values in the two dysplastic categories were higher, at about 5%. This is consistent with the view that the presence of dysplasia is an important predictor of malignant transformation. Unfortunately, the sample numbers in some categories are too small for statistical analysis.

In our study, 15 patients (3.55%) with histologically innocent hyperkeratosis/epithelial hyperplasia transformed to oral cancer, in a mean time of 41.27 months. This demonstrates that the matter is further complicated because lesions that are not dysplastic may become malignant. Therefore, conventional clinical and histopathological information may be insufficient to base decisions on the risk of malignancy in a particular lesion. Our understanding of the molecular biology of oral pre-cancer and cancer has increased dramatically and may, in the future, supplement clinical and histopathological parameters in evaluating clinical outcomes.

Submucous fibrosis and lichen planus are two examples of pre-cancerous conditions (1, 3, 4). In the present study, eight of the 402 patients (1.9%) with submucous fibrosis progressed to OSCC over an average time course of 52.25 months. To our knowledge, this is the first study that estimates the risk and duration of transformation of submucous fibrosis in the Chinese population in Taiwan. Our figure is lower than a previous study conducted in an Indian population, in which 66 patients with submucous fibrosis were followed up for a period of 17 years, and OSCC developed in five patients (7.6%; 15). This may reflect a much larger sample size, as well as the implementation of strict selection criteria in this study. For lichen planus, three of the 143 patients (2.10%) in the present study progressed to OSCC with a mean time to malignant transformation in 14.67 months. This data are similar to a recent study in an Italian population where nine of the 402 patients (2.24%) with lichen planus developed oral cancer (eight OSCC and one verrucous carcinoma), but only three were found in the same site as the initial biopsy (16). This data are, on the other hand, slightly higher than the three other studies reported in Danish, American and Greek populations (1.5%, 1.2% and 1.3%, respectively; 17–19). Verrucous hyperplasia has been regarded as a pre-cancerous lesion. In the present study, 10 of the 324 patients (3.09%) with verrucous hyperplasia were found to progress to oral cancer, in an

average time of 54.6 months. To our knowledge, this may be the first study that estimates the rate and time to transformation of verrucous hyperplasia in a large Chinese population in Taiwan.

In this study, the cases with proven progression to malignancy had an average interval to transformation of 42.64 months (Table 1), similar to other work from different countries (9, 10, 12). It is particularly noteworthy that lichen planus had the shortest mean time to transformation, compared with the other categories in this study (Table 1). This may imply that the mechanism of malignant transformation in lichen planus may be different to the other potentially malignant oral lesions. For the other potentially malignant oral lesions, the mechanism of transformation may relate to the risk factors of betel-quid chewing, cigarette smoking and alcohol drinking, as demonstrated in a number of previous studies (20, 21). For lichen planus lesions, an epidemiological study has suggested the coexistence of lichen planus with hepatitis C in southern Taiwan (22). Infection with hepatitis C virus is proposed as one of the possible risk factors for oral cancer (23). In the present study, only a few patients had proven hepatitis C infection. Therefore, it is difficult to interpret the shorter mean duration of transformation in this study in terms of hepatitis C infection alone; nevertheless, this issue is worthy of further investigation.

Although no statistical significance could be established, our data indicated that the time to malignant transformation in epithelial hyperplasia/hyperkeratosis or submucous fibrosis with epithelial dysplasia was shorter than those lesions without epithelial dysplasia.

In conclusion, the rate and the time to malignant transformation across a spectrum of potentially malignant oral epithelial lesions have been established in a Chinese population in Taiwan. This long-term study of 1458 pre-cancerous patients indicates that the management of oral pre-malignancy includes careful follow up. In the future, developments in the understanding of the progression of oral cancer on a biomolecular level will also add to our understanding of the mechanism of malignant transformation.

References

1. Reibel J. Prognosis of oral pre-malignant lesions: significance of clinical, histopathological, and molecular biological characteristics. *Crit Rev Oral Biol Med* 2003; **14**: 47–62.
2. Chen YK, Hsuen SS, Lin LM. Expression of inducible nitric oxide synthase in human oral premalignant epithelial lesions. *Arch Oral Biol* 2002; **47**: 387–92.
3. Pindborg JJ, Murti PR, Bhonsle RB, Gupta PC, Daftary DK, Mehta FS. Oral submucous fibrosis as a precancerous condition. *Scand J Dent Res* 1984; **92**: 224–9.
4. Krutchkoff D, Cutler L, Laskowski S. Oral lichen planus: the evidence regarding potential malignant transformation. *J Oral Pathol* 1978; **7**: 1–7.
5. Pindborg JJ, Daftary DK, Mehta FS. A follow-up study of sixty-one oral dysplastic precancerous lesions in Indian villagers. *Oral Surg Oral Med Oral Pathol Oral Radiol Endod* 1977; **43**: 383–90.

6. Lumerman H, Freedman P, Kerpel S. Oral epithelial dysplasia and the development of invasive squamous cell carcinoma. *Oral Surg Oral Med Oral Pathol Oral Radiol Endod* 1995; **79**: 321–9.
7. Wright A, Shear M. Epithelial dysplasia immediately adjacent to oral squamous cell carcinoma. *J Oral Pathol* 1985; **14**: 559–64.
8. Bouquot JE, Kurland LT, Weiland LH. Leukoplakia of the head and neck: characteristics of 568 lesions with 6720 person years follow-up. *Oral Surg Oral Med Oral Pathol Oral Radiol Endod* 1999; **88**: 202.
9. Silverman S Jr, Gorsky M, Lozada F. Oral leukoplakia and malignant transformation. A follow-up study of 257 patients. *Cancer* 1984; **53**: 563–8.
10. Cowan CG, Gregg TA, Napier SS, McKenna SM, Kee F. Potentially malignant oral lesions in Northern Ireland: a 20-year population-based perspective of malignant transformation. *Oral Dis* 2001; **7**: 18–24.
11. Chen YK, Huang HC, Lin LM, Lin CC. Primary oral squamous cell carcinomas: an analysis of 703 cases in southern Taiwan. *Oral Oncol* 1999; **35**: 173–9.
12. Bánóczy J, Sugar L. Longitudinal studies in oral leukoplakias. *J Oral Pathol* 1972; **1**: 265–72.
13. Mincer HH, Coleman SA, Hopkins KP. Observations on the clinical characteristics of oral lesions showing histologic epithelial dysplasia. *Oral Surg Oral Med Oral Pathol Oral Radiol Endod* 1972; **33**: 389–99.
14. Gupta PC, Mehta FS, Daftary DK, et al. Incidence rates of oral cancer and natural history of oral precancerous lesions in a 10-year follow up study of Indian villagers. *Community Dent Oral Epidemiol* 1980; **8**: 283–333.
15. Murti PR, Bhonsle RB, Pindborg JJ, Daftary DK, Gupta PC, Mehta FS. Malignant transformation rate in oral submucous fibrosis over a 17-year period. *Community Dent Oral Epidemiol* 1985; **13**: 340–1.
16. Gandolfo S, Richiardi L, Carrozzola M, et al. Risk of oral squamous cell carcinoma in 402 patients with oral lichen planus: a follow-up study in an Italian population. *Oral Oncol* 2004; **40**: 77–83.
17. Silverman S Jr, Gorsky M, Lozada-Nur F. A prospective follow-up study of 570 patients with oral lichen planus: persistence, remission, and malignant association. *Oral Surg Oral Med Oral Pathol* 1985; **60**: 30–4.
18. Holmstrup P, Thorn JJ, Rindum J, Pindborg JJ. Malignant development of lichen planus-affected oral mucosa. *J Oral Pathol* 1988; **17**: 219–25.
19. Markopoulos AK, Antoniadis D, Papanayotu P, Trigonidis O. Malignant potential of oral lichen planus: a follow-up study of 326 patients. *Oral Oncol* 1997; **33**: 263–9.
20. Lee CH, Ko YC, Huang HL, et al. The precancer risk of betel quid chewing, tobacco use and alcohol consumption in oral leukoplakia and oral submucous fibrosis in southern Taiwan. *Br J Cancer* 2003; **88**: 366–72.
21. Jacob BJ, Straif K, Thomas G, et al. Betel quid without tobacco as a risk factor for oral precancers. *Oral Oncol* 2004; **40**: 697–704.
22. Chung CH, Yang YH, Chang TT, Shieh DB, Liu SY, Shieh TY. Relationship of oral lichen planus to hepatitis C virus in southern Taiwan. *Kaohsiung J Med Sci* 2004; **20**: 151–9.
23. Nagao Y, Sata M, Noguchi S, et al. Detection of hepatitis C virus RNA in oral lichen planus and oral cancer tissues. *J Oral Pathol Med* 2000; **29**: 259–66.

This document is a scanned copy of a printed document. No warranty is given about the accuracy of the copy. Users should refer to the original published version of the material.