

CLINICAL REPORTS

Implant-Supported Rehabilitation of the Severely Atrophic Maxilla: A Clinical Report

Miguel Peñarrocha-Diago, MD, DDS, PhD;¹ Roberto Uribe-Origone, DDS, MDS;² and Juan Guarinos-Carbó, MD, DDS, PhD³

Implant-supported rehabilitation in the posterior maxillary region presents a series of challenges because of the possibility of increased pneumatization of the maxillary sinus after dental loss. In cases where significant maxillary bone resorption has occurred, efforts center on maximizing the use of the remaining bone to afford primary stability to the implants. This clinical report describes a patient with extreme maxillary atrophy for whom fixed rehabilitation supported on 8 implants was accomplished. A zygomatic implant, a pterygomaxillary implant, and 2 implants mesial and distal to both canine eminences were placed. This rehabilitation was accomplished with a less invasive technique and in a much shorter time period compared to a sinus lift procedure. One year after prosthetic loading, the clinical and radiological results remain satisfactory.

J Prosthodont 2004;13:187-191. Copyright © 2004 by The American College of Prosthodontists.

INDEX WORDS: severe maxillary atrophy, zygomatic fixtures, pterygomaxillary implants, paranasal angulation of implants

THE LOSS OF POSTERIOR maxillary alveolar bone results in reduction of the residual ridge in both height and thickness.^{1,2} In addition, the maxillary sinus expands as a result of hyperpneumatization. This zone often exhibits poor bone quality, generally involving type 3 or 4 bone, according to the Lekholm and Zarb classification,³ resulting in an area that lacks primary stability and that may compromise osseointegration.⁴ A variety of techniques have been proposed to resolve the problem of maxillary atrophy,⁵ with the most widely used approaches being elevation of the maxillary sinus floor⁶⁻¹¹ and surgical maxillary reconstruction with iliac crest,^{12,13} cortical plate expansion, and osteotome sinus lift technique,^{14,15} or calvarial autologous bone grafts.¹⁶

To optimize primary fixation, the implants are often positioned in those zones having the most

optimal residual bone. Following extraction of the maxillary first molar, an increased amount of bone is retained in the alveolus of the palatal root. In the completely edentulous patient, this affords a good option for placing canine post and parasinus angulation implants.¹⁷⁻¹⁹ In most cases, the maxillary tuberosity lacks a cortical component, although it joins inferiorly to the pterygoid and pyramidal processes of the palatal bone. This offers a very compact cortical layer capable of providing primary stability for pterygoid implants.²⁰ In addition, zygomatic implants have been developed for rehabilitating completely edentulous cases with advanced maxillary resorption, using the zygomatic bone as an anchor for oral implants.^{21,22} Both pterygoid and transzygomatic implants require the presence of other implants mesial to the maxillary sinus to ensure prosthetic stability and function.

This clinical report describes a patient with severe maxillary atrophy, whose implant-supported rehabilitation was carried out making maximum use of the residual bone of the canine, pterygoid, and maxillo-malar sites.

Clinical Report

A 48-year-old non-smoking female had been fully edentulous in the maxillary arch for 10 years, with

From the Valencia University Dental School, Valencia, Spain.

¹Assistant Professor of Oral Medicine, Director of the Master of Oral Surgery and Implantology.

²Master of Oral Surgery and Implantology.

³Associate Professor, Master of Oral Surgery and Implantology.

Accepted February 2, 2004.

Correspondence to: Miguel Peñarrocha-Diago, MD, DDS, PhD, Clínica Odontológica, Gascó Oliag 1, 46010 – Valencia, Spain. E-mail: penarrocc@uv.es

Copyright © 2004 by The American College of Prosthodontists 1059-941X/04

doi: 10.1111/j.1532-849X.2004.04031.x

sinus hyperpneumatization and severe maxillary atrophy. She wore a mandibular fixed prosthesis supported by the remaining teeth in the mandible, and a poor-fitting complete maxillary prosthesis with inadequate retention. The prosthesis had been frequently modified in the past. The patient's chief complaint was that she was unhappy with the retention and fit of the current maxillary denture. Following clinical examination, development of articulated diagnostic casts, and radiographic studies, including panoramic radiography (Fig 1) and computed tomography, a treatment plan involving fixed implant-supported rehabilitation was developed.

Surgery was carried out under intravenous sedation with midazolam with close clinical monitoring. After local anesthetic infiltration (4% articaine with 1:200,000 epinephrine), a supracrestal linear incision was made from one tuberosity to the other, raising a full thickness flap and revealing a crest of bone with a width of approximately 3 mm. The recipient sites were prepared using osteotomes in the anterior maxillary region. Four threaded ITI® implants (ITI Straumann, Walderburg, Switzerland) with SLA surfaces, measuring 12 mm in length and 4.1 mm in diameter were placed in zones 1.4, 1.3, 2.2, and 2.4. As a result of minimal (3 mm) bone width, fenestrations and bone dehiscences occurred during implant placement, principally in the anterior maxillary region—zones 1.4, 1.3, and 2.2 of the vestibular table (Figs 2 and 3). Under infiltrating anesthesia, block parasymphiseal autologous bone grafts were harvested with a trephine bur and affixed with osteosynthesis screws to cover the dehiscences and fenestrations (Fig 4).

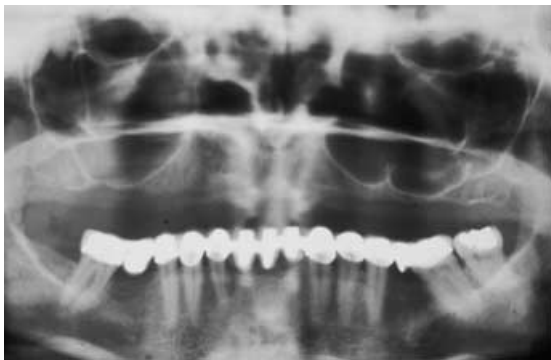

Figure 1. Panoramic X-ray view showing maxillary bone resorption and sinus hyperpneumatization.

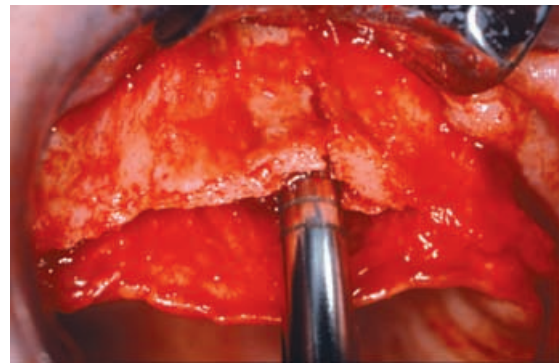


Figure 2. Vestibular bone dehiscences in the preparation and threading of maxillary implants in the 1.3 region.

Based on the technique described by Tulasne,²⁰ an ITI® pterygoid implant measuring 16 mm in length and 4.1 mm in diameter was positioned in each hemiarch with good primary fixation. Brånemark Zygomatics Fixtures® (Nobel Biocare, Göteborg, Sweden) measuring 40 mm in length were then placed, following the sinusal bone window technique of the Zygomatics Fixture, Brånemark System®.²¹ Primary closure was obtained with 3.0 silk, leaving all the implants submerged. The patient's complete maxillary prosthesis was relieved directly above the implants and adapted with tissue conditioner (Viscogel(R), Dentsply-Detrey, Konstanz, Germany). Controlled panoramic X-rays were obtained (Fig 5), and the required postoperative instructions were provided. Prescribed medications included amoxicillin 500 mg, ibuprofen

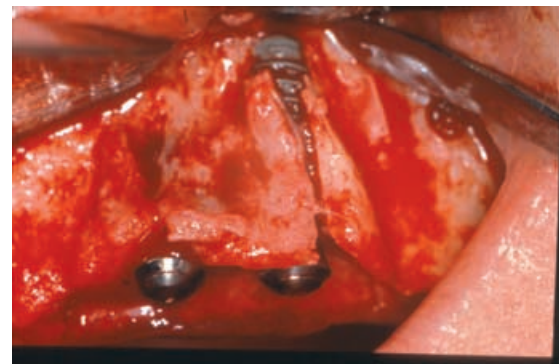


Figure 3. Vestibular bone dehiscences in the preparation and threading of maxillary implants in the right parasinus regions.

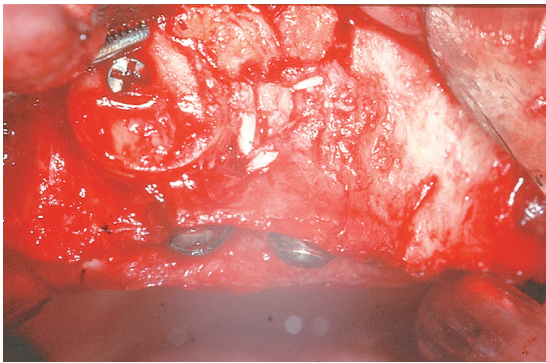


Figure 4. Covering of the bone defect with chin plate autograft affixed with a titanium screw.

600 mg, and paracetamol 650 mg with codeine 10 mg every 8 hours. Mouth rinses with 0.12% chlorhexidine digluconate twice daily were also prescribed.

Six months later the second stage of surgery was performed; healing abutments were placed and impressions were made (Fig 6) in preparation for the fixed complete maxillary prosthesis (Figs 7 and 8). One year after prosthetic loading, the implants appeared clinically and radiologically normal, and the patient reported significant improvement in oral function.

Discussion

In the extremely atrophic maxilla, implantation offers the possibility of increasing the maxillary dimension with autologous grafting from a bone-rich donor zone.^{12-16,23} However, this entails an added risk, i.e., possible graft failure, and moreover, often requires general anesthesia. Limiting factors include the marked resorption of bone

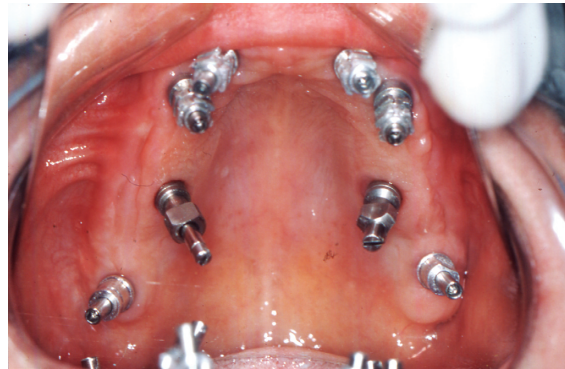

Figure 6. Impression copings in place, demonstrating angulation of the implants.

harvested from the iliac crest during healing, and the limited volume of bone afforded by calvarial grafts. The discomfort experienced by patients in the donor region during the postoperative period constitutes another important factor.

Elevation of the floor of the maxillary sinus provides another option, employing implants that penetrate 2–3 mm into the floor of the maxillary and nasal sinuses. Brånemark et al have reported a survival rate of 88–96% in such cases.¹⁹ In patients with insufficient bone, filling with graft material is required. Mixtures of hydroxyapatite^{24,25} and calcium sulfate have been used,²⁶ as well as autologous bone, allografts, and xenografts. This, in turn, requires additional surgery, as well as the necessity of obtaining bone from a donor site (chin, tuberosity, mandibular retromolar trigone, iliac crest, or skull).²⁷⁻³² In cases of severe maxillary resorption, with remnant bone heights of 3 mm, implant surgery should be postponed 6

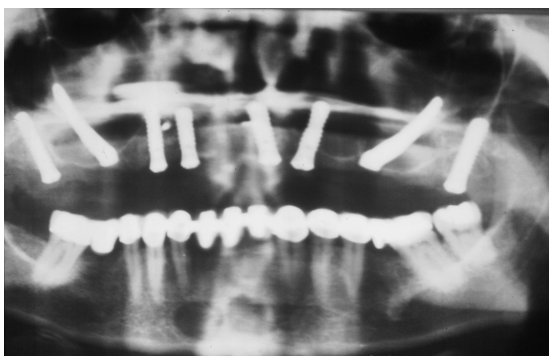


Figure 5. Postoperative panoramic X-ray.

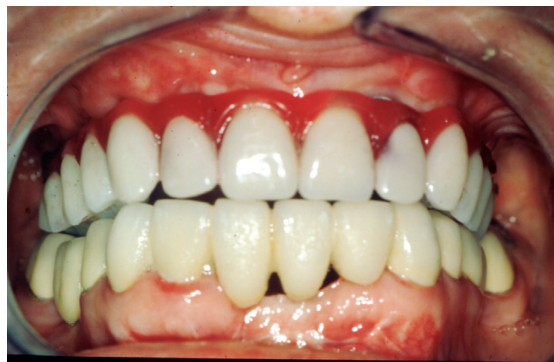

Figure 7. Facial view of final prosthesis.

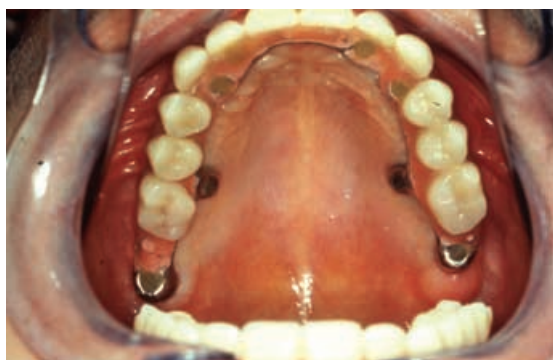

Figure 8. Palatal view of the implant-supported metal-porcelain fixed prosthesis.

months after direct elevation of the sinus floor.²⁷ As a result, placing implants in the maxillary sinus zone required direct elevation of the sinus floor in 2 steps. Reported success rates for delayed implantation range from 80.9% according to Blomqvist et al³³ to 87.4% and 94% as reported by Jensen³⁴ and Lozada et al³⁵. Although this is a common and safe technique, it is not without potential complications such as sinusitis, graft and implant losses, and osteomyelitis.³⁶ In the case described in this clinical report, the patient rejected the proposal involving second-stage surgery and prolongation of the waiting time for prosthesis preparation.

Placing implants in pterygoid or zygomatic zones represented complex but valid surgical alternatives for this patient. Both techniques afford very high survival rates. An 80% success rate for a series of 52 pterygoid implants has been reported by Tulasne,²⁰ while Balshi and Wolfinger have reported a success rate of 88.2% from a sample of 356 implants.³⁷ Pi, in 1998, reported a 97.2% success rate in 177 implants,³⁸ and Raspall in 1998 reported success in 99% of 238 implants.³⁹ A high proportion of success for zygomatic implants has also been reported. Brånemark et al²¹ reported a 97% survival rate in 164 implants with a follow-up of 1–10 years. Aparicio and Malevez⁴⁰ reported successful placement of 58 implants and provided a review of the technique and the preparation of prostheses.

In the clinical situation described in this report, a combination of implantation techniques was judged appropriate and resulted in a satisfactory prosthetic outcome, less surgical trauma and waiting time than with other alternatives, and,

perhaps most importantly, optimum acceptance by the patient.

Acknowledgment

The authors gratefully acknowledge the laboratory assistance of Rafael Gil in the fabrication of the prosthesis.

References

1. Tallgren A: The continuing reduction of the residual alveolar ridges in complete denture wearers: a mixed-longitudinal study covering 25 years. *J Prosthet Dent* 1972;27:120-132
2. Cawood JI, Howell RA: A classification of the edentulous jaws. *Int J Oral Maxillofac Surg* 1988;17:232-236
3. Lekholm U, Zarb G: Patient selection and preparation. In: Brånemark PI, Zarb G, Albrektsson T, eds. *Tissue-Integrated Prostheses*. Chicago, IL, Quintessence, 1985, pp 199-209
4. Pi J: Reconstrucción quirúrgica del maxilar superior atrófico mediante autoinjerto e implantes de titanio puro. Resultados de 4 años de experiencia. *Rev Act Odontostomatológica Esp* 1995;10:37-43
5. Peñarrocha M, Pi J: Situaciones Especiales. In: Peñarrocha M, ed. *Implantología Oral*. Barcelona, Ars Medica, 2001, pp 95-127
6. Jensen OT. *The Sinus Bone Graft*. London, Quintessence, 1999
7. Jensen OT, Shulman LB, Block MS, et al: Report of the Sinus Consensus Conference of 1996. *Int J Oral Maxillofac Implants* 1998;13:11-45
8. Rosen PS, Summers R, Mellado JR, et al: The bone-added osteotome sinus floor elevation technique: multicenter retrospective report of consecutively treated patients. *Int J Oral Maxillofac Implants* 1999;14:853-858
9. Padrós A: Técnicas implantológicas en zona posterior de maxilar superior. Seguimiento y valoración con sinuscopías y resonancias magnéticas. *Implantes* 1994;1:8-14
10. Vila M, Marcet JM, Faura M: Implantes pterigoideos versus elevación sinusal. Comparación crítica. *Archivos de Odontostomatología* 1999;5:523-535
11. Moy PK, Lundgren S, Holmes RE: Maxillary sinus augmentation: histomorphometric analysis of graft materials for maxillary sinus floor augmentation. *J Oral Maxillofac Surg* 1993;51:857-862
12. Breine U, Brånemark PI: Reconstruction of alveolar jaw bone. An experimental and clinical study of immediate and preformed autologous bone grafts in combination with osseointegrated implants. *Scand J Plast Reconstr Surg* 1980;14:23-48
13. Adell R, Lekholm U, Grondahl K, et al: Reconstruction of severely resorbed edentulous maxillae using osseointegrated fixtures in immediate autogenous bone grafts. *Int J Oral Maxillofac Implants* 1990;5:233-246
14. Nentwig GH: Technic of bone splitting for alveolar recession in anterior maxillary region. *Quintessence* 1986;37:1825-1834
15. Peñarrocha M, Sanchis JM, Guarinos J, et al: Estudio comparativo entre la técnica convencional y la de

- los osteodilatadores para la creación del lecho implantológico. A propósito de 226 implantes colocados en 80 pacientes. *Avances Periodoncia e Implantología* 2000;10:189-198
16. Donovan MG, Dickerson NC, Hellstein JW, et al: Autologous calvarial and iliac onlay bone grafts in miniature swine. *J Oral Maxillofac Surg* 1993;51:898-903
 17. Guarinos J, Peñarrocha M, Sanchis JM, et al: Tres casos clínicos de la técnica de angulación parasinusal en implantología oral. *Quintessence (Span. edit.)* 1997;10:37-41
 18. Bert M, Missika P: Técnicas quirúrgicas especiales. In: Bert M, Missika P, eds. *Implantes Oseointegrados*. Barcelona, Masson, 1994, pp 221-238
 19. Brånemark PI, Adell R, Albrektsson T, et al: An experimental and clinical study of osseointegrated implants penetrating the nasal cavity and maxillary sinus. *J Oral Maxillofac Surg* 1984;42:497-505
 20. Tulasne FJ: Osseointegrated fixtures in the pterygoid region. In: Worthington P, Branemark PI eds. *Advanced Osseointegration Surgery: Applications in the Maxillofacial Region*. Chicago, IL, Quintessence, 1992, pp 182-188
 21. The Zygomaticus fixture. Brånemark System. Nobel Biocare. Göteborg-Sweden, 1998
 22. Aparicio C, Brånemark PI, Keller EE, et al: Reconstruction of the premaxilla with autogenous iliac bone in combination with osseointegrated implants. *Int J Oral Maxillofac Implants* 1993;8:61-67
 23. Isaksson S, Alberius P: Maxillary alveolar ridge augmentation with onlay bone-grafts and immediate endosseous implants. *J Craniomaxillofac Surg* 1992;20:2-7
 24. Smiler DG, Johnson PW, Lozada JL, et al: Sinus lift grafts and endosseous implants. Treatment of the atrophic posterior maxilla. *Dent Clin North Am* 1992;36:151-186
 25. Wagner J: A 3 $\frac{1}{2}$ -year clinical evaluation of resorbable hydroxylapatite OsteoGen (HA Resorb) used for sinus lift augmentations in conjunction with the insertion of endosseous implants. *J Oral Implantol* 1991;17:152-164
 26. Pecora GE, De Leonardi D, Della Rocca C, et al: Short-term healing following the use of calcium sulfate as a grafting material for sinus augmentation: a clinical report. *Int J Oral Maxillofac Implants* 1998;13:866-873
 27. Misch C: Levantamiento y elevación del seno maxilar con aumento subantral. In: Misch C, ed. *Implantología Contemporánea*. Madrid, Mosby/Doyma, 1995, pp 539-567
 28. Raghoobar GM, Brouwer TJ, Reintsema H, et al: Augmentation of maxillary sinus floor with autogenous bone for the placement of endosseous implants: a preliminary report. *J Oral Maxillofac Surg* 1993;51:1198-1203
 29. Chiapasco M, Romeo E, Vogel G: Tridimensional reconstruction of knife-edge edentulous maxillae by sinus elevation, onlay grafts, and sagittal osteotomy of the anterior maxilla: preliminary surgical and prosthetic results. *Int J Oral Maxillofac Implants* 1998;13:394-399
 30. Zinner ID, Small SA: Sinus-lift graft: Using the maxillary sinuses to support implants. *J Am Dent Assoc* 1996;127:51-57
 31. Neyt LF, De Clercq CA, Abeloos JV, et al: Reconstruction of the severely resorbed maxilla with a combination of sinus augmentation, onlay bone grafting, and implants. *J Oral Maxillofac Surg* 1997;55:1397-1401
 32. Wood RM, Moore DL: Grafting for the maxillary sinus with intraorally harvested autogenous bone prior to implant placement. *Int J Oral Maxillofac Implants* 1988;3:209-214
 33. Blomqvist JE, Alberius P, Isaksson S: Retrospective analysis of one-stage maxillary sinus augmentation with endosseous implants. *Int J Oral Maxillofac Implants* 1996;11:512-521
 34. Jensen OT, Sennerby L: Histologic analysis of clinically retrieved titanium microimplants placed in conjunction with maxillary sinus floor augmentation. *Int J Oral Maxillofac Implants* 1998;13:513-521
 35. Lozada JL, James RA, Boyne M, et al: Valoración clínica y respuesta histológica de materiales autólogos y heterólogos, empleados en la elevación del seno maxilar, para la colocación de implantes endoóseos. *Act Implantol* 1998;3:33-41.
 36. Regev E, Smith RA, Perrot DH, et al: Maxillary sinus complications related to endosseous implants. *Int J Oral Maxillofac Implants* 1995;10:451-461
 37. Balshi TJ, Wolfinger GJ, Balshi SF II: Analysis of 356 pterygomaxillary implants in edentulous arches for fixed prosthesis anchorage. *Int J Oral Maxillofac Implants* 1999;14:398-406
 38. Pi J: Implantes en la región pterigomaxilar: Estudio retrospectivo con seguimiento de 1 a 10 años. *RCOE* 1998;4:339-348
 39. Raspall G, Rodríguez J: Implantes pterigoideos. *RCOE* 1998;5:461-467
 40. Aparicio C, Malevez C: El implante trans-zigomático. *RCOE* 1999;2:171-184

Copyright of Journal of Prosthodontics is the property of Blackwell Publishing Limited. The copyright in an individual article may be maintained by the author in certain cases. Content may not be copied or emailed to multiple sites or posted to a listserv without the copyright holder's express written permission. However, users may print, download, or email articles for individual use.