

CLINICAL REPORT

An Innovative Approach to Chairside Provisional Replacement of an Extracted Anterior Tooth: Use of Fiber-Reinforced Ribbon-Composites and a Natural Tooth

Neslihan Eminkahyagil, DDS, MSc, PhD;¹ and Selim Erkut, DDS, PhD²

Immediate chairside replacement of an extracted anterior tooth may contribute to a patient's comfort, treatment acceptance, and expectations of treatment; however, fabrication of a custom restoration in the anterior region of the mouth may result in an esthetic compromise for patients during the fabrication period. Chairside tooth replacement is an excellent application of fiber-reinforced composite resin technology. This article presents an innovative, affordable chairside procedure in which Ribbond Multi-Purpose Bondable Reinforcement Ribbon is used to replace a single extracted anterior tooth using the patient's own tooth.

J Prosthodont 2006;15:316-320. Copyright © 2006 by The American College of Prosthodontists.

INDEX WORDS: fiber-reinforced composite, provisional restoration, extracted tooth

WHEN A SINGLE tooth is extracted from the anterior region of the mouth, patients now expect immediate esthetic restoration of the edentulous spaces until the definitive restoration is placed. The final restorations may be implant-assisted or a fixed/removable prosthesis. In all cases, there is a healing period during which the gingival and bone architecture undergo changes associated with healing.

Fiber-reinforced composite (FRC) resin technology offers various solutions to many complex problems in restorative dentistry. The two most important mechanical properties for FRC resins are strength and stiffness. The properties of FRC resins that make them well suited for various chairside applications include strength, desirable esthetic characteristics, ease of use, adaptability of various shapes, and potential for direct bonding to tooth structure.¹

Chairside tooth replacement is an excellent application of fiber-reinforced technology. Previous attempts at chairside tooth replacement involved the use of pontics derived from extracted teeth,²⁻⁴ acrylic resin denture teeth with or without lingual wire reinforcement,^{5,6} and resin composite.^{3,7-10} All these materials have various limitations: poor handling characteristics, over bulking, insufficient bonding, maintenance, and poor esthetic outcomes. Those procedures were usually considered to be short-term solutions.¹

This article presents chairside procedures of three cases in which interim provisional replacement of missing teeth prior to implant replacement was accomplished by Ribbond-reinforced composite resin technology.

Clinical Report

Case 1

A 41-year-old man was referred for implant replacement of a maxillary left central incisor. The tooth was to be extracted secondary to the advanced bone loss of periodontal disease (Fig 1). Immediately after the extraction, the tooth was sectioned at the cemento-enamel junction. The pulp chamber was sealed with composite resin and fitted as a pontic in the edentulous space. A groove was prepared in the mid-palatal section

From the Baskent University, Ankara, Turkey.

¹Assistant Professor, Department of Conservative Dentistry.

²Assistant Professor, Department of Restorative Dentistry.

Accepted June 1, 2005.

Correspondence to: Neslihan Eminkahyagil, Department of Conservative Dentistry, Baskent University, 11.sok no: 26 Ankara Bahcelievler 06490, Turkey. E-mail: neslihan@baskent.edu.tr

Copyright © 2006 by The American College of Prosthodontists
1059-941X/06

doi: 10.1111/j.1532-849X.2006.00125.x

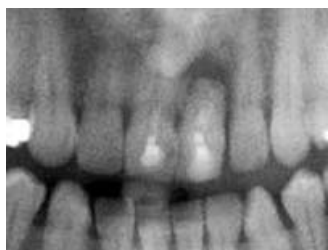


Figure 1. Radiographic view of Case 1.

(Fig 2). This intracoronar groove was a horizontal channel to accommodate the width and thickness of the FRC resin reinforcement material in the middle third of the tooth.^{10,11} The dimensions of this groove usually range from 2 to 3 mm wide and 1 to 2 mm deep. The pontic was temporarily held in position with composite resin without acid etching and bonding to minimize rotation during the treatment (Fig 3).

The required length of ribbon (Ribbond, Ribbond Inc., Seattle, WA) was determined by measuring the space with dental floss on the diagnostic cast before extraction (Fig 4). The ribbon was wet with unfilled resin (Filtek Flow, 3M ESPE, St. Paul, MN). Care was taken to keep the wet ribbon from light to prevent initial polymerization, which would interfere with manipulation of the ribbon. The adjacent central and lateral incisors' mid-palatal and proximal sections were prepared according to the manufacturers' directions. Lip retractors and cotton rolls were used to isolate the working area. The palatal and proximal surfaces of the adjacent teeth and the pontic were acid etched with 37% phosphoric acid (Scotchbond Etchant, 3M ESPE) (Fig 5). Bonding agent (Single Bond,

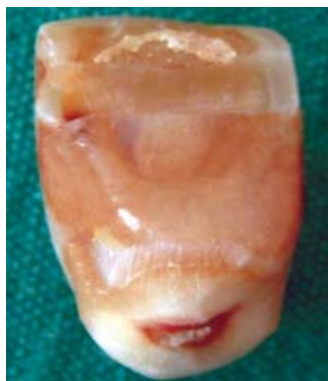

Figure 2. The prepared pontic tooth.

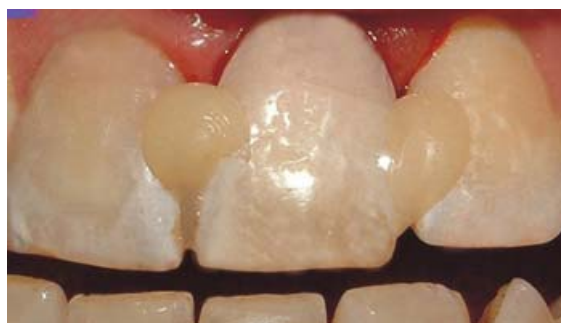

Figure 3. The temporary attachment of the pontic tooth by composite resin.

3M ESPE) was applied and light polymerized with a halogen light of 500 mW/mm² (Hilux, Benlioglu, Turkey) for 10 seconds. A thin layer of universal hybrid composite resin (Filtek Z250, 3M ESPE) was placed on the palatal surfaces of the adjacent teeth and extended slightly to the proximal surfaces of each tooth adjacent to the edentulous area.

The wetted ribbon was pressed into the composite resin and placed on the palatal surfaces. The ribbon was light polymerized for 40 seconds from lingual and proximal directions and covered by another layer of composite resin. The composite resin placed previously to prevent pontic movement during the treatment was removed with a hand instrument. The final step was adjustment of occlusion and esthetic contouring of the provisional restoration. Care was taken to avoid centric and eccentric occlusal contacts on the pontic. The splint was finished and polished (Sof-lex, 3M ESPE) (Fig 6).

As the fixed interim restoration was bulky and overcontoured, the patient was clearly informed of the importance of oral hygiene by giving more

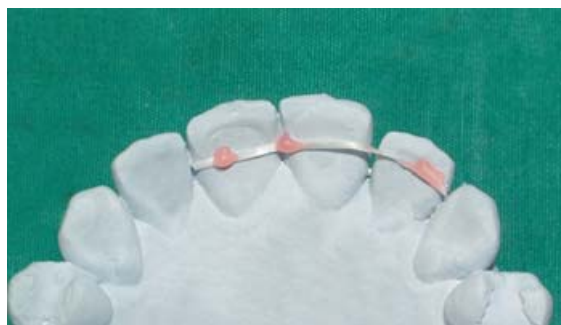

Figure 4. Determination of the required length of ribbon by dental floss.

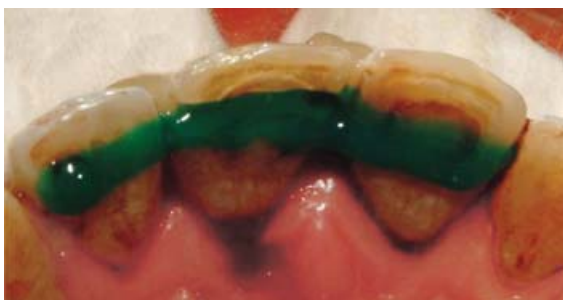

Figure 5. The acid etching of palatal surfaces.

attention to plaque control and traditional home care procedures using proximal brushes and dental floss. The patient was seen for 1-week, 1-month, 6-month, 12-month, and 15-month follow-up appointments.

The patient was satisfied with the esthetic outcome of the treatment modality and requested postponement of the implant surgery. No crack propagation, fractures, or damage around soft and hard tissues were observed in the follow-up appointments, and the patient remained asymptomatic. Thus, it was decided to determine the durability of the provisional restoration. Figure 7 shows the condition of the restoration and surrounding soft tissues at the 15-month follow-up appointment.

Case 2

A 48-year-old man was referred to the clinic with a chief complaint of “discomfort while chewing and biting” with the mandibular anterior teeth. After consultation with the periodontist, it was decided to extract the mandibular left central incisor (Fig 8). The clinical periodontal prognosis of the adjacent teeth was unpredictable for a fixed restoration. They were not considered to be

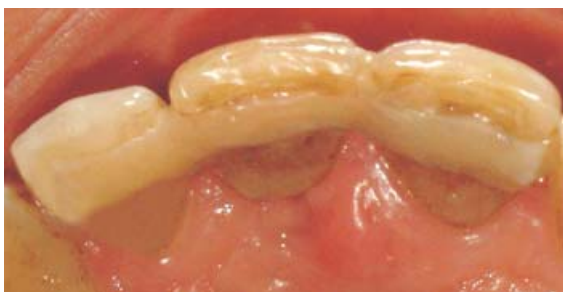

Figure 6. Palatal view of the final restoration.

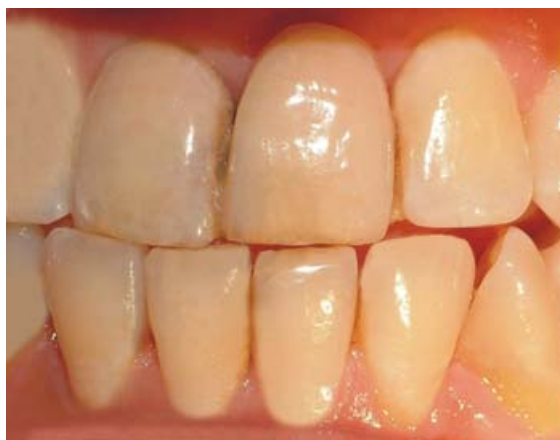

Figure 7. Facial view of the restoration after 15 months.

satisfactory abutments for a fixed partial denture. Also, the patient was in the middle of chemo-radio therapy and could not tolerate either long dental appointments or dental implant surgery. It was decided to extract the tooth, remove the crown from the root, and use it as the interim fixed restoration in a single appointment. The extracted tooth and the adjacent teeth were prepared as in Case 1. The restoration was placed and finished. The patient was called for follow-up appointments at 1 week, 1 month, and 8 months. Figure 9 shows the clinical condition at the 8-month follow-up appointment.

Case 3

A 45-year-old woman was referred to the clinic with severe mobility of mandibular incisors

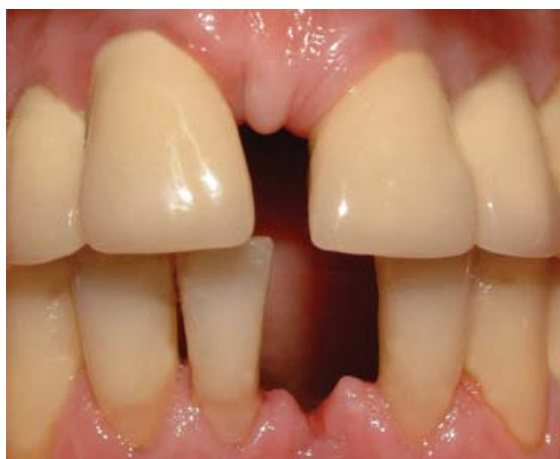

Figure 8. Initial facial view of Case 2.

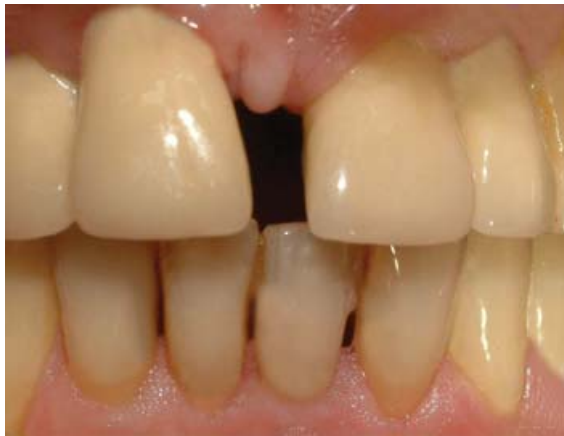

Figure 9. Facial view of the final restoration after 8 months.

(Fig 10). The mandibular left central incisor was determined to have a hopeless prognosis and was planned for extraction. The patient demanded an immediate restoration for the edentulous space. The restoration was accomplished as previously described. Figure 11 shows the clinical condition at the 8-month follow-up appointment.

Discussion

Dental implants possess many advantages and can be an essential part of prosthodontic treatment planning for missing teeth. In the anterior region of the mouth, implant-assisted restorations may provide optimal esthetics and avoid irreversible preparations of intact adjacent teeth. When implants are placed with a 2-stage surgical protocol in the anterior segments of both jaws, esthetic compromises during healing are of concern. Many

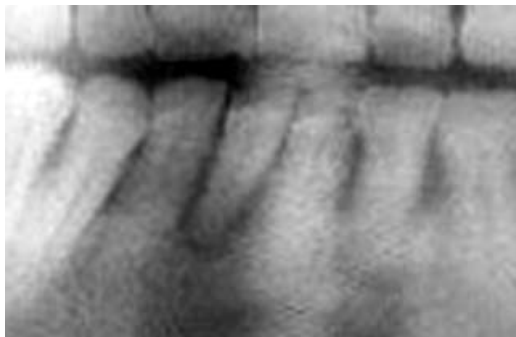

Figure 10. Radiographic view of Case 3.

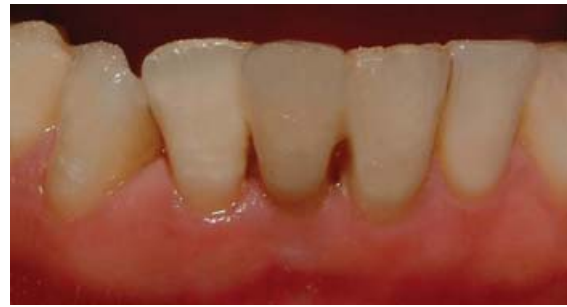

Figure 11. Facial view of Case 3 after 8 months.

patients demand an attractive provisional solution immediately after the extraction of the anterior tooth.¹²

In order to replace a missing tooth immediately following extraction, a long-term interim fixed prosthesis may be the treatment of choice before implant surgery. In most cases, this allows the surgically altered tissues to fully mature in preparation for the definitive fixed prosthesis. When placed immediately after extraction, the fixed provisional restoration can serve as a protective covering over the extraction site, preventing debris and contaminants from entering the surgical area.¹³

Horizontal grooves prepared in the midpalatal sections of the pontics are one of the key concepts illustrated in the above treatments. This technique ensures maximum adhesion and durability when bonding the pontics to the adjacent natural teeth with composite resin.

Reinforcement fibers have been shown to increase the flexural strength and fracture toughness of composite resin restorations and thus help prevent fracture due to high stresses associated with mastication.¹⁴ Since the early 1990s, a lenowoven polyethylene ribbon (Ribbond™) has been used successfully for tooth splinting, replacement of missing teeth, reinforcement of provisional acrylic resin fixed partial dentures, and orthodontic retention.¹⁵ The fibers are made for chairside use in a single appointment procedure that requires no special treatment preparation or instrumentation.¹⁶

Conclusion

The chairside fiber-reinforced composite resin prostheses described in this clinical report offer

a fast, minimally invasive approach for esthetic, interim tooth replacement that combines the benefits of the fiber-reinforced composite resin material for a functional and durable result.

Acknowledgments

We thank Sule Bulut, DDS, PhD and Emine Alaaddinoglu DDS, PhD of the Department of Periodontology, Faculty of Dentistry, Baskent University for their contributions in the patient treatment illustrated in this paper.

References

1. Freilich MA, Meiers JC, Duncan JP, et al: Fiber-Reinforced Composites in Clinical Dentistry. Carol Stream, IL, Quintessence, 2000, pp 49-70
2. Antonson DE: Immediate temporary bridge using an extracted tooth. *Dent Surv* 1980;56:22-25
3. Ibsen RL: Fixed prosthetics with a natural crown pontic using an adhesive composite. Case history. *J South Calif Dent Assoc* 1973;41:100-102
4. Strassler HE, LoPesti J, Scherer W, et al: Clinical evaluation of a woven polyethylene ribbon used for splinting. *Esthet Dent Update* 1995;6:80-84
5. Davila JM, Gwinnett AJ: Clinical and microscopic evaluation of a bridge using acid-etch resin technique. *ASDC J Dent Child* 1978;45:228-232
6. Littman H, Regan D, Rakow B: Provisional temporization with acid-etch resin technique. *Clin Prev Dent* 1980;2:14-15
7. Jensen ME, Meiers JC: Resin Bonded Retainers in Clinical Dentistry, vol 4. Philadelphia, Harper and Row, 1984, pp 4-5
8. Simonsen R, Thompson V, Barrack G: Etched Cast Restorations: Clinical and Laboratory Techniques. Chicago, Quintessence, 1983
9. Strassler HE, Gerhardt DE: Trouble shooting everyday restorative emergencies. *Dent Clin North Am* 1993;37:353-366
10. Strassler HE: Planning with diagnostic casts for success with direct composite bonding. *J Eshet Dent* 1995;7:32-40
11. Strassler HE, Serio FG: Stabilisation of the natural dentition in periodontal cases using adhesive restorative materials. *Perio Insights* 1997;4:4-10
12. Goldstein RE: Change Your Smile (ed 3). Chicago, Quintessence, 1997, pp 2-3
13. Shuman IE: Long-term provisionalization following tooth extraction: an innovative approach. *Dent Today* 2003;22:60-63
14. Valittu PK: A review of fiber-reinforced denture base resins. *J Prosthodont* 1996;5:270-276
15. Dickerson WG: A conservative alternate to single tooth replacement: a three-year follow-up. *Pract Periodontics Aesthet Dent* 1995;5:43-49
16. Strassler HE: Aesthetic management of traumatized anterior teeth. *Dent Clin North Am* 1995;39:181-202

Copyright of Journal of Prosthodontics is the property of Blackwell Publishing Limited and its content may not be copied or emailed to multiple sites or posted to a listserv without the copyright holder's express written permission. However, users may print, download, or email articles for individual use.