

CLINICAL REPORT

The Evolution of Advanced Prosthodontic Care: A 30-Year Patient Report

Thomas J. Balshi, DDS, FACP;¹ Stephen F. Balshi, MBE;²
and Glenn J. Wolfinger, DDS, FACP³

This clinical report demonstrates the history of a patient with progressive periodontal deterioration and illustrates how prosthodontic treatment has evolved over time. In 1974, maxillary and mandibular telescopic porcelain-fused-to-gold fixed prostheses and a semi-precision maxillary distal-extension removable partial denture represented leading edge technology. Over time, a gradual deterioration in the patient's intraoral condition occurred secondary to chronic, inflammatory periodontal disease, failed appointments, and recurrent caries. Prosthodontic treatment was also evolving. The patient's teeth were extracted and ultimately replaced with two implant-supported fixed prostheses. This clinical report is one example of how patients continually benefit from continued research in biology and materials science.

J Prosthodont 2007;16:43-49. Copyright © 2007 by The American College of Prosthodontists.

INDEX WORDS: telescopic prosthesis, Brånemark implants, immediate implant placement, freeze-dried bone, surgical guide, tissue-integrated prosthesis

SINCE ITS INCEPTION, the specialty of prosthodontics has been devoted to research, education, and patient care at the highest level of expertise. In the early 1970s, the American Board of Prosthodontics required all candidates who wanted to become diplomates present the results of specific treatments. The candidates also had to defend the treatment plan, procedures, and materials used. The Board required that all treatments embody prosthodontic art and science in its most advanced form.

The patient described in this report was the subject of a successful 1976 Board presentation. The treatment she received in 1974 and 1975 was the result of thorough radiographic and physical examinations, treatment planning, and treat-

ment. For a number of years, it satisfied her dental needs and expectations. Certain life events exposed the patient to dental trauma and stress. Approximately 15 years after the original treatments were completed, the patient developed significant irreversible problems. Prosthodontics had developed more advanced solutions to these problems. The following clinical report is the description of the diagnosis, treatment planning, and treatment for this patient, including the use of endosseous dental implants.

Clinical Report

Initial Patient Presentation and Treatment (1974-1976)

This 51-year-old teacher was in good general health with a dental complaint of pain and swelling of the gingival tissues associated with maxillary anterior porcelain jacket crowns placed 4 months earlier.

Multiple teeth were missing in both dental arches. Recurrent caries was also evident in all restored teeth, along with poorly contoured restorations (Fig 1), and bone loss associated with advanced periodontal disease (types III and IV). Radiographs showed evidence of periapical pathology and varying degrees of alveolar bone loss (Fig 2).

¹Prosthodontist, Prosthodontics Intermedica, Fort Washington, PA; Diplomate, American Board of Prosthodontics; Director, Institute for Facial Esthetics, Fort Washington, PA.

²Biomedical Engineer and Director of Research, Prosthodontics Intermedica, Fort Washington, PA.

³Prosthodontist, Prosthodontics Intermedica; Diplomate, American Board of Prosthodontics; Staff Prosthodontist, Department of Veterans Affairs Medical Center, Philadelphia, PA.

Accepted August 11, 2005.

Correspondence to: Stephen F. Balshi, MBE, 467 Pennsylvania Avenue, #201, Fort Washington, PA 19034. E-mail: Balshi2@aol.com

Copyright © 2006 by The American College of Prosthodontists
1059-941X/06

doi: 10.1111/j.1532-849X.2006.00153.x

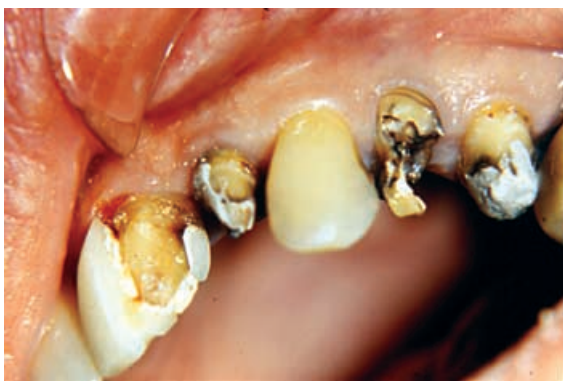

Figure 1. Fractured restorations and recurrent dental caries of numerous teeth at the initial patient presentation (1974).

A multidisciplinary treatment plan was developed. This included periodontal surgery, endodontics, and fixed/removable prosthodontics.

The first phase of the plan involved controlling the caries in the maxillary teeth with a fixed provisional splint for teeth #5 to 13. A posterior distal-extension removable partial denture (RPD) was to be used to replace the missing posterior teeth.¹⁻⁵

Several of the mandibular teeth were treated with root canal therapy and cast post and cores. All the mandibular teeth were splinted with a full-arch acrylic resin provisional fixed partial denture. This treatment was developed in coordination with the requirements for the American Board of Prosthodontics, using procedures and technology deemed appropriate in the 1970s.²⁻⁶

Over the course of the next year, teeth #12, 14-16, 24-26, and 31 were identified as having hopeless prognoses and were removed. The patient underwent full-mouth periodontal surgery. The provisional restorations were modified during the course of periodontal therapy and healing.

The definitive maxillary prosthesis consisted of cast gold (Type III gold, Ney, Bloomfield, CT) primary copings for all remaining abutment teeth (Fig 3). These were splinted with a porcelain-fused-to-high-gold (Jelenko "O," J.F. Jelenko, Armonk, NY) telescopic overcasting. Attachments (Tach-E-Z with a milled equipoise bracing arm, Attachments International, San Mateo, CA) were placed into the distal surfaces of the distal retainers for the Kennedy Class I RPD (Fig 4).⁷

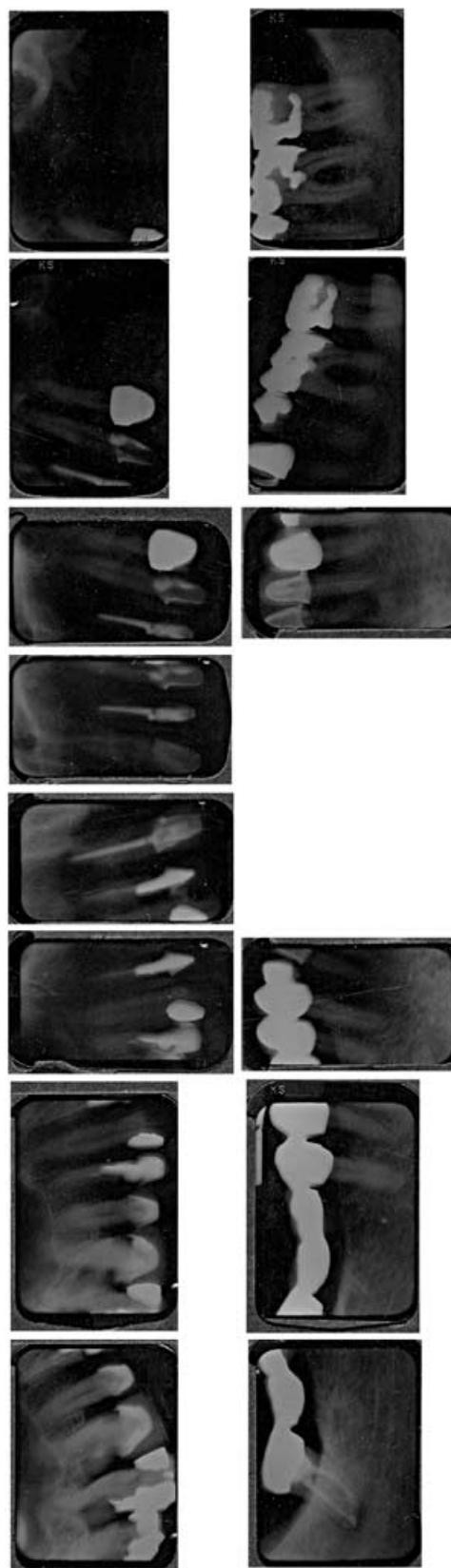


Figure 2. Preoperative periapical radiographs demonstrate advanced bone loss, recurrent caries, multiple missing teeth, and widened periodontal ligaments (1974).

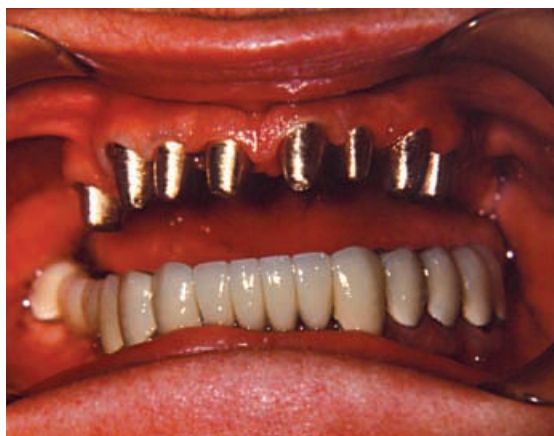

Figure 3. Gold primary copings restoring maxillary abutment teeth (1975).

The definitive mandibular prosthesis consisted of cast gold (Type III gold) primary copings for all abutments. The mandibular teeth were splinted with a porcelain-fused-to-high-gold (Jelenko "O")

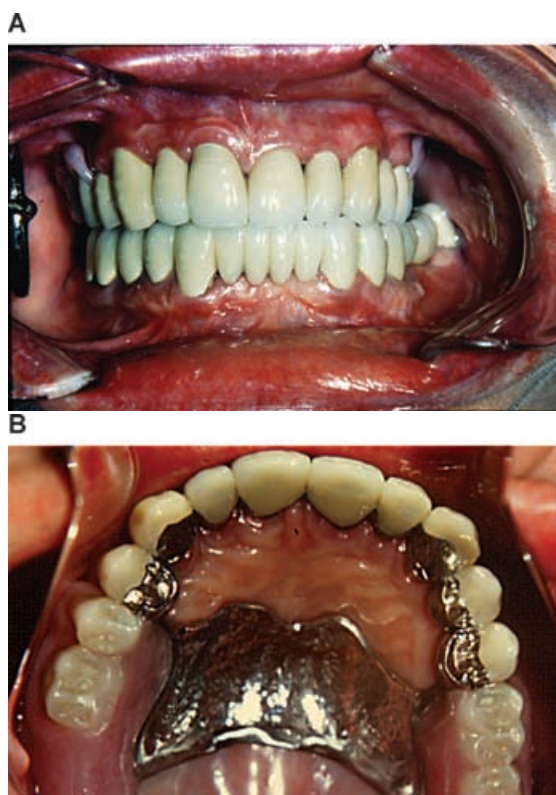


Figure 4. (A) Anterior view of the initial porcelain-fused-to-gold maxillary and mandibular fixed telescopic prostheses (1975). (B) Palatal view of the initial prosthesis demonstrating the design of the Kennedy Class I removable partial denture (1975).

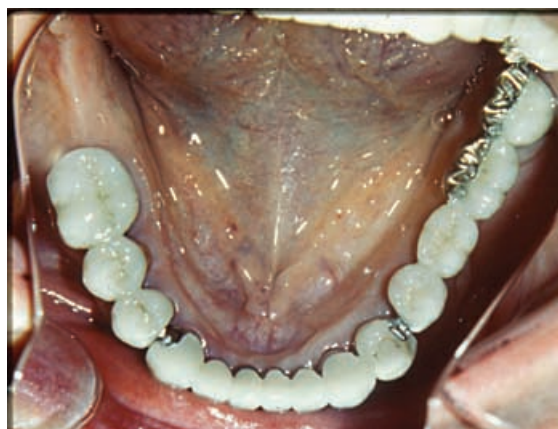

Figure 5. Occlusal view of the initial mandibular porcelain-fused-to-gold fixed telescopic prosthesis with precision attachments distal to the canine (1975).

telescopic overcasting fabricated in three sections. The nonrigid connectors were made with precision attachments (096 G/L Sterngold, Attleboro, MA).⁸ The three segments were connected at the distal surfaces of the canines (Fig 5). The mandibular treatment was completed in December 1975 and was followed monthly until the completion of the maxillary treatment in July 1976, at which time the patient was lost to follow-up until 1978.

Treatment 1978-1984

In 1978, the patient presented for recementation of the mandibular prosthesis. She was maintained with the same hygiene protocol used in prior visits for the next 2.5 years. In 1980, she returned when the mandibular left posterior abutment tooth presented with gingival inflammation and periodontal and intraradicular bone loss (tooth #30). The maxillary RPD received a chairside reline because of alveolar ridge atrophy. The patient was reluctant to pursue any additional treatment other than hygiene maintenance until 1984.

Treatment 1984-1994

In 1984, the patient presented with a fractured prosthesis (framework) in the mandibular left posterior segment. A new prosthesis was immediately constructed with intercoronal connectors, which had larger diameters.

In 1985, the patient returned with a loose maxillary prosthesis. The telescopic prosthesis was recemented, including the post and core in tooth



Figure 6. The maxillary telescopic porcelain/gold anterior splint had loosened and was contained within the maxillary RPD. The post and core for the maxillary left canine was nonretentive and required recementation (1985).

#11 (Fig 6). Heavy wear facets were noted on all the anterior teeth, as was severe bone loss indicative of chronic refractive periodontal disease.⁹⁻¹¹

The maxillary RPD was nonretentive. The patient also revealed that she was under significant professional stress.¹² It is the authors' observation and opinion that patients with high stress levels frequently present with destructive dental function and force patterns that lead to failure of both prosthetic materials and periodontal support.¹³

The new treatment plan for the maxilla included posterior dental implants for support and retention of artificial teeth that would eliminate the need for an RPD. Fixed restorations would minimize overloading the maxillary anterior natural dentition.¹⁴

The patient declined the recommended treatment, but returned in the spring of 1986 when severe occlusal wear prompted her to seek further evaluation and treatment. The occlusal wear was significant enough to perforate casting of the maxillary right first premolar (tooth #5). Tooth #7 was extracted due to advanced periodontal disease.

In May 1986, the patient accepted the treatment plan presented to her the previous year, calling for eight Brånemark implants in the maxilla. A surgical guide,¹⁵ was fabricated but was not used, resulting in a suboptimal implant (Brånemark System, Nobelpharma, Göteborg, Sweden) position in area #7.

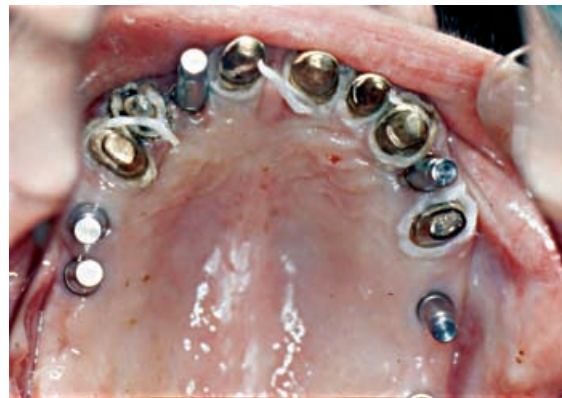

Figure 7. Occlusal view of maxillary preparations and implant impression copings in place prior to making the definitive impression (1987).

A two-stage 7-month surgical protocol was employed.¹⁶ At second-stage surgery, three 7-mm-long implants in the maxillary posterior segment were mobile, not considered to be osseointegrated, and removed. This observation coincides with Berman and Jaffin's report on short length machine surface implants.¹⁷ The remaining five implants were positioned to support a fixed porcelain-fused-to-gold prosthesis while retaining several natural tooth abutments^{18,19} from the previous reconstruction. This prosthesis would eliminate the need for the RPD. The combined implant-tooth-supported prosthesis was constructed in two sections; the segments were separated at the midline. Two implants supported the left section, and three supported the right section (Fig 7). An occlusal centric relation splint to be worn at night was constructed for the maxillary arch, because over a decade the patient demonstrated pronounced parafunctional habits.^{20,21}

Generalized periodontal deterioration was noted around the natural abutment teeth in both arches in 1987. The following year, a loose mandibular left overcasting prompted further treatment. Although increased pocket depths were recorded for all mandibular teeth, the splinted prosthesis remained stable. The maxillary implants remained stable; however, the natural abutment teeth exhibited clinical mobility (Fig 8).²²

In February 1989, the mandibular left prosthesis was loose, prompting treatment with three Brånemark implants in the area of the first molar and second bicuspid, because the natural

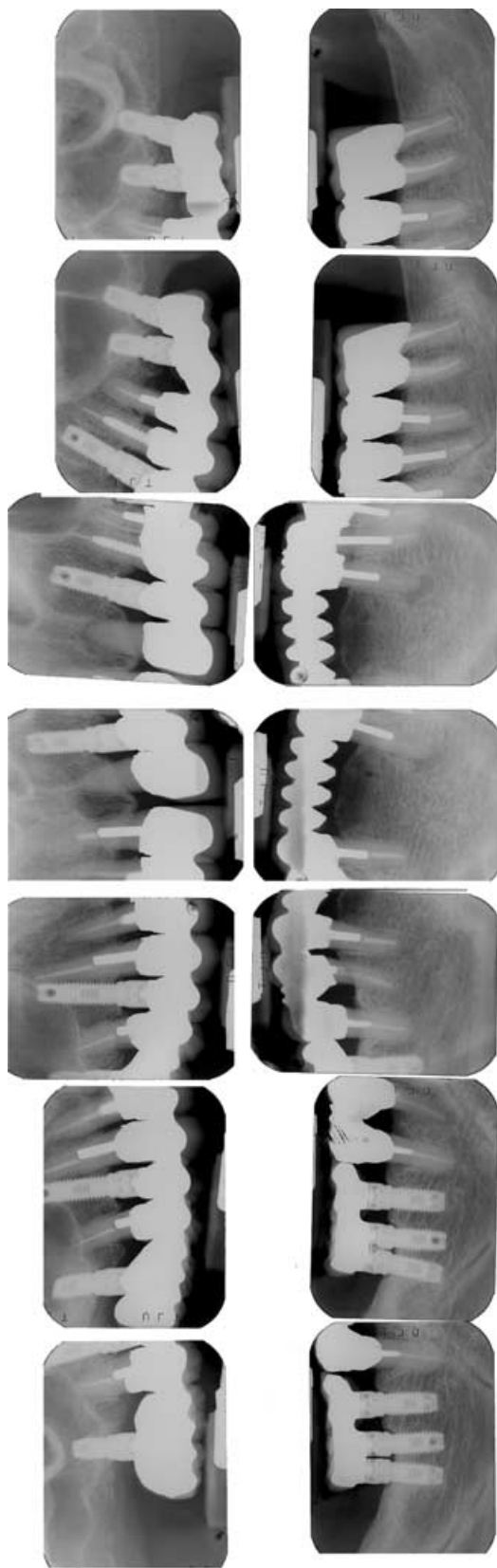


Figure 8. Intraoral radiographs showing the maxillary two-piece porcelain/gold fixed prosthesis supported by two implants on the left and three on the right (1988).

abutment teeth were periodontally hopeless. Two months later, additional bone loss was noted radiographically around teeth #20 and 21.

After a 4-month healing period, standard abutments were customized to accommodate converging implant angulations. A conversion prosthesis²³ was constructed, and the third molar (tooth #17) was extracted. A month later, the definitive prosthesis was delivered.

At the 4-month recall, no screw loosening was detected; however, the remaining natural dentition continued to suffer periodontal deterioration.

The patient was followed bimonthly in 1990 and 1991 with multiple periodontal maintenance and reevaluation visits. Recurrent cervical caries under the telescopic coping of the maxillary right central incisor was treated.

In February 1992, as part of a routine evaluation, the maxillary prosthesis was removed. Although all five implants remained stable, the abutment teeth had increased mobility, indicating disuse atrophy of the periodontal ligament as a result of no functional stimulation.²⁴

Treatment 1992-1994

In June 1992, the patient reported pain in the mandibular right posterior segment secondary to acute periodontitis. Two months later, the patient complained of a bad taste in the maxilla in the area of teeth #9 and 10. The maxillary prosthesis was again removed, and all abutment screws were found to be loose, indicating underengineering with insufficient implant support in a patient with parafunctional habits.²⁵ A new treatment plan for the maxilla was developed, prescribing additional implants and extraction of the natural teeth.

In August, two 15 mm × 3.75 mm Brånemark implants were placed in the pterygomaxillary area^{26,27} to eliminate posterior cantilevers and subsequent detrimental bending moments on the anterior implants.²⁷⁻²⁹ At the same time, four additional implants were placed into the anterior extraction sites in the areas of teeth #4, 8, 10, and 11 using the two-stage Brånemark protocol.

In January 1993, stage II surgery was completed, and all implants were found to be osseointegrated. The last remaining maxillary tooth (#9) was extracted. A conversion prosthesis²³ was used for 3 months, after which the final prosthesis was delivered. The patient was followed with 3-month recurring periodontal maintenance visits.

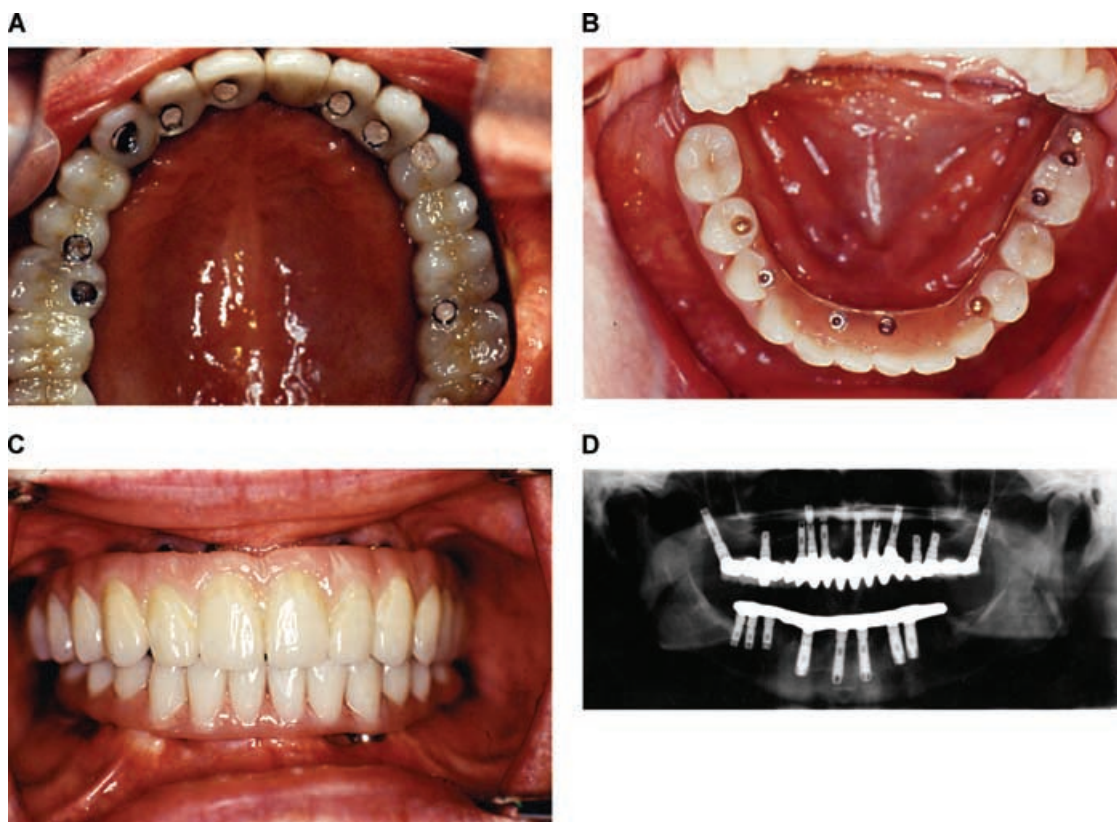


Figure 9. (A) Palatal view of maxillary fixed implant-supported prosthesis (1994). (B) Occlusal view of mandibular fixed implant-supported prosthesis (1994). (C) Anterior view of definitive maxillary and mandibular implant-supported prostheses (1994). (D) Panoramic radiograph with definitive prostheses in place (1994).

Advanced bone loss and periodontal inflammation were again noted in November 1993 around the remaining mandibular dentition. A new treatment plan was executed with the placement of six additional Brånemark implants into fresh extraction sites. After 3 months of healing, abutments were placed. Prior to loading, one implant in the right posterior mandible in type IV bone¹⁷ (site #31) did not osseointegrate and was removed. An acrylic resin denture tooth prosthesis supported by a type IV gold framework with screw retention was delivered in March 1994.

Both maxillary and mandibular prostheses at this stage were entirely retained and supported by implants (Fig 9).

Since that time, the patient has been conscientious about returning for clinical reevaluations and hygiene treatment. Her occlusion, implants, and peri-implant soft tissues have remained stable, with no oral pathology of any kind evident. Follow-up radiographs in 2005 indicate stability of

the alveolar bone in both dental arches (Fig 10). The implant-supported prostheses have enabled her to return to normal masticatory function.

Conclusion

The 30-year history of prosthodontic treatment for the patient described in this report illustrated

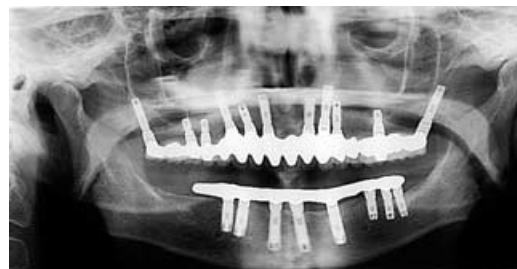

Figure 10. Panoramic radiograph with definitive prostheses in place (2005).

prosthodontic treatment concepts in use during this timeframe. The illustrated prosthodontic treatments exemplified the following principles: (1) the inadvisability of connecting natural teeth to osseointegrated implants when multiple implants were being used, (2) the incidence of failure associated with short (7 mm) machine surface parallel-sided screw-shaped implants in soft bone, and (3) that the patient was prosthetically transitioned from a combination fixed/removable reconstruction to a totally fixed screw-retained rehabilitation.

Acknowledgments

Dr. Ernest Mingledorff, mentor and former chairman of the Department of Prosthodontics, Temple University School of Dentistry, Philadelphia.

Periodontists Andy Albert, Brian Wall, Richard Cutler, and Alan Meltzer; oral/maxillofacial surgeons Fredrick Disque and James Gustainis.

Prosthodontist Irving Zamikoff for prosthetic maintenance and oral health follow-up care.

Special thanks to Robert Winkelman, CDT, MDT, and Robin Mongeon, Fort Washington Dental Lab Inc., for construction of the definitive prosthesis.

References

- Weinberg LA: Atlas of Removable Partial Denture Prosthodontics. St. Louis, MO, Mosby, 1969
- Yalisove IL, Dietz JB: Telescopic Prosthetic Therapy: Periodontal Prosthesis Fixed and Removable. Philadelphia, PA, George F Stickley Co., 1977
- Grieder A, Cinotti WR: Periodontal Prosthesis, vol 1, 2. St. Louis, MO, Mosby, 1968
- Kornfeld M: Mouth Rehabilitation: Clinical and Laboratory Procedures (ed 2). St. Louis, MO, 1974
- Kazis H, Kazis AJ: Complete Mouth Rehabilitation Through Crown and Bridge Prosthodontics. Philadelphia, PA, Lea & Febiger, 1956
- Shillingburg HT, Hobo S, Whitsett LD: Fundamental of Fixed Prosthodontics. Chicago, IL, Quintessence, 1976
- Preiskel HW: Precision Attachments in Dentistry (ed 2). St. Louis, MO, Mosby, 1973, pp 73
- Preiskel HW: Precision Attachments in Dentistry (ed 2). St. Louis, MO, Mosby, 1973, pp 44
- Grant D, Stern IB, Everett FG: Orban's Periodontics: A Concept—Theory and Practice (ed 2). St. Louis, MO, Mosby, 1963, pp 60-63
- Kerr DA, Ash MM, Millard HD: Oral Prognosis (ed 3). St. Louis, MO, Mosby, 1970, pp 182-186
- Goldman HM, Cohen DW: Periodontal Therapy (ed 5). St. Louis, MO, Mosby, 1973, pp 81-83
- Watson RM: The role of removable prostheses and implants in the restoration of the worn dentition. Eur J Prosthodont Restor Dent 1997;5:181-186
- Dawson PE: Evaluation, Diagnosis, and Treatment of Occlusal Problems. St. Louis, MO, Mosby, 1974, pp 169
- Balshi TJ: Osseointegration for the periodontally compromised patient. Int J Prosthodont 1988;1:51-58
- Balshi TJ, Garver DG: Surgical guidestents for placement of implants. J Oral Maxillofac Surg 1987;45:463-465
- Brånemark P-I, Zarb GA, Albrektsson T: Tissue-Integrated Prostheses, Osseointegration in Clinical Dentistry. Chicago, IL, Quintessence, 1987, pp 225-228
- Jaffin RA, Berman CL: The excessive loss of Brånemark fixtures in Type IV bone: a 5-year analysis. J Periodontol 1991;62:2-4
- Balshi TJ: Converting patients with periodontally hopeless teeth to osseointegration prostheses. Int J Periodontics Restorative Dent 1988;8:8-33
- Balshi TJ: Advantages and disadvantages of linking implants to the natural dentition. Oral Maxillofac Surg Clin North Am 1991;3:945-964
- Shore NA: Occlusal Equilibration and Temporomandibular Joint Dysfunction (ed 1). Philadelphia, PA, JB Lippincott, 1959, pp 130-131
- Dawson PE: Evaluation, Diagnosis, and Treatment of Occlusal Problems. St. Louis, MO, Mosby, 1974, pp 310
- Rieder CE, Parel SM: A survey of natural tooth abutment intrusion with implant-connected fixed partial dentures. Int J Periodontics Restorative Dent 1993;13:334-347
- Balshi TJ, Wolfinger GJ: Conversion prosthesis: a transitional fixed implant-supported prosthesis for an edentulous arch—a technical note. Int J Oral Maxillofac Implants 1996;11:106-111
- Krogh P: Anatomic and surgical considerations in the use of osseointegrated implants in the posterior maxilla. Oral Maxillofac Surg Clin North Am 1991;11:853-868
- Balshi TJ: Overload management of osseointegrated fixtures to achieve optimum bone remodeling through multistage prosthodontic loading. In: Laney WR, Tolman DE (eds). Tissue Integration in Oral, Orthopedic and Maxillofacial Reconstruction. Chicago, IL, Quintessence, 1992, pp 364-371
- Bahat O: Osseointegrated implants in the maxillary tuberosity: report of 45 consecutive patients. Int J Oral Maxillofac Implants 1992;7:459-467
- Balshi TJ: Preventing and resolving complications with osseointegrated implants. Dent Clin North Am 1989;33:821-868
- Balshi TJ, Lee HY, Hernandez RE: The use of pterygomaxillary implants in the partially edentulous patient: a preliminary report. Int J Oral Maxillofac Implants 1995;10:89-98
- Balshi TJ, Wolfinger GJ, Balshi SF 2nd: Analysis of 356 pterygomaxillary implants in edentulous arches for fixed prosthesis anchorage. Int J Oral Maxillofac Implants 1999;14:398-406

Copyright of Journal of Prosthodontics is the property of Blackwell Publishing Limited and its content may not be copied or emailed to multiple sites or posted to a listserv without the copyright holder's express written permission. However, users may print, download, or email articles for individual use.