

A Preliminary Survey of Impression Trays Used in the Fabrication of Fixed Indirect Restorations

Sonya T. Mitchell, DMD, MSHA, Merrie H. Ramp, DMD, MS, Lance C. Ramp, DMD, PhD, & Perng-Ru Liu, DDS, MS, DMD

Department of Comprehensive Dentistry, University of Alabama at Birmingham, Birmingham, AL

Keywords

Full single-arch tray; partial single-arch tray; full dual-arch tray; partial dual-arch tray.

Correspondence

Lance C. Ramp, Department of Comprehensive Dentistry, University of Alabama at Birmingham, 1919 7th Ave S., Birmingham, AL 35294. E-mail: lramp@uab.edu

Previously presented at the IADR/AADR/CADR 85th General Session and Exhibition (March 21–24, 2007).

Accepted September 8, 2008

doi: 10.1111/j.1532-849X.2009.00493.x

Abstract

Purpose: A variety of impression trays are used in the fabrication of fixed indirect restorations. Impressions used in the construction of fixed indirect restorations were examined for tray type, manner of use, and overall impression quality.

Materials and Methods: A commercial dental laboratory provided 1403 impressions used to fabricate fixed indirect restorations during a 3-month period. Impressions were examined for tray type, quantity and type of recorded abutments, the impression of intact teeth adjacent to and opposing the abutment, the presence of the canine in the impression, and an assessment of the quality of the impression.

Results: A majority of trays examined were plastic (864, or 61.6%). Dual-arch trays comprised 73.1% of the total. Most of these were metal posterior (n = 499) or plastic posterior (n = 280). Among partial dual-arch impressions, 561 (55.7%) were for the single abutment restoration, bounded by intact teeth anterior and posterior, and with an intact opposing tooth. Eleven percent of plastic dual-arch impressions failed to register the canine. Regarding restoration type, there were 955 impressions for the single-tooth crown, 46 for implant-supported restorations, and 11 for veneers. Twenty impressions were for posts, inlays, or onlays. Impressions for multiple single-tooth crowns and fixed partial dentures comprised the remainder. In terms of overall quality, 85.3% of impressions were excellent or good. The lowest performance in terms of excellent quality was in the anterior plastic single-arch impression (44.8%), whereas the best rate of excellent quality noted was for the posterior dual-arch impression (82.4%).

Conclusions: Within the limitations of this study, dual-arch trays were the most commonly used tray. Recommendations for the use of the dual-arch tray were not followed in a substantial number of impressions examined.

A variety of impression trays and techniques are available for use in the fabrication of fixed indirect restorations, each with advantages, disadvantages, and indications for use.^{1–5} Prefabricated metal or plastic stock trays may be used to record a full or partial arch. Traditionally, custom trays have been advocated for impressions used to fabricate fixed dental prostheses.^{5,6} Most investigations conclude that custom trays produce more accurate casts than stock trays, with variations related to tray quality and technique used.^{2,7–11}

The dual-arch impression is currently a popular impression method employing a prefabricated dual-arch tray. It is a closed-mouth technique that simultaneously records the abutment, opposing teeth, adjacent teeth, and the maximal intercuspal position.^{1–5} In selected cases, impressions made with dual-arch trays are a useful alternative to other methods and have been

shown to be accurate, to be comfortable to the patient, and to require less time and impression material.^{12,13}

Partial dual-arch trays do have published limitations restricting their use to posterior single abutments or short-span fixed dental prostheses.^{1–5} For optimal results, the abutment should be bounded anteriorly and posteriorly by intact dentition, with an intact antagonist.^{3,4} Ideally, the patient should possess a canine-protected articulation, an intact dentition (Bräley Class I), an Angle Class I occlusion, and an ability to close into maximum intercuspation without interference.^{3,4}

While many dentists appreciate the advantages of the dual-arch technique, some have questioned the accuracy of the dies and occlusion record generated from the dual-arch impression.^{11–19} Since the technique does not record contralateral dentition, unwanted lateral interferences may be incorporated into




Figure 1 Tray type and distribution.

*Trays returned to the dentist and not examined.

the restoration.¹²⁻¹⁴ This investigation surveyed impressions subsequent to the fabrication of fixed indirect restorations for tray type, manner of use, and overall impression quality.²⁰⁻²²

Materials and methods

A commercial dental laboratory provided impressions previously used in the fabrication of fixed indirect restorations over a 3-month period. The impressions were divided into eight groups according to tray type (Figs 1 and 2). At the time of the survey, the laboratory contributing the trays served approximately 50 dentists. A Certified Dental Technician owned the laboratory, which employed ten technicians, served dentists in multiple states, and performed only fixed dental prosthetic laboratory procedures. The laboratory fees were above average for the local area.

Impressions were examined by visual inspection to determine the quantity and description of the abutments recorded, the presence of an intact ipsilateral canine, and for dual-arch trays, adherence to usage guidelines proposed by Kaplowitz, (a single abutment, bounded by intact teeth anteriorly and posteriorly, with an intact opposing antagonist).^{3,4} These data were acquired by four calibrated investigators. An assessment of the quality of the impression was made based on the criteria of Beier *et al*²⁰ and listed below (Fig 3):

Excellent: No defects (voids, bubbles) and perfect reproduction of the abutment finish line.

Good: Minimal defects (≤ 2 mm) not involving the abutment finish line.

Poor: Larger defects (> 2 mm) or defects involving the abutment finish line.

For consistency, one investigator evaluated impression quality. For impressions with multiple abutments, impression defects noted in any abutment were sufficient to rate the entire

impression as less than excellent. There was no attempt to identify the cause of a defective impression, assess the quality of tray material used, or identify the tray by manufacturer. No selection or rejection criteria were imposed.

Results

Data were tabulated by frequency. Figure 1 designates group letter, tray type, and distribution. In all, 1403 impressions were examined. Table 1 shows the number of impressions (n) used in the fabrication of each restoration type and the percentage of each type of abutment recorded by tray type. With partial-arch impressions, it could not be ascertained if the abutments were for a fixed partial denture (FPD) or two surveyed crowns; thus, these categories were grouped.

Table 2 contains percentage data for adherence to dual-arch tray guidelines, registration of the ipsilateral canine, and impression quality. With respect to single-arch trays, no information was available regarding the opposing arch; the table relates the percentage of bounded, single abutments. No impressions without abutments to be restored were observed. All impressions consisted of poly(vinyl siloxane) or polyether material.

Full single-arch tray

Three hundred thirteen (22.3%) trays observed were plastic (group A), and the second most commonly used tray. No metal stock trays or custom trays were observed. Approximately, two-thirds of these impressions recorded multiple abutments, and 19.5% were poor quality. In 96 (30.7%) cases, these impressions recorded the bounded, single abutment.

Partial single-arch trays

Few anterior (29, or 2.1%) and posterior (35, or 2.5%) trays were observed (groups B and C). All were plastic. Among



Figure 2 Examples of tray type.

29 anterior impressions, 12 recorded the single abutment, and 31% were poor quality. All impressions registered the canine. Of 35 posterior impressions, one did not register the canine, and 31.4% were poor quality.

Full dual-arch tray

Full dual-arch trays (group D) represented 1.3% of the trays examined. All were plastic. Sixteen (88.8%) were used in recording multiple abutments. All registered the canine, and 16.7% were poor quality.

Partial dual-arch trays

The partial dual-arch tray constituted 71.8% ($n = 1008$) of all trays. One hundred eighty-nine (18.8%) were anterior plastic (group E), 280 (27.8%) were posterior plastic (group F), 40 (4%) were anterior metal (group G), and 499 (49.5%) were posterior metal (group H). In the anterior group, three impres-

sions failed to register the canine. One hundred twelve (14.3%) posterior trays failed to register the canine. Among anterior impressions, 22.3% were poor, and 9.1% of posterior impressions were poor.

Restorations to be fabricated

Nine hundred fifty-five (68.0%) impressions were made for the single-tooth crown, 46 (3.2%) for implant-supported restorations, and 11 (0.8%) for veneers. Twenty (1.4%) impressions were for posts, inlays, or onlays. The balance was primarily for multiple single-tooth restorations and FPDs.

Discussion

Full single-arch tray

The full single-arch tray is versatile with few limitations for use.⁵ All observed in this investigation were plastic. These

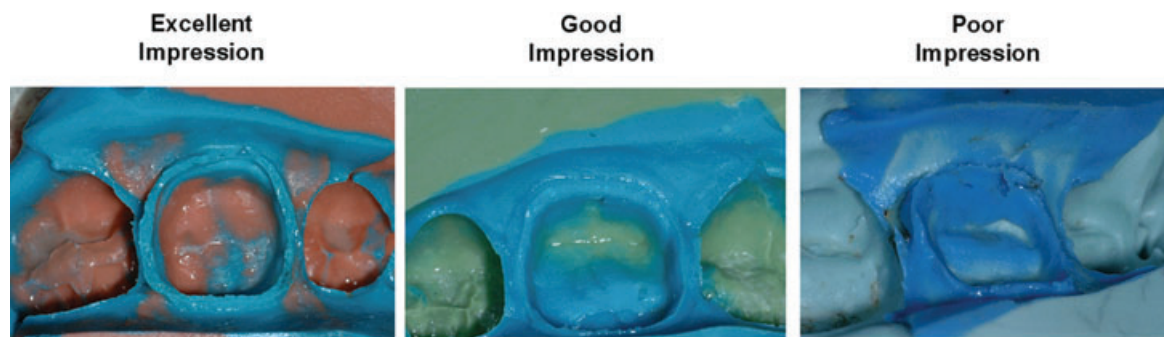


Figure 3 Examples of impression quality.

Table 1 Impression tray selection and restoration type

Tray type (see Fig 1)		A	B	C	D	E	F	G	H
Restoration	Trays (n)	Percentage of restorations fabricated per tray type							
Single crown	955	10.9	1.2	2.9	0.2	12.1	23.9	2.8	46.0
Multiple single crowns	254	40.9	4.3	1.6	1.6	20.1	13.4	3.9	14.2
Single veneer	5	80.0	0.0	0.0	0.0	20.0	0.0	0.0	0.0
Multiple single veneers	6	66.7	16.7	0.0	0.0	16.7	0.0	0.0	0.0
Implant-supported single crown	17	70.6	5.9	5.9	0.0	0.0	0.0	0.0	17.6
Implant-supported single crowns	1	0.0	0.0	0.0	100	0.0	0.0	0.0	0.0
FPD or surveyed crowns	117	55.6	5.1	1.7	8.5	6.8	10.3	1.7	10.3
Implant-supported FPD	28	35.7	0.0	0.0	7.1	32.1	14.3	0.0	10.7
Post	13	61.5	0.0	0.0	0.0	23.1	0.0	7.7	7.7
Onlay	1	0.0	0.0	0.0	0.0	0.0	0.0	0.0	100
Inlay	6	0.0	0.0	0.0	0.0	0.0	33.3	0.0	66.7

impressions recorded a bounded, single abutment in 30.7% of cases. For this group, it was not possible to evaluate the opposing arch.

The laboratory returned 171 additional assorted metal and 104 plastic trays to the dentists for reasons such as the desire to reuse the tray, and/or to assess the impression with respect to fabrication of the restoration. Assuming these were full single-arch trays, this tray would still account for fewer than half of all trays.

In the present investigation, no custom trays were examined or returned to the dentists. This finding was similar to that of Samet *et al*,²¹ who examined 193 impressions submitted from 11 dental laboratories. They observed one custom tray, 129 plastic trays (66.8%), and 63 (33%) metal trays. Winstanley *et al*,²² examining 290 impressions acquired from four dental laboratories in England, noted only three custom trays (which were made at a military facility). They also observed a substantial percentage (58%) of “flexible plastic” trays.

In addition to tray rigidity,⁷⁻¹⁰ one fundamental argument supporting the use of custom trays is to provide uniform thickness of impression material.⁶⁻¹⁰ Difficulties in actually achieving this relate to tray fabrication and tray orientation in the mouth.⁶ Other reported disadvantages of the custom tray are time and expense of fabrication.⁶

These results suggest less frequent use of the full single-arch plastic stock or custom trays in practice and the metal variety even less frequently than other tray types. In this investigation, the number of partial-arch impressions greatly exceeded the

full-arch impressions. This was particularly true of partial dual-arch impressions, which have several distinct advantages over the full single-arch method.^{11,13}

Lane *et al*,¹³ in a clinical trial comparing single crowns made using either a metal stock tray or a plastic dual-arch tray, found no differences in fit or occlusion of the restorations. They showed that the dual-arch technique was significantly faster and used one-half as much impression material. The dual-arch technique was easier for the operator and more comfortable for 80% of the patients, and they reported making their dual-arch impressions with a material specifically designed for use with the dual-arch tray. Parker *et al*¹¹ observed 12 times greater accuracy in the maximal intercuspal position with the dual-arch cast. Full single-arch trays are useful when fabricating multiple restorations when sufficient teeth would not be present in the dual-arch cast to provide guidance, when increasing vertical dimension, and for extensive restorations.¹¹

Partial single-arch trays

These trays comprised 4.6% of all trays, with multiple restorations fabricated from 62% of anterior impressions (group B). Thirty-one percent of the impressions were poor. Potential problems in using anterior trays are difficulty in mounting the casts due to unstable occlusal contacts and the ability to restore anterior guidance adequately.

Within the posterior trays (group C), only 21 of 35 (60%) impressions recorded the bounded, single abutment. Besides being

Table 2 Tray selection and impression criteria

Tray type (see Fig 1)	A	B	C	D	E	F	G	H	
Criteria (%)									Total
Canine not registered	0.0	0.0	2.9	0.0	0.5	10.4	5.0	16.6	8.3
Quality									
Excellent	73.5	44.8	45.7	55.6	73.0	82.5	52.5	82.4	76.3
Good	7.0	24.1	22.9	27.8	6.9	9.3	15.0	8.0	9.0
Poor	19.5	31.0	31.4	16.7	20.1	8.2	32.5	9.6	14.7
Single abutment, bounded, intact opposing	30.7	34.5	60.0	5.6	56.1	53.6	60.0	56.3	49.1

difficult to mount, the cast presents difficulties in determining the plane of occlusion and in correcting occlusal discrepancies.

As measured in this investigation, quality was not determined by tray type. The poor quality noted may relate to the presence of multiple abutments in a single impression, and to the smaller sample size in some groups with the likelihood that the specimens could have originated from a limited or single source. Particularly with anterior trays, poor impressions noted in this investigation may be attributable to subgingival finish lines.² Beier *et al*²⁰ examined 1466 abutment impressions from a group of 293 patients, observing that 96% of the impressions were good or excellent. They found adverse effects to quality when abutment finish lines were more than 2-mm subgingival.²⁰

Samet *et al*²¹ evaluated 193 impressions, reporting voids, bubbles, and marginal tears in approximately 150. Samet *et al*²¹ and Winstanley *et al*²² attributed impression errors to faulty handling of impression material, a lack of critical self-evaluation on the part of the dentist, and failure of the dentist to understand limitations of the trays employed.

Full dual-arch tray

A majority of these impressions (group D) recorded multiple abutments. One advantage of using this tray is that because the impression records both complete arches, the technician may better assess tooth anatomy and contour. The usefulness of this technique is limited when the casts are mounted on a simple hinge articulator.

Partial dual-arch trays

These impressions (groups E to H) comprised 71.8% ($n = 1008$) of all impressions. Seven hundred seventy-nine were posterior, and the metal posterior dual-arch tray (group H) was the most frequent (35.6%). The large number of posterior trays and overall good quality observed was probably because the single abutment restoration was the most commonly observed restoration type.

Ideally, when using this technique, the single abutment will be bounded by intact teeth and opposed by an intact tooth.^{3,4} Five hundred sixty-one impressions (55.7%) were used according to these guidelines. In addition, the canine should be registered. Requirements for using partial dual-arch trays preclude their use with the unbounded abutment, surveyed crown, or restorations restoring anterior guidance. Multiple abutments should be planned with caution.^{2,12}

Among anterior plastic tray impressions (group E), 68 (36%) were used for multiple restorations fabricated without an anterior guide table. Anterior metal tray impressions (group G) comprised a much smaller group (2.9%), with a relatively large number used to record multiple abutments. The reasons for the relatively low impression quality seen may be similar to those discussed earlier with respect to partial single-arch trays. Selection of anterior trays for use in fabrication of multiple restorations has little documentation in the scientific literature.

A number of dual-arch impressions were used for fabrication of FPDs (Table 1). While Davis and Schwartz¹² confirmed the potential of the posterior metal dual-arch tray in longer-span restorations, they recommended against this because of

possible occlusal instability and the potential for incorporation of noncentric contacts.¹²

Since most partial dual-arch impressions capture only five to seven paired teeth, multiple abutment preparations may increase the difficulty of maintaining cast stability. The presence of intact teeth anterior and posterior to the abutment as well as opposing the abutment better assures that the mounting is stable,¹ allows one to evaluate the occlusal plane and to develop the correct occlusal anatomy. Other concerns with using the partial dual-arch impression with multiple abutments are the ability of the technician to establish anatomic symmetry with the contralateral side and the accuracy of multiple dies produced.¹²⁻¹⁴

The presence of the canine in the cast allows the dental laboratory technician to better reproduce the patient's original occlusal scheme.^{3,4} Fourteen percent of posterior dual-arch impressions (groups F and H) did not register the canine, likely due to the size and shape of the tray selected. The anterior-posterior lengths noted in these trays ranged from 55 to 75 mm. The posterior dual-arch tray should extend distally to avoid interference to maximum intercuspation, while providing sufficient length to record the canine. Marking the canine position on the tray prior to making the impression assures canine registration and accurate anterior-posterior placement of the tray. If patient closure into maximum intercuspation is in doubt, an occlusion record should be made.^{3,4}

Casts constructed from the dual-arch impression should be attached to the articulator prior to separation from the impression,¹ eliminating the need for an occlusion record. In cases where there is no opposing occlusion, the primary advantage of recording the occlusion in a dynamic state is not realized. An intact opposing tooth creates the best opportunity to establish a fully functional occlusal relationship.

Four hundred sixty-nine dual-arch trays were plastic. In 1983, Wilson and Werrin¹ noted the importance of rigidity of the dual-arch tray.¹ They realized that certain impression materials could increase the overall rigidity of the tray/impression complex,⁴ and thus recommended using a stiff-bodied material. The dental laboratory procedure protocol of Wilson and Werrin¹ called for pouring of the counter impression first, followed by the working side. Since that time, the issue of tray flexibility has been debated and has been the subject of several investigations with mixed results. Most of the limitations to these studies depend upon the materials used and techniques employed.¹²⁻¹⁸

In 1991, Davis and Schwartz¹² published an *in vitro* investigation concluding that both metal and plastic dual-arch trays produced dies as accurately as custom trays. They reported using an addition silicone material, and reported pouring the working side cast first. The die dimensions produced with each tray type were within clinically acceptable limits; however, the plastic tray data showed that for intertooth measurements, plastic trays produced less accurate dies than did the metal dual-arch tray. These authors noted the potential for deformation of impression material along unsupported tray borders and distortion of the tray by impingement and suggested a preference for the metal tray.¹²

Later, Breeding and Dixon¹⁴ compared poly(vinyl siloxane) or polyether in both metal and plastic dual-arch trays, finding

differences they attributed to tray type but none related to impression material. They suggested that greater die distortion produced with plastic trays could result from unsupported borders of the plastic tray, or their pouring technique, wherein they only poured the side with the tooth preparation.

In a clinical pilot study, Cox *et al*¹⁵ determined that selection of impression material used with the dual-arch technique could be clinically significant. They observed that the combination of a flexible tray with heavy-bodied impression material produced larger discrepancies in interabutment and die dimensions than the custom tray or metal dual-arch tray. While metal and plastic dual-arch trays with putty-loaded impression material produced dies as accurate as those made with a custom tray, greater variability existed in die dimensions produced with the plastic trays. A common finding in their investigation was the “show-thru” of the sides of the tray, implying the possibility of tray flexure.¹⁵ Larson *et al*¹⁶ confirmed the potential for distortion of plastic trays when impingement of the tray occurred and recommended the use of the metal tray.¹⁶

Ceyhan *et al*¹⁷ compared the effects of an assortment of trays, impression materials, and sequence of pour on die dimensions. Using a monophasic material, they demonstrated that dies produced in plastic dual-arch trays were more variable in size when the working side was poured first, followed by the counter impression. Although these small differences probably would not be clinically significant,¹⁷ this finding seemed to substantiate the Wilson and Werrin¹ recommendation of pouring the opposing side of the dual-arch impression first, followed by the working side. Ceyhan *et al*¹⁸ agreed with Cox *et al*¹⁵ that a rigid tray/impression combination was to be preferred. Ceyhan *et al*¹⁸ observed that plastic trays produced dies equal to or superior to dies fabricated from metal trays, and that patients preferred the plastic tray. In an *in vitro* investigation using 3D analysis, Cayouette *et al*¹⁹ concluded that the custom tray impression was the most accurate technique. Their study ranked dual-arch plastic trays above the metal dual-arch in terms of accuracy and precision with the impression materials used. They found no differences related to pouring sequence.

While clinically acceptable restorations may be fabricated using the posterior plastic dual-arch tray,^{13,18} impressions made with the plastic tray are more susceptible to clinical and dental laboratory variables than impressions made with the rigid metal tray. Because concerns with flexure and poor support for the impression material continue to exist, Donovan and Chee² recommend avoiding “plastic-mesh” trays when employing the dual-arch technique.² Correct tray selection remains the clinical judgment of the dentist, but requires further research. Case selection, clinical technique and assessment, and dental laboratory procedures employed are critical elements relating to tray usage.

With respect to restoration type, the overwhelming majority of all impressions observed were made for the single-tooth crown. Several implant-supported restorations were fabricated using dual-arch impressions. Since conventional implant impression posts may prevent maximum intercuspation, these impressions used a short snap-on plastic impression coping.

The level of dentist training, schools of contributing dentists, and implications of these factors on the results could not be ascertained. One dental laboratory provided the impressions,

and no assessment of the quality of the laboratory work or final restorations could be made. Production for the 3-month period assessed is considered typical for the laboratory surveyed. The number of restorations made during this period requiring refabrication is unknown.

Most impressions were good or excellent in quality. Some poor quality impressions could be attributed to tearing of the margins during separation from the cast. Braley and Angle classification and the patient's ability to close could not be evaluated. Specific patient factors leading to tray selection could not be assessed. In many cases, it may be assumed that presumptive fabrication defects from incorrect tray selection could be corrected with judicious chairside adjustment. Future investigations on a larger scale are needed to determine if these results are specific to this laboratory.

Conclusions

Within the limitations of this study, these data lead to valuable conclusions with clinical significance:

1. The dual-arch impression was the most commonly used impression technique. The single-tooth crown was the most common restoration.
2. A substantial number of single-arch tray impressions recorded the bounded, single abutment.
3. Recommendations for use of the partial dual-arch tray were not followed in a number of cases. Further research and better understanding of the indications and limitations of these trays is needed.
4. The quality of impressions examined was higher in posterior dual-arch trays than for other tray types in this investigation.

References

1. Wilson EG, Werrin SR: Double arch impressions for simplified restorative dentistry. *J Prosthet Dent* 1983;49:198-202
2. Donovan TE, Chee WWL: A review of contemporary impression materials and techniques. *Dent Clin North Am* 2004;48:445-479
3. Kaplowitz GJ: Trouble-shooting dual-arch impressions. *J Am Dent Assoc* 1996;127:234-240
4. Kaplowitz GJ: Trouble-shooting dual arch impressions II. *J Am Dent Assoc* 1997;128:1277-1281
5. Rosensteel SF, Land MF, Fujimoto J (eds): *Contemporary Fixed Prosthodontics* (ed 4). St. Louis, MO, Mosby Elsevier, 2006, pp. 462
6. Bomberg TJ, Hatch RA, Hoffman W: Impression material thickness in stock and custom trays. *J Prosthet Dent* 1985;54:170-172
7. Gordon GE, Johnson GH, Drennon DG: The effect of tray selection on the accuracy of elastomeric impression materials. *J Prosthet Dent* 1990;63:12-15
8. Millstein P, Maya A, Segura C: Determining accuracy of stock and custom tray. *J Oral Rehabil* 1998;25:645-648
9. Martinez LJ, von Fraunhofer JA: The effects of custom tray material on the accuracy of master casts. *J Prosthodont* 1998;7:106-110
10. Thongthammachai S, Moore BK, Barco MT, *et al*: Dimensional accuracy of dental casts: influence of tray material, impression material, and time. *J Prosthodont* 2002;11:98-108

11. Parker MH, Cameron SM, Hughbanks JC, et al: Comparison of occlusal contacts in maximum intercuspation for two impression techniques. *J Prosthet Dent* 1997;78:255-259
12. Davis RD, Schwartz RS: Dual-arch and custom tray impression accuracy. *Am J Dent* 1991;4:89-92
13. Lane DA, Randall RC, Lane N, et al: A clinical trial to compare double-arch and complete-arch impression techniques in the provision of indirect restorations. *J Prosthet Dent* 2003;89:141-145
14. Breeding LC, Dixon DL: Accuracy of casts generated from dual-arch impressions. *J Prosthet Dent* 2000;84:403-407
15. Cox JR, Brandt RL, Hughes HJ: A clinical pilot study of the dimensional accuracy of double-arch and complete-arch impressions. *J Prosthet Dent* 2002;87:510-515
16. Larson TD, Nielsen MA, Brackett WW: The accuracy of dual-arch impressions: a pilot study. *J Prosthet Dent* 2002;87:625-627
17. Ceyhan JA, Johnson GH, Lepe X, et al: The effect of tray selection, viscosity of impression material, and sequence of pour on the accuracy of dies made from dual-arch impressions. *J Prosthet Dent* 2003;90:143-149
18. Ceyhan JA, Johnson GH, Lepe X, et al: A clinical study comparing the three-dimensional accuracy of a working die generated from two dual-arch trays and a complete-arch custom tray. *J Prosthet Dent* 2003;90:228-234
19. Cayouette MJ, Burgess JO, Jones RE, et al: Three-dimensional analysis of dual-arch impression trays. *Quintessence Int* 2003;34:189-198
20. Beier US, Grunert I, Kulmer S, et al: Quality of impressions using hydrophilic polyvinyl siloxane in a clinical study of 249 patients. *Int J Prosthodont* 2007;20:270-274
21. Samet N, Shohat M, Livny A, et al: A clinical evaluation of fixed partial denture impressions. *J Prosthet Dent* 2005;94:112-117
22. Winstanley RB, Carotte PV, Johnson A: The quality of impressions for crowns and bridges received at commercial dental laboratories. *Br Dent J* 1997;183:209-213

Copyright of Journal of Prosthodontics is the property of Blackwell Publishing Limited and its content may not be copied or emailed to multiple sites or posted to a listserv without the copyright holder's express written permission. However, users may print, download, or email articles for individual use.