

# Orthodontics Using an Occlusal Splint: A Clinical Report

Akit Patel, BDS, MClintDent (Prosthodontics), MFDS RCS (Eng),<sup>1</sup>

Christopher J. Tredwin, BDS, BSc, MSc, PhD, MFDS RCS (Eng), FDS (Rest Dent) RCS, FHEA,<sup>2</sup>

& Daljit S. Gill, BDS, BSc, MSc, FDS RCS(Eng), MOrth, Forth<sup>3</sup>

<sup>1</sup> Specialist Trainee in Prosthodontics, Unit of Prosthodontics, UCL Eastman Dental Institute, University College London, UK

<sup>2</sup> Senior Clinical Lecturer in Prosthodontics/Honorary Consultant in Restorative Dentistry, Unit of Prosthodontics, UCL Eastman Dental Institute, University College London, UK

<sup>3</sup> Consultant/Honorary Senior Lecturer in Orthodontics, Eastman Dental Hospital (UCLH NHS Foundation Trust)/UCL Eastman Dental Institute, London, UK

## Keywords

Occlusal splint; anterior guidance; orthodontic tooth movement; z-spring; orthodontic-restorative; PDI Class IV dentate patient.

## Correspondence

Christopher Tredwin, Unit of Prosthodontics, UCL Eastman Dental Institute, University College London, 256 Grays Inn Rd., London WC1X 8LD, UK. E-mail: c.tredwin@eastman.ucl.ac.uk

## Abstract

Careful management of the occlusion is necessary for successful prosthodontic treatment. A reorganized occlusal approach requires a more accurate registration of the desired jaw position, and where it is difficult to achieve this, an occlusal splint is indicated. This clinical report documents a 60-year-old man with a Prosthodontic Diagnostic Index Class IV dentition, who prior to a full-mouth reconstruction, underwent occlusal splint therapy with a Michigan-type splint that incorporated z-springs to allow concurrent orthodontic tooth movement of two anterior teeth to positions that would allow favorable restorations by correcting occlusal and esthetic form.

Accepted: February 26, 2009

doi: 10.1111/j.1532-849X.2009.00543.x

An occlusal splint or device is a removable artificial occlusal surface used for diagnosis or therapy, affecting the relationship of the mandible to the maxilla.<sup>1</sup> Varying in its design, the most commonly used is the stabilization or Michigan-type splint as described by Ramfjord and Ash.<sup>2</sup> Its role is mainly as a preventive and diagnostic appliance, used in circumstances such as preventing wear of the dentition, protection of restorations, treatment of temporomandibular disorders, pre-restorative stabilization, distribution of occlusal forces, and stabilization of unopposed or hypermobile teeth. Clinical research demonstrates the efficacy of its use.<sup>3-7</sup>

The purpose of occlusal treatment is to make teeth conform to a correct skeletal position of the condylar axis. Determining this axis, and thereby the retruded position of the mandible when reorganizing the occlusion, is important before embarking on any restorative therapy. Diagnostically and therapeutically, an occlusal splint "breaks" proprioceptive learned muscle patterns, causing their immediate and pronounced relaxation, repositioning the mandible until the correct condylar axis position can be determined and confirmed.

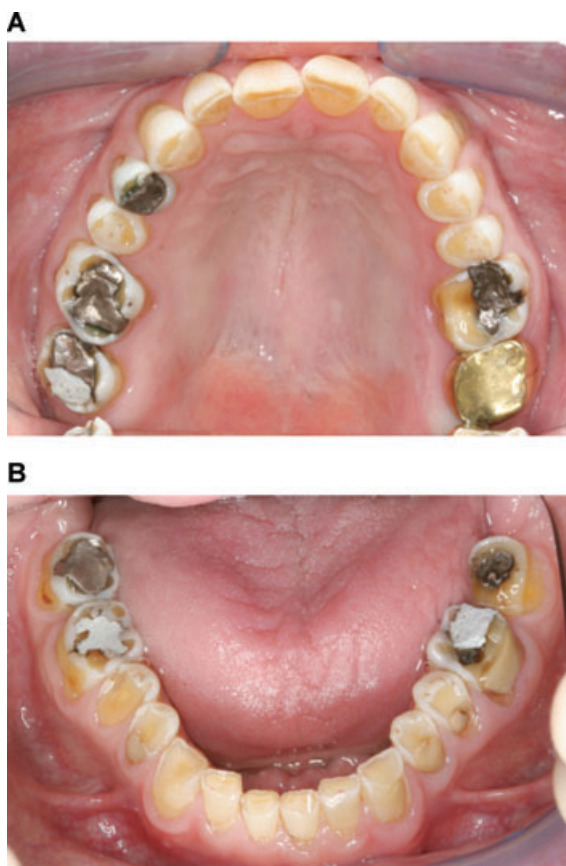
In accordance with most current occlusal philosophies, the stabilization splint provides an idealized biological occlusion with posterior support and anterior guidance. This is accomplished initially by having point contacts on all the teeth. On any excursive movement, anterior palatal ramps with shall-

ow gentle to steep inclines, allow immediate disclusion of the posterior teeth. Restorative convenience follows a similar approach, which seems logical for muscle and load distribution. Many factors, including the vertical and anterior-posterior jaw relations, the level of vertical and horizontal overlap of the anterior teeth as well as their shape, incisal position, and palatal contours, determine the form of anterior guidance. The aim is to establish a pattern of guidance within the envelope of function and motion to which the patient can successfully adapt, and also to achieve the required esthetics and phonetics.

This clinical report describes a combined approach to improve esthetics and anterior occlusal form (and hence factors determining anterior guidance) of a maxillary incisor and canine, in a severely worn dentition, with the use of a Michigan-type splint with integral orthodontic springs. This is a unique way to set the case for restorative care without the expense of any destructive preparatory treatment and offers a fast, acceptable alternative for the patient.

## Clinical report

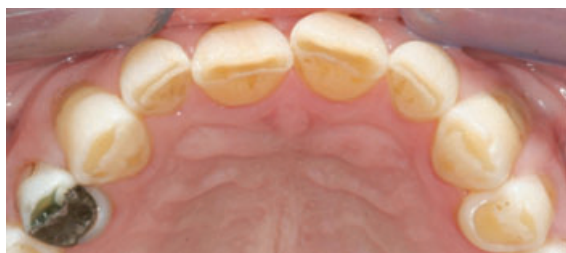The patient presented to the Eastman Dental Hospital, London with concerns regarding his level of tooth wear, gingival appearance, and episodes of dentine sensitivity. These primary



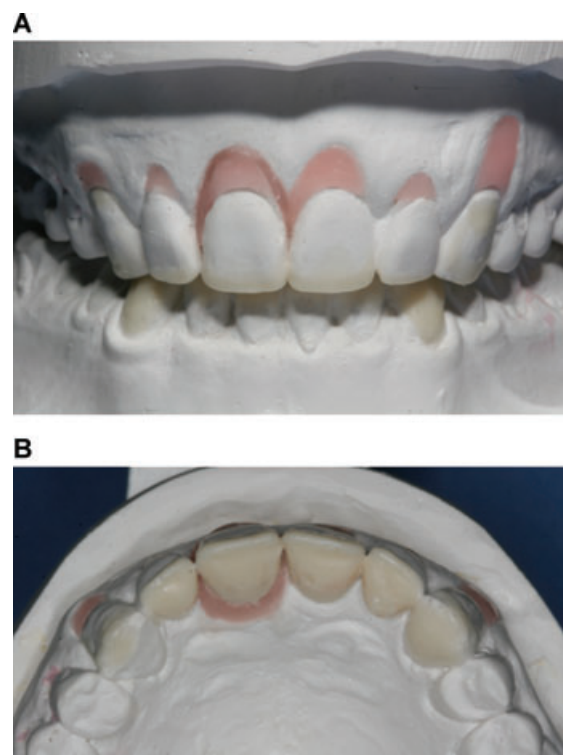
**Figure 1** (A) Maxillary. (B) Mandibular arches (occlusal views).

issues were addressed with a new oral hygiene regime and topical fluoride therapy for sensitive exposed dentine areas. Several posterior teeth were investigated, and caries was stabilized while a cause for the tooth wear was investigated.

On clinical examination, the patient was classified as Class IV according to the Prosthodontic Diagnostic Index (PDI).<sup>8</sup> The maxillary arch was noted to be fairly well aligned with a slightly palatally positioned upper right central incisor and signs of severe generalized tooth surface loss with loss of occlusal stability and shape (Figs 1 and 2). Analysis of the occlusion on the articulator following retruded mounting of diagnostic casts, showed the retruded contact on the upper and lower right first molars with minimal vertical and horizontal slide to the



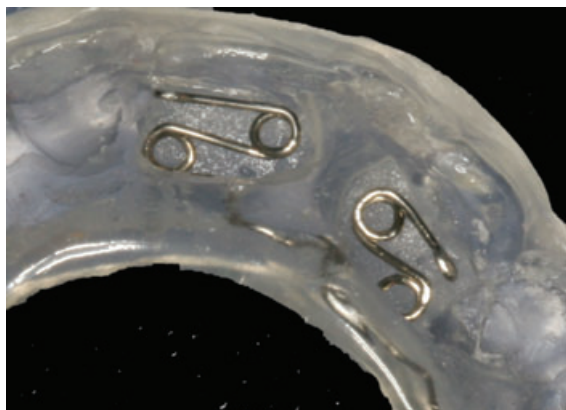**Figure 2** Maxillary (occlusal view) anterior teeth showing palatally positioned number 11.



**Figure 3** (A) Diagnostic set-up of number 11. (B) Wax-up of anterior teeth.

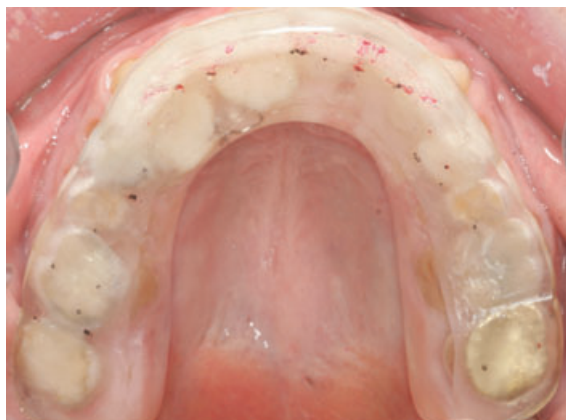patient's current intercuspal position. The incisal relationship was classed as Class III with a reduced overbite, and a shallow anterior guidance was anticipated, especially when the occlusal vertical dimension (OVD) was increased. The reduction in overjet in the region of the upper right central incisor and canine did not allow for favorable anterior guiding contours and presented potential risks for these teeth becoming interferences in occlusion. It would also mean heavy preparation of palatal aspects of these teeth to create space for any palatal indirect restorations.

To ensure a true retruded diagnostic jaw registration prior to complex restorative intervention, a hard acrylic Michigan-type splint was planned. To help with esthetic correction of the palatally positioned central incisor and to provide a functional horizontal overlap at the proposed OVD for anterior guiding concavity, as well as space created to restore worn palatal surfaces (also achievable by splint therapy alone by repositioning of the mandible distally), the axial inclination of the upper right incisor and canine would be corrected by orthodontic tooth movement at the same time as splint therapy. This not only reduced clinical treatment time but allowed assessment of patient compliance. An orthodontic set-up of these teeth and an anterior diagnostic wax-up was carried out to determine final positioning and how much horizontal space was required for sufficient anterior guidance at an increased OVD (Fig 3). A mock try-in was tested in the mouth using a self-cure polymerizing resin (Dentsply International, Inc., York, PA). To tilt these two teeth, z-springs would be used to procline the central incisor and canine.

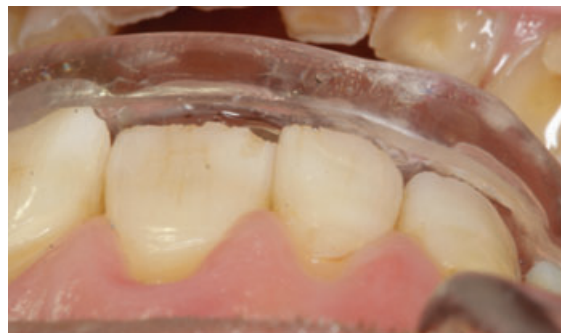

**Figure 4** Fitting surface of occlusal splint with attached z-springs prior to activation.

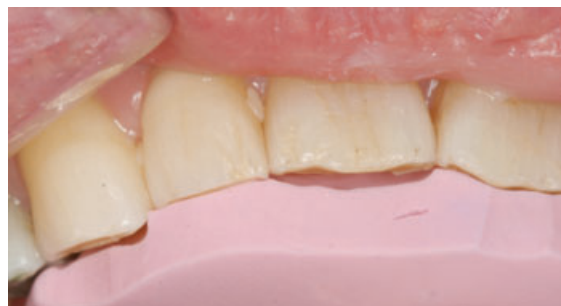On an articulated maxillary cast (Waterpik Technologies, Inc., Pittsburgh, PA; British Gypsum Ltd., Nottingham, UK), two z-springs were formed in 0.5-mm diameter stainless steel wire (K. C. Smith & Co., Potters Bar, Herts, UK) and waxed onto the palatal surfaces of the upper right central incisor and canine teeth. The splint was then waxed in baseplate wax (Tenatex, Kemdent, Swindon, Wiltshire, UK) to achieve the theoretically ideal occlusal scheme at the proposed recorded vertical dimension. The wax extended 3 mm onto palatal soft tissues and about 1 mm over the buccal and labial cusps. The occlusal aspect was modified carefully by functional waxing to create a flat occlusal wax surface to produce even point contacts with all the opposing teeth. A shallow, smooth wax pattern was built up in the anterior region to provide immediate disclusion of the posterior teeth on lateral and protrusive excursions. A shelf was extended posteriorly to the incisal tip contacts by about 1.5 mm to allow for possible subsequent mandibular repositioning. The cast was invested in a flask using a capping technique and the wax was boiled out, packed, and processed with a heat-cured clear acrylic resin (Lucitone 199, Dentsply International Inc.). Following deflasking, the cast was reattached to its split mount-



**Figure 5** Adjusted occlusal splint with idealized occlusal scheme marked (occlusal view).



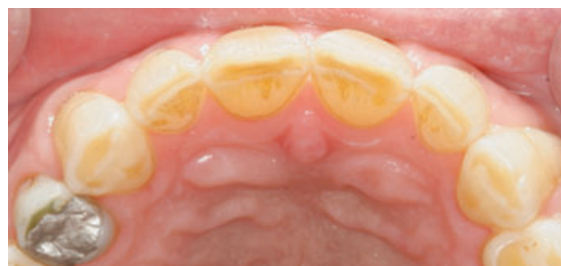**Figure 6** Lateral view of splint showing unrestricted space for number 11 and 13, to move.



**Figure 7** Final tooth position of number 11 and 13, (anterior-palatal view) labial to their pre-orthodontic movement as shown by a silicone putty index.

ing, and the occlusal surface was checked, devested for final finishing, and ready for fit (Fig 4).

Proximal enamel stripping was carried out with abrasive strips (3M EPSE, St Paul, MN) adjacent to the incisor and canine, and the z-springs were activated with orthodontic Adams pliers. The maxillary splint was fitted and checked for its retention and correct occlusal objective (Figs 5 and 6). The splint was adjusted labially and around the incisor and canine teeth to allow for unhindered orthodontic movement. The patient was instructed to wear the appliance during the night, preferably all day as well, and reviewed on a weekly basis for occlusal readjustment and every two weeks to reactivate z-springs by pulling them downward and forwards in the direction of desired tooth movement.



**Figure 8** Maxillary (occlusal view) of anterior teeth showing orthodontically corrected position of number 11 and 13.

A stable relationship was achieved orthodontically and restoratively after 5 months, when occlusal contact markings on the splint remained unchanged for two successive visits, and the final esthetic outcome was achieved as pre-determined by the diagnostic set-up (Figs 7 and 8). Stabilization of the occlusion on the splint was followed by new accurate mounting of diagnostic casts in the new maxillomandibular relationship.

## Discussion

It is often helpful when treating extensively failed dentitions to reposition teeth orthodontically to help in planning the final occlusal scheme. This occlusal appliance allowed for stabilization of the occlusion, and hence maxillomandibular jaw position, while simple orthodontic movements were being carried out. In this clinical report, the removable appliance only allowed for simple tooth movement where the upper right central incisor and canine teeth were proclined without controlling the root position. Bodily tooth movement is not possible with removable appliances and requires a fixed appliance approach. An accurate diagnosis, which must include determination of the retruded position, diagnostic tooth positioning on duplicate diagnostic casts, and assessing patient compliance with any initial restorative therapy, is essential before prescribing orthodontic treatment. Although it is helpful to seek the assistance of an or-

thodontist, simple orthodontic therapy can be carried out by the prosthodontist. This simplifies care to a single clinician, allows for a reduction in cost and time, and is a conservative option in management of the occlusion with integral orthodontic movement.

## References

1. Glossary of prosthodontic terms. *J Prosthet Dent* 2005;94:10-92
2. Ramfjord SP, Ash MM: Occlusion. Philadelphia, Saunders, 1966
3. Beard CC, Clayton JA: Effects of occlusal splint therapy on TMJ dysfunctions. *J Prosthet Dent* 1980;44:324-335
4. Capp N: Occlusion and splint therapy. *Br Dent J* 1999;186:217-222
5. Carossa S, Di Bari E, Lombardi M, et al: A graphic evaluation of the intermaxillary relationship before and after therapy with the Michigan splint. *J Prosthet Dent* 1990;63:586-592
6. Solberg WK, Clark GT, Rugh JD: Nocturnal electromyographic evaluation of bruxism patients undergoing short-term splint therapy. *J Oral Rehab* 1975;12:215-223
7. Wassell RW, Steele JG, Welsh G: Considerations when planning occlusal rehabilitation: a review of the literature. *Int Dent J* 1998;48:571-581
8. McGarry TJ, Nimmo A, Skiba JF, et al: Classification system for the completely dentate patient. *J Prosthodont* 2004;13:73-82

Copyright of Journal of Prosthodontics is the property of Blackwell Publishing Limited and its content may not be copied or emailed to multiple sites or posted to a listserv without the copyright holder's express written permission. However, users may print, download, or email articles for individual use.