

Digital Image Capture and Rapid Prototyping of the Maxillofacial Defect

Jennifer V. Sabol, DDS, MS,¹ Gerald T. Grant, DMD, MS,² Peter Liacouras, PhD, MS,³ & Stephen Rouse, DDS³

¹ Department of Prosthodontics, Walter Reed Army Medical Center, Washington, DC

² Department of Maxillofacial Prosthetics, National Naval Medical Center, Bethesda, MD

³ Department of 3D Modeling, Walter Reed Army Medical Center, Washington, DC

Keywords

Moulage; stereolithography; 3dMDface.

Correspondence

Jennifer V. Sabol, Department of Prosthodontics, Walter Reed Army Medical Center, 6900 Georgia Ave, NW Washington, DC 20307. E-mail: jsabol1019@hotmail.com

Previously presented at the American Academy of Maxillofacial Prosthetics, 55th Annual Meeting, Scottsdale, AZ, October 2007

Supported in part by the National Naval Medical Center, Bethesda, MD

The views expressed in this article are those of the author and do not necessarily reflect the official policy or position of the Department of the Navy, Department of the Army, Department of Defense, nor the U.S. Government.

Accepted August 18, 2010

doi: 10.1111/j.1532-849X.2011.00701.x

Abstract

In order to restore an extraoral maxillofacial defect, a moulage impression is commonly made with traditional impression materials. This technique has some disadvantages, including distortion of the site due to the weight of the impression material, changes in tissue location with modifications of the patient position, and the length of time and discomfort for the patient due to the impression procedure and materials used. The use of the commercially available 3dMDface™ System creates 3D images of soft tissues to form an anatomically accurate 3D surface image. Rapid prototyping converts the virtual designs from the 3dMDface™ System into a physical model by converting the data to a ZPrint (ZPR) CAD format file and a stereolithography (STL) file. The data, in conjunction with a Zprinter® 450 or a Stereolithography Apparatus (SLA), can be used to fabricate a model for prosthesis fabrication, without the disadvantages of the standard moulage technique. This article reviews this technique and how it can be applied to maxillofacial prosthetics.

Stereolithography (STL) for the fabrication of prostheses has been used with success for more than two decades. Commonly, data obtained from computerized tomography (CT) or magnetic resonance imaging (MRI) have been used to create images that can be used not only for treatment planning but also for the fabrication of implantable material.^{1,2} This has been successful when considering treatment for neoplasms, congenital and developmental defects, or trauma.³ However, these images are usually of the hard tissues, and do not capture the soft tissue detail and contour required to fabricate a facial prosthesis. To restore an extraoral maxillofacial defect, a moulage technique is commonly used with traditional impression materials. The resultant cast often exhibits distortions due to the patient position and weight of the impression materials. The amount of time necessary to make the impression, as well as subsequent vis-

its required to locate ocular positions and make modifications to compensate for distortion of materials are other problems associated with this technique.

Recent advances in digital technology have resulted in systems using 3D photography to capture an image. This type of photography has recently become popular in the plastic surgery community for medical evaluations and records. The commercially available 3dMDface™ System (3dMD, Atlanta, GA) creates images of soft tissues to form an anatomically accurate 3D surface image.⁴⁻⁷ Three-dimensional surface images can be used to evaluate the external surface of the patient, as opposed to the information obtained from a CT scan.⁸ The image is captured with patients in a more natural position, with their eyes open, and is not an invasive or an uncomfortable procedure. It takes approximately 1.5 ms to capture the image.⁹



Figure 1 – 3dMDface™ System.



Figure 2 Patient seated at 3dMDface™.

Geometrically, the cameras form a continuous point cloud from two stereo camera viewpoints, and the information acquired is used to produce a wire diagram used in the manufacture of 3D models.⁹ To date, there is no literature demonstrating the use of the 3dMDface™ System to fabricate a 3D model for a facial prosthesis (Fig 1).

Case presentation

This case presentation demonstrates the use of a 3D image capture device (3dMDface™) in the fabrication of a facial prosthesis. An 80-year-old female patient presented to the clinic with a chief complaint that she needed a new facial prosthesis, but she was apprehensive about having another facial impression made. The patient had a history of adenoid cystic carcinoma to her ethmoid and left maxillary sinus, diagnosed in 1986. Her treatment consisted of surgical removal of the left maxilla, the left orbit, and surrounding soft tissue, followed by neutron beam radiation treatment. She is currently free of any pathology. The resultant defect provided minimal retention for an adhesive-retained extraoral restoration, with a small unsupported “band” of tissue from the left ala of the nose to the lateral maxillary area to include the left upper lip area. She has been success-

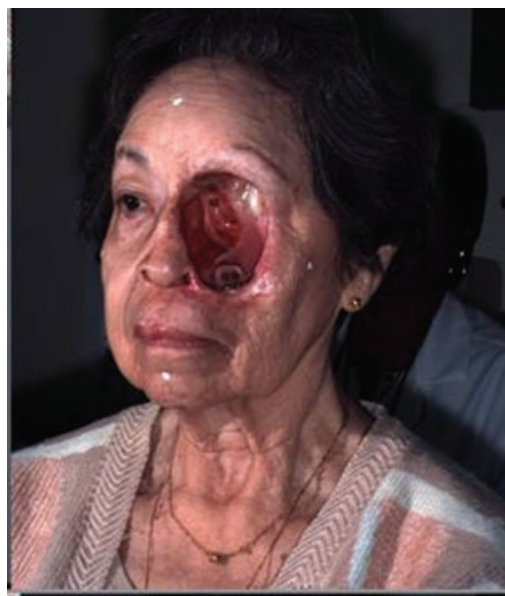

Figure 3 Picture of patient taken with 3dMDface™.

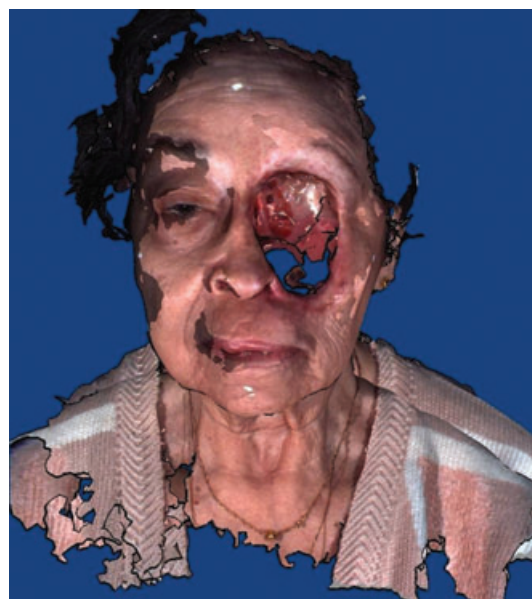

Figure 4 Altered photo frontal position.

fully restored in the past with a combination of obturator/facial prosthesis using magnet retention.

Procedure for image capture

Due to the patient's apprehension of a conventional mouldage technique, a novel 3D image capture system was used to provide a solution for a computer-aided design (CAD) mouldage. The 3dMDface™ System was calibrated as per the manufacturer's instructions for the combined camera/flash pods for synchronization and light balance. Although the total depth of the defect

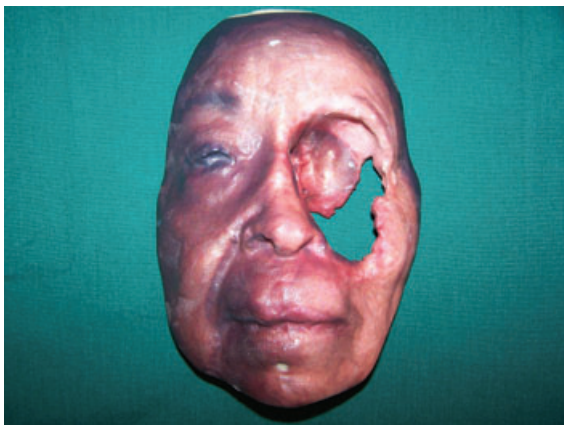

Figure 5 Color model made with the ZPrinter[®] 450 and high performance composite material.

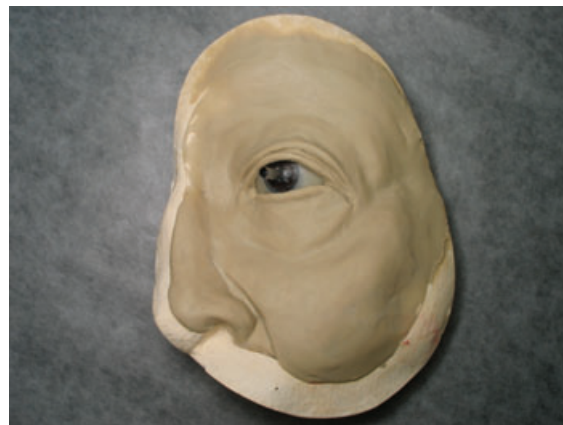

Figure 7 Clay sculpture on model.



Figure 6 Clear model made with the SLA 7000 and UV light-activated epoxy resin.

would not be used in the fabrication of the prosthesis, some of the undercut areas were desirable for retention. The patient was seated in an upright position with her obturator in place. She was oriented to face between the two camera tripods ensuring that the margins of the defect were visible in the computer windows and the image was captured. Another image was made orienting the patient to capture the undercut, just inferior to the superior orbital rim, and another set of images was made to capture the lateral walls of the medial aspects of the defect. The images were reconstructed and imported into the 3dMD patient software. The composite data were stored in a format to fabricate a rapid prototype model (Figs 2-4).

Procedure for model fabrication

The 3dMD files were exported as a Virtual Reality Modeling Language (VRML) file. The VRML files were imported into Magics version 12.01 (Materialise, Ann Arbor, MI) with an accuracy of 0.0250 mm, with colors and textures. Any artifacts, such as holes or sharp triangular edges, were manually removed from the computational file.

The patient's face was computationally cut from the VRML file perpendicular to the screen, viewing the face sagittally, thus

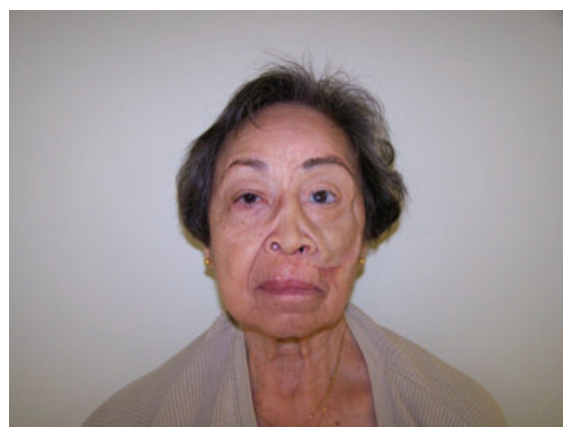


Figure 8 Patient and final prosthesis without glasses.

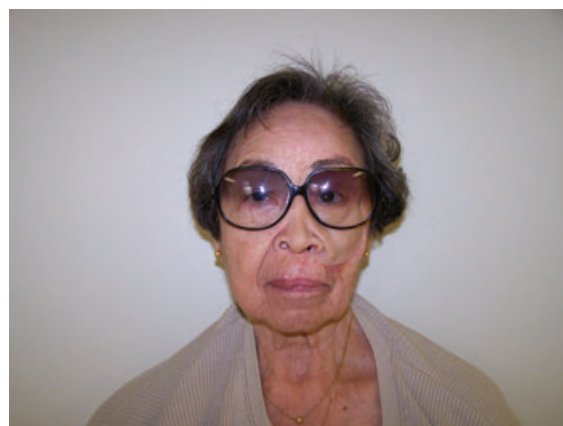


Figure 9 Patient and final prosthesis with glasses.

creating a solid file. The "Hollow Part" feature was used to make the model 3-mm thick internally. The posterior portion of the model was then cut off for rapid prototyping purposes. The image was then saved as a ZPrint (ZPR) CAD format file and an STL file. The two formats allow for two types of models

to be fabricated, based on the rapid prototyping machine being used.

The ZPR file was rapid prototyped on a Zprinter[®] 450 (Z Corporation, Burlington, MA) using zb59 binder and zp130 powder, printing layer by layer at 0.004-inch increments. After printing, the model was excavated from the build chamber's bed of powder, and excess powder was removed with a gentle stream of compressed air. After the model was thoroughly dried and cleansed of residual powder, it was infiltrated with RP Binder XL (VA Solutions, Port Washington, WI), a cyanoacrylate solution.

The STL File was processed on a build platform using Light Year, and was rapid prototyped using an SLA 7000, a Stereolithography Apparatus (3D Systems, Rock Hill, SC). Three-dimensional Systems resin, SI40, was locally cured using a UV laser, layer by layer in the Z-direction at 0.125-mm increments. The model was drained, washed in Tripropylene Glycol Monomethyl Ether (TPM), rinsed in water, and dried. Supports were stripped from the model, followed by the model being postcured (Post Curing Apparatus, 3D Systems) (Figs 5 and 6).

Procedure for prosthesis fabrication

Once the RP model was obtained, the approximate borders of the proposed prosthesis were outlined and duplicated with SternTek[®] Duplicating Material (SternGold Dental, LLC, Attleboro, MA). The duplication was poured in Type 4 stone (Prep-Stone[™] Ivory, ETI Empire Direct, Anaheim, CA) and was used as the master cast for prosthesis fabrication. A pressure-formed biocryl stent (Great Lakes Orthodontics, Ltd., Tonawanda, NY) was made to act as a carrier for the sculpting material, to index the ocular placement, to index the magnets to the obturator, and to verify the margins of the defect. Using clay and a previously fabricated ocular prosthesis, the gaze was set and indexed on the master cast, and the contour and details were finalized on the original RP model in clay and verified on the patient. A stone mold was created, the clay was removed, and the mold was cleansed of any residue. A blend of 70% MDX4-4210 (Silastic[®] Dow Corning Corp, Midland, MI) and 30% Medical Adhesive Silicone Type A (Silastic[®] Dow Corning Corp) was pigmented to match the patient. The magnets were fixed in an acrylic housing using Velcro strips for retention to the silicone. The mold was packed using a polyurethane liner. Extrinsic characterization, eyelashes, and an eyebrow were placed after processing. Retention for the prostheses was provided by the use of magnets attached to a well-fitting maxillary obturator the patient currently had (Figs 7-9).

Discussion

The connection between computers and medicine is becoming more and more intertwined. With the development of computer-aided design/computer-aided manufacturing (CAD/CAM) technology, data obtained from CT scans or MRIs have been invaluable for use in medicine. Digital photography allows for another mode of data acquisition, obtaining surface information and detail.

An STL model and a 3D printed model were available for fabrication by the technicians. There were no appreciable differences in the fit of the final prosthesis to either as a master cast; however, the technicians felt it was easier to discern the contours and margins of the defect on the printed color model than the STL model, which exhibited some extra contouring due to the layering effect.

There are some limitations to this type of technology. Generally, these systems are expensive, as they include the camera systems for 3D capture, the software for CAD, and the costs of the CAM equipment. Another limitation[®] is the color matching for the model made from the Zprinter[®] 450. Currently, the color does not match natural skin tones. This avenue needs to be pursued further. If a patient has an intraoral prosthesis that affects the contours of the skin, the patient must wear it for the photo. This may necessitate fabrication of the intraoral prosthesis before the images can be captured. Lastly, this method may not be indicated when tissue is lacking in tone, so it must be supported. A two-stage impression may be more useful in order to have proper orientation of the tissue in question.

Conclusion

A 3D photographic image capture is a viable moulage technique for fabricating an extraoral maxillofacial prosthesis. The advantages of this technique include less discomfort for the patient and no distortion from conventional impression materials or patient position. In less than a second, data are available for fabrication of a model that can be used to fabricate a prosthesis. This is in contrast to the time involved when making an impression and the vast armamentarium required to do so. Color models can provide shading, contours, and an open-eye position, which are not available with conventional moulage impression techniques; however, there are limitations in color matching. As advances in technology continue, less time will be required by the patient during the fabrication procedure. Model color match should improve, allowing for improved matching of the prosthesis to the patient when the patient is not present. This type of CAD/CAM technology can offer the practitioner and patient an improved method for fabrication, as well as improved fit of the prosthesis.

References

1. Santler G, Kärcher H, Gaggli A, et al: Stereolithography versus milled three-dimensional models: comparison of production method, indication, and accuracy. *Comput Aided Surg* 1998;3:248-256
2. de Zélicourt D, Pekkan K, Kitajima H, et al: Single-step stereolithography of complex anatomical models for optical flow measurements. *J Biomech Eng* 2005;127: 204-207
3. Powers DB, Edgin WA, Tabatchnick L: Stereolithography: a historical review and indications for use in the management of trauma. *J Craniomaxillofac Trauma* 1998;4:16-23
4. Lübbers HT, Medinger L, Kruse A, et al: Precision and accuracy of the 3dMD photogrammetric system in craniomaxillofacial application. *J Craniofac Surg* 2010;21: 763-767

5. Moyer HR, Carlson GW, Styblo TM, et al: Three-dimensional digital evaluation of breast symmetry after breast conservation therapy. *J Am Coll Surg* 2008;207:227-232
6. Weinberg SM, Naidoo S, Govier DP, et al: Anthropometric precision and accuracy of digital three-dimensional photogrammetry comparing the Genex and 3dMD imaging systems with one another and with direct anthropometry. *J Craniofac Surg* 2006;17:477-483
7. Aldridge K, Boyadjiev SA, Capone GT, et al: Precision and error of three-dimensional phenotypic measures acquired from 3dMD photogrammetric images. *Am J Med Genet A* 2005;138A:247-253
8. 3dMD Benefits. <http://www.3dmd.com/Benefits/index.asp>. Accessed on 28 May 2008
9. Homepage of 3dMD. <http://www.3dmd.com>. Accessed on 28 May 2008

Copyright of Journal of Prosthodontics is the property of Wiley-Blackwell and its content may not be copied or emailed to multiple sites or posted to a listserv without the copyright holder's express written permission. However, users may print, download, or email articles for individual use.