

ORIGINAL ARTICLE

Triamcinolone acetonide mouth rinses for treatment of erosive oral lichen planus: efficacy and risk of fungal over-infection

A González-García¹, M Diniz-Freitas¹, P Gándara-Vila¹, A Blanco-Carrión², A García-García³, JM Gándara-Rey²

¹Department of Oral Surgery and Oral Medicine, School of Dentistry, University of Santiago de Compostela, Santiago de Compostela, Spain; ²Department of Oral Medicine, School of Dentistry, University of Santiago de Compostela, Santiago de Compostela, Spain; ³Department of Maxillofacial Surgery, Clinical University Hospital, University of Santiago de Compostela, Santiago de Compostela, Spain

OBJECTIVES: To assess the efficacy of triamcinolone acetonide mouthrinse for treatment of erosive oral lichen planus (OLP), and to evaluate the risk of fungal over-infection.

PATIENTS AND METHODS: Clinical records of all cases of erosive and erosive-ulcerative OLP treated in our Oral Medicine Service over the period 1993–2003 were reviewed. All patients had been treated with mouthrinses containing triamcinolone acetonide at 0.3% (T1) or 0.5% (T2). Clinical outcome for each patient was classified at 1, 3 and 6 months after start of treatment as total remission (TR), partial remission (PR) or no remission (NR). Fungal over-infection was also recorded.

RESULTS: A total of 35 cases were included in the study. Clinical outcomes considering both treatment groups together (T1 + T2) were as follows: at month 1, 28.6% TR, 62.9% PR, 8.6% NR; at month 3, 57.1% TR, 37.1% PR, 5.7% NR; and at month 6, 80.0% TR, 17.1% PR, 2.9% NR. In four patients (11.4%) fungal over-infection was noted during the study period.

CONCLUSION: Triamcinolone acetonide mouthrinse is an appropriate treatment for erosive OLP, in view of the high efficacy and low risk of fungal over-infection.

Oral Diseases (2006) 12, 559–565

Keywords: fungal infections; oral lichen planus; topical corticoids; triamcinolone

Introduction

Oral lichen planus (OLP) is a chronic inflammatory disease that appears in about 1–2% of the general population (Pindborg *et al*, 1997; Miller *et al*, 2001) and is characterized by a clinical course with periodic remissions and reactivations (Eisen, 1993; Lozada-Nur and Miranda, 1997a; Scully *et al*, 1998; Chainani-Wu *et al*, 2001). Lichen planus is a mucocutaneous disease with characteristic histological appearance, very frequently showing oral manifestations, generally benign though occasionally showing malignant transformation (Silverman, 2000). It is an autoimmune disorder mediated principally by T lymphocytes, but its aetiology remains unknown.

There are various clinical presentations of OLP. In terms of treatment strategy, however, cases can be divided into two broad categories: the white form with reticular or plaque lesions, and the red form with erosive or erosive-ulcerative lesions (Bagán-Sebastian *et al*, 1992). In the white form, the treatment strategy generally involves informing the patient about the disorder, eliminating local irritants and initiating a programme of check-ups. However, the red form is characterized by painful symptoms and by insidious course with recurring outbreaks, and there may possibly be a risk of malignant transformation (Epstein, 2003; van der Meij *et al*, 2003), particularly in the dorsolingual location (Pogrel and Weldon, 1983; Camisa *et al*, 1998; Epstein, 2003; Gándara-Rey *et al*, 2004). In view of these characteristics, treatment generally involves not only elimination of local irritants, but also more frequent check-ups and topical administration of steroid anti-inflammatories, for both their anti-inflammatory and anti-proliferative effects.

It is well known that systemic corticoids should be used with caution, in view of secondary effects. With topical administration these problems are less severe and

Correspondence: A González-García, Facultad de Medicina y Odontología, Calle Entrerrios S/N, 15782 Santiago de Compostela, Spain. Tel: +34 981 56 31 00 (ext. 12357), Fax: +34 981 56 22 26, E-mail: gonzalezgarcia@gmail.com
Received 13 October 2005; revised 14 December 2005; accepted 19 December 2005

less frequent but still relevant, including in some cases hirsutism and moon face (González-Moles *et al*, 2002; González-Moles and Scully, 2005a), and alterations in endogenous cortisol secretion leading to dependence (Walsh *et al*, 1993). More frequently, corticoid-induced local immunosuppression increases the risk of opportunist infections such as oropharyngeal candidiasis (Ellepola and Samaranayake, 2001a). All these effects are related to dose, potency and treatment duration, and it is important to administer these drugs at the correct dose, for no longer than is necessary, and with gradual withdrawal (Schacke *et al*, 2002).

There have been few studies of the clinical effectiveness of corticosteroids of lower potency than clobetasol propionate (González-Moles and Scully, 2005b). The aim of the present study was to evaluate the efficacy of 0.3 and 0.5% triamcinolone acetonide mouthrinses for treatment of erosive OLP, and to evaluate the incidence of fungal over-infections in patients treated in this way.

Patients and methods

Patient selection

This was a retrospective study of clinical records of all cases treated in the Oral and Maxillofacial Medicine Service of the University Hospital Complex of Santiago de Compostela in north-west Spain. Criteria for inclusion were as follows: (1) treated between 1 January 1993 and 31 December 2002; (2) clinical and histological diagnosis based on the World Health Organization's clinical and histopathological definition of OLP (WHO Collaborating Centre for Oral Precancerous Lesions, 1978) (Table 1); (3) follow-up period of at least 6 months; (4) mucosal lesions with an erosive or ulcerative component; and (5) treated with 0.3% or 0.5% triamcinolone acetonide mouthrinse. Criteria for exclusion were as follows: (1) treatment with triamcinolone acetonide at other doses or in other presentations, or treatment with other corticoids; (2) contraindications for corticosteroid use (immunodeficiency, severe haematological alterations, pregnancy or lactation); and/or (3) presence of candidiasis before treatment.

For each patient we recorded age, sex, reason for consultation, smoking habits, lesion location, lesion shape and characteristics, treatment received, fungal over-infection if occurring during treatment and clinical

outcome. We also recorded whether the patient had other related diseases or was undergoing treatment with psychoactive drugs (anxiolytics or antidepressants), which may be associated with OLP severity or with the appearance of candidiasis.

Clinical characteristics

Symptoms at first consultation were classified as (1) 'absence of symptoms' when the patient consulted for some other reason; (2) 'no pain, with discomfort' when the patient reported itchiness or a burning sensation or discomfort, but did not explicitly report pain; (3) 'moderate or severe pain' when the patient reported pain, but not functional incapacity; or (4) 'functional incapacity' when the patient explicitly reported severe pain that made normal mastication, deglutition and phonation impossible. Principal lesion type at first consultation was classified as (1) 'erosive' when the lesions were erythematous, with epithelial thinning, and inflammation, or (2) 'erosive-ulcerative' when the mucosa showed ulceration; in both cases lesion classification was independent of the presence of white reticulate striae.

Treatment

Treatment was with a 0.3% (T1) or 0.5% (T2) aqueous solution of triamcinolone acetonide, as a 1-min mouthwash three times daily (standard dosage), until the lesions fully remitted, with subsequent gradual withdrawal at maintenance dosage (first month after remission, same mouthrinse, 1 min two times daily, morning and evening; second month after remission, same mouthrinse, 1 min once daily, morning). If at any stage the lesions recurred, the initial mouthrinse dosage was reintroduced.

T2 was generally selected for patients with more extensive lesions in multiple locations and more serious symptoms, and T1 for the remaining patients; this decision was based on professional judgement. Some patients (Table 2) also received a 0.12% aqueous solution of chlorhexidine digluconate throughout the study.

Treatment also included elimination of potential mechanical and chemical irritants such as calculus, sharp edges on teeth or dentures, poorly fitting dentures, alcohol and tobacco, as well as improved oral hygiene.

Response to treatment

Lesion response was classified at 1, 3 and 6 months after the start of treatment by a modification of the classifi-

Table 1 WHO clinical and histological definition of oral lichen planus

Clinical criteria	
Presence of bilateral lesions	
Presence of a network of slightly raised greyish-white striae (reticulate form)	
Erosive, atrophic, bullous or plaque-like lesions (accepted as subtypes only in the presence of reticular lesions in some part of the oral mucosa)	
Histopathological criteria	
Presence of banded cellular infiltrate (only in the most superficial parts of the connective tissue, principally consisting of lymphocytes)	
Signs of degeneration due to liquefaction in basal layers	
Absence of epithelial dysplasia	

Table 2 Relationships between digluconate chlorhexidine mouthwash use and clinical form

		Erosive form	Erosive-ulcerative form	Total
Chlorhexidine	No	7 (46.7)	9 (45.0)	16 (45.7)
	Yes	8 (53.3)	11 (55.0)	19 (54.3)

Values are expressed as *n* (%).

cation of Carrozzo and Gandolfo (1999), as total remission (TR), partial remission (PR) or no remission (NR). TR was defined as complete disappearance of functional incapacity, pain and discomfort, and erosive lesions (independently of whether reticulate striae remained); NR was defined as no change with respect to initial clinical status; PR was defined as any state intermediate between TR and NR.

All patients had been treated with triamcinolone acetonide and the clinical outcome for each patient was classified at 1, 3 and 6 months after start of treatment as TR, PR or NR.

Fungal over-infection

Oral candidiasis was diagnosed by clinical findings of a white plaque, which could be scraped off, and red patches, both of which underwent confirmation culture. All patients were checked for fungal over-infection by clinical examination before and throughout the study, and on the basis of baseline culture at the start of the study to identify *Candida* carriers (> 50 colony-forming units per square mm). In cases in which we detected erythematous or pseudomembranous candidiasis during treatment, we performed a second culture to confirm and identify the species involved, using the API ID 32C yeast identification kit (bioMérieux, Marcy l'Etoile, France).

Statistical analysis

Correlations between categorical variables were assessed by using the chi-squared test. Statistical significance was set at $P < 0.05$. Data were collated and analysed using the SPSS 10.0 software package (SPSS Inc., Chicago, IL, USA).

Results

Of the 136 patients with an initial clinical diagnosis of OLP, only 35 met all inclusion criteria. The remaining 101 were excluded because of lack of histological confirmation of OLP (32 patients), white as opposed to red form of OLP (53 patients), systemic corticoid treatment (two patients), intralesion injections (two patients), hypersensitivity to triamcinolone acetonide (one patient), treatment with other topical corticoids or triamcinolone acetonide with different presentation (10 patients) or previous candidiasis (one patient). This latter patient showed pseudomembranous candidiasis, and he was the only patient with > 50 CFU at the baseline culture.

The epidemiological characteristics, smoking habits and systemic pathologies of the patients are summarized in Table 3. Of the 35 patients, 13 (37.1%) were men and 22 (62.9%) women; mean age was 54.4 years (± 12.6 , range 31–79). Fourteen patients (40.0%) were receiving anxiolytics or antidepressants.

Thirty patients showed lichen lesions in the mouth only, while the other five additionally showed lesions in other locations (three only on the skin, two on skin, nails and genitals). The oral lesions were distributed as follows: 34 patients (97.1%) with lesions of the buccal

Table 3 Basic demographic characteristics, life habits and associated disorders in the sample of 35 OLP patients

	Diabetes	Hepatitis	Rheumatological diseases	Treatment with psychoactive drugs	Smoking
<i>n</i>	4	3	12	14	4
%	11.5	8.6	34.3	40	11.5

n = 35, mean age 54.4 years \pm 12.62, range 31–79 years; 13 men, 22 women. OLP, oral lichen planus.

mucosa, 19 (54.3%) with lesions of the tongue, 13 (37.1%) with lesions of the lips, 10 (28.6%) with lesions of the palate, nine (5.7%) with chronic desquamative gingivitis and 18 (5.4%) with lesions of the alveolar ridge or buccal vestibule.

At first consultation, 15 patients (42.9%) showed only erosive lesions, while 20 (57.1%) showed erosive-ulcerative lesions. Symptoms at first consultation were classified (see Patients and methods) as 'absence of symptoms' in four cases (11.4%), as 'no pain, with discomfort' in 18 cases (51.4%), as 'moderate or severe pain' in nine cases (25.7%) and as 'functional incapacity' in four cases (11.4%). Relationships between clinical form and symptoms at the start of the study are summarized in Figure 1.

No significant association was detected between OLP form and systemic disorders, psychoactive drug use, or tobacco or alcohol use. Likewise, no significant association was detected between candidiasis and these patient characteristics.

Treatment T1 was applied in 29 patients (82.9%): 14 (48.3% of 29) with erosive lesions only and 15 (51.7%) with erosive-ulcerative lesions. Treatment T2 was applied in the remaining six patients (17.1%): one (16.7%) with erosive lesions only and five (83.3%) with erosive-ulcerative lesions. In addition, chlorhexidine was administered to eight (53.3%) of the 15 patients with erosive lesions only and to 11 (55.0%) of the 20 patients with erosive-ulcerative lesions (Table 2).

Clinical outcomes in the T1 group were as follows: at month 1, 27.6% TR, 65.5% PR, 6.9% NR; at month 3, 62.1% TR, 31.0% PR, 6.9% NR; and at month 6, 82.8% TR, 13.8% PR, 3.4% NR. (Figure 2).

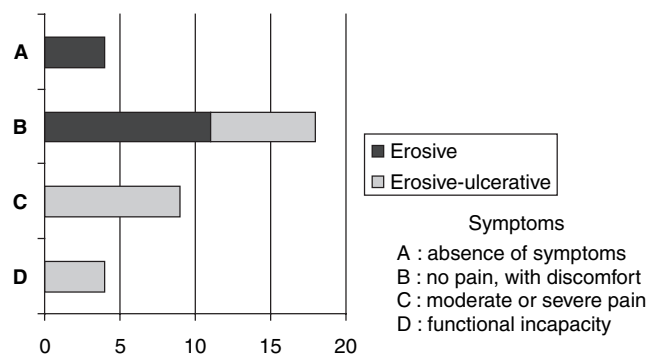


Figure 1 Relationship between symptoms at first consultation and clinical form (erosive or erosive-ulcerative)

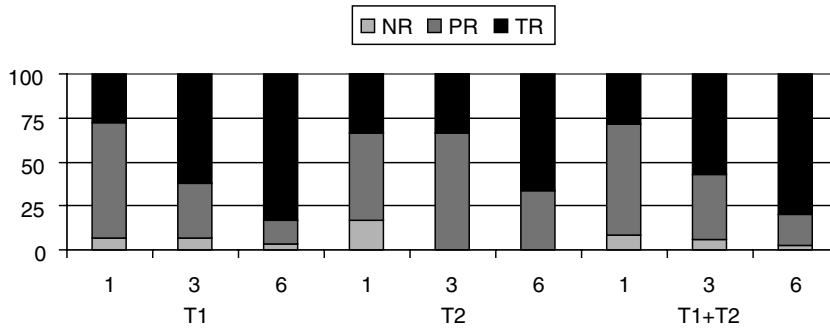


Figure 2 Clinical response of the patients in each treatment group at 1, 3 and 6 months after treatment start [T1, 0.3% triamcinolone acetonide; T2, 0.5% triamcinolone acetonide; T1 + T2, all patients; TR, total remission; PR, partial remission; NR, no remission.]

Clinical outcomes in the T2 group were as follows: at month 1, 33.3% TR, 50.0% PR, 16.0% NR; at month 3, 33.3% TR, 66.7% PR, 0% NR; and at month 6, 66.7% TR, 33.3% PR, 0% NR. (Figure 2).

Clinical outcomes considering both treatment groups together (T1 + T2) were as follows: at month 1, 28.6% TR, 62.9% PR, 8.6% NR; at month 3, 57.1% TR, 37.1% PR, 5.7% NR; and at month 6, 80.0% TR, 17.1% PR, 2.9% NR. (Figure 2).

Note that clinical responses were not necessarily unidirectional: for example, two patients in the T1 group were classed as TR in month 3, but as PR in month 6.

At the end of the study, from month 6 onwards, seven patients (20.1%) were receiving the original corticoid dose and 10 patients (28.4%) the maintenance dose,

while the remaining 18 patients (51.4%) were no longer receiving treatment. Full details of each patient's treatment regime are given in Figure 3.

Fungal over-infection was noted during the study period in three (10.3%) of the 29 patients in the T1 group, one (16.7%) of the six patients in the T2 group, and four (11.4%) of the total of 35 patients in both groups together (Table 4). In all cases the fungal infection appeared as pseudomembranous candidiasis, and was confirmed by culture: all cultures were positive within 24 h, with counts of more than 50 CFU per square mm. In all cases the infecting organism was identified as *Candida albicans*.

Seventy five per cent of cases of candidiasis appeared in patients who did not receive chlorhexidine

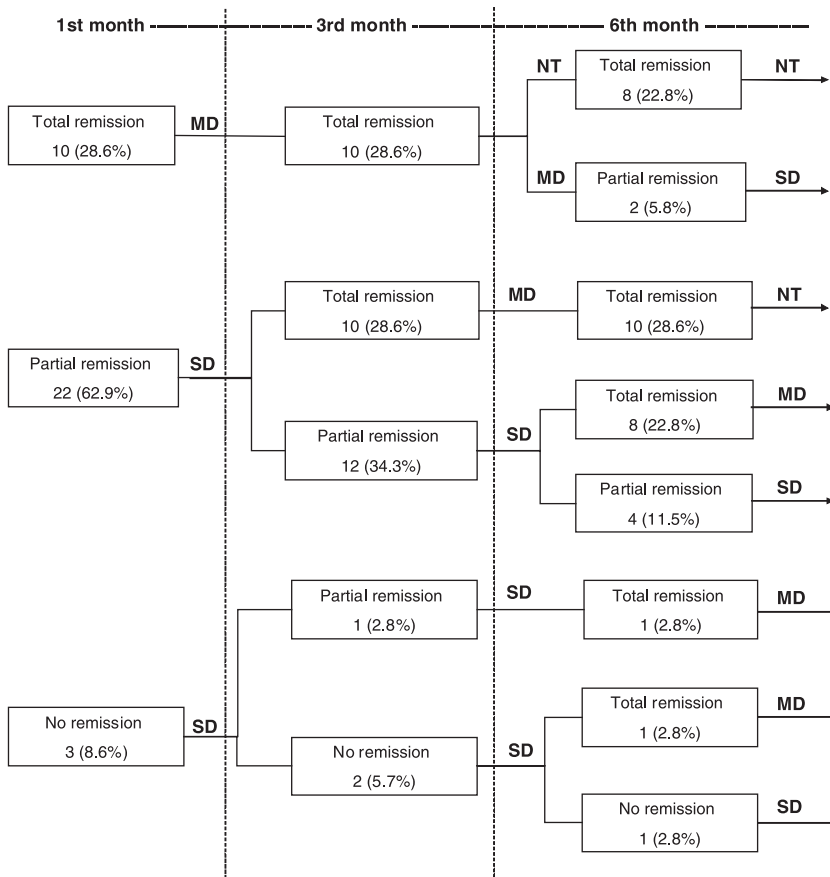


Figure 3 Treatment regime for the 34 patients over the study period [SD, standard dosage: 0.3% or 0.5% aqueous solution of triamcinolone acetonide, as a 1-min mouthwash three times daily. MD, maintenance dosage: first month after remission, same mouthrinse, 1 min two times daily, morning and evening; second month after remission, same mouthrinse, 1 min once daily, morning. NT, no corticoid treatment.]

Table 4 Incidence of candidiasis during treatment

		T1	T2	Total
Candidiasis	No	26 (89.7)	5 (83.3)	31 (88.6)
	Yes	3 (10.3)	1 (16.7)	4 (11.4)

Values are expressed as *n* (%). T1: 0.3% triamcinolone acetonide; T2: 0.5% triamcinolone acetonide.

mouthrinse (45.7% of the total of patients); this proportion is not significantly higher than expected assuming no effect ($\chi^2 = 1.561$, $P = 0.212$), but this is probably because of the small sample size and low overall incidence of candidiasis.

Discussion

The clinical and epidemiological characteristics seen in the present study (patient age, sex, habits, symptoms, lesion location and characteristics) are in line with the findings of previous studies (Silverman *et al*, 1991; Lozada-Nur and Miranda, 1997a; Thongprasom *et al*, 2003). In the present study symptoms were classified on the basis of subjective criteria, without specifically following previously published clinical scales (Thongprasom *et al*, 1992). In any case, symptoms at first consultation were clearly typical symptoms of erosive or erosive-ulcerative lichen planus.

Various treatments have been used for OLP in recent decades, not always with good results. Treatments include topical retinoid therapy (Regezi *et al*, 1986), which is less effective than topical corticoid therapy (Buajeeb *et al*, 1997), and which may have various adverse effects if administered systemically (Ferguson *et al*, 1984; Gorsky and Raviv, 1992). Low-dose cyclosporin mouthrinses (Pacor *et al*, 1994) have also been reported to be effective, but are not widely used because of their high cost, immunosuppressive effects and poor efficacy for the more severe forms of OLP (Porter *et al*, 1993; Sieg *et al*, 1995; Epstein and True-love, 1996).

Notwithstanding these various alternative treatment options, the treatment of choice remains corticoid therapy, in view of the autoimmune character of OLP, its effects on epithelial and connective tissues, and its location in the oral cavity. Topical corticoids effectively penetrate the squamous epithelium, and have less severe side effects than systemic corticoids (Lozada-Nur and Miranda, 1997b; Epstein, 2003), due to their low systemic absorption (Plemons *et al*, 1990).

A recent review has suggested that although topical corticoids remain the treatment of choice for OLP, there is in fact little objective evidence to support their efficacy (Chan *et al*, 2000).

Nevertheless, in recent decades there have been several studies of the efficacy of various corticoids for the treatment of erosive-ulcerative OLP, including triamcinolone acetonide, fluocinolone acetonide, fluocinonide, clobetasol propionate, mometasone furoate and hydrocortisone hemisuccinate, as mouthrinses, ointments, gels and tablets (González-Moles and Scully, 2005b; Lodi

et al, 2005). Gingival lesions manifesting as chronic desquamative gingivitis tend to be more recalcitrant to treatment with mouthrinses, although this problem can be overcome by administration in custom trays carrying gels or ointments, which increase contact time (González-Moles *et al*, 2003). In all other localizations of OLP lesions, oral rinses are effective topical applications when compared with creams or ointments (Vincent *et al*, 1990; Ungphaiboom and Maitani, 2001).

A number of studies have considered the immunosuppressive effects of local treatment with corticoids, in some cases leading to an alteration in the oral flora as a result of excessive growth of fungal species, mainly *C. albicans*, provoking oropharyngeal candidiasis (Ellepola and Samaranayake, 2001b). In view of these effects, some authors have proposed parallel administration of antifungals (Carrozzo and Gandolfo, 1999). The incidence of candidiasis in the present study was 11.4% (4/35), similar to or rather lower than in previous studies using topical corticoids (Lozada-Nur *et al*, 1991; Thongprasom *et al*, 1992; Chainani-Wu *et al*, 2001; Aguirre *et al*, 2004).

Vincent *et al* (1990) treated symptomatic OLP with 0.1% or 0.2% triamcinolone acetonide in aqueous solution four times per day in 46 patients, and in another 17 patients applied the same treatment in combination with a burst of systemic prednisone. Secondary candidiasis arose in 25 (40%) of the 63 patients, but nine of these patients were predisposed to infection because of previous treatment with antibacterial antibiotics or topical or systemic steroids, while another two patients were predisposed to infection because of type II diabetes. The clinical responses to topical treatment alone were similar to those observed in the present study (84.3% complete relief, 12.5% partial relief, 3.2% no relief). The average follow-up time was 3 months.

Thongprasom *et al* (1992) found that pseudomembranous candidiasis arose in 47.3% (9/19) of OLP patients treated with fluocinolone acetonide in orabase 0.1% vs 25.0% (4/16) in patients treated with triamcinolone acetonide in orabase 0.1%. This suggests that the risk of fungal over-infection is lower with triamcinolone acetonide. However, after 4 weeks of treatment significantly more lesions were cured in the fluocinolone group than in the triamcinolone group, but fluocinolone was not effective in six of the 19 cases.

Thongprasom *et al* (2003) treated 28 OLP patients with a 0.1% fluocinolone acetonide solution. Of these patients, 21.4% showed complete remission within the first 2 years of treatment. Oral candidiasis was recorded after treatment in 14.3% of patients.

Chlorhexidine is known to have antifungal properties (Anil *et al*, 2001), and various authors have found that chlorhexidine mouthrinses reduce the risk of fungal over-infection in OLP patients treated with topical corticoids (Carbone *et al*, 1999; Ellepola and Samaranayake, 2001b).

In the present study we did not find any association between OLP presentation forms or candidiasis and any of the systemic disorders, psychoactive drugs or habits considered. The risk of candidiasis appears to have been

reduced by the use of chlorhexidine mouthrinse, as 75% of the cases of candidiasis arose in patients not receiving chlorhexidine. However, this apparent effect was not statistically significant. In any case, this low incidence of candidiasis (only 11.4%) indicates that the risk of fungal over-infection during treatment with triamcinolone acetonide mouthrinse is low. A similarly low risk of fungal over-infection in OLP patients treated with topical corticoids, which have similar potency, has been noted in previous studies (Vincent *et al*, 1990; Thongprasom *et al*, 2003).

The results of the present study suggest that of the various treatments available, triamcinolone acetonide is effective for red form OLP, with 91.5% of patients showing partial or TR of lesions within the first month. It is important to note that not all our patients showed steady unidirectional resolution: for example, two patients in the T1 group were classed as 'TR' in month 3, but as 'PR' in month 6 (after receiving the triamcinolone acetonide maintenance dosage from month 3 onwards).

It should be noted that some remissions may have been spontaneous and unrelated to drug treatment. Furthermore, the possible influences of elimination of mechanical and chemical irritants and of improvements in oral hygiene have not been evaluated. Like other authors (Holmstrup *et al*, 1990; Ramon-Fluixa *et al*, 1999; Lodi *et al*, 2005) we consider that factors of this type may affect outcome.

In any case, all patients with red form OLP should be monitored throughout life, in view of the chronic nature of this disorder, with frequent reactivations. Control of pain and functional incapacity is particularly important, and in such cases the doctor may opt for one of the treatments mentioned above, or for other more potent treatments, always striving to achieve an appropriate balance between treatment efficacy and risk and severity of side effects.

Continuing improvements in topical corticoid formulations, aimed at maximizing penetration of the epithelium, will foreseeably improve efficacy (Campisi *et al*, 2004). Very recently, a study in Australia has obtained good results by pretreatment with Azone^R (Yick-Vic Chemicals and Pharmaceuticals Ltd., Hong Kong, China) as an enhancer of uptake and retention of triamcinolone acetonide by the oral mucosa (Nicolazzo *et al*, 2005).

In conclusion, 0.3% or 0.5% triamcinolone acetonide mouthrinse appears to be an effective treatment for erosive and erosive-ulcerative OLP. In addition, the risk of fungal over-infection is low, and can probably be reduced still further by co-prescription of a chlorhexidine mouthrinse, although further studies will be required to confirm this latter conclusion.

References

Aguirre JM, Bagán JV, Rodríguez C *et al* (2004). Efficacy of mometasone furoate microemulsion in the treatment of erosive-ulcerative oral lichen planus: pilot study. *J Oral Pathol Med* **33**: 381–385.

- Anil S, Ellepola AN, Samaranayake LP (2001). The impact of chlorhexidine gluconate on the relative cell surface hydrophobicity of oral *Candida albicans*. *Oral Dis* **7**: 119–122.
- Bagán-Sebastian JV, Milian-Manaset MA, Peñarrocha-Diogo M, Jimenez Y (1992). A clinical study of 205 patients with oral lichen planus. *J Oral Maxillofac Surg* **50**: 116–118.
- Buajeeb W, Kraivaphan P, Poburksa C (1997). Efficacy of topical retinoic acid compared with topical fluocinonide acetonide in the treatment of oral lichen planus. *Oral Surg Oral Med Oral Pathol Oral Radiol Endod* **83**: 21–25.
- Camisa C, Hamaty FG, Gay JD (1998). Squamous cell carcinoma of the tongue arising in lichen planus: a case report and review of the literature. *Cutis* **62**: 175–178.
- Campisi G, Giandalia G, de Caro V, di Liberto C, Aricò P, Giannola LI (2004). A new delivery system of clobetasol-17 propionate (lipid-loaded microspheres 0.025%) compared with a conventional formulation (lipophilic ointment in a hydrophilic phase 0.025%) in topical treatment of atrophic/erosive oral lichen planus. Phase V, randomized, observer-blinded, parallel group clinical trial. *Br J Dermatol* **150**: 984–990.
- Carbone M, Conrotto D, Carrozzo M, Broccoletti R, Gandolfo S, Scully C (1999). Topical corticosteroids in association with miconazole and chlorhexidine in the long-term management of atrophic-erosive oral lichen planus: a placebo-controlled and comparative study between clobetasol and fluocinonide. *Oral Dis* **5**: 44–49.
- Carrozzo M, Gandolfo S (1999). The management of oral lichen planus. *Oral Dis* **5**: 181–182.
- Chainani-Wu N, Silverman S Jr, Lozada-Nur F, Mayer P, Watson JJ (2001). Oral lichen planus: patient profile, disease progression and treatment responses. *J Am Dent Assoc* **132**: 901–909.
- Chan ES-Y, Thornhill M, Zakrzewska J (2000). Interventions for treating oral lichen planus. *Cochrane Database Syst Rev* CD001168.
- Eisen D (1993). The therapy of oral lichen planus. *Crit Rev Oral Biol Med* **4**: 141–158.
- Ellepola AN, Samaranayake LP (2001a). Inhalation and topical steroids, and oral candidosis: a mini review. *Oral Dis* **7**: 211–216.
- Ellepola AN, Samaranayake LP (2001b). Adjunctive use of chlorhexidine in oral candidosis: a mini-review. *Oral Dis* **7**: 11–17.
- Epstein JB (2003). Oral lichen planus: progress in understanding its malignant potential and implications for clinical management. *Oral Surg Oral Med Oral Pathol Oral Radiol Endod* **96**: 32–37.
- Epstein JB, Truelove EL (1996). Topical cyclosporine in a bioadhesive for treatment of oral lichenoid mucosal reactions: an open label clinical trial. *Oral Surg Oral Med Oral Pathol* **82**: 532–536.
- Ferguson MM, Simpson NB, Hammersly N (1984). The treatment of erosive lichen planus with a retinoid-etretinate. *Oral Surg Oral Med Oral Pathol* **58**: 283–287.
- Gándara-Rey JM, Diniz-Freitas M, Gándara-Vila P, Blanco-Cañón A, Suárez-Peñaranda JM, García-García A (2004). Malignant transformation of oral lichen planus in lingual location: report of a case. *Oral Oncol* **40**: 1–4.
- González-Moles MA, Scully C (2005a). Vesiculo-erosive oral mucosal disease – management with topical corticosteroids: (2) Protocols, monitoring of effects and adverse reactions, and the future. *J Dent Res* **84**: 302–308.

- González-Moles MA, Scully C (2005b). Vesiculo-erosive oral mucosal disease – management with topical corticosteroids: (1) Fundamental principles and specific agents available. *J Dent Res* **84**: 294–301.
- González-Moles MA, Morales P, Rodríguez-Archilla A, Isabel IR, González-Moles S (2002). Treatment of severe chronic oral erosive lesions with clobetasol propionate in aqueous solution. *Oral Surg Oral Med Oral Pathol Oral Radiol Endod* **93**: 264–270.
- González-Moles MA, Ruiz-Ávila I, Rodríguez-Archilla A et al (2003). Treatment of severe erosive gingival lesions by topical application of clobetasol propionate in custom trays. *Oral Surg Oral Med Oral Pathol Oral Radiol Endod* **95**: 688–692.
- Gorsky M, Raviv M (1992). Efficacy of etretinate (Tigason) in symptomatic oral lichen planus. *Oral Surg Oral Med Oral Pathol* **73**: 52–55.
- Holmstrup P, Schiotz AW, Westergaard J (1990). Effect of dental plaque control on gingival lichen planus. *Oral Surg Oral Med Oral Pathol* **69**: 585–590.
- Lodi G, Scully C, Carrozzo M, Griffiths M, Sugerman PB, Thongprasom K (2005). Current controversies in oral lichen planus: report of an international consensus meeting. Part 2. Clinical management and malignant transformation. *Oral Surg Oral Med Oral Pathol Oral Radiol Endod* **100**: 164–178.
- Lozada-Nur F, Miranda C (1997a). Oral lichen planus: epidemiology, clinical characteristics, and associated diseases. *Semin Cutan Med Surg* **16**: 273–277.
- Lozada-Nur F, Miranda C (1997b). Oral lichen planus: topical and systemic therapy. *Semin Cutan Med Surg* **16**: 295–300.
- Lozada-Nur F, Zhong Huang M (1991). Open preliminary clinical trial of clobetasol propionate ointment in adhesive paste for treatment of chronic oral vesiculoerosive diseases. *Oral Surg Oral Med Oral Pathol* **71**: 293–297.
- van der Meij EH, Schepman KP, van der Waal I (2003). The possible premalignant character of oral lichen planus and oral lichenoid lesions: a prospective study. *Oral Surg Oral Med Oral Pathol Oral Radiol Endod* **96**: 164–171.
- Miller CS, Epstein JB, Hall EH, Sirois D (2001). Changing oral care needs in the United States: the continuing need for oral medicine. *Oral Surg Oral Med Oral Pathol Oral Radiol Endod* **91**: 34–44.
- Nicolazzo JA, Reed BL, Finnin BC (2005). Enhancing the buccal mucosal uptake and retention of triamcinolone acetonide. *J Control Release* **105**: 240–248.
- Pacor ML, Biasi D, Urbani G, Lombardo G, Lunardi C (1994). The efficacy of cyclosporine for topical use in oral lichen planus. *Minerva Stomatol* **43**: 129–132.
- Pindborg JJ, Reichart PA, Smith CJ, Sobin LH (1997). *WHO International Histological Classification of Tumors: Histological Typing of Cancer and Precancer of the Oral Mucosa*. Springer: Berlin.
- Plemons JM, Rees TD, Zachariah NY (1990). Absorption of a topical steroid and evaluation of adrenal suppression in patients with erosive lichen planus. *Oral Surg Oral Med Oral Pathol* **69**: 688–693.
- Pogrel MA, Weldon LL (1983). Carcinoma arising in erosive lichen planus in the midline of the dorsum of the tongue. *Oral Surg Oral Med Oral Pathol* **55**: 62–66.
- Porter SR, Scully C, Eveson JW (1993). The efficacy of topical cyclosporine in the management of desquamative gingivitis due to lichen planus. *Br J Dermatol* **129**: 753–755.
- Ramon-Fluixa C, Bagan-Sebastian J, Milian-Masanet M, Scully C (1999). Periodontal status in patients with oral lichen planus: a study of 90 cases. *Oral Dis* **5**: 303–306.
- Regezi JA, Ellis CN, Stewart JC, Giustina TA (1986). Histological changes associated with the topical use of isotretinoin on oral lichen planus. *Oral Surg Oral Med Oral Pathol* **61**: 479–484.
- Schacke H, Docke WD, Asadullah K (2002). Mechanisms involved in the side effects of glucocorticoids. *Pharmacol Ther* **96**: 23–43.
- Scully C, Beyli M, Ferreiro MC et al. (1998). Update on oral lichen planus: etiopathogenesis and management. *Crit Rev Oral Biol Med* **9**: 86–122.
- Sieg P, Von Domarus H, Von Zitzewitz V, Iven H, Farber L (1995). Topical cyclosporin in oral lichen planus: a controlled, randomized, prospective trial. *Br J Dermatol* **132**: 790–794.
- Silverman S Jr (2000). Oral lichen planus: a potentially premalignant lesion. *J Oral Maxillofac Surg* **58**: 1286–1288.
- Silverman S Jr, Gorsky M, Lozada-Nur F, Giannotti K (1991). A prospective study of findings and management in 214 patients with oral lichen planus. *Oral Surg Oral Med Oral Pathol* **72**: 665–670.
- Thongprasom K, Luangjarmekorn L, Sererat T, Taweasap W (1992). Relative efficacy of fluocinolone acetonide compared with triamcinolone acetonide in treatment of oral lichen planus. *J Oral Pathol Med* **21**: 456–458.
- Thongprasom K, Luengvisut P, Wongwatanakij A, Boonjatturus C (2003). Clinical evaluation in treatment of oral lichen planus with topical fluocinolone acetonide: a 2-year follow-up. *J Oral Pathol Med* **32**: 315–322.
- Ungphaiboom S, Maitani Y (2001). In vitro permeation studies of triamcinolone acetonide mouthwashes. *Int J Pharm* **220**: 111–117.
- Vincent SD, Fotos PG, Baker KA, Williams TP (1990). Oral lichen planus: the clinical, historical, and therapeutic features of 100 cases. *Oral Surg Oral Med Oral Pathol* **70**: 165–171.
- Walsh P, Aeling JL, Huff L, Weston WL (1993). Hypothalamus-pituitary-adrenal axis suppression by superpotent topical steroids. *J Am Acad Dermatol* **29**: 501–503.
- WHO Collaborating Centre for Oral Precancerous Lesions (1978). Definition of leukoplakia and related lesions: an aid to studies on oral precancer. *Oral Surg Oral Med Oral Pathol* **46**: 518–539.

Copyright of Oral Diseases is the property of Blackwell Publishing Limited and its content may not be copied or emailed to multiple sites or posted to a listserv without the copyright holder's express written permission. However, users may print, download, or email articles for individual use.