

INVITED REVIEW

The emerging role of botulinum toxin in the treatment of temporomandibular disorders

PC Song¹, J Schwartz², A Blitzer³

¹Harvard Medical School, Massachusetts Eye and Ear Infirmary, Boston, MA; ²Georgetown University, Washington, DC;

³Department of Clinical Otolaryngology, Columbia University and NY Center for Voice and Swallowing Disorders, New York, NY, USA

The objective of this review was to discuss the emerging role of botulinum toxin in the treatment of temporomandibular disorders (TMD), to review the current literature, recent clinical trials, as well as preliminary data from our own clinical study, and to formulate an algorithm for the work-up and treatment of TMD.

Oral Diseases (2007) 13, 253–260

Keywords: botulinum toxin; temporomandibular disorders; headache

Introduction

Temporomandibular disorders (TMD) are pain syndromes that are characterized by pathology localized to the jaw and muscles of mastication. For a variety of reasons, objective data and clinical efficacy are difficult to assess between different modes of treatment. Reasons for the lack of consensus for the treatment approach for TMD include the heterogeneity in clinical presentation, the differences in diagnostic criteria, and the lack of objective radiographic or diagnostic tools to measure TMD. The disorder is often difficult to clinically separate from other facial pain disorders such as chronic sinusitis, fibromyalgia, chronic neck pain, trigeminal neuralgia, tension headaches and migraines. Over the past several years, botulinum toxin (BoNT) has been increasingly utilized as an adjuvant treatment for head and neck pain, such as tension type headaches and migraine headaches. BoNT for the treatment of TMD is a subject of study at various treatment centers. The purpose of this article was to review the current role of BoNT in chronic head and neck pain disorders with a focus on TMD. Over the past 12 years, we have treated over 200 patients in our office with BoNT for TMD. We have developed a TMD algorithm for management with BoNT. We treat patients after they have failed the traditional conservative therapies, and before they go to

surgery. We do not, at the moment, include patients with primary TM joint pathology.

Temporomandibular disorders may be divided into two primary groups – those related to the muscles themselves (myofascial) and those related to the temporomandibular joint (TMJ; arthrogenic) (Ohrbach and Stohler, 1992). TMD-associated pain may arise from the joint itself or may be secondary to hyperfunction of the muscles of mastication resulting in chronic inflammation and pain. BoNT is a neurotoxin that targets the presynaptic release of acetylcholine (Ach) in the neural junction. The earliest clinical use of BoNT was for the treatment of motor dystonias such as blepharospasm. The pain-relieving effects of BoNT were observed during the clinical trials for the treatment of cervical dystonia, oromandibular dystonias, and this pain relief is well known to our practice population (Blitzer and Sulica, 2001). More recent data suggest that pain relief is not just mediated at the neuromuscular junction, but also by decreasing the release of inflammatory mediators [calcitonin gene-related peptide (CGRP), substance P, glutamate, etc.]. These mediators are also released by soluble N-ethylmaleimide-sensitive factor attachment receptor (SNARE) proteins.

Temporomandibular disorders may be associated with headache, periauricular pain, neck pain, decreased jaw excursion, locking episodes, and noisy joint movement. Although clinical findings such as joint clicks, palpation tenderness, and dental malocclusion can suggest a diagnosis of TMD, psychological components such as depression, anxiety, and somatization are being increasingly recognized as a synergistic factor in those patients who seek treatment (Brister *et al*, 2006). Recent avenues for research have emphasized the cognitive and neurologic basis for pain processing and the interaction between the peripheral and central nervous systems (CNS).

Although the effect of BoNT on the motor endplate had been the subject of extensive study for the past 20 years, clinical applications based on the function of BoNT at the parasympathetic nervous system and pain receptors (nociceptors) are only now being actively pursued. The clinical improvement seen in patients with migraines and classical vascular headaches after

treatment with BoNT has prompted a reexamination of what is traditionally understood to be the basis of pain in headaches. Consequently, an alternative hypothesis about the pathophysiology of TMD-related pain as well as idiopathic facial pain syndromes has been suggested.

Temporomandibular disorder is a nonspecific diagnosis and is often used as a clinical label that describes pain related to the jaw and masticatory muscles that are of unclear etiology. It is also commonly associated with other pain symptoms affecting the head and neck region such as headache, ear-related symptoms, and cervical spine disorders (De Wijer *et al*, 1996). Patients with chronic TMD frequently report symptoms of depression, poor sleep quality, and low energy. Furthermore, chronic TMD has been found to interfere with normal social activity and interpersonal relationships and to negatively affect the ability to maintain employment (Morris *et al*, 1997). Reaching a correct diagnosis for patients presenting with chronic head, neck, and facial pain can be difficult. Global anxiety, feelings of helplessness, and mood disorders can often coexist in those patients, and obscure the physician's ability to acquire the necessary information to arrive at a diagnosis. In addition, psychological stresses and comorbid headache disorders can often obscure the clinical picture and make treatment strategies difficult.

Pain related to the TMJ and associated muscles is a very common complaint. A survey study of temporomandibular signs and symptoms based on a Health Maintenance Organization (HMO) population put the prevalence estimates at 10–12% (Dworkin *et al*, 1990). Several population survey studies suggest prevalence rates between 10% and 58% with most falling in the range of 25% of the general population (Lipton *et al*, 1993; Gremillion, 2000; McFarlane *et al*, 2002). A meta-analysis performed on the Dutch population survey suggested that 30% of the population had TMD-related complaints (De Kanter *et al*, 1993). The prevalence data are quite consistent between different cultural and racial groups when taking into account survey methods (Pow *et al*, 2001). There are differences in rates of those who seek treatment for orofacial pain and TMD. For instance, Asian patients are lower seekers of treatment (McMillan *et al*, 2006).

Symptomatology

The correct diagnosis of TMD is fundamental to implementing an effective treatment regimen and avoiding persistent patient disability. Often the diagnosis will be clear following a thorough patient history, although occasionally additional testing is required. Associated headache disorders are very common. On occasion, testing is warranted for patients who are disabled by their fear of serious pathology, or when the physician has concerns despite the lack of organic pathology indicators.

As there is no uniformity in the diagnosis, efforts have been made to stratify and formulate inclusion criteria for the purposes of research design. The Research Diagnostic Criteria for Temporomandibular Disorders

(RDC/TMD) utilizes a physical and psychological/social approach model to diagnose and classify patients with TMD. The first component (axis 1) groups TMD into three broad groups – muscle disorders involving myofascial pain, temporomandibular disk displacement, and joint disorders such as arthralgias, arthritis, and arthrosis. Signs and symptoms of axis 1 inclusion are persistent orofacial pain, limitations in mandibular range of motion, pain on masticatory muscle palpation, and detectable sounds in the TMJ during jaw function. The second component (axis 2) is a quality of life questionnaire that integrates behavioral modification and adaptation, psychological factors, depression, and disability (Dworkin *et al*, 2002a). Axis 2 assesses impairment of masticatory muscle function (e.g., eating, communication, bruxism), depression, and nonspecific physical symptoms (Dworkin *et al*, 2002b).

Treatment

First-line pharmacologic treatment for TMD includes anti-inflammatory agents, muscle relaxants, and narcotics. Physical treatments such as orthotic devices, physiotherapy, massage, acupuncture, and others are also often used. Other non-pharmacologic approaches including exercise, dietary adjustment, and biofeedback therapy continue to play an important role in TMD management. Rarely, surgical intervention such as arthrocentesis, intra-articular steroid injection, arthroscopy, and open arthrotomy are performed. Despite these options, treatment for TMD is often unsatisfying and incomplete. Approximately three quarters of patients with severe chronic facial pain who have been treated with narcotics continue to have functional limitations and pain (Zenz *et al*, 1997). Most of the patients in our referral base have failed multiple therapy. For patients who are referred initially, we generally employ conservative measures of treatment such as physical therapy, massage, warm compresses and behavioral therapy, oral appliances, as well as anti-inflammatory agents and muscle relaxants. We will generally offer a trial of BoNT therapy for patients who have not responded to these conservative measures.

There is currently one formulation of botulinum toxin type A (BoNT-A) (Botox) and one type B complex (Myobloc) that is FDA-approved for clinical use. There are several other BoNT-A approved in Europe and a number of others in various basic or clinical trials throughout the world. These products have different dosing, safety, and efficacy characteristics, and familiarity with each complex is essential prior to administration. There are no well established methodologies to calculate equivalent doses (Jankovic and Brin, 1997).

Lyophilized BoNT-A (Botox; Allergan, Inc., Irvine, CA, USA) is the only type A toxin currently available in the United States. Each vial contains 100 U of BoNT-A, and requires dilution with bacteriostatic 0.9% saline. The authors typically dilute each vial with either, 2 or 4 ml of saline to prepare a 5.0 or 2.5 U per 0.1 ml stock, respectively. BoNT-B (Myobloc; Solstice Neurosciences, Inc., South San Francisco, CA, USA) is available in

2500 U and 5000 U ml⁻¹ vials prediluted with 0.05% human serum albumin.

Although there is no consensus regarding dilution of BoNT for TMD, our experiences have indicated a greater overall response using lower concentrations at multiple sites with larger injection volumes (e.g., 2.5–5.0 U per 0.1 ml) as opposed to higher concentrations at fewer sites with smaller injection volumes (Blumenfeld *et al*, 2004). The diffusion of toxin is about 1 cm at each injection site. Affected areas may remain untreated if an inadequate number of injection sites are infiltrated, resulting in an incomplete response. Total dose administration is often individualized, taking into consideration the severity of symptoms, body habitus, pain distribution, and the patient's individual response to toxin.

Botulinum toxin injection for TMD primarily targets the muscles of mastication and is typically administered by injecting the primary muscle groups in a fixed-position technique depending upon the pain type and physical examination (see Figure 1). For TMD, we favor targeting muscles based on our physical examination and patient symptoms. We often adjust the dose given to the muscle groups depending on the amount of muscle tenderness and pain that the patient reports. The temporalis and masseter muscles (see Figure 2) are almost universally affected and are the most common muscles injected. We generally favor 10–25 U for each temporalis muscle and 25–50 U for the masseter muscles. If the patient complains of significant pain under the cheeks, if there is significant lateral jaw deviation, or if bruxism and teeth grinding is a major complaint, we will also deliver 7.5–10 U to the lateral pterygoids. We use EMG guidance for all injections (see Figures 3 and 4).

Following appropriate dilution, the toxin is drawn from the stock vial into a 1-ml syringe and a 27-gauge

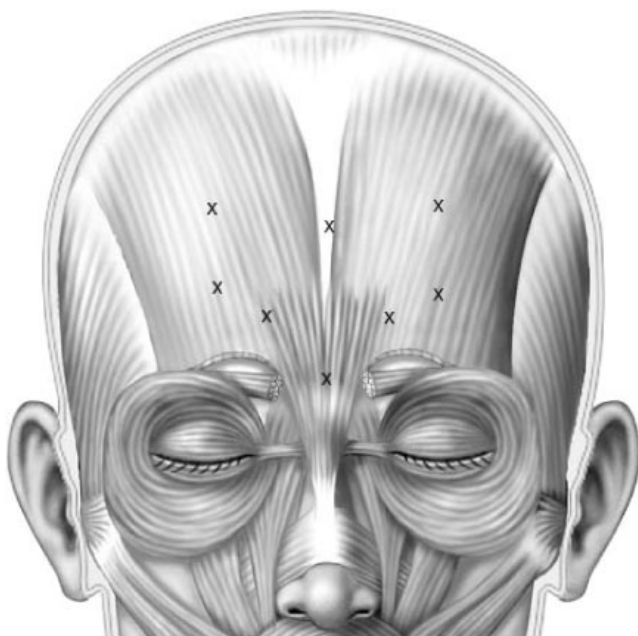


Figure 1 Injection of corrugator and frontalis muscles

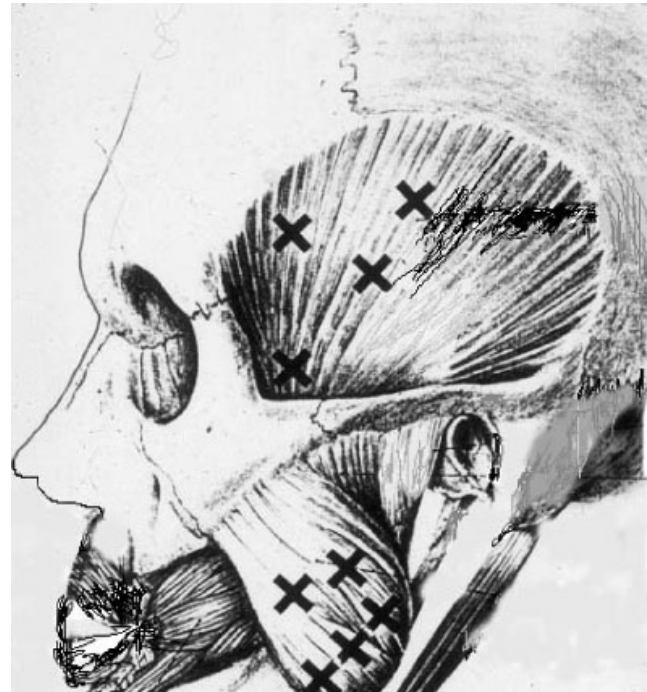

Figure 2 Injection points of masseter and temporalis muscles

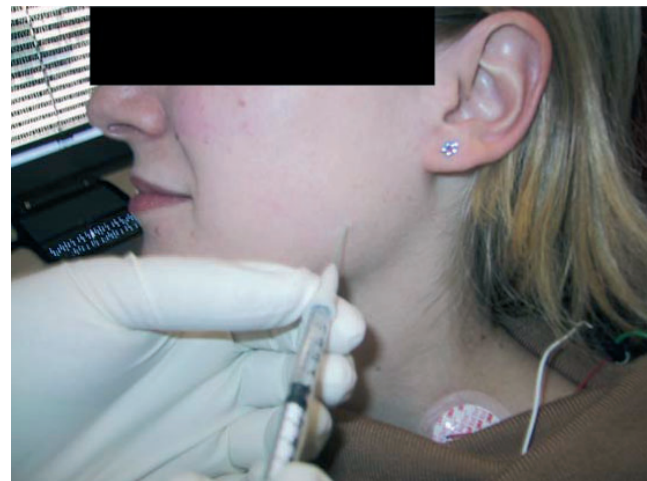

Figure 3 Injection of the masseter muscle using EMG guidance

monopolar electrode injection needle is attached. Sterile technique is used both during toxin preparation and administration. The patient is placed in either a sitting or supine position and the skin cleansed with alcohol to remove debris and contaminants.

The temporalis is a large fan-shaped muscle that covers the lateral aspect of the cranium, originating from the temporal line and inserting to the coronoid process of the mandible. While palpating the temporal area, having the patients clench their teeth enables localization for injection. Injections are usually administered as 5 U in 0.2 ml aliquots at four to five distinct sites. Because of the large size of the muscle, a larger volume may be administered without affecting adjacent structures.

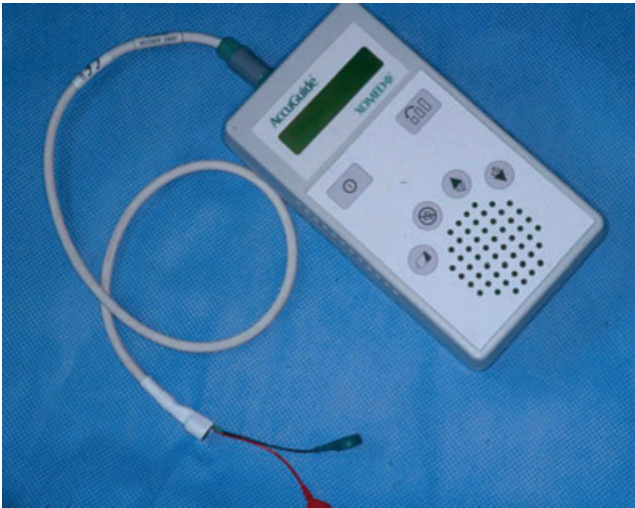


Figure 4 Pocket-sized EMG machine used for injection guidance

The masseter muscle originates in the inferior border of the zygomatic arch and inserts into the lateral surface of the ramus and the coronoid process. The needle is inserted transcutaneously into the areas of maximal muscle tenderness. We generally use the dilution of 5U in 0.1 ml. Each individual masseter muscle receives a series of five injections of 0.1 ml solution yielding total dose of 25 U per individual muscle.

The lateral pterygoid muscle is identified intraorally by palpating the lateral pterygoid plate. The needle is placed between the pterygoid plate and the coronoid process of the mandible parallel to the length of the muscle. The EMG signal should be robust with lateral excursion of the jaw. We generally inject 7.5 U in 0.3 ml at several positions along the length of the muscle.

If there is coexisting pain and tenderness in other muscle groups we will often administer concomitant treatment. Muscles of the occipital area, cervical region (see Figure 5), and back are addressed based upon patient report and the finding of tenderness on palpation. Pain may be present at the occipital region (lateral to the protuberance), yet more often is located in the paraspinal area adjacent to the nuchal line. Within this region, the trapezius muscle, splenius capitis, and semispinalis muscles converge. Precision is not crucial within this region, and injections should be correlated with areas of maximal tenderness. Larger doses (5–15 U per area) and larger injection volumes are acceptable, as extravasation will enhance the regional penetrance of the toxin.

Adverse effects are often mild or transient, and can usually be minimized through proper injection technique. The most significant adverse effects involve sequelae of weakening or paralyzing muscles at or near the injection site. Most local complications are cosmetic in nature. Very few of the complications reported during cosmetic BoNT-A administration have been noted when treating headache disorders. Adverse effects reported during the treatment of headache disorders include blepharoptosis, brow ptosis, diplopia, and muscle weakness at the site of injection (Silberstein *et al*,

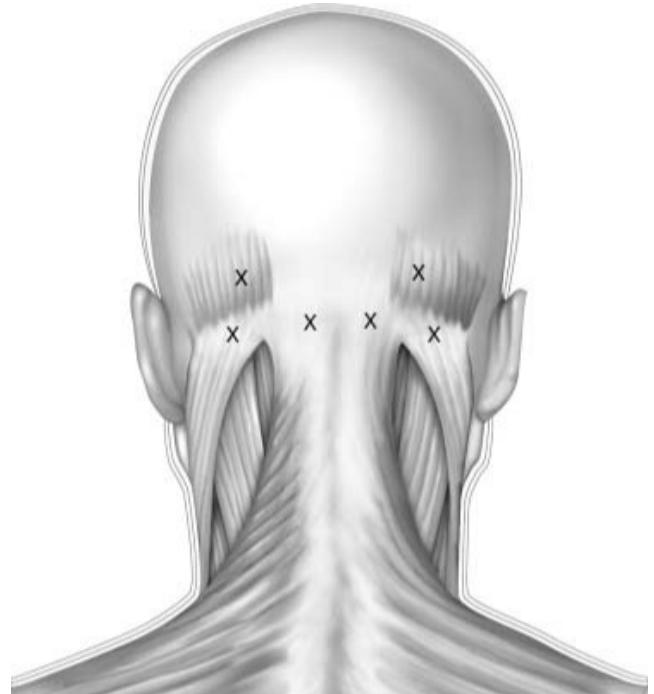


Figure 5 Injection sites of the occipitalis muscle and muscles along the nuchal line

2000). Various minor sequelae associated with needle injections such as bruising and local tenderness have been observed.

The pain relief from BoNT-A may take several weeks to reach maximal effect. Patients should maintain an accurate headache diary during the course of botulinum injections, documenting the time, severity, duration, and frequency of all headache events. Any medications taken to relieve acute breakthrough headaches should be noted. The patient should return for reevaluation at 4–6 weeks following the previous injection to document any adverse effects or suboptimal responses. Additional BoNT-A may be administered at that time as dictated by the clinical examination.

Repeated injections are necessary as the botulinum effect subsides. There is tremendous variation among patients with respect to optimal dosing frequency. Some patients experience relief well beyond the predicted pharmacokinetic duration of the drug. This suggests a possible neuromodulating effect of the toxin at the level of the CNS. In addition, the response to toxin injection may change over time, with some patients reporting greater therapeutic effect with repeat injections (Mathew and Kaup, 2002). While the majority of patients require repeat injections at 3- to 4-month intervals significantly longer intervals of relief have been observed. Pain diaries serve as a useful guide for the physician to direct future treatment.

Discussion

Botulinum toxin type A is a paralytic neurotoxin whose main action is to inhibit Ach release at the

neuromuscular junction. FDA approved for treating blepharospasm, strabismus, hemifacial spasm, cervical dystonia, glabellar lines and hyperhidrosis, BoNT-A has been safely used to treat hyperfunctional facial lines, other dystonias, spasticity, and tremor of the head and neck. BoNT-A also blocks Ach release at parasympathetic nerve terminals and is used to treat sialorrhea and hyperhidrosis. The indications that BoNT-A may be effective for treating pain disorders stemmed from anecdotal reports of patients being treated for hyperfunctional facial lines. These patients noticed marked reduction in the frequency and severity of headache episodes and facial tension (Carruthers, 1999). Investigators have often observed that pain improvement after BoNT-A treatment often did not always correspond to the region of neuromuscular effects, suggesting an independent effect on pain pathways (Brin *et al*, 1987). BoNT-A is now being used for pain relief as a primary treatment goal in conditions such as myofascial pain (Cheshire *et al*, 1994), tension headache (Zwart *et al*, 1994), migraine (Binder *et al*, 1998), and post-herpetic neuralgia.

The pathophysiology of TMD pain is poorly understood. In some patients, there is obvious clinical evidence of TMJ erosion and ankylosis and hyperfunction of the muscles of mastication, however in many patients, no readily identifiable anatomic reason for their complaint exists, or the anatomic deformity is out of proportion to the degree of pain produced. TMD has been considered on some level to be an idiopathic pain disorder (Diatchenko *et al*, 2006). Maixner *et al* put forth a discussion that physical and psychological triggers initiate a cycle of pain amplification and psychological distress (Maixner *et al*, 1998).

There are many fundamental questions regarding the etiology of pain associated with TMD. It is unclear whether the source of pain is muscular, joint, or nerve. In many ways, the success of BoNT on chronic pain disorders caused a reexamination of beliefs regarding sensory pathways. BoNT appears not to have any effect on the immediate discharge of sensory nerves. Blersch *et al* (2002) performed a randomized study on the effects of BoNT on pain reception on human volunteers. BoNT was injected subcutaneously and the right and left arm pain thresholds compared with heat and electrical pain. The authors did not find any difference between arms.

The mechanism by which BoNT-A relieves pain is unclear; however, various hypotheses have been described. They include direct effects at the neuromuscular junction and direct antiproceptive effects on nerves of the head and neck. Recent evidence suggests that BoNT-A may also inhibit the release of various neuropeptides and neuromodulators and block the transmission of afferent neuronal signals (Volkandt, 1995).

The specificity of BoNT-A for cholinergic neurons is based on specific binding receptors that are commonly found on motor nerves and parasympathetic nerves (Black and Dolly, 1986). However, given its ability to access the intracellular compartment,

inhibition of other neurotransmitters released by SNARE proteins can also take place. BoNT-A has been found to inhibit substance P release (Welch *et al*, 2000) and CGRP from sensory neurons (Durham *et al*, 2004). Substance P is primarily released by nociceptive afferents (C fibers) and CGRP is an inflammatory neuropeptide that is co-localized with substance P in most trigeminal and other sensory ganglia neurons. Cui *et al* (2004) demonstrated dose-dependent inhibition of formalin-induced inflammatory pain in rats. Further experiments looking at Fos expression in dorsal horn neurons of the rat spine suggest that BoNT-A does not have a direct action on the activation of sensory neurons but appears to block second phase activity that mediates neurogenic inflammation. Aoki (2005) hypothesized that this would reduce inflammatory pain and peripheral input to the spinal cord and reduce nociceptive processing at the spinal cord level via inhibition of peripheral sensitization, with a rise in the pain threshold.

Peripheral sensitization and neurogenic inflammation with alterations in the CNS processing of afferent signals is a potential mechanism for the development of pain syndromes. The understanding of the interaction between the peripheral sensory system and the CNS has been expanding in recent years and there is a growing body of work that supports the importance of sensitized afferents in the site of injury. Harriott *et al* (2006) studied the masseter muscles of rats after inducing chemical inflammation (Freund's adjuvant). The authors demonstrated hyperexcitability of the sensory receptors and neurons within the trigeminal ganglia.

An open label prospective evaluation of 13 patients with trigeminal neuralgia treated with BoNT reported significant improvement in all patients. These patients were given subcutaneous injections of BoNT-A in the distribution of their pain. The study reported significant pain relief and reduction in medication use. These effects lasted 60 days (Piovesan *et al*, 2005).

Inflamed sensory nerves have reduced thresholds and increased excitability (Treede *et al*, 1992). This feature has been demonstrated in various organ systems such as bladder (Yoshimura and de Groat, 1999), colon (Beyak *et al*, 2004), and skin (Andrew and Greenspan, 1999). Studies of muscles demonstrate a heightened sensitivity after inflammation that is mediated by alterations in ion channels (Radhakrishnan *et al*, 2003; Ambalavanar *et al*, 2006). Alterations in sodium and potassium channels in the nociceptors of the TMJ in rats showed similar changes and increased excitability (Flake and Gold, 2005). Although the body of evidence consistently suggests that inflammation induces a hyperexcitable state, it is unclear whether the changes are caused by mediators within the nerve itself or in the target tissue. It has been observed that the mechanisms of hyperexcitability differ depending on the target tissue. Gold and Traub (2004) demonstrated differences between the colon and skin dorsal root ganglion cells in reaction to inflammation mediated by prostaglandin 2 injection. They noted that sensitization may be tissue specific and they hypothesized that it may be possible to treat pain

arising from different body parts with unique therapeutic interventions. The innate properties of the trigeminal ganglia in response to neurogenic inflammators may at some point be a target for chronic orofacial pain. As BoNT-A has been shown to decrease the release of inflammatory mediators, there may be a role for the treatment of primary joint disease. There are several ongoing studies evaluating intra-articular injections for arthritis. Reduction in joint pain may also increase the pain thresholds centrally.

Few clinical trials have evaluated the efficacy of BoNT, especially for TMD. Freund and Schwartz reported using BoNT in 46 patients with TMD. By using 150 U of BoNT-A to the masseters and temporalis muscles under electromyographic guidance, they reported significant reductions in pain, function, mouth opening, and tenderness to palpation (Freund and Schwartz, 2002). In a subsequent paper, they described successful treatment of a variety of disorders under the category of TMD such as bruxism and clenching, oromandibular dystonias, myofascial pain, trismus, hypermobility, masseter and temporalis hypertrophy, and headaches (Schwartz and Freund, 2002).

In an open-label study of 100 patients with TMD, we found a 60% response rate to BoNT-A injections. A response was defined as a 50% reduction of pain and/or frequency of pain. Some of the initial data we have from a just completed phase 2 FDA-approved double-blind trial shows a 70% reduction of pain at best during the study with the maximum effect between the 8- and 12-week period. The global assessment shows 7% unchanged, 7% with total resolution of pain, and 50% with marked improvement. The placebo group showed 40% unchanged from baseline. A full report of the data is pending further analysis.

There is a great deal of overlap between TMD and other head and neck pain disorders, including headache. The International Headache Society (IHS) criteria for chronic tension headache include symptoms of pain that is non-pulsatile, tightening, or pressing, a frontal-occipital location, bilateral, and not aggravated by physical activity. Significant overlap between TMD and chronic tension type headache has been observed. In one study, 77% of patients presenting with TMD met (IHS) diagnostic criteria for tension headache (Freund and Schwartz, 2002). In addition, when treated with BoNT, 100% ($n = 46$) of the patients with concomitant headache reported a 50% or greater reduction in symptoms.

Clinical evidence supports the use of BoNT injections for headache disorders. In one open-label study, 51% of migraine sufferers treated with prophylactic therapy reported complete responses, and an additional 38% reported partial responses. Complete responders reported a mean benefit of 4.1 months, while partial responders benefited for 2.7 months. Furthermore, 70% of patients treated acutely for migraine pain reported complete response (Binder *et al*, 2001). A multicenter randomized controlled trial studying botulinum treatment for tension-type headache showed a significant decrease in the number of headache free days at 90 days postinjection but not at 60 days (Silbertstein 2006).

Summary

Temporomandibular disorders are a common cause of chronic facial pain and headache. The disorder is thought to be secondary to hyperfunction of the muscles of mastication resulting in chronic inflammation and pain. TMD is considered a group of pathologies affecting the masticatory muscles, the TMJ, and related structures (McNeill, 1993). TMD pain may be muscular pain or joint pain and can be associated with headache, myofascial pain of the back and shoulders, and neck pain. There can be associated disorders within the TMJ such as ankylosis and arthritis, however these disorders can often be present without any accompanying joint pathology. Associated complaints include earache, headache, neck pain, and facial swelling.

Temporomandibular disorder is a widespread pain disorder of the head and neck. Chronic pain and associated symptoms significantly interfere with interpersonal relations, professional duties, and overall quality of life. Patients suffering from chronic pain have an increased risk of developing psychiatric disorders, particularly affective disorders such as depression. A detailed examination with appropriate diagnostic testing often allows the physician to classify the specific disorder and initiate an effective therapeutic plan.

Botulinum toxin, through poorly understood pathways, provides significant relief from facial pain in many of the patients, and reduces intensity, frequency, and duration of recurrent episodes when properly administered. We suggest that BoNT therapy be instituted after standard conservative therapy failure and before surgical interventions. Injection protocols, including fixed-site and follow-the-pain techniques, have provided lasting relief in patients with TMD, idiopathic facial pain, trigeminal neuralgia, and headache. The adverse effects from BoNT are often mild, transient, and limited to adjacent muscle weakness, which can often be avoided through the use of proper injection technique. Basic science and clinical trials are necessary to fully elucidate the efficacy of this treatment but BoNT therapy may provide a safe and effective means by which to treat TMD and other chronic pain disorders of the head and neck.

References

- Ambalavanar R, Moritani M, Moutanni A, Gangula P, Yallampali C, Dessem D (2006). Deep tissue inflammation upregulates neuropeptides and evokes nociceptive behaviors which are modulated by a neuropeptide antagonist. *Pain* **129**: 53–68.
- Andrew D, Greenspan JD (1999). Mechanical and heat sensitization of cutaneous nociceptors after peripheral inflammation in the rat. *J Neurophysiol* **82**: 2649–2656.
- Aoki KR (2005). Review of a proposed mechanism for the antinociceptive action of botulinum toxin type A. *Neurotoxicology* **26**: 785–793.
- Beyak MJ, Ramji N, Krol KM, Kawaja MD, Vanner SJ (2004). Two TTX-resistant Na⁺ currents in mouse colonic dorsal root ganglia neurons and their role in colitis-induced hyperexcitability. *Am J Physiol Gastrointest Liver Physiol* **287**: G845–G855.

- Binder W, Brin MF, Blitzer A, Schenrock L, Diamond B (1998). Botulinum toxin type A (BoNT-A) for migraine: an open label assessment. *Mov Disord* **13**: 241.
- Binder WJ, Brin MF, Blitzer A et al (2001). Botulinum toxin type A (BOTOX) for treatment of migraine headaches: an open label study. *Otolaryngol Head Neck Surg* **123**: 669–676.
- Black JD, Dolly JO (1986). Interaction of 125I-labeled botulinum neurotoxins with nerve terminals. I. Ultrastructural autoradiographic localization and quantitation of distinct membrane receptors for types A and B on motor nerves. *J Cell Biol* **103**: 521–534.
- Blersch W, Schulte-Mattler WJ, Przywara S, May A, Bigalke H, Wohlfarth K (2002). Botulinum toxin A and the cutaneous nociception in humans: a prospective, double-blind, placebo-controlled randomized study. *J Neurol Sci* **205**: 59–63.
- Blitzer A, Sulica L (2001). Botulinum toxin: basic science and clinical uses in otolaryngology. *Laryngoscope* **111**: 218–226.
- Blumenfeld A, Binder WJ, Blitzer A et al (2004). The emerging role of botulinum toxin type A in headache prevention. *Op Tech Otolaryngol Head Neck Surg* **15**: 90–96.
- Brin MF, Fahn S, Moskowitz C et al (1987). Localized injections of botulinum toxin for the treatment of focal dystonia and hemifacial spasm. *Mov Disord* **2**: 237–254.
- Brister H, Turner JA, Aaron LA, Mancl L (2006). Self efficacy is associated with pain, functioning and coping in patients with chronic temporomandibular disorder pain. *J Orofac Pain* **20**: 115–124.
- Carruthers A (1999). Improvement of tension-type headache when treating wrinkles with botulinum toxin A injections. *Headache* **39**: 662–5.
- Cheshire WP, Abashain SW, Mann JD (1994). Botulinum toxin in the treatment of myofascial pain syndrome. *Pain* **59**: 65–69.
- Cui M, Khanijou S, Rubino J, Aoki KR (2004). Subcutaneous administration of botulinum toxin A reduces formalin-induced pain. *Pain* **107**: 125–33.
- De Kanter RJ, Truin GJ, Burgersdijk RC et al (1993). Prevalence in the Dutch adult population and a meta-analysis of signs and symptoms of temporomandibular disorder. *J Dent Res* **72**: 1509–18.
- De Wijer A, De Leeuw JR, Steenks MH, Bosnian F (1996). Temporomandibular and cervical spine disorders: self-reported signs and symptoms. *Spine* **21**: 1638–1646.
- Diatchenko L, Nackley AG, Slade GD, Fillingim RB, Maixner W (2006). Idiopathic pain disorders – pathways of vulnerability. *Pain* **123**: 226–230.
- Durham PL, Cady R, Cady R (2004). Regulation of calcitonin gene-related peptide secretion from trigeminal nerve cells by botulinum toxin type A: implications for migraine therapy. *Headache* **44**: 35–42.
- Dworkin SF, Huggins KH, LeResche L et al (1990). Epidemiology of the signs and symptoms in temporomandibular disorders: clinical signs in cases and controls. *J Am Dent Assoc* **120**: 273–281.
- Dworkin SF, Huggins K, Wilson LE et al (2002a). A randomized clinical trial using research diagnostic criteria for temporomandibular disorders: axis I to target clinic cases for a tailored self care TMD program. *J Orofac Pain* **6**: 48–63.
- Dworkin SF, Turner JA, Mancl L et al (2002b). A randomized clinical trial of a tailored comprehensive care treatment program for temporomandibular disorders. *J Orofac Pain* **16**: 259–276.
- Flake NM, Gold MS (2005). Inflammation alters sodium currents and excitability of temporomandibular joint afferents. *Neurosci Lett* **384**: 294–299.
- Freund BJ, Schwartz M (2002). Relief of tension type headache symptoms in subjects with temporomandibular disorders treated with botulinum toxin-A. *Headache* **42**: 1033–1037.
- Freund B, Schwartz M, Symington JM (2000). Botulinum toxin: a new treatment for temporomandibular disorders. *Br J Oral Maxillofac Surg* **38**: 466–471.
- Gold MS, Traub RJ (2004). Cutaneous and colonic rat DRG neurons differ with respect to both baseline and PGE2-induced changes in passive and active electrophysiological properties. *J Neurophysiol* **91**: 2524–2531.
- Gremillion HA (2000). The prevalence and etiology of temporomandibular disorders and orofacial pain. *Tex Dent J* **117**: 30–39.
- Harriott AM, Dessem D, Gold MS (2006). Inflammation increases the excitability of master muscle afferents. *Neuroscience* **141**: 433–442.
- Jankovic J, Brin MF (1997). Botulinum toxin: historical perspective and potential new indications. *Muscle Nerve* **6**(Suppl.): S129–S145.
- Lipton JA, Ship JA, Larasch-Robinson D (1993). Estimated prevalence and distribution of reported orofacial pain in the United States. *J Am Dent Assoc* **124**: 115–121.
- Maixner W, Fillingim R, Sigurdsson A, Kincaid S, Silva S (1998). Sensitivity of patients with painful temporomandibular disorders to experimentally evoked pain: evidence for altered temporal summation of pain. *Pain* **76**: 71–81.
- Mathew NT, Kaup AO (2002). The use of botulinum toxin type A in headache treatment. *Curr Treat Options Neurol* **4**: 365–373.
- McFarlane TV, Blinkhorn AS, Davies RM, Kincy J, Worthington HV (2002). Orofacial pain in the community: prevalence and associated impact. *Community Dent Oral Epidemiol* **30**: 52–60.
- McMillan AS, Wong MCM, Zheng J, Lam CLK (2006). Prevalence of orofacial pain and treatment seeking in Hong Kong Chinese. *J Orofac Pain* **20**: 218–225.
- McNeill C, ed (1993). *Epidemiology. In: Temporomandibular disorders: guidelines for classification, assessment, and management*, 2nd edn. Quintessence Publishing Co.: Chicago, pp. 19–22.
- Morris S, Benjamin S, Gray R, Bennett D (1997). Physical, psychiatric and social characteristics of the temporomandibular disorder pain dysfunction syndrome: the relationship of mental disorders to presentation. *Br Dent J* **182**: 255–260.
- Ohrbach R, Stohler CS (1992). Review of the literature: a current diagnostic system. *J Craniomandib Disord* **6**: 307–317.
- Piovesan EJ, Teive HG, Kowacs PA, Coletta MV, Werneck LC, Silberstein SD (2005). An open study of botulinum-A toxin treatment of trigeminal neuralgia. *Neurology* **65**: 1306–1308.
- Pow EHN, Leung KCM, McMillan AS (2001). Prevalence of symptoms associated with temporomandibular disorders in Hong Kong Chinese. *J Orofac Pain* **15**: 228–234.
- Radhakrishnan R, Moore SA, Sluka KA (2003). Unilateral carageenan injection into muscle or joint induces chronic bilateral hyperalgesia in rats. *Pain* **104**: 567–577.
- Schwartz M, Freund B (2002). Treatment of temporomandibular disorders with botulinum toxin. *Clin J Pain* **18**: S198–S203.
- Silberstein S, Mathew N, Saper J et al (2000). Botulinum toxin type A as a migraine preventative treatment. For the BOTOX Migraine Clinical Research Group. *Headache* **40**: 445–450.

- Silbertstein SD, Gobel H, Jensen R *et al* (2006). Botulinum toxin type A in a prophylactic treatment of chronic tension-type headache: a multicentre, double-blind, randomized placebo-controlled, parallel-group study. *Cephalalgia* **26**: 790–800.
- Treede RD, Meter RA, Raja SN, Campbell JN (1992). Peripheral and central mechanisms of cutaneous hyperalgesia. *Prog Neurobiol* **38**: 397–421.
- Volkandt W (1995). Commentary: the synaptic vesicle and its targets. *Neuroscience* **64**: 277–300.
- Welch MJ, Prukiss JR, Foster KA (2000). Sensitivity of embryonic rat dorsal root ganglia neurons to Clostridium botulinum neurotoxins. *Toxicon* **38**: 245–258.
- Yoshimura N, de Groat WC (1999). Increased excitability of afferent neurons innervating rat urinary bladder after chronic bladder inflammation. *J Neurosci* **19**: 4644–4653.
- Zenz M, Strumph M, Tryba M (1997). Long-term oral opioid therapy in patients with chronic nonmalignant pain. *J Pain Symptom Manage* **7**: 69.
- Zwart JA, Bovim G, Sand T, Sjaastad O (1994). Tension headache: botulinum toxin paralysis of temporal muscles. *Headache* **34**: 458–462.

Copyright of Oral Diseases is the property of Blackwell Publishing Limited and its content may not be copied or emailed to multiple sites or posted to a listserv without the copyright holder's express written permission. However, users may print, download, or email articles for individual use.